



COMPARISON OF TVUS, MRI, AND FROZEN SECTION METHODS IN PREOPERATIVE DETECTION OF MYOMETRIAL INVASION IN PATIENTS WITH ENDOMETRIAL CANCER

Hasim Kural¹, Ercan Yilmaz¹, Rauf Melekoglu¹, Aysenur Akatli² and Leyla Karaca³

¹Inonu University Medicine Faculty, Obstetrics and Gynecology Department, Malatya, Turkey;

²Inonu University Medicine Faculty, Pathology Department, Malatya, Turkey;

³Inonu University Medicine Faculty, Radiology Department, Malatya, Turkey

SUMMARY – We aimed to evaluate the depth of myometrial invasion preoperatively with transvaginal ultrasound, magnetic resonance imaging, and frozen section examination techniques in patients diagnosed with endometrial cancer. Our study included 65 patients. Transvaginal ultrasound and magnetic resonance imaging were performed in study patients in the preoperative period. Frozen section examination was performed in all hysterectomy samples obtained from all study patients. Data were analyzed with SPSS Statistics 22.0 program. The sensitivity of transvaginal ultrasound in determining the depth of myometrial invasion was 88.64%, specificity 90.48%, positive predictive value 95.12%, and negative predictive value 79.17%. For magnetic resonance imaging, the sensitivity was 63.64%, specificity 95.24%, positive predictive value 96.55%, and negative predictive value 55.56%. In addition to the frozen section examination, which is the gold standard in determining the myometrial invasion depth, transvaginal ultrasound and magnetic resonance imaging have become commonly used methods for this purpose in recent years. Ultrasound examination performed by an experienced specialist is superior to magnetic resonance imaging as it is fast, inexpensive, and associated with higher sensitivity.

Key words: *Endometrial cancer; Myometrial invasion; TVUS; MRI; Frozen section*

Introduction

Endometrial cancer is the most frequent malignancy of all cancers of the female genital system, ranking fourth among cancer types of all organ systems in females. Since the disease is symptomatic at the early stage, a significant proportion of patients are diagnosed relatively early¹.

The main treatment approach is surgery and intraoperative frozen section examination of hysterectomy material provides important information to decide on

the mode of surgery. Frozen section examination offers information on the condition of the cervix, tumor size and diameter, and bilateral adnexa, as well as informing physicians on the depth of myometrial invasion². Invasion of cancer cells into more than 1/2 of the myometrial depth leads to the diagnosis of stage Ib endometrial carcinoma according to the International Federation of Gynecology and Obstetrics (FIGO) 2018 staging system, resulting in the inclusion of lymphadenectomy and omentectomy in addition to hysterectomy in the surgical procedure³. Determining the depth of myometrial invasion in the preoperative period allows for scheduling the precise mode of surgery for the treatment of these patients.

The method that evaluates myometrial invasion most precisely is intraoperative frozen section exami-

Correspondence to: *Assoc. Prof. Ercan Yilmaz, MD, PhD*, Inonu University Medicine Faculty, Obstetrics and Gynecology Department, Malatya, Turkey

E-mail: ercanyilmazgyn@yahoo.com

Received October 16 2019, accepted July 8, 2020

nation; however, involving some of the current imaging methods preoperatively also helps physicians in determining the depth of myometrial invasion. Transvaginal ultrasound (TVUS) and magnetic resonance imaging (MRI) are the leading techniques preferred to be used in the preoperative period in order to determine the depth of invasion of cancer cells into the myometrium⁴.

In this study, we selected and scheduled the most appropriate surgical approach in the preoperative period by evaluating the depth of myometrial invasion with TVUS and MRI in patients diagnosed with endometrial cancer and we compared the efficacy of both of these imaging methods to the findings obtained by frozen section examination.

Patients and Methods

Patient selection

Our study included a total of 65 patients diagnosed with endometrial carcinoma. Patients with a family history of cancer, those diagnosed with any other type of tumor in body organs or systems, and patients with a history of chemotherapy or radiotherapy were excluded from the study. Based on the results of endometrial biopsy examination, only patients with a diagnosis of endometrioid adenocarcinoma were included in the study, whereas patients with other histopathologic diagnoses were excluded. TVUS, computed tomography (CT), and MRI were performed to determine invasion in the preoperative period. Intraoperative and postoperative hysterectomy materials were examined to determine the depth of myometrial invasion by an expert pathologist.

Frozen section and final pathological examination procedures

Total abdominal hysterectomy and bilateral salpingo-oophorectomy (TAH + BSO) materials were submitted to the pathology laboratory for intraoperative examination. The size of the uterus, uterine tubes, and ovaries were measured and the endometrial and myometrial depth were determined intraoperatively. After evaluating tumor localization and its size, the depth of myometrial invasion and total thickness of the myometrial wall were measured in the deepest area of invasion in the myometrium by taking slices at 4–5 mm

intervals from the anterior and posterior aspects of the uterus. The condition of the adnexa and the presence of an extension to the cervix were determined macroscopically. Depending on the macroscopic appearance and distribution of the tumor, 1 to 3 slices were taken from the deepest areas of myometrial invasion, extending from the endometrium to serosa, and these samples were examined intraoperatively. Samples were also taken from the respective areas and they were examined in patients with suspected ovarian and cervical involvement macroscopically. The findings of the intraoperative examination were reported to the clinician, including the diameter, type, and grade of the tumor, the depth of myometrial invasion, and the presence of cervical and/or adnexal involvement. The terminology to define surgical staging is based on the morphology criteria as grade 1–2 endometrioid tumor with the depth of invasion involving more than upper half of the myometrium, grade 3 endometrioid tumor, cervical extension of the tumor, and non-endometrioid tumor. The intraoperatively evaluated parameters including histologic type, grade, and size of the tumor, any presence of lymphovascular invasion, and the depth of myometrial invasion were examined once more in the permanent paraffin sections taken from the macroscopically collected samples. The histopathologic differences among the findings of intraoperative consultation, the findings of final pathologic examination, and the results of the US and MRI were examined in terms of their consistency.

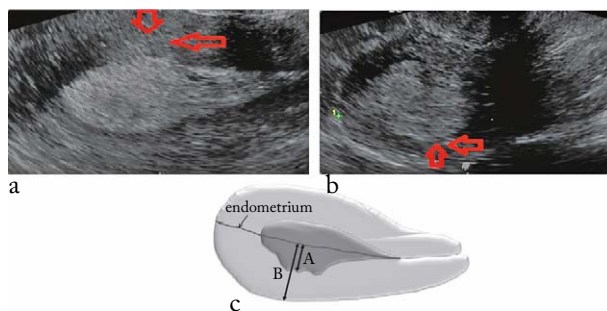
Transvaginal ultrasound examination

After the bladder was emptied, the patient lay on the gynecologic examination table in the lithotomy position. The same clinician conducted the ultrasound examination for every study patient using the IC5-9-D 7 MHz transducer of the Voluson E6 (GE Healthcare, Milwaukee, WI, USA) ultrasound device. Endometrial thickness was measured from the point where the thickness was maximum in the sagittal sections of the uterus, including both endometrial layers. Based on the examination findings, the patients were classified according to the degree of myometrial invasion as follows: (a) in the presence of a continuous halo surrounding the endometrial echoes or in the absence of any endometrial echo extending to the myometrium, it was accepted that there was no invasion. When endometrial echoes extended only to the first half of

the myometrial depth, it was accepted that the invasion was $<50\%$; and (b) when endometrial echoes extended beyond the first half of the myometrium, it was accepted that the invasion was $\geq 50\%$ (Fig. 1).

Magnetic resonance imaging protocol

Magnetic resonance imaging was performed using a 3 Tesla MR (Siemens, Erlangen, Germany) and 32-channel body coil. The imaging was performed in the one-hour period before the examination when the rectum was empty and the bladder was moderately filled. Turbo spin echo (TSE) images were obtained in



*Fig. 1. Evaluation of myometrial invasion by transvaginal ultrasound: (a) myometrial invasion $< 1/2$; (b) myometrial invasion $> 1/2$; (c) schematic presentation of the evaluation of myometrial invasion: (A) maximum distance of tumor depth; (B) total myometrial thickness; (A/B) invasion rate; *schematic figure is taken from reference number 15; red arrows indicate the depth of myometrial invasion.*

the axial, sagittal, and coronal planes. Myometrial invasion depth of the tumor was measured in the axial plane in the contrast-enhanced T1-weighted series. The thickness of the whole myometrium was measured in the T2-weighted sagittal images. The diameter of the tumor was measured three-dimensionally in the axial and sagittal T2-weighted series. Imaging parameters were obtained from the fast spin echo sequences and imaging in T2-weighted sequences (repetition time [TR] ms/echo time [TE] ms, 1600/89; average, 3; matrix, 256 \times 320; field of view (FOV), 20 cm). DW MR imaging was performed using a single-shot echo-planar technique (TR/TE, 5500/56; average, 1; section thickness, 3 mm; range, 1 mm; matrix, 128 \times 128; FOV, 20 cm). Apparent diffusion coefficient (ADC) maps were created using 0, 400, and 800 s/mm² b values and isotropic DW images (Syngo, Siemens, Erlangen, Germany). Dynamic contrast-enhanced (DCE) MRI was performed on the axial plane at 0, 30, 60, 90, and 120 seconds (3.3/1.3; NEX 1; matrix, 256 \times 320; FOV, 20 cm) and on the sagittal plane in the 180th second after the intravenous bolus injection of the contrast medium (gadopentetate dimeglumine, Magnevist, Schering, Berlin, Germany) at a dose of 0.1 mmol/kg (Fig. 2).

Total abdominal hysterectomy and bilateral salpingo-oophorectomy

The patient was prepared for the surgery under general anesthesia. The abdomen was entered through

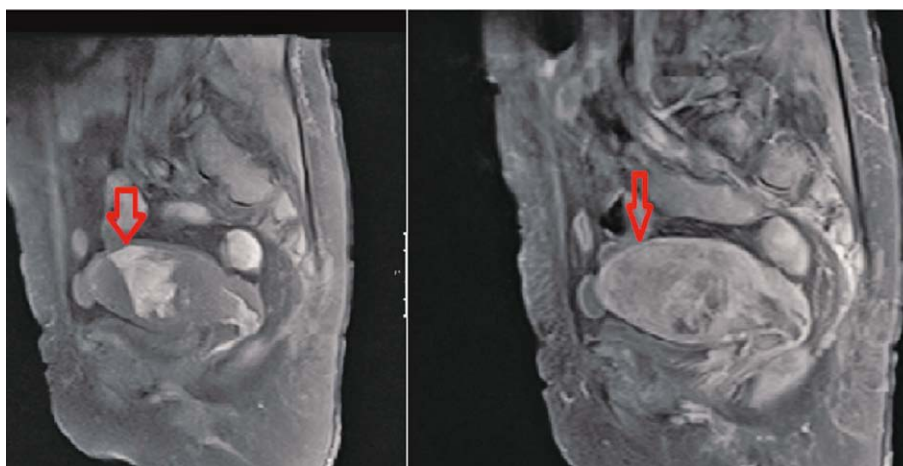


Fig. 2. Myometrial invasion extending to serosa in the T2-weighted and T1 post-contrast sagittal sections of magnetic resonance image; red arrows indicate the depth of myometrial invasion.

a median or Pfannenstiel incision below the umbilicus. Bilateral round ligaments, infundibulopelvic ligaments, and uterine arteries were clamped, cut, and ligated. The bladder and the rectum were released from the anterior and posterior aspects, respectively. The sacrouterine and cardinal ligaments were clamped, cut, and ligated. The vaginal cuff was sutured shut with individual stitches.

Pelvic and para-aortic lymph node dissection

Pelvic lymphatic tissue dissection started from the external iliac artery region. The dissections extended to the level of aortic bifurcation superiorly and to the level of the inguinal ligament and deep circumflex iliac vein inferiorly. Bilateral external iliac, internal iliac, and obturator lymph node dissections were performed. Para-aortic lymph node dissections were performed after incising the peritoneum on the lower aorta and right common iliac vessels. The surgical site was carefully examined by inspection and palpation. Para-aortic lymph node dissection started immediately below the level of the bifurcation of the aorta and extended superiorly to the level of the renal vein. After the inferior mesenteric artery, the anterior wall of the inferior vena cava, and the lymph nodes on the right side of the aorta were elevated and resected by sharp dissections. Lymph node dissection was performed using a 17-cm harmonic ligature at 55.5 kHz frequency (Harmonic Focus, New Jersey, USA).

Omentectomy

After the omentum was released and clamped superiorly, a dissection line was formed in the serosa of the transverse colon. Then, omentectomy was performed starting from the right transverse colon at the infracolic region. Omentectomy was performed using an Ethicon Endo-Surgery Tissue Sealer G2 22 cm and a Super Jaw Enseal.

Statistical analysis

Data were expressed as mean (standard deviation) and numbers (percentage). Shapiro-Wilk test was used to determine data conformity to normal distribution. For statistical data analysis, Mann-Whitney U test, Yates' correction for the χ^2 -test, Pearson correlation coefficient, and diagnostic tests (receiver operating characteristic [ROC] curve analysis, sensitivity, specificity,

etc.) were used where appropriate. The level of statistical significance was set at $p < 0.05$ for all kinds of tests. IBM SPSS Statistics 22.0 program was used to perform statistical analyses.

Results

A total of 65 patients with endometrial cancer, mean age 60.75 ± 12.28 , were included in our study.

Table 1. Demographic, surgical, and histopathologic features of study patients

	Mean \pm SD, n (%)
Age (yrs)	60.75 \pm 12.28
Complaint:	
menometrorrhagia	14 (22%)
PMH	51 (77%)
Surgical procedure:	
TAH + BSO	34 (52%)
TAH + BSO + PLND	15 (23%)
TAH + BSO + PPLND	16 (25%)
Number of lymph nodes:	
pelvic	25.52 \pm 10.68
para-aortic	14.88 \pm 4.01
Stage:	
Ia	42(64.6%)
Ib	8 (12.3%)
II	4 (6.2%)
IIIa	7 (10.8%)
IIIb	1 (1.5%)
IIIc1	1 (1.5%)
IIIc2	2 (3.1%)
Tumor size (mm)	43.2 \pm 21.5
Grade:	
1	29 (44%)
2	18 (18%)
3	18 (18%)
LVI:	
positive	26 (40%)
negative	39 (60%)
Radiotherapy:	
brachytherapy	13 (20%)
external	17 (26%)
Chemotherapy:	
yes	15 (23%)
no	50 (77%)

SD = standard deviation; n = number of patients; PMH = postmenopausal hemorrhage; TAH + BSO = total abdominal hysterectomy and bilateral salpingo-oophorectomy; PLND = pelvic lymph node dissection; PPLND = para-aortic lymph node dissection; LVI = lymphovascular area invasion

Table 2. Sensitivity, specificity, PPV, and NPV (in percentages) of TVUS, MRI, and frozen section examination in determining myometrial invasion

	TVUS (%)	MRI (%)	Frozen section examination (%)
Sensitivity	88.64	63.64	100
Specificity	90.48	95.24	85.71
PPV	95.12	96.55	93.62
NPV	79.17	55.56	100

TVUS = transvaginal ultrasound; MRI = magnetic resonance imaging; PPV = positive predictive value; NPV = negative predictive value

When the presenting complaints of the patients were examined in general, it was found that 51 (78%) patients were admitted to the hospital with postmenopausal vaginal bleeding and 14 (22%) patients with menometrorrhagia. TAH + BSO was performed in 34 patients, TAH + BSO + pelvic lymph node dissection (PLND) in 15 patients, and TAH + BSO + omentectomy and pelvic para-aortic lymph node dissection (PPLND) in 16 patients. The mean number of dissected pelvic lymph nodes was 25.52 ± 10.68 and the number of dissected para-aortic lymph nodes was 14.88 ± 4.01 . Based on the FIGO staging system, 42 patients were in stage Ia, 8 patients in stage Ib, 4 patients in stage II, 7 patients in stage IIIa, 1 patient was in stage IIIb, 1 patient was in stage IIIc1, and 2 patients were in stage IIIc2. The mean tumor size was 43.2 ± 21.5 mm. Histopathologic examination of the specimens revealed the diagnoses of grade 1 tumors in 29 (44%), grade 2 tumors in 18 (18%), and grade 3 (18%) tumors in the remaining 18 patients. The lymphovascular area invasion (LVI) was considered positive in a total of 26 patients, while it was reported to be negative in 39 patients. In the postoperative period, 30 patients received adjuvant radiotherapy, of which 13 (20%) received brachytherapy and 17 (26%) received external irradiation. A total of 15 (23%) patients received adjuvant chemotherapy treatment (Table 1).

In all patients, TVUS and MRI were performed in order to determine the depth of myometrial invasion preoperatively. The hysterectomy materials of all study patients were submitted to a frozen section examination and the depth of myometrial invasion was determined clearly. The sensitivity of TVUS was 88.64%, its specificity was 90.48%, its positive predictive value (PPV) was 95.12%, and its negative predictive value (NPV) was 79.17% in determining the depth of myometrial invasion. For MRI, the sensitivity was 63.64%,

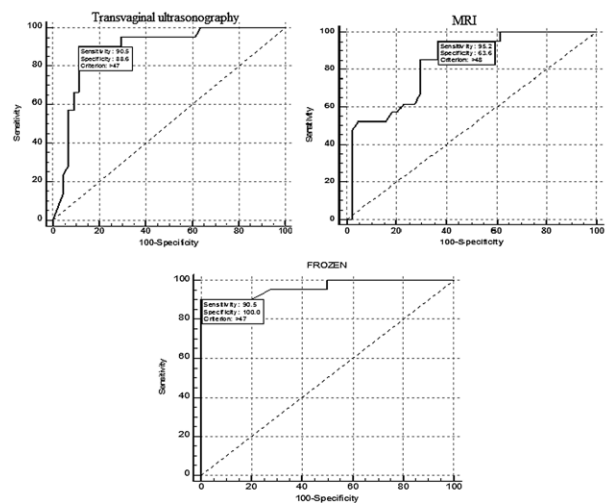


Fig. 3. Sensitivity and specificity of transvaginal ultrasound, MRI, and frozen section examination in determining the depth of myometrial invasion.

MRI = magnetic resonance imaging

specificity was 95.24%, PPV was 96.55%, and NPV was 55.56% (Table 2, Fig. 3).

Discussion

The most common type of tumor of the female genital tract is endometrial cancer and the standard treatment is TAH + BSO. There is a strong correlation between the incidence of lymphatic metastasis and the depth of myometrial invasion in this type of tumors. As myometrial invasion extends deeper (especially if it extends beyond half of the myometrial thickness), the disease is considered stage Ib according to the FIGO staging system. At this stage of the disease, the likelihood of pelvic and/or para-aortic lymph node metastases increases, requiring lymphadenectomy to be per-

formed along with the standard surgical procedures. Several publications have reported that the presence of deep myometrial invasion is associated with an increased rate of lymph node metastases^{6,7}.

The necessity of lymphadenectomy in the surgical treatment of endometrial cancer has been a matter of debate in recent years. The overall survival (OS) and disease-free survival (DFS) data after this mode of surgery are far from meeting the expectations. As it has been well established, systematic lymphadenectomy in FIGO stage Ib and beyond and in grade 3 tumors affects the OS and DFS significantly while it is still a subject of debate to perform systematic lymphadenectomy in early stage endometrial cancers⁸. Mariani *et al.* demonstrated that lymphadenectomy had no favorable effects on the early stage and grade 1-2 tumors and in patients with a myometrial invasion depth <1/2. Another study by Panici *et al.* included patients with similar characteristics to that of Mariani *et al.* study and concluded that systemic lymphadenectomy did not significantly contribute to DFS and OS^{9,10}. This has led physicians to perform some preoperative investigations to determine the need for lymphadenectomy in patients diagnosed with endometrial cancer and the most reasonable approach has been determination of the depth of myometrial invasion. Some techniques used for evaluating the depth of invasion provide physicians with the insight into which type of surgery should be scheduled.

The basic and most reliable technique for the evaluation of myometrial invasion is frozen section examination of the hysterectomy material intraoperatively. Studies have shown that the sensitivity of the frozen section examination varies from 80% to 96.5%¹¹. Aidos *et al.* performed a study on 286 patients and demonstrated that the sensitivity of the frozen section examination was 96.25% in diagnosing endometrial cancer and in determining the depth of myometrial invasion¹². A meta-analysis reports that the frozen section examination was the gold standard in endometrial cancer, especially in determining the depth of myometrial invasion¹³.

Preoperative imaging methods can also provide information on the depth of invasion. Within this scope, the easiest and cheapest technique is TVUS. In a study on cancer patients, the sensitivity and specificity of TVUS in determining the depth of myometrial inva-

sion have been reported to be 81.6% and 89.5%, respectively. In the same study, the sensitivity of performing only macroscopic examination was found to be 78.9% in determining the depth of invasion¹⁴. In a meta-analysis examining the findings of a total of 184 publications, it is reported that the sensitivity of TVUS was 82% in determining the depth of myometrial invasion, concluding that ultrasound imaging was found to be reliable for this purpose¹⁵.

Magnetic resonance imaging is another imaging modality used to determine the depth of invasion. Compared to ultrasound, it has a significant disadvantage as it is a more expensive method, however, the sensitivity of MRI in determining the depth of myometrial invasion was found to be 84.2% in 167 patients diagnosed with endometrial cancer¹⁶. In a meta-analysis evaluating the results of 50 studies including a total of 3720 patients, the sensitivity of MRI in determining the depth of myometrial invasion is reported to be 80.7%¹⁷.

A review of the studies examining the superiority of each of the three methods has revealed that TVUS is more advantageous compared to MRI, providing higher accuracy rates. In a study of 177 patients who were evaluated with TVUS and MRI preoperatively, the rate of detecting the depth of invasion was found to be 66.9% for TVUS and 64% for MRI¹⁸. In another study evaluating the efficacy of frozen section examination and TVUS on 77 patients diagnosed with endometrial cancer, the sensitivity in detecting myometrial invasion depth was 87.8% for TVUS and 85.7% for frozen section examination. The authors report that ultrasound could be used reliably by experienced physicians in the preoperative period as its accuracy rate was as high as that of frozen section examination¹⁹. In another study of 51 patients diagnosed with endometrial cancer, the MRI findings were compared with the findings of the intraoperatively performed frozen section examination in regards to determining the depth of myometrial invasion. It was found that both methods yielded similar results (the sensitivity of both MRI and frozen section examination was 90.2%)²⁰. In our study, we obtained the highest accuracy rates with frozen section examination, consistent with the literature. TVUS demonstrated a higher sensitivity compared to MRI (88.64% *vs.* 63.64%), although it did not reveal findings as accurate as frozen section examination.

Conclusions

Lymphadenectomy does not contribute to OS and DFS in the surgical treatment of early-stage endometrial cancer (FIGO stage Ia, grade 1-2 tumors), as the current literature indicates. Systematic lymphadenectomy is a recommended approach in FIGO stage Ib cases, which are characterized by invasion of $>1/2$ of the myometrial depth. Especially in cases where frozen section examinations are not possible, determining the depth of invasion in the preoperative period provides very useful information for the patients and physicians and enables the surgeon to schedule surgical approach before the operation in advance. TVUS and MRI are the leading imaging modalities commonly used for this purpose. Besides the frozen pathology examination, which is used as the gold standard for determining the depth of myometrial invasion, these imaging modalities have also become common. As MRI is an expensive and time-consuming method, it has been found that it is not more advantageous than TVUS based on the results of our study and the reports in the literature. Being inexpensive and easy to perform, TVUS has been found to be more advantageous in determining the depth of myometrial invasion when it is performed by experienced specialists.

References

1. Yilmaz E, Coskun EI, Gul M, Sahin N, Tuncay G, Simsek Y. Nuclear factor-kappa beta pathway and endometrial cancer: a pilot study. *Eur J Gynecol Oncol.* 2017;38(4):536-40. DOI: 10.12892/ejgo3471.2017
2. Tanaka T, Terai Y, Fujiwara S, Tanaka Y, Sasaki H, Tsunetoh S, *et al.* Preoperative diffusion-weighted magnetic resonance imaging and intraoperative frozen sections for predicting the tumor grade in endometrioid endometrial cancer. *Oncotarget.* 2018;9(93):36575-84. DOI: 10.18632/oncotarget.26366
3. Amant F, Mirza MR, Koskas M, Creutzberg CL. Cancer of the corpus uteri. *Int J Gynaecol Obstet.* 2018;143 Suppl 2:37-50. DOI: 10.1002/ijgo.12612.
4. Rizzo S, Femia M, Radice D, Del Grande M, Franchi D, Origi D, *et al.* Evaluation of deep myometrial invasion in endometrial cancer patients: is dual-energy CT an option? *Radiol Med.* 2018;123(1):13-9. DOI: 10.1007/s11547-017-0810-2
5. Ozdemir S, Celik C, Emlik D, Kiresi D, Esen H. Assessment of myometrial invasion in endometrial cancer by transvaginal sonography, Doppler ultrasonography, magnetic resonance imaging and frozen section. *Int J Gynecol Cancer.* 2009;19(6):1085-90. DOI: 10.1111/IGC.0b013e3181ad3eb6
6. Toptas T, Simsek T, Karaveli S. Prognostic risk factors for lymph node involvement in patients with endometrial cancer. *Turk J Obstet Gynecol.* 2017;14(1):52-7. DOI: 10.4274/tjod.52385
7. Akbayir O, Corbacioglu A, Goksedef BP, Numanoglu C, Akca A, Guraslan H, *et al.* The novel criteria for predicting pelvic lymph node metastasis in endometrioid adenocarcinoma of endometrium. *Gynecol Oncol.* 2012;125(2):400-3. DOI: 10.1016/j.ygyno.2012.01.051
8. Gasparri ML, Caserta D, Benedetti Panici P, Papadia A, Mueller MD. Surgical staging in endometrial cancer. *J Cancer Res Clin Oncol.* 2018;20:1-9. DOI: 10.1007/s00432-018-2792-4
9. Mariani A, Dowdy SC, Cliby WA, Gostout BS, Jones MB, Wilson TO, *et al.* Prospective assessment of lymphatic dissemination in endometrial cancer: a paradigm shift in surgical staging. *Gynecol Oncol.* 2008;109(1):11-8. DOI: 10.1016/j.ygyno.2008.01.023
10. Panici PB, Basile S, Maneschi F. Systematic pelvic lymphadenectomy *versus* no lymphadenectomy in early-stage endometrial carcinoma: randomized clinical trial. *J Natl Cancer Inst.* 2008;100(23):1707-16.
11. Ozturk E, Dikensoy E, Balat O, Ugur MG, Aydin A. Intraoperative frozen section is essential for assessment of myometrial invasion but not for histologic grade confirmation in endometrial cancer: a ten-year experience. *Arch Gynecol Obstet.* 2012;285(5):1415-9. DOI: 10.1007/s00404-011-2135-z
12. Aidos J, Verissimo R, Almeida J, Carvalho T, Martins NN, Martins FN. Frozen section in the management of ovarian and uterine tumors: the past 5 years in a tertiary centre. *Rev Bras Ginecol Obstet.* 2018;40(8):458-64. DOI: 10.1055/s-0038-1668526
13. Wang X, Li L, Cragun JM, Chambers SK, Hatch KD, Zheng W. Assessment of the role of intraoperative frozen section in guiding surgical staging for endometrial cancer. *Int J Gynecol Cancer.* 2016;26(5):918-23. DOI: 10.1097/IGC.0000000000000692
14. Pineda L, Alcázar JL, Caparrós M, Mínguez JA, Idoate MA, Quiceno H, *et al.* Agreement between preoperative transvaginal ultrasound and intraoperative macroscopic examination for assessing myometrial infiltration in low-risk endometrioid carcinoma. *Ultrasound Obstet Gynecol.* 2016;47(3):369-73. DOI: 10.1002/uog.14909
15. Alcázar JL, Orozco R, Martínez-Astorquiza Corral T, Juez L, Utrilla-Layna J, Mínguez JA, *et al.* Transvaginal ultrasound for preoperative assessment of myometrial invasion in patients with endometrial cancer: a systematic review and meta-analysis. *Ultrasound Obstet Gynecol.* 2015;46(4):405-13. DOI: 10.1002/uog.14905
16. Teng F, Zhang YF, Wang YM, Yu J, Lang X, Tian WY, *et al.* Contrast-enhanced MRI in preoperative assessment of myometrial and cervical invasion, and lymph node metastasis: diagnostic value and error analysis in endometrial carcinoma. *Acta Obstet Gynecol Scand.* 2015;94(3):266-73. DOI: 10.1111/aogs.12570

17. Luomaranta A, Leminen A, Loukovaara M. Magnetic resonance imaging in the assessment of high-risk features of endometrial carcinoma: a meta-analysis. *Int J Gynecol Cancer*. 2015;25(5):837-42. DOI: 10.1097/IGC.0000000000000194
18. Yahata T, Aoki Y, Tanaka K. Prediction of myometrial invasion in patients with endometrial carcinoma: comparison of magnetic resonance imaging, transvaginal ultrasonography, and gross visual inspection. *Eur J Gynaecol Oncol*. 2007;28(3):193-5.
19. Fishman A, Altaras M, Bernheim J, Cohen I, Beyth Y, Tepper R. The value of transvaginal sonography in the preoperative assessment of myometrial invasion in high and low grade endometrial cancer and in comparison to frozen section in grade 1 disease. *Eur J Gynaecol Oncol*. 2000;21(2):128-30.
20. Gallego JC, Porta A, Pardo MC, Fernandez C. Evaluation of myometrial invasion in endometrial cancer: comparison of diffusion-weighted magnetic resonance and intraoperative frozen sections. *Abdom Imaging*. 2014;39(5):1021-6. DOI: 10.1007/s0061-014-0134-9

Sažetak

USPOREDBA TRANSVAGINALNOG ULTRAZVUKA, MAGNETSKE REZONANCIJE I METODE SMRZNUTIH REZOVA U PRIJEOPERACIJSKOM OTKRIVANJU ZAHVAĆENOSTI MIOMETRIJA U BOLESNICA S KARCINOMOM ENDOMETRIJA

H. Kural, E. Yilmaz, R. Melekoglu, A. Akatli i L. Karaca

Cilj je bio prijeoperacijski procijeniti dubinu zahvaćenosti miometrija pomoću transvaginalnog ultrazvuka, magnetske rezonancije i metode smrznutih rezova u bolesnica s dijagnozom karcinoma endometrija. Istraživanje je obuhvatilo 65 bolesnica. Transvaginalni ultrazvuk i magnetska rezonancija provedeni su kod ovih bolesnica u prijeoperacijskom razdoblju. Ispitivanje smrznutih rezova provedeno je na uzorcima prikupljenim tijekom histerektomije kod svih bolesnica uključenih u istraživanje. Dobiveni podatci analizirani su programom SPSS Statistics 22.0. Osjetljivost transvaginalnog ultrazvuka u određivanju dubine zahvaćenosti miometrija bila je 88,64%, specifičnost 90,48%, pozitivna prediktivna vrijednost 95,12% i negativna prediktivna vrijednost 79,17%. Za magnetsku rezonanciju osjetljivost je bila 63,64%, specifičnost 95,24%, pozitivna prediktivna vrijednost 96,55% i negativna prediktivna vrijednost 55,56%. Uz metodu smrznutih rezova, koja je zlatni standard u određivanju dubine invazije miometrija, posljednjih godina se transvaginalni ultrazvuk i magnetska rezonancija često primjenjuju za ovu namjenu. Ultrazvučna pretraga koju provodi iskusni specijalist bolja je od magnetske rezonancije, jer je brza, osjetljivija i nije skupa.

Ključne riječi: *Karcinom endometrija; Invazija miometrija; Transvaginalni ultrazvuk; Magnetska rezonancija; Smrznuti rezovi*