

## Pyogenic Granuloma of the Proximal Part of a Nail Unit in a Child

Dear Editor,

We present a case of proximal pyogenic granuloma in 4-year-old child. The patient presented to our Department due to a fast-growing lesion on the proximal part of the nail unit. The lesion had appeared over several weeks, and it was extremely painful for the child. On the day of the 1<sup>st</sup> visit, the lesion was not bleeding but was very painful during examination and photo-documentation. Clinically, it presented as an exogenous tumoral lesion of the proximal 1/3 of the nail, partially exulcerated with one part exhibiting coagulated hemorrhage and with uneven coloration (Figure 1). The lesion was not sharply demarcated. Dermoscopically, the majority of the lesion presented an unspecific dermoscopic structure, orange background color, and matched the criteria for a vascular lesion: few unspecific vessels and hemorrhage. The "sticky fiber" sign was also present (Figure 2). Since the lesion was fast-growing and due to the unspecific dermoscopic appearance, the child was referred to a pediatric surgeon and a complete excisional biopsy of the lesion was performed. The dermoscopy of pyogenic granuloma has been already described (1). The histology report confirmed pyogenic granuloma.

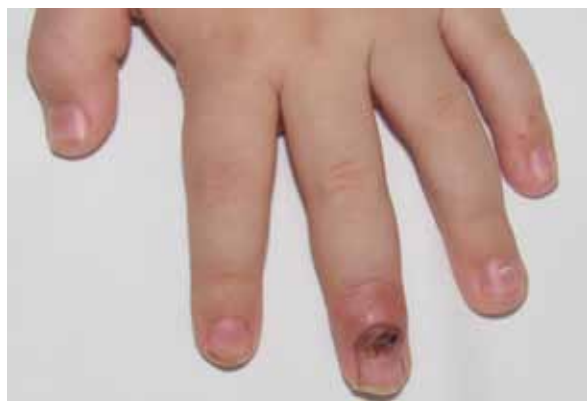


Figure 1.

Pyogenic granulomas of the nail unit are not a common finding, but our case confirms that even this location can be site of this type of benign lesion. It more commonly found in the periungual region and can be expected due to adverse effects of different kinds of systemic therapies. However, due to differential diagnosis that includes different types of tumors occurring at the nail unit, most importantly amelanotic melanoma and SCC, it is suggested to excise or take a biopsy of this type of lesion to be able to exclude aggressive tumor types, which are very rare but not impossible the in pediatric population (2). In cases of

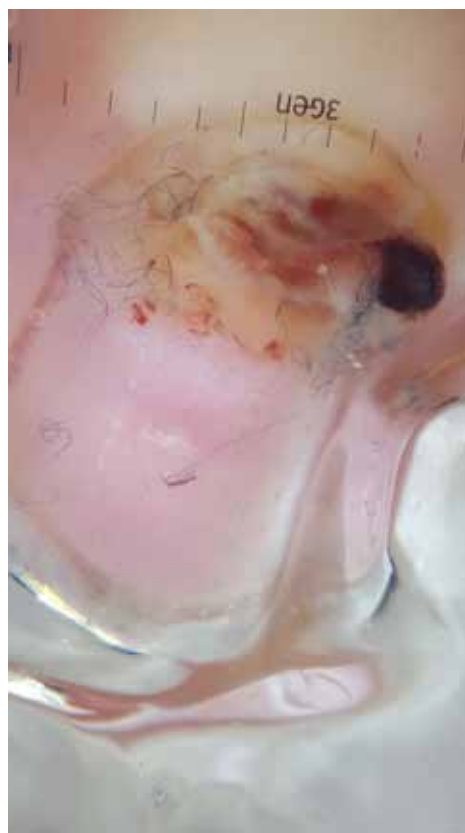

Figure 2.

unquestionable diagnosis, several local treatments are available. Since the lesion presented a destructive nature in our case, we decided to perform excisional biopsy followed by histology, which in our case was both a diagnostic and therapeutic procedure.

#### References:

1. Zaballos P, Llambrich A, Cuellar F, Puig S, Malveyh J. Dermoscopic findings in pyogenic granuloma. *Br J Dermatol.* 2006;154:1108-11.
2. McCormack L, Hawryluk EB. Pediatric melanoma update. *G Ital Dermatol Venereol.* 2018;153:707-15.

**Ružica Jurakić Tončić, Anamaria Balić,  
Danijela Ćurković, Karmela Husar**

*University of Zagreb School of Medicine,  
Department of Dermatology and Venereology,  
University Hospital Centre Zagreb, Zagreb, Croatia*

#### Corresponding author:

Ružica Jurakić Tončić, MD, PhD  
University of Zagreb School of Medicine  
Department of Dermatology and Venereology  
University Hospital Centre Zagreb  
Kišpatićeva 12, 10000 Zagreb, Croatia  
*rjtoncic@gmail.com*

Received: January 31, 2019

Accepted: March 15, 2021

