

## The Pancreatitis, Panniculitis, and Polyarthritits (PPP) Syndrome: Subcutaneous Nodular Fat Necrosis, a Cutaneous Marker of Pancreatic Neoplasia

Małgorzata Bernacka <sup>1</sup>, Konrad Kosztowny <sup>2</sup>, Robert A. Schwartz <sup>3</sup>,  
Piotr Hogendorf <sup>2</sup>, Jarosław Bogaczewicz <sup>1</sup>, Anna Woźniacka <sup>1</sup>

<sup>1</sup>Department of Dermatology and Venereology, Medical University of Lodz, Lodz, Poland; <sup>2</sup>Department of Transplant and General Surgery, Medical University of Lodz, Lodz, Poland; <sup>3</sup>Dermatology and Pathology, Rutgers New Jersey Medical School, Newark, New Jersey

### Corresponding author:

Małgorzata Bernacka, MD  
Department of Dermatology and Venereology  
Medical University of Lodz,  
Plac J. Hallera 1/6  
90-647 Lodz  
Poland  
[malgosia.bernacka@interia.pl](mailto:malgosia.bernacka@interia.pl)

Received: September 14, 2020

Accepted: March 15, 2021

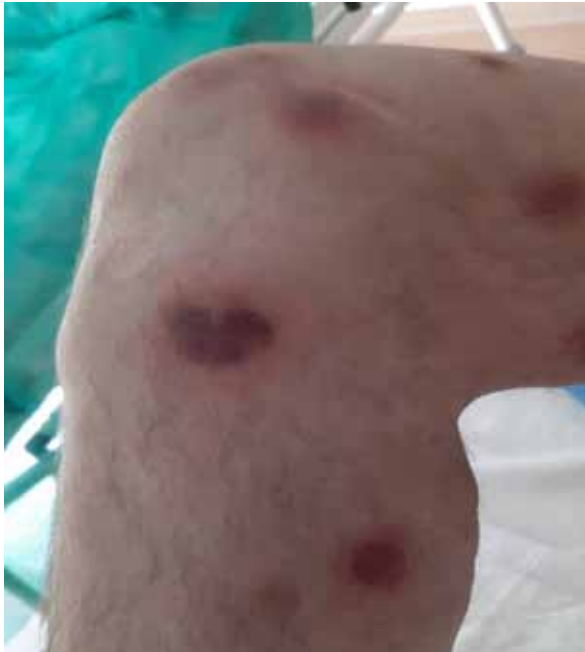**ABSTRACT** The pancreatitis, panniculitis, polyarthritits (PPP) syndrome is a rare skin, joint, and pancreatic disorder, also known as subcutaneous nodular fat necrosis. It results from obstruction of pancreatic ducts with direct secretion of pancreatic enzymes into the bloodstream, causing extra pancreatic fat necrosis with subcutaneous tissue and joint inflammation. It is usually a cutaneous sign of pancreatic cancer or pancreatitis. To our knowledge, this is the first case associated with a pancreatic pseudotumor. We describe a 59-year-old man initially presenting with numerous painful erythematous subcutaneous nodules due to a fibrous pancreatic pseudotumor and its extreme dermatologic disease, resulting in necrosis of the shin and foot so severe that an amputation of the lower leg above the knee was required, a complication not previously described, to our knowledge. We emphasize that PPP syndrome is a cutaneous marker of internal malignancy, most often of pancreatic cancer or pancreatitis, but in this case of a rare pancreatic pseudotumor.

### INTRODUCTION

The pancreatitis, panniculitis, polyarthritits (PPP) syndrome, also known as nodular fat necrosis, is a rare skin, joint, and pancreatic disorder (1,2). It is cutaneous marker of internal malignancy, but may instead be due to pancreatitis. Typically, the cancer is a deadly acinar cell carcinoma, but may be rarely an islet cell tumor (2). PPP syndrome results from direct secretion of pancreatic enzymes into the bloodstream, causing extra pancreatic fat necrosis with subcutaneous tissue and joint inflammation. To our knowledge, we describe the first case due to a pancreatic pseudotumor, a rare entity that must be differentiated from pancreatic cancer (3,4).

### CASE REPORT

A 59-year-old man was admitted for numerous painful erythematous subcutaneous nodules localized mainly on the back, abdomen, and upper and lower limbs (Figure 1, Figure 2, Figure 3). These nodules, 2-3 cm in diameter, had initially appeared ten days earlier. They were tender on palpation, with some oozing brownish oily fluid. The patient complained of pain in the ankle joints, impaired mobility, and significantly swollen feet (Figure 4). A week earlier, he had been prescribed a combination of prednisone 15 mg daily, bilastine, a second generation antihistaminic, twice daily, and nimesulid, a non-steroid anti-inflammatory drug (NSAID), none of which proved beneficial.

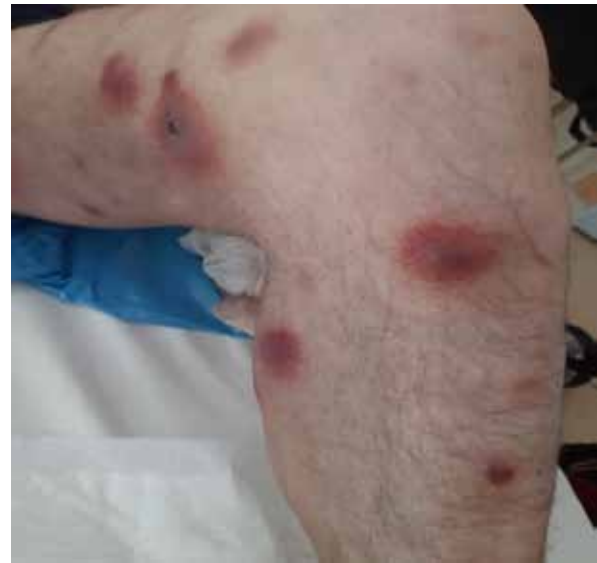

**Figure 1.** Red nodules in the subcutaneous tissue on the lower extremities.

A month earlier, the patient had taken ranitidine *ad hoc* to treat chronic gastritis. He denied respiratory and gastrointestinal infections as well as symptoms from the digestive tracts such as abdominal pain, nausea, vomiting, weight loss, diarrhea, or constipation in the period preceding the occurrence of skin lesions. He denied alcohol abuse. He reported drinking little alcohol and only occasionally. Past medical history was significant for chronic gastritis, perforation of gastric ulcer, laparoscopic cholecystectomy, acute pancreatitis of unknown etiology (2012), surgical treatment of a hernia of the nucleus pulposus in the lumbar region (1995), and surgical treatment of the varices of the right lower limb.

Two skin biopsy specimens were taken from subcutaneous nodules. Pathological examination identified Balser necrosis-like (steatonecrosis) and ghost-like cells in adipose tissue with an organizing fibrosis and infiltration of small lymphocytes (Figure 5).

Laboratory tests showed elevated levels of inflammation markers (CRP 361.9 mg/L, WBC 27 800/  $\mu$ L, Neu 25 630/  $\mu$ L, Procalcitonin 0.73 ng/mL) and moderately elevated liver function tests: AST 63 U/L, ALT 53 U/L. They also revealed elevated pancreatic parameters: amylase 9673 U/L (normal range 28-100 U/L) and lipase >21 585 U/L (normal range 13-60 U/L). Contrast-enhanced CT of the abdominal cavity revealed a mass measuring 27×19 mm surrounded by calcifications, localized in the uncinata process of the pancreas. The pancreatic duct was narrowed. Labora-

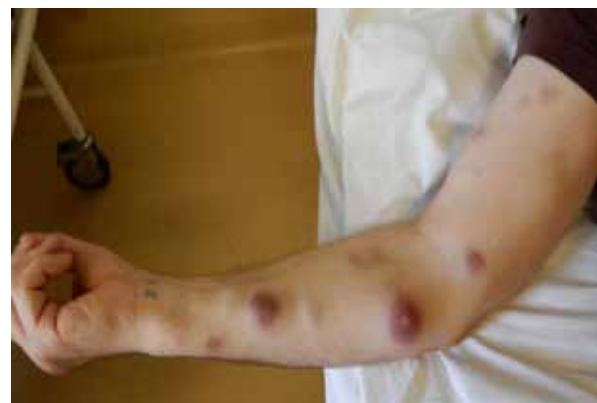

**Figure 2.** Red nodules in the subcutaneous tissue on the lower extremities

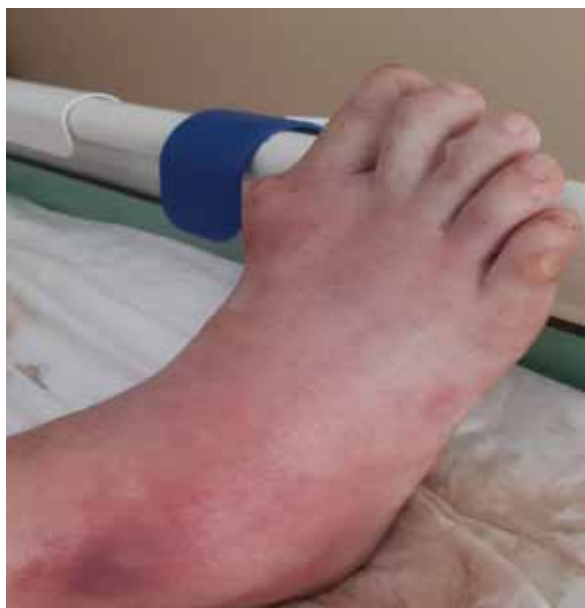tory tests strongly suggested acute pancreatitis; however, the patient did not have abdominal pain.

After a gastroenterological consultation, the patient was prescribed antibiotic ceftriaxon 1 g intravenously twice daily and oral metronidazole 500 mg three times a day, together with steroids – methylprednisolone 32 mg daily, ichthyol wraps, boric acid wraps and clobetasol propionate cream with recommended elevation of the lower limbs. However, this conservative treatment did not improve the patient's condition. Inflammation markers (CRP, WBC, Neu) and pancreatic parameters (amylase, lipase) remained elevated throughout hospitalization, and the patient remained febrile.

A suspicion of pancreatic tumor and PPP syndrome (pancreatic disease, panniculitis, polyarthritis) arose. The patient was treated with somatostatin



**Figure 3.** Red nodules in the subcutaneous tissue on the upper extremities

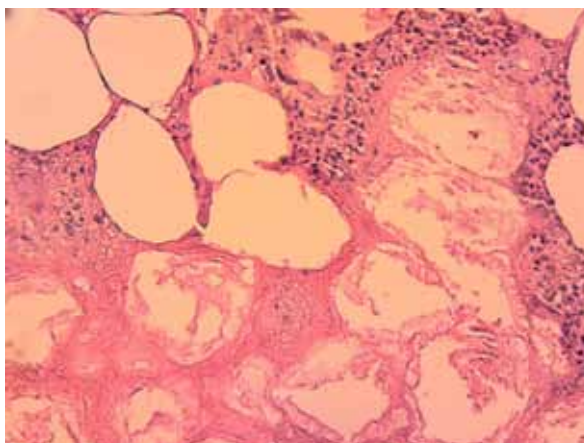


**Figure 4.** Painful, swollen ankle joint – tender on palpation

infusion 4.2 mL/h IV (6 mg daily), then 3.1 mL/h IV (3mg daily). The patient was administered a narcotic painkiller in response to strong joint ache. The new treatment regimen resulted in a significant reduction of pancreatic (amylase 100 U/L, lipase 64 U/L) and inflammatory parameters (CRP 95.5 mg/L, WBC 14 500 /  $\mu$ L, Neu 12 290 /  $\mu$ L). An endoscopic ultrasound study (EUS) of the pancreas revealed a hypoechogenic mass 30x25 mm in size with calcification localized in the head of the pancreas. The parenchyma of the pancreas showed fibrosis. The pancreatic duct measured 3-4 mm in diameter at the head of the pancreas. The biopsy also revealed normal pancreatic benign epithelio-glandular cells.

A blood culture was also taken following a recurring fever. Although the result was negative twice, antibiotics ceftriaxon and metronidazol were replaced by meropenem 1 g IV three times daily.

The patient was admitted to the Department of General and Transplant Surgery to remove a pancreatic tumor and to treat bilateral bed sores of the coccal and heel regions and inflammatory nodules of the left shin. Systemic antibiotics were administered, and silver-based dressings were applied. The patient did not report any abdominal symptoms during hospitalization. The blood tests were significant for anemia, with a hemoglobin level of 7.8 g/dL, CRP elevated to 261 mg/dL and mild leukocytosis (11.1 G/L). CEA, Ca-125, and Ca 19-9 tumor markers were not elevated; serum amylase was present at 84 U/L. Due to diffuse necrosis of the shin and foot, an amputation was performed above the knee. After several days of recovery, the patient underwent surgery with



**Figure 5.** Balsec necrosis in adipose tissue with organizing fibrosis and infiltration of small lymphocytes.

the intention of performing pancreaticoduodenectomy. Intraoperatively, the surgeons identified and dissected adhesions between the omentum and the abdominal wall. A fibrous tumor of the pancreatic head approximately 5 cm in diameter was also identified. However, it was unresectable due to infiltration of the mesentery. The gastroduodenal artery was ligated to decrease blood flow to the pancreatic head, and a choledochal stent (Fr 9) was placed into the common bile duct.

The postoperative period was uneventful. Pathological examination of the tumor biopsy taken during the operation revealed diffuse fibrosis of the pancreas. Somatostatin, later replaced by ocreotide, improved the management of the skin lesions to a degree. On day 25 of hospitalization, the patient was discharged with inflammatory skin nodules of the lower extremity requiring further attention in the Surgical Outpatient Clinic.

The patient was readmitted to the ward four weeks later due to exacerbation of the panniculitis in the remaining lower extremity. No significant elevation of serum lipase (65 U/l) or amylase (77 U/l) were observed. Intravenous antibiotics (amoxicillin + clavulanic acid) and daily wound care were applied.

A few months later, the skin nodules and joint pain completely disappeared.

## DISCUSSION

Clinically characterized by tender subcutaneous nodules and systemic signs including weight loss and fatigue, the pancreatitis, polyarthritis, panniculitis syndrome (PPP syndrome) is a rare disorder also known as nodular fat necrosis that is recognized as a cutaneous sign of internal malignancy (1,2). The main feature of this syndrome is fat necrosis, which is probably caused by lipase, amylase, and trypsin release

from damaged pancreatic tissue. Such hypersecretion may be due to their overproduction by cancerous exocrine cells or by an obstruction due to pancreatitis (1). Trypsin release increases the permeability of blood vessels, allowing lipase to penetrate into the subcutaneous tissue and hydrolyze fatty acids. High concentrations of lipase induce tissues lipolysis, resulting in fat necrosis and inflammation in the peripheral tissues and bone marrow (5). Both immunological disorders and vascular damage are believed to play additional roles in this process (6).

The majority of patients with PPP are men, with a mean age of  $51 \pm 16$  years, with 52.1% having pancreatitis and 43.8% pancreatic neoplasia (5). They often demonstrate alcohol abuse if due to pancreatitis (7). In our presented case, alcohol abuse and trauma were excluded. In addition, 52.1% of PPP cases have pancreatitis and 43.8% have neoplastic conditions (5). These patients rarely complain about abdominal disorders (7). Although a few cases are caused by trauma of the pancreas (5), including in children (8), the most common cause of PPP syndrome is carcinoma, especially acinar cell carcinoma (5,9). Examples of PPP syndrome have also been described in patients with pseudopapillary pancreatic tumor (10), neuroendocrine carcinoma of the pancreas (2,6) or pancreatic-type acinar cell carcinoma of the liver (11). It may occur as a result of fistula formation between the inferior vena cava and a pancreatic pseudocyst (12) or between the superior mesenteric vein and a post-pancreatic pseudocyst (13). In both cases, vein thrombosis was revealed by preoperative imaging, which suggested the presence of a small fistula and requires exploratory surgery (12,13). In our presented case, the tumor biopsy revealed diffused fibrosis of the pancreas. There was no evidence of malignancy or islet cell tumor in this pancreatic pseudotumor.

PPP syndrome manifests on the skin as tender (1), or painless erythematous subcutaneous nodules, which often ooze yellowish brown fluid (14). They demonstrate a tendency towards ulceration (15), as in our patient. Ulceration is more common in patients with pancreatic carcinoma (15). Nodules usually occur earlier than other symptoms (14). They are most frequently located on the lower extremities, followed by the trunk or buttocks (9). A punch skin biopsy specimen typically shows foci of fat necrosis characterized by ghost-like cells with thick shadowy walls and no nuclei, dystrophic calcification, and a mixed inflammatory zone (16). In our case, we observed Balser necrosis-like cells in adipose tissue and ghost-like cells with organizing fibrosis and infiltration of small lymphocytes.

In the joints, PPP mainly affects the ankles, knees and wrists, typically presenting as a symmetric or asymmetric polyarthritis and in some cases as oligoarthritis or monoarthritis (9). Patients complain of joint pain and swelling unresponsive to non-steroidal anti-inflammatory drugs, steroids, or immunosuppressant medication. Our patient also complained of severe joint pain, impaired mobility, and swollen feet, which did not respond to painkillers.

The most frequent complications are osteonecrosis, intraosseous fat necrosis (17,18), synovitis with thickening of the synovium, bone destruction, periostitis of the tubular bones of the extremities (18), osteomyelitis (19), or calcification of the medullary cavities. In our patient we also observed diffuse necrosis of the shin and foot, which led to amputation above the knee, an unfortunate outcome and not previously described, to our knowledge. The best way to recognize necrosis in bone marrow is by MRI imaging (18,20). Yellowish fluid is often found during synovial aspiration (17).

Laboratory findings in patients with PPP syndrome include high levels of lipase, amylase, or trypsin (7). Eosinophilia is also sometimes observed as a part of the triad of subcutaneous fat necrosis, polyarthritis, and eosinophilia, and is associated with pancreatic tumor and poor prognosis (21).

Treatment of PPP syndrome includes management of the underlying condition, whether using a conservative approach or a surgical one such as pancreatoduodenectomy (22), total pancreatectomy (18), resection of the fistula between the pancreas pseudocyst and vein (12,13), lithotripsy during endoscopic cholangiopancreatography, or endoscopic stent placement in chronic pancreatitis. Alternatively, a combination of chemotherapy with radiotherapy can be considered in case of advanced cancer (5). In some cases, intravenous octreotide has been used to reduce the high levels of lipase and amylase (11,23), as has plasmapheresis (24). The treatment in our patient included somatostatin followed by octreotide intravenously to diminish the level of pancreatic enzymes. Due to infiltration of the mesentery, the tumor was unresectable. In order to decrease blood flow to the pancreatic head and to reduce the tumor mass, the gastroduodenal artery was ligated and a choledochal stent was placed into the common bile duct.

## CONCLUSION

The prognosis in PPP syndrome is poor if there is an acinar cell carcinoma of pancreas. Fortunately, there was no underlying malignancy, so the prognosis in our patient was favorable.



## References:

1. Virshup AM, Sliwinski AJ. Polyarthritis and subcutaneous nodules associated with carcinoma of the pancreas. *Arthritis Rheum.* 1973;16:388-92.
2. Schwartz RA, Fleishman JS: Association of insulinoma with subcutaneous nodular fat necrosis. *J Surg Oncol.* 1981;16:305-11.
3. Clark A, Zeman RK, Choyke PL, White EM, Burrell MI, Grant EG, *et al.* Pancreatic pseudotumors associated with multifocal idiopathic fibrosclerosis. *Gastrointest Radiol.* 1988;13:30-2.
4. Baião JM, Martins RM, Correia JG, Jordão D, Vieira Carço T, Caetano Oliveira R, *et al.* Inflammatory Pseudotumor of the Pancreas Mimicking a Pancreatic Neoplasm. *Case Rep Gastroenterol.* 2019 Jun 13;13:245-52.
5. Zundler S, Strobel D, Manger B, *et al.* Pancreatic Panniculitis and Polyarthritis. *Curr Rheumatol Rep.* 2017 Aug 26;19:62.
6. Preiss JC, Faiss S, Lodenkemper C, *et al.* Pancreatic panniculitis in an 88-year-old man with neuroendocrine carcinoma. *Digestion.* 2002;66:193-6.
7. Narváez J, Bianchi MM, Santo P, *et al.* Pancreatitis, panniculitis, and polyarthritis. *Semin Arthritis Rheum.* 2010;39:417-23.
8. Loverdos I, Swan MC, Shekherdimian S, *et al.* A case of pancreatitis, panniculitis and polyarthritis syndrome: Elucidating the pathophysiologic mechanisms of a rare condition. *J Pediatr Surg Case Rep.* 2015 May;3:223-6.
9. Kim EJ, Park MS, Son HG, *et al.* Pancreatitis, Panniculitis, and Polyarthritis Syndrome Simulating Cellulitis and Gouty Arthritis. *Korean J Gastroenterol.* 2019 Sep 25;74:175-182.
10. Vasdev V, Bhakuni D, Narayanan K, *et al.* Intra-medullary fat necrosis, polyarthritis and panniculitis with pancreatic tumor: a case report. *Int J Rheum Dis.* 2010 Oct;13:e74-8.
11. Zundler S, Erber R, Agaimy A, *et al.* Pancreatic panniculitis in a patient with pancreatic-type acinar cell carcinoma of the liver-case report and review of literature. *BMC Cancer.* 2016 Feb 20;16:130.
12. Jo S, Song S. Pancreatitis, panniculitis, and polyarthritis syndrome caused by pancreatic pseudocyst: A case report. *World J Clin Cases.* 2019 Sep 26;7:2808-14.
13. Dieker W, Derer J, Henzler T, *et al.* Pancreatitis, panniculitis and polyarthritis (PPP-) syndrome caused by post-pancreatitis pseudocyst with mesenteric fistula. Diagnosis and successful surgical treatment. Case report and review of literature. *Int J Surg Case Rep.* 2017;31:170-5.
14. Durden FM, Variyam E, Chren MM. Fat necrosis with features of erythema nodosum in a patient with metastatic pancreatic carcinoma. *Int J Dermatol.* 1996 Jan;35:39-41.
15. Fernández-Sartorio C, Combalia A, Ferrando J, *et al.* Pancreatic panniculitis: A case series from a tertiary university hospital in Spain. *Australas J Dermatol.* 2018 Nov;59:e269-e272.
16. Szymański FJ, Bluefarb SM. Nodular fat necrosis and pancreatic diseases. *Arch Dermatol.* 1961 Feb;83:224-9.
17. Kang DJ, Lee SJ, Choo HJ, *et al.* Pancreatitis, panniculitis, and polyarthritis (PPP) syndrome: MRI features of intraosseous fat necrosis involving the feet and knees. *Skeletal Radiol.* 2017 Feb;46:279-85.
18. Ferri V, Ielpo B, Duran H, *et al.* Pancreatic disease, panniculitis, polyarthritis syndrome successfully treated with total pancreatectomy: Case report and literature review. *Int J Surg Case Rep.* 2016;28:223-6.
19. Langenhan R, Reimers N, Probst A. Osteomyelitis: A rare complication of pancreatitis and PPP-syndrome. *Joint Bone Spine.* 2016 ;83:221-4.
20. Agarwal S, Sasi A, Ray A, *et al.* Pancreatitis panniculitis, polyarthritis syndrome with multiple bone infarcts. *QJM.* 2019;112:43-4.
21. Beltraminelli HS, Buechner SA, Häusermann P. Pancreatic panniculitis in a patient with an acinar cell cystadenocarcinoma of the pancreas. *Dermatology.* 2004;208:265-7.
22. Sondhi AR, Wamsteker EJ, Piper MS. "Doc, I Can't Walk"-A Classic Presentation of a Rare Disease. *Gastroenterology.* 2018;155:1703-5.
23. Hudson-Peacock MJ, Regnard CF, Farr. PM Liquefying panniculitis associated with acinous carcinoma of the pancreas responding to octreotide. *J R Soc Med.* 1994;87:361-2.
24. Francombe J, Kingsnorth AN, Tunn E. Panniculitis, arthritis and pancreatitis. *Br J Rheumatol.* 1995;34:680-3.