

## Colonic diverticulum in a dog - a case report

Marija Lipar<sup>1\*</sup>, Sonja Vukelić<sup>2</sup>, Andrija Musulin<sup>1</sup>, Branimir Škrilin<sup>3</sup>, Andrea Martinović<sup>2</sup>,  
Matko Buljan<sup>4</sup>, and Dražen Vnuk<sup>1</sup>

<sup>1</sup>*Clinic for Surgery, Orthopaedics and Ophthalmology, Faculty of Veterinary Medicine, University of Zagreb, Zagreb, Croatia*

<sup>2</sup>*Student, Faculty of Veterinary Medicine, University of Zagreb, Zagreb, Croatia*

<sup>3</sup>*Department of Radiology, Ultrasound and Physical Therapy, Faculty of Veterinary Medicine, University of Zagreb, Zagreb, Croatia*

<sup>4</sup>*Clinical Hospital Dubrava, Zagreb, Croatia*

---

**LIPAR, M., S. VUKELIĆ, A. MUSULIN, B. ŠKRLIN, A. MARTINOVIĆ, D. VNUK: Colonic diverticulum in a dog - a case report. Vet. arhiv 91, 673-679, 2021.**

### ABSTRACT

The objectives of the current case report are to describe and report the diagnostics and surgical treatment of colonic diverticulum in a dog. A 13-year-old intact male Labrador retriever, suffering from the inability to defecate for 10 days, was diagnosed with a mass between the colon and the urinary bladder, filled with faeces. The diagnosis of a colonic diverticulum was obtained using plain abdominal radiography, ultrasonography, cystography and irigography. Native and contrast abdominal radiography and ultrasonography detected an abdominal mass with a diameter of 9 cm, filled with faeces, connected to the descending colon, and an enlarged prostatic gland. The dog was treated surgically with orchiectomy, exploratory celiotomy, partial resection of the colonic diverticulum wall, followed by reconstruction of the colon using the wall of the colonic diverticulum as a flap. The dog defecated 24 hours after surgery. On the 5<sup>th</sup> postoperative day, a wound infection was observed (redness, serous discharge from the ventral midline wound). The functional outcome was satisfactory. To the best of our knowledge, such a case report has not been reported before.

**Key words:** canine; colonic diverticulum; exploratory celiotomy

---

### Introduction

The definition of diverticula in the gastrointestinal tract varies and depends on their location. Oesophageal diverticula can be single or multiple, congenital or acquired, and can be further classified as pulsion or traction types. Pulsion diverticula are mucosal herniations through the muscular layer of the oesophagus, and they are the consequence of either an oesophageal foreign body or a vascular ring anomaly. Traction diverticula consist of all the oesophageal layers and develop

as a consequence of adhesion formation between the oesophagus and adjacent tissues (RUNGE and CULP, 2013; KYLES and HUCK, 2017).

Rectal diverticula are always related to perineal hernia. Distinguishing the rectal sacculation from diverticula depends on the number of rectal layers. Rectal sacculation consists of all rectal layers, while rectal diverticula are produced by an outpouching of the rectal mucosa through a defect in the rectal muscular layer (MANN, 1993).

---

\*Corresponding author:

Marija Lipar, DVM, PhD, Faculty of Veterinary Medicine, Heinzelova 55, 10000 Zagreb, Croatia, E-mail: mlipar@vef.hr

Colonic diverticula are well known in human medicine; however, they only develop clinical signs once infected. Diverticula are predominantly formed as a mucosal protrusion through a weak spot in the bowel wall (PARDI, 2006). A giant colonic diverticulum is considered larger than 4 cm in diameter, and may be classified as a true diverticulum, consisting of all four intestinal layers, whereas pseudodiverticulae consist of a reduced number of intestinal layers (ALTAF et al., 2005; BEDDY et al., 2010).

This article reports a case of an abdominal mass in a dog diagnosed with a colonic diverticulum using abdominal native radiography, cystography and irigography. This diagnosis was confirmed during exploratory celiotomy, and diverticulum resection with reconstruction was performed using the diverticulum tissue as a flap.

### Case presentation

A 13-year old intact male Labrador retriever weighing 36 kg was admitted (the first day) to a private veterinary clinic, with a history of only one defecation in the previous 10 days, and inappetence for three days. Blood work was performed (complete blood count (CBC) and bilirubin, glucose, creatinine, alkaline phosphatase (ALP), alanine aminotransferase (ALT)). Blood results were unremarkable. Amoxicillin/clavulanic acid, ranitidine and metamizole were administered. The following day (the second day), the dog was again brought in to the same private practitioner and the blood work was repeated (CBC and bilirubin). The blood results were again unremarkable. Amoxicillin-clavulanic acid, enrofloxacin, carprofen and ranitidine were administered. Unfortunately, the therapy failed to give results.

On the third day, the dog was admitted to the University clinic with a history of inappetence, lack of defecation, tenesmus and depression. Body temperature was 39.5 °C, heart rate 166/min and respiratory rate 36/min. Clinical examination revealed abdominal distension and a palpable abdominal mass. Digitorectal palpation detected an empty rectum. Bloodwork was performed, and ALT, blood urea nitrogen, creatinine, gamma glutamate transferase, sodium and potassium were within

the normal ranges. Doehl bodies were found in a blood smear examination. The electrocardiography finding was unremarkable. The changed parameters are shown in Table 1.

Therapy was started with crystalloid fluid, ampicillin 22 mg/kg (Ampicillin Sandoz 1 g/ bottle, Sandoz GmbH, Austria), ranitidine 2 mg/kg (Arnetin®, Medochemie, Cyprus), methadone 0.2 mg/kg (Comfortan® 10 mg/mL, Dechra, UK), diazepam 0.2 mg/kg (Apaurin®, Krka, Slovenia) IV. The intensive care started. Native abdominal radiography, cystography, irigography and ultrasonography were performed.

Surgery was performed under general anaesthesia. Venous cannulation was performed with a 20G catheter in the left cephalic vein. Premedication was administered IV in doses of 0.2 mg/kg of methadone and 0.2 mg/kg of midazolam (Midazolam 15 mg/3 mL, Braun, Germany). Induction to general anaesthesia was performed IV with 4 mg/kg 1% propofol (Propofol-Lipuro 10 mg/mL, Braun, Germany). The animal was intubated with a 12 mm i.d. endotracheal tube, and connected to inhalation anaesthetic sevoflurane (Sevoflurane, Baxter, UK) at a concentration of 1.6 to 1.8% in 75% oxygen and 25% air. Sufentanil (Sufentanil 50 µg/10 mL, Laboratoire Renaudin, France) was used IV at a continuous infusion rate (1-3 µg/kg/h) depending on pain during the procedure. With increased pain stimulus, a bolus of sufentanil 0.25 mg/kg IV was administered five times every 20 minutes, also a 1 mg/kg IV bolus of ketamine (Ketomidol® 10%, Richterpharma ag, Austria) and a 1 mg/kg IV bolus of lidocaine (Lidocaine 2%, Braun, Germany). Fluid therapy during the surgical procedure was maintained at a constant infusion rate at doses of 10 mL/kg/h of 0.9% NaCl (NaCl 0.9% 1000 mL, Braun, Germany) as a continuous infusion. Prior to surgery, the dog received 12 mg/kg metronidazol (Metronidazol "Kabi" 0.5%, Poland) and ampicillin 22 mg/kg IV every 90 minutes. During the surgical procedure, arterial blood pressure was within physiological range, with a mean arterial pressure around 100 mm Hg measured by indirect oscillometric method. The mechanical supported ventilation was set at a respiratory rate of 10/minute, with CO<sub>2</sub> concentration ranging from 38 to 43 mm Hg.

Table 1. Blood test results performed at the university clinic preoperatively and the second day postoperatively (table presents only remarkable parameters)

Parameter	Preoperative	2 <sup>nd</sup> day postoperative	Range
RBC $\times 10^{12}/L$	5.8	4.4	5.87-7.59
Hematocrit (%)	40	30	41.1-55.0
WBC $\times 10^9/L$	20.2	28.1	6.87-13.99
Band neutrophils (%)	30	5	0
ALP (U/L)	204	230	20-120
CRP (mg/L)	241.1	135	<5
Lactate (mmol/L)	6.29	1.33	3-15
TP (g/L)	60	51	54-78
Albumin (g/L)	25	17	22-34

The skin of the ventral abdomen was aseptically prepared for surgery. Orchiectomy was performed by the closed method. The midline prescrotal skin was incised, intact spermatic cord and vaginal tunics were doubly ligated by transfixation and circumferential ligation using glycomer 631 USP 2-0 (Biosyn, Covidien, UK). The subcutaneous tissue and the skin were closed standardly.

Exploratory laparotomy was performed. The skin incision was parapreputial and the abdominal wall was opened in the ventral midline. Surgical gross exploration of the abdomen revealed the absence of free fluid. The urinary bladder was moderately filled with urine. The prostatic gland was enlarged with numerous cysts. Puncture of one cyst was performed. Creatinine in the prostatic cyst fluid was 65  $\mu\text{mol}/L$  (71  $\mu\text{mol}/L$  in serum). Incisional biopsy of prostatic gland tissue was performed at the ventral part, and the biopsy site was sutured with glycomer 631 USP 3-0 (Biosyn, Covidien, UK) using a simple continuous suture pattern. One mass, 10 cm in diameter, was found between the trigonum of the urinary bladder and the colon. An uncompressible mass was fixed to the colon and the urinary bladder. At the moment of blunt dissection of the mass, the wall opened and faeces were observed. After complete dissection of the mass from the urinary bladder, the mass was opened ventrally in a length of 5 cm. Dry, hard faeces was found. Communication was detected between the mass and the colon. Transanally, a gastric tube (diameter 15 mm) was administered to detect the

colon direction, cranially to the lesion. The mass was in contact laterally with a prostatic cyst. In the dorsolateral part of the cyst, 10 mL of white-yellow discharge was detected in the direction from the prostatic cyst. The mass wall was resected, cranially to caudally. It was estimated that in the case of complete resection of the mass wall, stricture could be formed. Therefore, a flap was created from the caudal wall of the mass. This flap was used as the material for reconstruction of the ventral colonic wall defect. The colonic wall was reconstructed with polyglyconate USP 3-0 (Maxon<sup>TM</sup>, Covidien, UK) in one layer using single interrupted sutures. Specimens of diverticulum wall and prostatic gland were submitted to histopathology. The abdominal cavity was flushed and the abdominal wall closed using PDS 1 (PDS<sup>®</sup>, Ethicon, Johnson and Johnson, USA) in a simple continuous fashion. The subcutis and cutis were reconstructed standardly.

Postsurgical analgesia was maintained for the first 24 hours with 0.15 mg/kg methadone every 5 hours IV and a fentanyl patch for the first 6 days (Durogesic<sup>®</sup> transdermal patch, Janssen-Cilag Limited, UK) 100  $\mu\text{g}/\text{h}$ . Following surgery, fluid therapy was continued for two days.

Antimicrobial drugs were administered intravenously for the next five days. Twenty-four hours following surgery, the dog started to take food and water. On the third postoperative day, formed stools without fresh blood were observed, but defecation was painful.

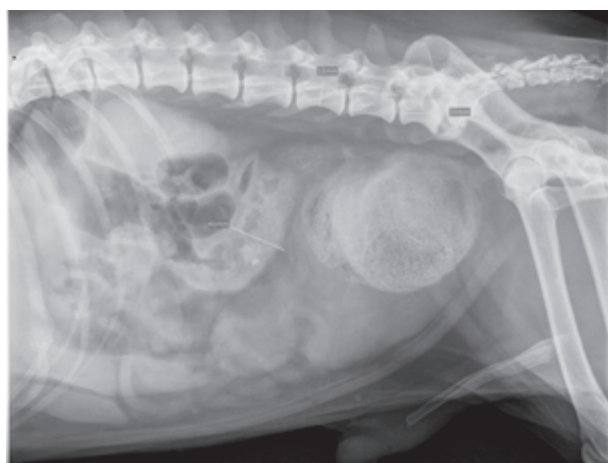


Fig. 1. Plain radiograph of dog with obvious intraabdominal mass

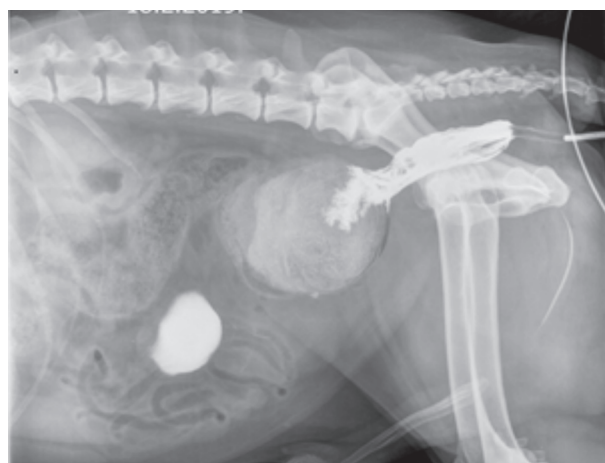

Fig. 2. Abdominal radiograph after irigography and cystography. Complete obstruction of the colon is obvious. The large prostatic gland displaces the urinary bladder cranially.

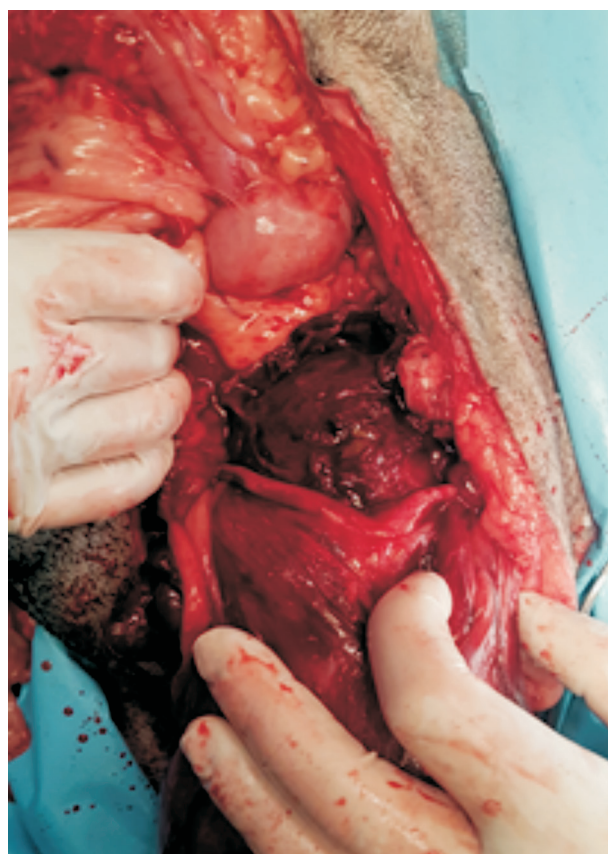


Fig. 3. Intraabdominal view during surgery. The colonic diverticulum is cranial to the vas deferens.

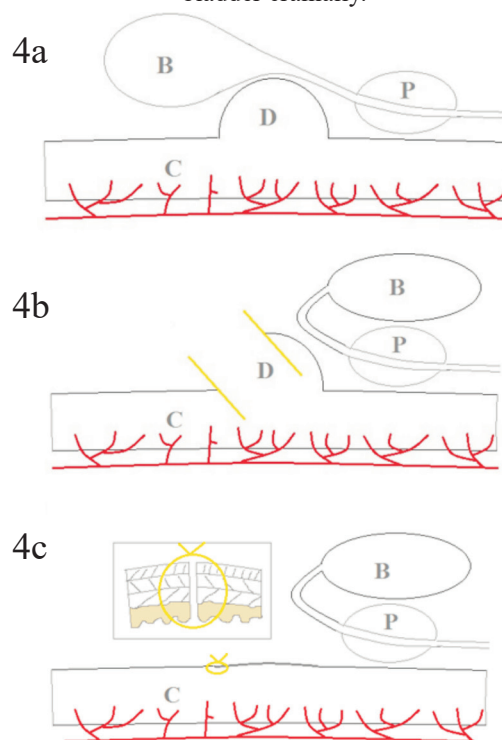


Fig. 4a. Scheme of the preoperative anatomy of the colonic diverticulum; Fig. 4b. The urinary bladder was retroflexed in order to approach the diverticula; the cranial part of the colonic diverticulum was cut off. Yellow lines indicate the line of colonic diverticulum incisions; Fig. 4c. A flap of the colonic diverticulum was used to reconstruct the colonic wall, single interrupted perforative sutures were used for closure. B - urinary bladder, C - colon, D - colonic diverticulum, P- prostatic gland (Source D. Vnuk).

A diffuse, painful, warm swelling in the ventral midline incision area and discharge from the cranial part of the skin incision were observed on the second postoperative day and lasted for 5 days.

Histopathological findings of the prostatic gland specimen revealed squared to low columnar epithelial cells forming papilla directed into the lumen. Beneath the epithelial cells, there was soft fibrovascular stroma. The cystic enlargement was filled with low protein liquid. No criteria for malignancy were observed. In the colon specimen, extensive focal ulcerations were detected; the mucous membranes were hyperplastic with fibromatous purulent inflammation. In the submucosa and muscular layer, neutrophils, lymphocytes and plasma cells were dominant in the inflammatory response. The colonic wall consisted of all four layers.

### Discussion

The etiology of intestinal diverticula is unknown. The human medicine literature has hypothesized that endodermal proliferation and recanalisation is disrupted during embryological development of the primitive gut. This may result in congenital abnormalities, including diverticula (VAN DER GAAG and TIBOEL, 1980). Another congenital condition, known as segmental dilation of the intestine, is also described in dogs. This congenital malformation was associated in human medicine with intrauterine intestinal injury (JOHNSON et al., 2019). The other possible etiologies include a true diverticulum caused by adhesion or extraluminal scarring relating to ulcerations (KNOEFEL and RATTNER, 2001).

There are also several theories concerning acquired diverticula formation, such as insufficient fibre intake (slower stool transit and lower stool weights), high pressure and an exaggerated motility index, muscular layer hypertrophy due to increased motor activity and prolonged use of non-steroidal anti-inflammatory drugs and opioid analgesics (HEISE, 2008).

In the current case report, the etiology of the colonic diverticulum is also unclear. One theory supports congenital etiology, whereas another

supports acquired etiology. The dog was 13 years old, without previous difficulties during defecation or other issues related to colonic diverticula. It is possible that the dog had congenital small diverticula without clinical significance, but the enlarged prostatic gland may have caused tenesmus during defecation and the impaction of the diverticulum with faeces and its enlargement. The theory of acquired colonic diverticula formation could be due to undiagnosed colonic disease or the cystic prostatic gland that was connected to the colonic wall. In this case, the cystic prostatic gland could produce traction of the colonic wall with adhesion. Disruption of the colonic wall was not observed during the histopathological exam.

Plain abdominal radiography and contrast enhanced CT were used to diagnose giant colonic diverticula in a human (ALTAF et al., 2005). Ultrasound was used to diagnose communicating tubular jejunal duplication in a dog. Plain abdominal radiography was not a sufficient diagnostic method (JUNG et al., 2009). In the current case, plain abdominal radiography was also not the only diagnostic method. Therefore, contrast irigography and cystography were also performed to detect the abdominal problem. Abdominal ultrasonography was the final diagnostic method to confirm the diagnosis. Exploratory celiotomy is often required to establish diagnosis and treatment, whereas definitive diagnosis is based on histopathology findings (ALTAF et al., 2005; PATOULIAS et al., 2018). In the presented case report, exploratory celiotomy confirmed the radiographic and ultrasonographic findings, and histopathological findings excluded malignancy and found four layers of diverticular wall in the specimen.

Prostatic hyperplasia was detected on x-ray, and due to the enlargement of the prostatic gland, castration was recommended. In the current case, the prostate cyst had no communication with the urinary bladder or urethra, proven by measuring creatinine in liquid originating from the cyst, which had only half the serum creatinine reference values. In dogs, 18% of prostatic cavity lesions contained urine, which was confirmation of urethral fistulation (BOKEMEYER et al., 2011).

Doehle bodies in mature neutrophils are situated in cytoplasm, representing retention and aggregation of the rough endoplasmic reticulum, which occurs under severe inflammation from bacterial infection (SMITH, 2000). In this case report, prior to surgical treatment, infection was proven by the elevated WBC and band neutrophils. Infection was caused by faecal impaction in the colonic diverticulum, which caused mucosal ischemia. Mucosal ischemia can be confirmed with elevated serum lactate concentrations (hyperlactacidemia). Hyperlactacidemia can be attributed to septic shock (elevated bound neutrophils) and huge abdominal conglomerates contained within the colonic diverticula, prostatic gland and urinary bladder, and subsequently causing ischemia and poor oxygen delivery (JAMES et al., 1999).

In the current case, colotomy was performed to remove fecaliths in the colonic diverticulum. Colonic resection and anastomosis were planned, but resection of 7-8 cm of the colonic wall could produce significant tension at the anastomosis site. Therefore, the tissue of the colonic diverticulum was used for reconstruction of the colonic wall as a full-thickness advancement flap. It was risky to use a colonic diverticulum flap, as the colonic diverticulum could consist of tumour cells. Macroscopically, the colonic wall was unchanged and histopathological findings did not detect any tumour cells in the colonic diverticulum tissue. The use of a full-thickness colonic flap has not previously been described in the literature. A seromuscular colonic flap was used for intrapelvic soft tissue coverage after extirpation of recurrent rectal cancer in human medicine (AHO et al., 2015).

The clinical relevance of this case report is the diagnostic approach in a dog suffering from an intraabdominal mass between the colon and urinary bladder. It is also the first case report to describe the use of a full thickness colonic flap for closure of the intestinal wall defect after resection of the diverticular tissue. Colonic diverticulum must be considered as a differential diagnosis in cases of observed masses near the colon.

## References

- AHO, J., S. WINOCOUR, Z. S. HAMMOUDEH, H. NELSON, P. ROSE, N. V. TRAN (2015): Seromuscular colonic flap for intrapelvic soft tissue coverage: A reconstructive option for plastic surgeons when traditionally used flaps are not available. *Case Rep. Surg.* Article ID 563641  
DOI: 10.1155/2015/563641
- ALTAF, N., S. GEARY, I. AHMED (2005): Giant colonic diverticulum. *J. R. Soc. Med.*, 98, 169-170.  
DOI: 10.1177/014107680509800411
- BEDDY, D., C. DEBLACAM, B. MEHIGAN (2010): An unusual cause of an acute abdomen - a giant colonic diverticulum. *J. Gastrointest. Surg.* 14, 2016-2017.  
DOI: 10.1007/s11605-010-1235-6
- BOKEMEYER, J., C. PEPPLERM, C. THIEL, K. FAILING, M. KRAMER, M. GERWING (2011): Prostatic cavity lesions containing urine in dogs. *J. Small Anim. Pract.* 52, 132-138.  
DOI: 10.1111/j.1748-5827.2011.01039.x
- HEISE, C. P. (2008): Epidemiology and pathogenesis of diverticular disease. *J. Gastrointest. Surg.* 12, 1309-1311.  
DOI: 10.1007/s11605-008-0492-0
- JAMES, J. H., F. A. LUCHETTE, F. D. MCCATRNER, J. E. FISCHER (1999): Lactate unreliable indicator of tissue hypoxia in injury or sepsis. *Lancet.* 354, 505-508.  
DOI: 10.1016/S0140-6736(98)91132-1
- JOHNSON, L., K. SIMONE, J. CULLEN, A. TALLEY, E. B. COHEN (2019): Radiographic features of congenital segmental dilation of the intestine in a german shepherd dog. *Vet. Radiol. Ultrasound* 60, E62-E65.  
DOI: 10.1111/vru.12581
- JUNG, J. H., J. H. CHANG, J. H. YOON, M. C. CHOI (2009): Imaging diagnosis - communicating tubular jejunal duplication in a dog. *Vet. Radiol. Ultrasound* 50, 83-85.  
DOI: 10.1111/j.1740-8261.2008.01495.x
- KNOEFEL, W. T., D. W. RATTNER (2001): Duodenal diverticula and duodenal tumours. In: *Oxford Textbook of Surgery.* (Morris, P. J., W. C. Wood, Eds.), 2<sup>nd</sup> ed. Oxford University Press, Oxford, pp. 943-949.
- KYLES, A. E., J. L. HUCK (2017): Esophagus, In: *Veterinary Surgery in Small Animal.* (Johnston, S. A., K. M. Tobias, Eds.), Elsevier, St.Louis. 1677-1700.
- MANN, F. A. (1993): Perineal herniation. In: *Disease Mechanism in Small Animal Surgery.* (Bojrab, J., Ed), second edition (Bojrab Lea&Febiger, Philadelphia, USA, pp. 92-97.
- PARDI, D. S. (2006): Mayo clinic: Gastroenterology and Hepatology Board Review, 2<sup>nd</sup> ed. (Hauser, S. C. Ed.), Mayo Clinic Scientific Press. USA, 131-140.  
DOI: 10.1201/b14426-23
- PATOULIAS, I., M. KALOGIROU, E. RACHMANI, K. CHATZOPOULOS, T. FEIDANTISIS, D. PATOULIAS

- (2018): Covered perforation of Meckel's diverticulum ulcer to transverse colon: Highlighting the urgent intervention and the avoidance of a dramatic evolution (case report and literature review). *Folia Med. Cracov* 3, 83-87.
- RUNGE, J. J., W. T. N. CULP (2013): Surgical treatment of esophageal disease. In: *Small Animal Soft Tissue Surgery*. (Monnet, E., Ed.), Wiley Blackwell, Ames, pp. 304-320.  
DOI: 10.1002/9781118997505.ch34
- SMITH, G. S. (2000): Neutrophils. In: *Schalm's Veterinary Hematology*. (Feldman, B. F., J. G. Zink, N. C., Jain, Eds.), Lippincott Williams Wilkins, Philadelphia, pp. 281-296.
- VAN DER GAAG, I., D. TIBBOEL (1980): Intestinal atresia and stenosis in animals: a report of 34 cases. *Vet. Pathol.* 25, 311-314.  
DOI: 10.1177/030098588001700505

Received: 28 February 2020

Accepted: 7 September 2021

---

**LIPAR, M., S. VUKELIĆ, A. MUSULIN, B. ŠKRLIN, A. MARTINOVIĆ, D. VNUK: Divertikul debelog crijeva u psa - prikaz slučaja. *Vet. arhiv* 91, 673-679, 2021.**

**SAŽETAK**

Cilj rada bio je prikazati dijagnostiku i kirurško liječenje divertikula debelog crijeva u psa. Mužjak u dobi od 13 godina pasmine labrador retriever, tijekom 10 dana nije mogao defecirati. Psu je dijagnosticirana tvorba između kolona i mokraćnog mjehura, ispunjena fecesom. Abdominalnom radiografijom, ultrazvukom, cistografijom i irigografijom postavljena je dijagnoza divertikula kolona. Nativna i kontrastna abdominalna radiografija i ultrazvuk otkrili su abdominalnu masu promjera 9 cm, ispunjenu fecesom i povezanu sa silaznim kolonom, kao i uvećanu prostatu. U psa je učinjena orhiektomija, eksploratorna celiotomija i parcijalna resekcija stijenke divertikula kolona, te rekonstrukcija debelog crijeva, upotrebom stijenke crijevnog divertikula kao preklopa. Nakon 24 sata pas je defecirao. Petog dana poslije kirurškog zahvata primijećena je infekcija rane (crvenilo, serozni iscjedak iz ventralnog srednjeg dijela rane). Funkcionalni ishod bio je zadovoljavajući. Prema nama dostupnim podacima ovakav slučaj dosad nije prikazan.

**Ključne riječi:** pas; divertikul debelog crijeva; eksploratorna celiotomija

---

