



Universiteit  
Leiden  
The Netherlands

## **Failing systemic right ventricle in a patient with dextrocardia and complex congenitally corrected transposition of the great arteries: a case report of successful transvenous cardiac resynchronization therapy**

Nederend, M.; Erven, L. van; Zeppenfeld, K.; Vliegen, H.W.; Egorova, A.D.

### **Citation**

Nederend, M., Erven, L. van, Zeppenfeld, K., Vliegen, H. W., & Egorova, A. D. (2021). Failing systemic right ventricle in a patient with dextrocardia and complex congenitally corrected transposition of the great arteries: a case report of successful transvenous cardiac resynchronization therapy. *European Heart Journal-Case Reports*, 5(4).  
doi:10.1093/ehjcr/ytab068

Version: Publisher's Version

License: [Creative Commons CC BY-NC 4.0 license](https://creativecommons.org/licenses/by-nc/4.0/)

Downloaded from: <https://hdl.handle.net/1887/3279761>

**Note:** To cite this publication please use the final published version (if applicable).

# Failing systemic right ventricle in a patient with dextrocardia and complex congenitally corrected transposition of the great arteries: a case report of successful transvenous cardiac resynchronization therapy

Marieke Nederend <sup>1,2</sup>, Lieselot van Erven<sup>1</sup>, Katja Zeppenfeld<sup>1</sup>,  
Hubert W. Vliegen<sup>1,2</sup>, and Anastasia D. Egorova <sup>1,2\*</sup>

<sup>1</sup>Department of Cardiology, Leiden Heart-Lung Center, Leiden University Medical Center, Albinusdreef 2, 2333 ZA Leiden, the Netherlands; and <sup>2</sup>CAHAL, Center for Congenital Heart Disease Amsterdam Leiden, Leiden University Medical Center, Albinusdreef 2, 2333 ZA Leiden, the Netherlands

Received 16 September 2020; first decision 30 October 2020; accepted 11 February 2021

## Background

Patients with congenitally corrected transposition of the great arteries (ccTGA) are prone to the development of advanced atrio-ventricular block requiring chronic ventricular pacing. The morphological right ventricle (RV) often develops systolic dysfunction as it is unable to withstand the chronic pressure overload it is exposed to when supporting the systemic circulation.

## Case summary

A 56-year-old woman with dextrocardia and complex ccTGA with a history of dual-chamber implantable cardioverter-defibrillator (DDD-ICD, high degree atrio-ventricular-block and syncopal ventricular tachycardia), presented with progressive heart failure and symptomatic atrial arrhythmias. She underwent a successful ablation and concomitant invasive haemodynamic evaluation of potential alternative/biventricular pacing modalities. During biventricular pacing, the QRS narrowed and the systemic RV intraventricular pressure (Dp/Dt) increased with 30%. She underwent a successful transvenous upgrade to cardiac resynchronization therapy (CRT). The electrocardiogram post-implantation showed biventricular capture and patient showed subjective and objective clinical improvement.

## Discussion

Systemic RV dysfunction in ccTGA can be aggravated by chronic pacing-induced dyssynchrony, contributing to progression of heart failure in this patient group. Transvenous CRT is feasible in ccTGA anatomy and may be pursued in order to improve or preserve the functional status of pacing-dependent ccTGA patients. Invasive haemodynamic contractility evaluation can help assess the potential benefit of CRT in patients with complex anatomy.

## Keywords

Systemic right ventricle • Congenitally corrected transposition of the great arteries • Heart failure • Pacing • Cardiac resynchronization therapy • Congenital heart disease • Case report

\* Corresponding author. Tel: +31 71 526 2020, Email: [a.egorova@lumc.nl](mailto:a.egorova@lumc.nl)

Handling Editor: Inga Voges

Peer-reviewers: Ina Michel-Behnke and Mohammed Al-Hijji

Compliance Editor: Kajaluxy Ananthan

Supplementary Material Editor: Aiste Monika Jakstaite

© The Author(s) 2021. Published by Oxford University Press on behalf of the European Society of Cardiology.

This is an Open Access article distributed under the terms of the Creative Commons Attribution Non-Commercial License (<http://creativecommons.org/licenses/by-nc/4.0/>), which permits non-commercial re-use, distribution, and reproduction in any medium, provided the original work is properly cited. For commercial re-use, please contact [journals.permissions@oup.com](mailto:journals.permissions@oup.com)

## Learning points

- Susceptibility of patients with congenitally corrected transposition of the great arteries (ccTGA) to advanced atrio-ventricular block requiring chronic ventricular pacing contributes to systemic right ventricle (sRV) dysfunction.
- Despite the often complex anatomy, efforts towards cardiac resynchronization therapy (CRT) should be made to preserve or improve sRV function of pacing-dependent ccTGA patients.
- Invasive haemodynamic evaluation prior to an upgrade to a biventricular pacing system can help assess the potential benefit of CRT in patients with complex anatomy.

## Introduction

Congenitally corrected transposition of the great arteries (ccTGA), or L-transposition of the great arteries, comprises about 0.5% of all congenital heart defects.<sup>1</sup> Adult ccTGA patients are prone to development of heart failure due to systolic dysfunction of the morphological right ventricle (RV) that functions as the systemic ventricle and is thus exposed to chronic pressure overload. The fundamental causes of morbidity and mortality in ccTGA patients are related to the gradual deterioration of systemic right ventricular (sRV) function, progressive tricuspid valve regurgitation and susceptibility to atrio-ventricular (AV) conduction disorders.<sup>2</sup> As over 80% of ccTGA patients currently survive over the age of 40 years, heart failure will be an increasing burden for this patient group.<sup>3</sup>

Malalignment of the AV septum, the relatively long course of AV conduction system and progressive shift of the AV septum towards the morphological left ventricle (LV) all contribute to the high incidence of advanced AV-block in ccTGA patients.<sup>4,5</sup> The reported prevalence of AV-block is up to 50%, with an annual risk of 2%.<sup>6</sup> Chronic pacing-induced dyssynchrony further contributes towards sRV dysfunction.<sup>5,7</sup>

Here we describe a ccTGA patient with progressive heart failure and chronic ventricular pacing that underwent a successful transvenous upgrade to cardiac resynchronization therapy (CRT).

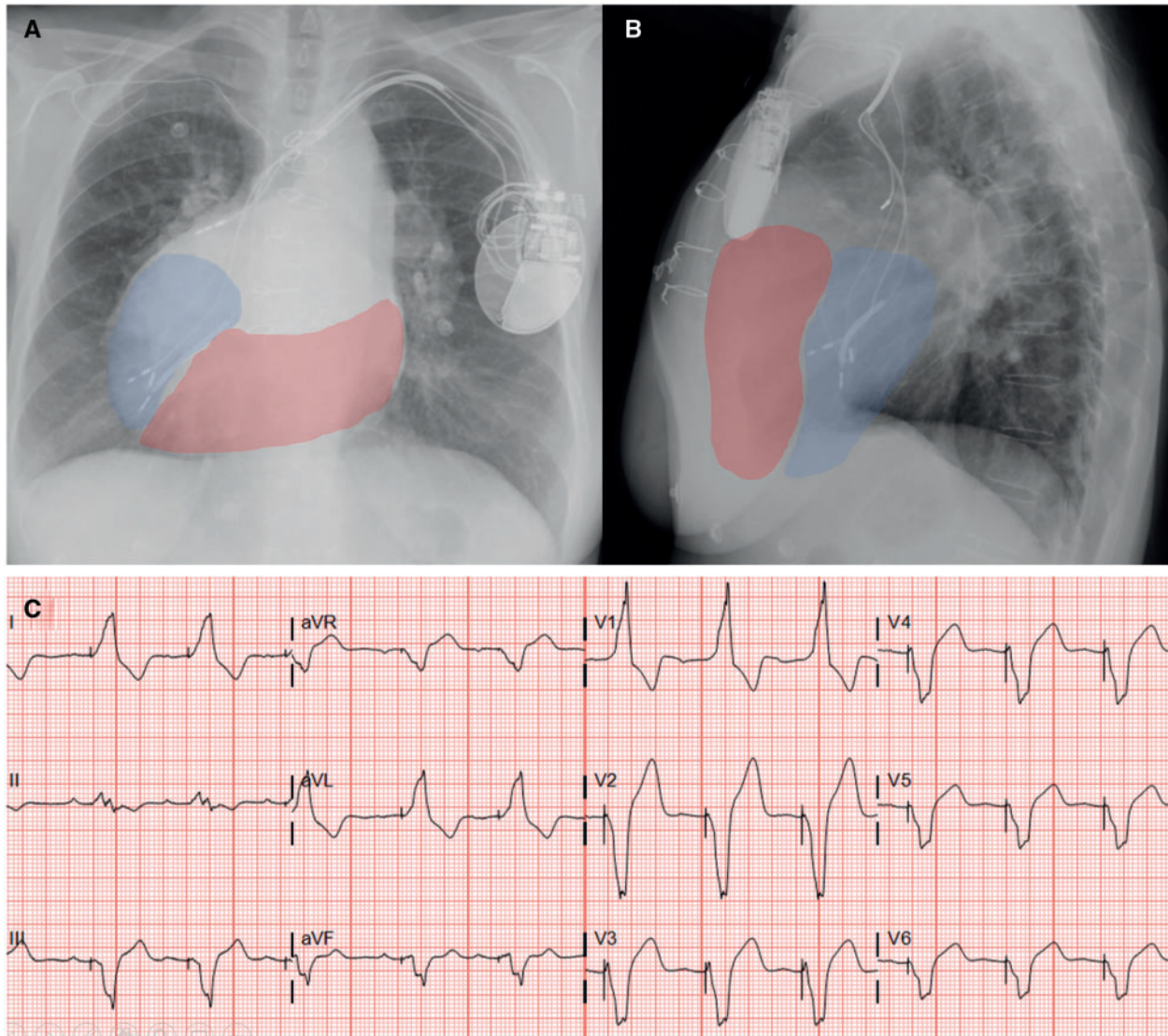
## Case presentation

A 56-year-old woman with dextrocardia and complex ccTGA was evaluated in the outpatient clinic. She had a history of surgical closure of a ventricular septal defect and correction of a pulmonary valve stenosis, a DDD-pacemaker implantation due to high degree AV-block and subsequent chronic ventricular pacing, tricuspid valve repair with an annuloplasty ring due to severe tricuspid regurgitation of an Ebstein-like valve and an upgrade to a dual-chamber implantable cardioverter-defibrillator (DDD-ICD) due to syncopal ventricular tachycardia (with a new P/S lead implant due to non-physiological oversensing). She also underwent an ablation of a ventricular tachycardia and cavo-mitral isthmus-dependent atrial flutter. A chest X-ray illustrating the anatomy and lead positions is shown in *Figure 1A and B*. Over the past few years, she had been admitted multiple times with decompensated congestive heart failure due to severely reduced systolic function [RV end-diastolic diameter (RVEDD) 56 mm, global longitudinal strain -3.5%, fractional area change (FAC) 10.3%] of the dilated sRV, despite maximum tolerated pharmacological therapy with metoprolol, candesartan, spironolactone, and furosemide.

The patient experienced recurrent palpitations due to an atrial tachycardia that could be terminated by atrial burst pacing. Electrocardiogram (ECG) in sinus rhythm with subpulmonary LV pacing showed a broad (210 ms) QRS complex (*Figure 1C*). She underwent successful re-ablation of the cavo-mitral isthmus-

## Timeline

|         |   |
|---------|---|
| 1963    | Congenital defects/anatomy:<br>Dextrocardia;<br>Congenitally corrected Transposition of the Great Arteries (ccTGA);<br>Ventricular septal defect (VSD);<br>Pulmonary valve stenosis (PS);<br>Ebstein-like tricuspid valve   |
| 1970    | Surgical closure of the VSD and repair of PS  |
| 1990    | DDD-pacemaker implantation due to complete heart block  |
| 2004    | Tricuspid valve annuloplasty  |
| 2005    | Admission: decompensated heart failure and atrial flutter   |
| 2009    | Syncope due to Ventricular Tachycardia (VT): ICD implantation   |
| 2011    | Multiple presentations and admissions: decompensated heart failure and atrial tachycardia/flutter   |
| 2015    | Appropriate ICD shock (VT);<br>Successful endocardial VT ablation and cavomitral isthmus flutter ablation   |
| 2015–18 | Recurrent presentations with atrial tachycardia and decompensation; New York Heart Association (NYHA) III   |
| 2019    | April: electrophysiology study and ablation of cavo-mitral isthmus-dependent flutter and atrial tachycardia;<br>Concomitant coronary sinus angiogram and invasive Dp/Dt measurements to assess cardiac resynchronization therapy (CRT);<br>May: admission with decompensated heart failure, successful upgrade to CRT-D;<br>June to December: stable clinical condition |
| 2020    | Stable clinical condition and NYHA functional class II  |

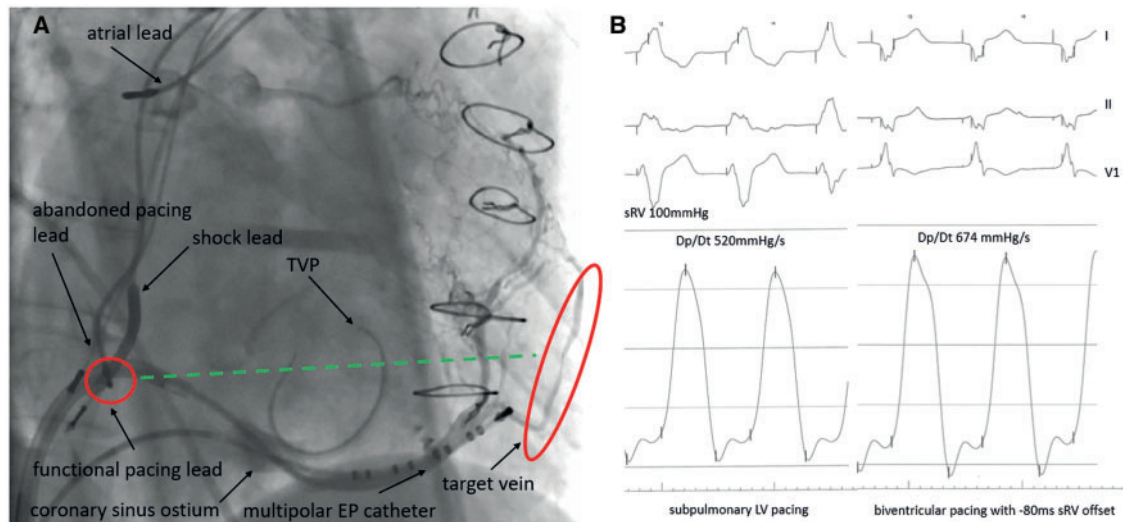


**Figure 1** (A) Postero-anterior and (B) lateral chest X-ray image of the patient presenting with congestive heart failure illustrating the dextrocardia and congenitally corrected transposition of the great arteries anatomy with left anterior position of the dilated systemic right ventricle (red) and right posterior position of the subpulmonary left ventricle (blue) with transvenous pacing leads in situ. (C) Twelve lead electrocardiogram with a broad QRS (210 ms) complex during left ventricular pacing.

dependent atrial flutter and incisional right atrial tachycardia. The broad paced QRS complex and recurrent admissions with decompensated heart failure prompted concomitant invasive haemodynamic evaluation of the intraventricular pressure (Dp/Dt) with a pigtail in the sRV, to assess potential alternative/biventricular pacing modalities (Figure 2). The anatomic subpulmonary LV pacing with a steerable catheter led to a QRS width >200 ms and Dp/Dt of 520 mmHg/s. A second steerable multiple electrode catheter was used for coronary sinus pacing to assess the optimal target site. Several intervals were tested—the optimal biventricular pacing with -80 ms right ventricular offset resulted in QRS narrowing to 157 ms and Dp/Dt increase to 674 mmHg/s (30%). This suggested that transvenous upgrade to a CRT-system was feasible and was expected to lead to significant haemodynamic improvement.

A second procedure was performed for upgrade to a CRT-system. The coronary sinus was engaged with an extended hook guiding-catheter and an RV target vein was selectively cannulated with a 90-degree inner-catheter. A unipolar 4.5 Fr (1.5 mm) lead with 2.6 Fr (0.87 mm) tip was advanced into the target branch over a wire (Figure 3). The threshold for sRV capture was 2.1 V/1 ms, without phrenic nerve stimulation during high output pacing. This lead position provided a large anatomical separation from the functional RV lead tip and an RV to LV sense interval of >150 ms, confirming good electric separation of the two leads. The postprocedural chest X-ray showed the lead position in relation to the patient's anatomy and ECG post-implantation showed significant reduction of the QRS width during biventricular capture (Figure 4).



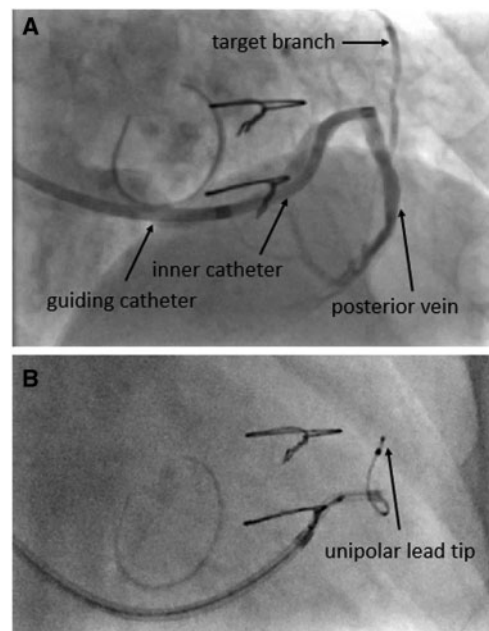


**Figure 2** (A) Angiographic projection (RAO 40°) showing the transvenous device leads and the multipolar electrophysiology catheter inserted into the coronary sinus that is in close proximity to the tricuspid valve annulus [identified here by the tricuspid valve annuloplasty ring (TVP)]. A contrast injection shows the course of the coronary sinus and its tributaries. The target vein is defined by optimal separation from the functional pacing lead tip electrode. (B) The intra-ventricular pressure-curves registered during the invasive haemodynamic evaluation of the different pacing modalities. Note the Dp/Dt of 520 mmHg/s during the subpulmonary left ventricular pacing (left panel) and Dp/Dt of 674 mmHg/s during biventricular pacing with -80 ms right ventricular offset (right panel).

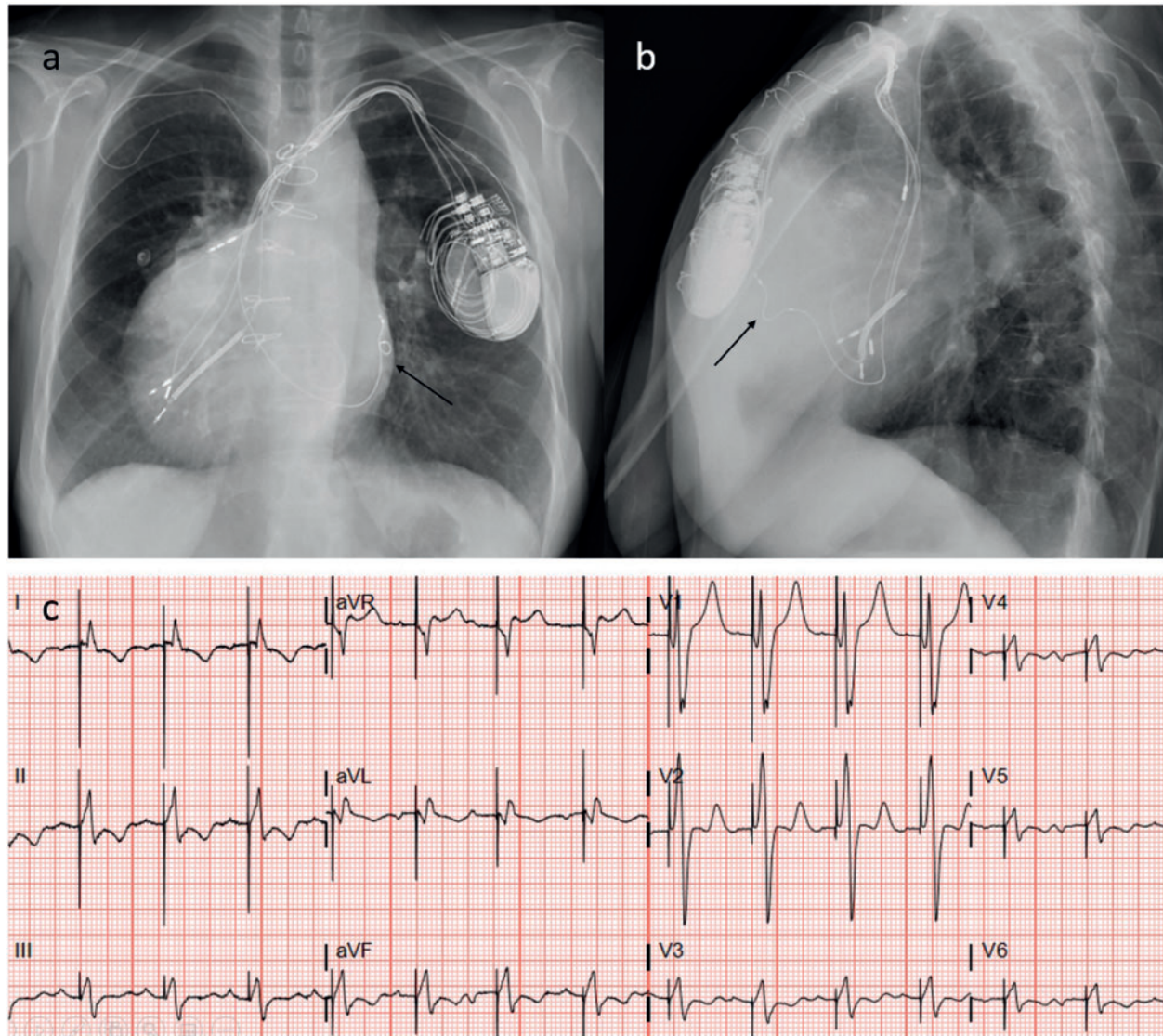
The patient reported evident and continuous improvement in clinical condition at follow-up 6, 12, and 24 weeks after discharge. [Table 1](#) summarizes clinical parameters at baseline and 24 weeks follow-up. Six-minute walk test and bicycle exercise test ( $VO_2$  max) showed consistent improvement from 417 to 522 m, 40 to 80 Watt, and 8.3 to 14.7 mL/min/kg, respectively. Echocardiography showed a slight reduction in RVEDD to 53 mm and FAC improvement to 14.6%. The patient is currently in stable clinical condition and New York Heart Association (NYHA) functional class II, with only mild dyspnoea on exertion (e.g. walking outside the house), 1 year after CRT procedure, no heart failure-related admissions occurred during this period.

## Discussion

Congenitally corrected transposition of the great arteries is a rare congenital heart anomaly that entails a combination of morphological AV and ventriculo-arterial discordance (often referred to as ‘double discordance’) resulting from abnormal looping of the embryonic cardiac tube. Although such anatomy can result in physiologically normal circulation, this is often not the case due to the common concomitant malformations, including ventricular septal defect, pulmonary stenosis, and abnormalities of the tricuspid valve.<sup>1,2</sup> The ccTGA patient described here was born with the illustrative combination of concomitant defects, including an Ebstein-like tricuspid valve and dextrocardia (encountered in about one in five of ccTGA patients). Another typical associated pathology illustrated in this case is a high degree AV conduction block. Additional to the abnormal conduction system in ccTGA hearts, the surgical closure of the ventricular septal defect in



**Figure 3** (A) Angiographic projection (RAO 27°) showing the guiding and inner-catheter engaged in the coronary sinus and the target branch, respectively. (B) Angiographic projection (RAO 37°) showing the position of the transvenous coronary sinus lead tip in the target vein.



**Figure 4** (A) Postero-anterior and (B) lateral chest X-ray image after the transvenous upgrade to cardiac resynchronization therapy. Arrow points towards the newly implanted lead on the systemic right ventricle. Note the epicardial lead projecting over the systemic right ventricle. (C) Twelve lead electrocardiogram during biventricular pacing showing significant QRS narrowing.

1970 (using a patch and requiring a ventriculotomy of the sRV) as well as progressive pressure overload of the sRV with shift of the intraventricular septum towards the LV are likely to have contributed to the progressive conduction disorder, making her pacing dependent at the age of 27 years.

Chronic pacing-induced dyssynchronous cardiomyopathy is recognized to contribute to progression of sRV dysfunction and small, yet consistent data suggest that efforts towards CRT should be undertaken in this patient group.<sup>5,7,8</sup> This is illustrated by our pacing-dependent cTGA patient who was a clear responder. However, appropriate selection of CRT candidates in failing sRV remains a matter of discussion and large randomized studies are lacking. This might be due to the morphological heterogeneity, the wide range of surgical techniques used to repair the associated structural defects and the

unknown predictive value of the electro-mechanical activation delay in complex anatomy.

Echocardiographic evaluation of the sRV (dyssynchrony) is often limited by the RV geometry, eccentric hypertrophy, and pronounced moderator band as well as to date poorly understood interventricular interactions.<sup>9</sup> The QRS width and morphology seem to be a relatively poor selection marker for sRV CRT candidates.<sup>10</sup> Contractility measurement derived from Dp/Dt has previously been validated in adult patients with dilated cardiomyopathy (with systemic LV).<sup>11</sup> In congenital heart disease patients, an improvement of Dp/Dt of >15% is correlated with a clinical response to CRT as well as long-term stable function and improvement in ejection fraction (up to 12 years of follow-up).<sup>9</sup> In this patient, Dp/Dt increased by 30% during biventricular pacing when compared with the subpulmonary LV pacing alone



**Table 1** Clinical parameters before and after CRT upgrade

|   | Pre-CRT          | Post-CRT         |
|---|------------------|------------------|
| General                                       |                  |                  |
| NYHA classification                           | III—ambulant IV  | II               |
| 6 MWT (m)                                     | 417              | 522              |
| Laboratory values                             |                  |                  |
| NT-pro BNP (ng/L)                             | 9663             | 6101             |
| Renal function, eGFR (mL/min/m <sup>2</sup> ) | 33               | 36               |
| Echocardiography                              |                  |                  |
| sRV function 'eyeballing'                     | Severely reduced | Severely reduced |
| Tricuspid valve regurgitation (grade)         | II               | II               |
| Basal sRVEDD (mm)                             | 56.0             | 53.0             |
| sRV GLS (%)                                   | -3.5             | -3.6             |
| sRV FAC (%)                                   | 10.3             | 14.6             |
| Exercise testing                              |                  |                  |
| Maximal capacity (Watt)                       | 40               | 80               |
| VO <sub>2</sub> max (mL/min/kg)               | 8.3              | 14.7             |

6 MWT, six-minute walk test; CRT, cardiac resynchronization therapy; eGFR, estimated glomerular filtration rate; FAC, fractional area change; GLS, global longitudinal strain; NT-pro BNP, N-terminal prohormone of brain natriuretic peptide; NYHA, New York Heart Association Functional Classification; RVEDD, right ventricular end-diastolic diameter; sRV, systemic right ventricle.

and correlated with subjective well-being and objective functional follow-up after initiation of CRT.

Despite the achieved subjective and objective improvement in this patient, it is sensible to expect the CRT to merely delay the progression of heart failure in this complex patient group. Donor hearts are scarce in the Netherlands and given the patient's anatomy, numerous previous thoracotomies, and renal functional impairment it is highly unlikely she will be eligible for a heart transplant listing. Ventricular assist device (VAD) implantation as destination therapy, however, should be considered in patients with severe sRV failure. Despite the potential complications of a VAD, it has been shown to be feasible in sRV patients and to result in survival benefit and clinical improvement.<sup>12</sup>

In conclusion, one should be aware of the heart failure prone sRV in ccTGA patients, particularly when complicated by advanced AV-block requiring chronic ventricular pacing. Transvenous CRT may be challenging, yet feasible in ccTGA anatomy and should be considered in order to improve or preserve the systolic sRV function. Invasive haemodynamic evaluation prior to upgrade to or implantation of biventricular pacing system may help to assess the potential benefit of CRT in patients with complex anatomy.

## Statement of ethics

All procedures performed involving the human participant were in accordance with the ethical standards of the institutional and/or national research committee and with the 1964 Helsinki declaration and its later amendments or comparable ethical standards.

## Lead author biography



Marieke Nederend (1993) is currently a PhD candidate at the Leiden University Medical Centre, the Netherlands. Her thesis is focusing on clinical outcomes in (the ageing) congenital heart disease patients, with a specific focus on the systemic right ventricular failure. During her time in the clinic, the work described in this case report was performed.

## Supplementary material

Supplementary material is available at *European Heart Journal - Case Reports* online.

**Slide sets:** A fully edited slide set detailing this case and suitable for local presentation is available online as [Supplementary data](#).

**Consent:** The authors confirm that written consent for submission and publication of this case report including images and associated text has been obtained from the patient in line with COPE guidance.

**Conflict of interest:** None declared.

**Funding:** The authors were funded by the general funding of the department of Cardiology of the Leiden University Medical Center (M.N., L.v.E., K.Z.E., H.W.V., and A.D.E.). A.D.E. received additional financial support from the Johanna Zaaijer fund of the Leiden University Medical Center.

## References

- Samánek M, Vorísková M. Congenital heart disease among 815,569 children born between 1980 and 1990 and their 15-year survival: a prospective bohemian survival study. *Pediatr Cardiol* 1999;**20**:411–417.
- Filippov AA, Del Nido PJ, Vasilyev NV. Management of systemic right ventricular failure in patients with congenitally corrected transposition of the great arteries. *Circulation* 2016;**134**:1293–1302.
- Dobson R, Danton M, Nicola W, Hamish W. The natural and unnatural history of the systemic right ventricle in adult survivors. *J Thorac Cardiovasc Surg* 2013;**145**:1493–1501; discussion 1501–3.
- Rutledge JM, Nihill MR, Fraser CD, Smith OE, McMahon CJ, Bezold LI. Outcome of 121 patients with congenitally corrected transposition of the great arteries. *Pediatr Cardiol* 2002;**23**:137–145.
- Jauvert G, Rousseau-Paziaud J, Villain E, Iserin L, Hidden-Lucet F, Ladouceur M et al. Effects of cardiac resynchronization therapy on echocardiographic indices, functional capacity, and clinical outcomes of patients with a systemic right ventricle. *Europace* 2009;**11**:184–190.
- Baruteau AE, Abrams DJ, Ho SY, Thambo JB, McLeod CJ, Shah MJ. Cardiac conduction system in congenitally corrected transposition of the great arteries and its clinical relevance. *J Am Heart Assoc* 2017;**6**: e007759.
- Hofferberth SC, Alexander ME, Mah DY, Bautista-Hernandez V, del Nido PJ, Fynn-Thompson F. Impact of pacing on systemic ventricular function in L-transposition of the great arteries. *J Thorac Cardiovasc Surg* 2016;**151**:131–138.
- Janoušek J, Kubuš P. Cardiac resynchronization therapy in congenital heart disease. *Herzschr Elektrophys* 2016;**27**:104–109.
- Karpawich PP, Bansal N, Samuel S, Sanil Y, Zelin K. 16 Years of cardiac resynchronization pacing among congenital heart disease patients: direct contractility

- (dP/dt-max) screening when the guidelines do not apply. *JACC Clin Electrophysiol* 2017;**3**:830–841.
10. Motonaga KS, Dubin AM. Cardiac resynchronization therapy for pediatric patients with heart failure and congenital heart disease: a reappraisal of results. *Circulation* 2014;**129**:1879–1891.
  11. Nelson GS, Berger RD, Fetcs BJ, Talbot M, Spinelli JC, Hare JM et al. Left ventricular or biventricular pacing improves cardiac function at diminished energy cost in patients with dilated cardiomyopathy and left bundle-branch block. *Circulation* 2000;**102**:3053–3059.
  12. Zandstra TE, Palmen M, Hazekamp MG, Meyns B, Beeres SLMA, Holman ER et al. Ventricular assist device implantation in patients with a failing systemic right ventricle: a call to expand current practice. *Neth Heart J* 2019;**27**: 590–593.