



Universiteit
Leiden
The Netherlands

Peritoneal dialysis improves quality-of-life in a left ventricular assist device destination therapy patient: a case report

Koppel, C.J.; Jonker, J.T.; Michels, W.M.; Beeres, S.L.M.A.

Citation

Koppel, C. J., Jonker, J. T., Michels, W. M., & Beeres, S. L. M. A. (2021). Peritoneal dialysis improves quality-of-life in a left ventricular assist device destination therapy patient: a case report. *European Heart Journal-Case Reports*, 5(10). doi:10.1093/ehjcr/ytab307

Version: Publisher's Version

License: [Creative Commons CC BY-NC 4.0 license](#)

Downloaded from: <https://hdl.handle.net/1887/3279745>

Note: To cite this publication please use the final published version (if applicable).

Peritoneal dialysis improves quality-of-life in a left ventricular assist device destination therapy patient—a case report

Claire J. Koppel ¹, Jacqueline T. Jonker², Wieneke M. Michels²,
Saskia L.M.A. Beeres^{1*}

¹Department of Cardiology, Leiden University Medical Center, Albinusdreef 2, 2333 ZA Leiden, The Netherlands; and ²Department of Nephrology, Leiden University Medical Center, Albinusdreef 2, 2333 ZA Leiden, The Netherlands

For the podcast associated with this article, please visit <https://academic.oup.com/ehjcr/pages/podcast>

Received 4 January 2021; first decision 18 May 2021; accepted 13 July 2021; online publish-ahead-of-print 29 July 2021

Background

Progressive renal insufficiency is frequent in heart failure patients with a left ventricular assist device (LVAD). The optimal strategy for long-term dialysis in LVAD patients and its effect on quality-of-life in these patients remain to be determined.

Case summary

Our 55-year-old patient with pre-existing renal insufficiency received an LVAD as destination therapy because of advanced ischaemic heart failure. Six years after implantation, he developed end-stage renal disease for which peritoneal dialysis (PD) was initiated. Left ventricular assist device flow alterations during ultrafiltration did not cause clinical or technical problems. The patient's exercise capacity increased and quality-of-life improved. Over 7.5 years after LVAD implantation and 16 months after PD initiation, he died from encephalitis.

Discussion

Despite initial improvement, renal function often gradually decreases after LVAD implantation. Data on long-term renal replacement therapy in LVAD patients are limited. Haemodialysis is most commonly applied. Conceptually, however, PD has advantages over haemodialysis including less bloodstream infections, less haemodynamic shifts, and the comfort of the ambulant setting. This case illustrates that PD in an LVAD patient is feasible and improves quality-of-life. Key factors contributing to successful PD in LVAD patients may be a good right ventricular function and close cardiology–nephrology collaboration.

Keywords

Left ventricular assist device • Renal replacement therapy • Peritoneal dialysis • Heart failure • Quality-of-life • Case report

Learning points

- Peritoneal dialysis (PD) can be a viable option for improving quality-of-life for left ventricular assist device patients developing end-stage renal disease.
- To prevent bleeding complications at the PD catheter site, temporary adjustment of antithrombotic regimen should be considered before PD catheter placement.
- Left ventricular assist device flow variations during high ultrafiltration can occur but in general do not cause clinical or technical problems.

* Corresponding author. Tel: +31 71 526 2020, Email: s.l.m.beeres@lumc.nl

Handling Editor: Matteo Cameli

Peer-reviewers: Abdullah Sayied Abdullah; ; Subhi Akleh; ; Lilit Baghdasaryan

Compliance Editor: Hibba Kurdi

Supplementary Material Editor: Nida Ahmed

© The Author(s) 2021. Published by Oxford University Press on behalf of the European Society of Cardiology.

This is an Open Access article distributed under the terms of the Creative Commons Attribution Non-Commercial License (<http://creativecommons.org/licenses/by-nc/4.0/>), which permits non-commercial re-use, distribution, and reproduction in any medium, provided the original work is properly cited. For commercial re-use, please contact journals.permissions@oup.com

Introduction

The number of patients with a left ventricular assist device (LVAD) increases. Accordingly, the specialized teams caring for these patients get more experienced in managing LVAD-associated complications and overall survival improves.^{1–3} Concomitant renal disease is frequent and affects survival and quality-of-life after LVAD implantation. As renal function is known to deteriorate over time,^{1,2} an increasing number of LVAD patients, while living longer, will develop end-stage renal disease and require renal replacement therapy (RRT).

The optimal strategy for long-term RRT in LVAD patients remains to be determined.⁴ Haemodialysis (HD) is the most common modality applied in this patient group. So far, only a few reports on peritoneal dialysis (PD) in LVAD patients have been published.^{4–6} Despite its paramount importance, data on how PD affects quality-of-life in LVAD patients are lacking. We present the case of an LVAD patient successfully treated with PD and the lessons learned.

Timeline

Date	Event(s)
23 years prior to index event	Heart failure with reduced ejection fraction after myocardial infarction.
16 years prior to index event	Septic shock complicated by acute tubulus necrosis. Temporarily continuous veno-venous haemofiltration (CVVH).
6 years prior to index event	Advanced heart failure New York Heart Association (NYHA) Class IV. Rejected for heart transplant because of impaired renal function [estimated glomerular filtration rate (eGFR) 22 mL/min/1.73 m ²]. Left ventricular assist device (LVAD) implantation as destination therapy. Post-operative temporarily CVVH. After discharge, NYHA Class II and eGFR 32 mL/min/1.73 m ² .
3–2 years prior to index event	eGFR values of 14–23 mL/min/1.73 m ² . Several hospitalizations for fluid overload of renal aetiology. Good LVAD function. Good right ventricular function.
3 months prior to index event	Worsening renal function due to contrast nephropathy: temporarily CVVH.
Index event	Readmission for fluid overload, persistently dependent on intravenous diuretics. Start peritoneal dialysis.
1–15 months post-admission	Ambulatory and NYHA Class II, no fluid overload, improved quality-of-life.
16 months post-admission	Herpes Zoster encephalitis. Patient passed away.

Case presentation

A 33-year-old Caucasian man developed heart failure after myocardial infarction in 1996. In 2003, he had a septic shock with acute tubular necrosis treated by continuous veno-venous haemofiltration (CVVH). Renal function recovered to an estimated glomerular filtration rate (eGFR) of 40 mL/min/1.73 m² (normal value >60 mL/min/1.73 m²). Despite revascularization and cardiac resynchronization therapy, he developed heart failure New York Heart Association (NYHA) Class IV in 2013. He was rejected for a heart transplant because of his impaired renal function (eGFR 22 mL/min/1.73 m²). A combined heart–kidney transplant is not performed in the Netherlands. During LVAD screening, ultrasonography showed normal kidney sizes with diffuse loss of renal cortex but no focal parenchymal degeneration or hydronephrosis. As on inotropes and temporary mechanical support with an Impella® (ABIOMED Inc., Danvers, MA, USA) renal function improved to an eGFR of 39 mL/min/1.73 m², we hypothesized that renal function could partly recover after optimization of haemodynamics with an LVAD. Accordingly, the patient was accepted for LVAD (HeartWare Inc., Framingham, MA, USA) implantation as destination therapy. The post-operative period was complicated by acute tubular necrosis treated by CVVH. Renal function recovered to eGFR of 27 mL/min/1.73 m² and exercise capacity improved to NYHA Class II.

In 2016–2017, renal function fluctuated with eGFR values of 14–23 mL/min/1.73 m². The patient was admitted several times with congestion in this time frame. Echocardiographic pump speed evaluation showed that, at the current speed (2700 RPM), the interventricular septum had a neutral position, indicating good left ventricular unloading. The tricuspid annular plane systolic excursion was 17 mm, evidencing a good right ventricular (RV) function. Aortic valve opening was intermittent with minimal diastolic regurgitation. With the latter, clinically relevant recirculation of blood volume (from the left ventricle through the LVAD into the aorta and back into the left ventricle) is excluded. Pump data revealed good LVAD function with a power of 4.4 W and a flow of 4.7 L/min with good pulsatility. Accordingly, it was concluded that the fluid overload mainly had a renal aetiology. Upon treatment with intravenous diuretics, a euvolemic status was reached during each admission whereafter the patient could be discharged home.

In 2018, at the age of 55, the patient was hospitalized because of acute renal function worsening with anuria due to contrast nephropathy after a computed tomography scan for abdominal pain. After 18 days of CVVH, renal function recovered. In February 2019, he was re-admitted for congestion. Echocardiography showed adequate left ventricular unloading and a good RV function. The LVAD values were normal. With intravenous furosemide he became euvolemic but remained dependent on intravenous diuretics. At this time, optimization of haemodynamics with inotropes did not improve renal function illustrating that the renal dysfunction was irreversible. Therefore, we decided to start dialysis. As there was no adequate vascular access to create a functional arteriovenous graft, HD was not possible. The PD catheter placement was complicated by an

abdominal wall haematoma treated by temporary interruption of anti-platelet therapy.

Continuous PD was started with 1 L icodextrin overnight resulting in an ultrafiltration of 300 mL and metabolites within range and a residual diuresis of 1.5 L. Body weight remained stable without the need for intravenous diuretics and he was discharged. In May 2019, he was re-admitted because of congestion despite intensification of the PD scheme to two long dwells of 1.5 L of icodextrin and 15 mg bumetanide a day. Urine production had decreased to 800 mL/24 h and ultrafiltration fluctuated from 100 mL to 1 L/day. LVAD flow and pulsatility remained stable between 3 and 6 L/min. The patient was treated with furosemide intravenously and initiation of glucose-based PD fluids (physioneal) using automated peritoneal dialysis (APD). With a regimen of seven cycles of 1 L 3.86% glucose in 9.5 h, 2–2.5 L ultrafiltration was established and bodyweight returned to target weight. Unfortunately, the patient had become anuric within this period. After 3 weeks, the patient was haemodynamically stable, without intravenous medication and with stable ultrafiltration on the new PD schedule. He was discharged with APD, seven cycles of 1.5 L 2.27% glucose in 10 h. He regained 500 mL residual diuresis and ultrafiltration on this schedule was 1600 mL/day.

From July 2019 until June 2020, the patient was ambulatory and in NYHA Class II. On physical examination and echocardiography, there were no signs of fluid overload. He was trained in adjustment of his PD schedule based on bodyweight and signs of congestion. His quality-of-life, assessed with the Minnesota Living with Heart Failure questionnaire, significantly improved from 80 of 105 before PD in February 2019 to 51 of 105 in July 2019. The patient reported he had regained pleasure in life again, especially due to the reduced sense of thirst and the improved exercise capacity that enabled him to sail his boat again. LVAD flow remained stable during PD (Figure 1). In July 2020, he developed herpes zoster encephalitis of which he died.

Discussion

Patients evaluated for LVAD therapy frequently have concomitant renal disease. An impaired renal function before LVAD implantation is inversely related to post-implant survival.^{3,4} In general, renal function initially improves after LVAD implantation, especially in patients with cardiorenal pathophysiology. After initial improvement, a gradual decline in eGFR is frequently observed.^{1,2} In clinical practice, however, it remains challenging to predict which patients will need RRT post-LVAD.¹ As RRT is associated with a poor prognosis and impairs quality-of-life, it is necessary to also take the patient's suitability and ability to perform dialysis into account when evaluating a patient with impaired renal function for LVAD.

Data on long-term RRT in LVAD patients are limited, and no trial data exist for patients needing dialysis for a prolonged time. The most common applied modality in LVAD patients is HD although, compared to PD, it is associated with an increased risk of bloodstream infections and the haemodynamic shifts during HD may interfere with optimal LVAD function and result in low flow alarm.^{4,5} Nevertheless, there are a few published series describing successful in-centre HD in LVAD patients.^{3,6,7} Conceptually, PD has several advantages over HD in LVAD patients, including the comfort of the ambulant setting and more patient self-management with respect to fluid balance.^{4,5} On the other hand, PD catheter placement in the proximity of the LVAD driveline may theoretically increase the risk of a driveline infection.

Only a few case reports describe successful PD in LVAD patients. Gugliemi *et al.*⁵ describe a 78-year-old patient with renal failure due to cholesterol embolic disease 1 year after LVAD implantation. Haemodialysis was attempted but unfeasible after which APD was successfully performed for at least 1 year.⁵ Thomas *et al.*⁸ describe a 63-year-old patient performing PD requiring an LVAD while awaiting a heart transplant. Peritoneal dialysis was performed for 11 days post-surgery after which the patient died of thrombo-embolic shock.

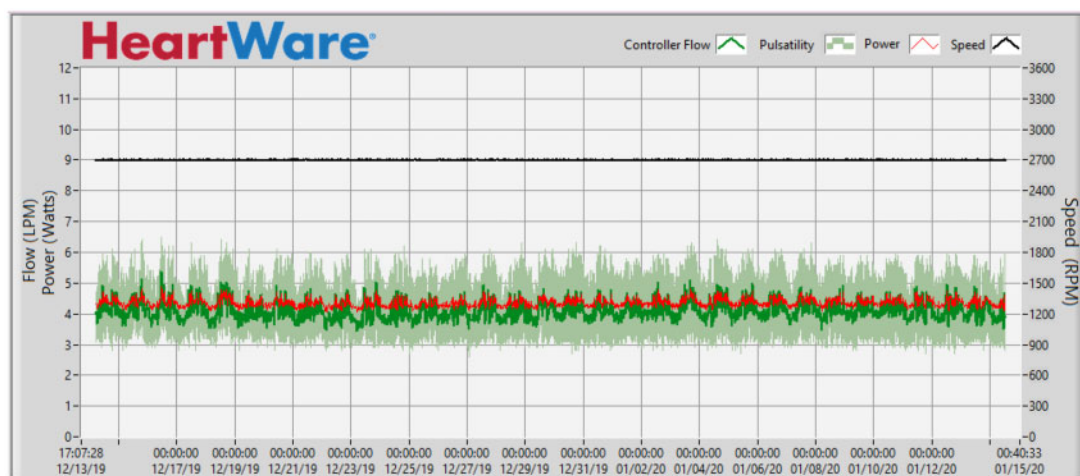


Figure 1 Heartware left ventricular assist device logfile report showing stable controller flow and pulsatility during peritoneal dialysis. The circadian rhythm visible indicates that the patient was active during this time. Flow mean: 4.4 L/min, pulsatility mean: 1.8 L/min, power mean: 4.4 W.

Table 1 Factors potentially contributing to successful peritoneal dialysis treatment in left ventricular assist device patients

Patient characteristics	Medical centre characteristics
<ul style="list-style-type: none"> • Adequate understanding of LVAD function and fluid retention • Trainable for self-adaptation of peritoneal dialysis scheme. Preferably also applicable to family/housemates • Good right ventricular function 	<ul style="list-style-type: none"> • Technical capacities for catheter placement • Close collaboration of cardiologists and nephrologists • Psychological support to accept the lifelong dependence on two devices

In line with the two above-described cases, we confirm that PD is technically feasible in an LVAD patient. Catheter placement was feasible although temporary adjustment of the antithrombotic regimen seems worthwhile. While on PD, a driveline infection did not occur, probably because the PD catheter was inserted on the contralateral side of the abdomen as the driveline exit site. In addition, patient education on the care of the driveline exit site and the PD catheter exit site was regularly repeated. During high ultrafiltration, variations in LVAD flow occurred but did not cause clinical or technical problems. This case extends the current knowledge by demonstrating that PD improves quality-of-life in an LVAD patient with end-stage renal disease. Medical and psychological counselling before the start, close cardiology–nephrology co-operation and a good RV function were crucial factors attributing to his improved quality-of-life (Table 1).

Conclusion

For LVAD patients developing end-stage renal disease, PD is a viable option for improving quality-of-life.

Lead author biography



Claire Koppel is a PhD candidate at the Cardiology department of the Leiden University Medical Center. Her research focusses on coronary anomalies and innervation after myocardial infarction. Next to her work as PhD candidate, she is also one of the LVAD coordinators at the department.

Supplementary material

Supplementary material is available at *European Heart Journal - Case Reports* online.

Slide sets: A fully edited slide set detailing these cases and suitable for local presentation is available online as [Supplementary data](#).

Consent: The authors confirm that witnessed verbal consent for submission and publication of this case report including images and associated text has been obtained from the patients detailed in this case report. This has been discussed with the editors.

Conflict of interest: None declared.

Funding: None declared.

References

1. Raichlin E, Baibhav B, Lowes BD, Zolty R, Lyden ER, Vongooru HR et al. Outcomes in patients with severe preexisting renal dysfunction after continuous-flow left ventricular assist device implantation. *ASAIO J* 2016;**62**:261–267.
2. Hasin T, Grupper A, Dillon JJ, Maleszewski JJ, Li Z, Topilsky Y et al. Early gains in renal function following implantation of Heartmate II left ventricular assist devices may not persist to one year. *ASAIO J* 2017;**63**:401–407.
3. Franz DD, Hussein WF, Abra G, Diskin CD, Duggal V, Teuteberg JJ et al. Outcomes among patients with left ventricular assist devices receiving maintenance outpatient hemodialysis: a case series. *Am J Kidney Dis* 2021;**77**:226–234.
4. Roehm B, Vest AR, Weiner DE. Left ventricular assist devices, kidney disease, and dialysis. *Am J Kidney Dis* 2018;**71**:257–266.
5. Guglielmi AA, Guglielmi KE, Bhat G, Siemeck R, Tatoes AJ. Peritoneal dialysis after left ventricular assist device placement. *ASAIO J* 2014;**60**:127–128.
6. Quader MA, Kumar D, Shah KB, Fatani YI, Katlaps G, Kasirajan V. Safety analysis of intermittent hemodialysis in patients with continuous flow left ventricular assist devices. *Hemodial Int* 2014;**18**:205–209.
7. Calenda BV, Smietana J, Casagrande L. Long-term hemodialysis via arteriovenous fistula in patients with continuous-flow left ventricular assist devices. *Artif Organs* 2016;**40**:712.
8. Thomas BA, Logar CM, Anderson AE. Renal replacement therapy in congestive heart failure requiring left ventricular assist device augmentation. *Perit Dial Int* 2012;**32**:386–392.