



**Universiteit
Leiden**
The Netherlands

Editor's Choice to the December 2021 issue

Reiber, J.H.C.

Citation

Reiber, J. H. C. (2021). Editor's Choice to the December 2021 issue. *International Journal Of Cardiovascular Imaging*, 37(12), 3371-3372. doi:10.1007/s10554-021-02463-1

Version: Publisher's Version

License: [Creative Commons CC BY 4.0 license](#)

Downloaded from: <https://hdl.handle.net/1887/3277695>

Note: To cite this publication please use the final published version (if applicable).



Editor's Choice to the December 2021 issue

Johan H. C. Reiber¹

Published online: 3 November 2021

© The Author(s), under exclusive licence to Springer Nature B.V. 2021

Dear reader,

This is already the final issue of 2021! Time flies!

This year we have introduced the Editor's Choice in highlighting a particular paper in an issue, that I found particularly worthwhile to mention, plus also the Commentaries on published papers. Although, the number of Commentaries is still relatively small, I do hope that our readership enjoys these; we are of course thankful to the authors of these Commentaries who spend the extra time and effort in writing these. It would be even nicer when these Commentaries are followed by other Commentaries again, so that a discussion is started.

For this December 2021 issue, I would like to recommend the paper "Transthoracic echocardiographic reference values of the aortic root: results from the Hamburg City Health Study" by Dr Jan-Per Wenzel and co-authors from Hamburg, Germany [1]. In this work, the authors have derived up-to-date reference values of transthoracic echocardiographic

aortic root dimensions matched by sex, age, and body surface area (BSA) derived from the population-based Hamburg City Health Study (HCHS) cohort. This work is based on a total of 1687 healthy subjects (mean age 57.1 ± 7.7 , 681 male and 1006 female), who participate in the Hamburg City Health Study, which includes a total of 45.000 participants. An example of the measurements is given below, which is their Fig. 2 in the original manuscript.

Also this Study has a number of limitations as the authors describe under Limitations, but it is a great start for deriving "normal" aortic root dimensions in individuals. They propose that other correlation studies with other imaging modalities, such as MRI and MSCT, are to be set up to establish a standardized and uniform measuring method.

Anyway, I wish you much pleasure in reading this and the other papers in this issue of the International Journal of Cardiovascular Imaging, and of course wish you a pleasant, successful and healthy last period of 2021.

✉ Johan H. C. Reiber
J.H.C.Reiber@lumc.nl

¹ Department of Radiology, Leiden University Medical Centre, Leiden, The Netherlands

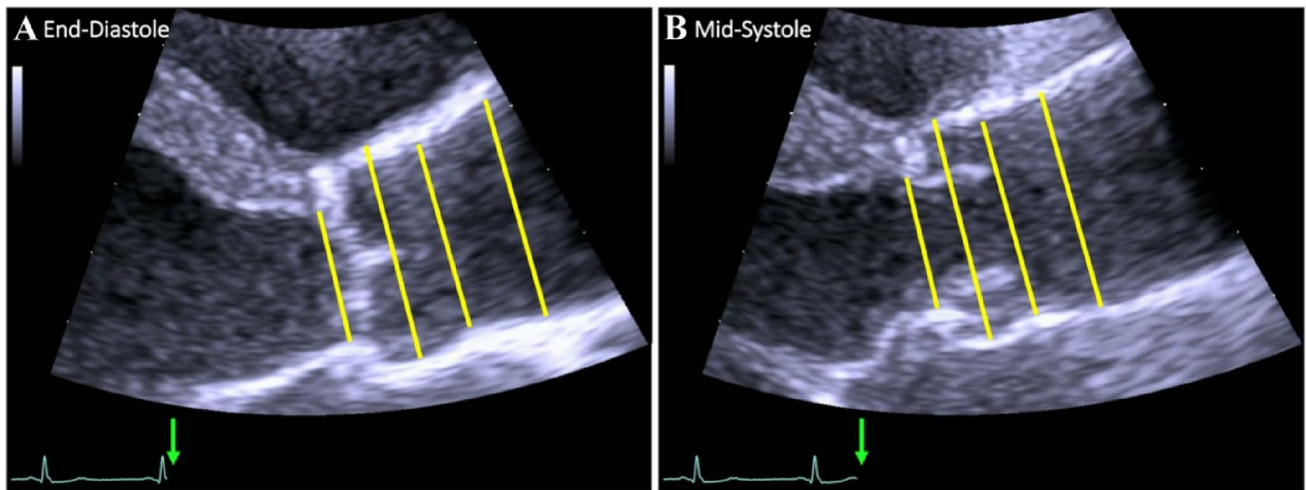


Fig. 2 Echocardiographic measurements of the aortic root in end-diastole (**A**) and mid-systole (**B**). From left to right: (1) aortic annulus, (2) sinus of Valsalva, (3) sinotubular junction, and (4) proximal

ascending aorta within 2 cm range of the STJ. The green arrows mark the measurement time points in relation to the ECG

Reference

1. Wenzel JP, Petersen E, Nikorowitsch J et al (2021) Transthoracic echocardiographic reference values of the aortic root: results from the Hamburg city health study. *Int J Cardiovasc Imaging*. <https://doi.org/10.1007/s10554-021-02354-5>

Publisher's Note Springer Nature remains neutral with regard to jurisdictional claims in published maps and institutional affiliations.