



Multi-segmented maxillary ortho-surgical treatment in Class II patients with maxillary protrusion and open bite: a concise systematic review

Jose David Aguayo Alban^{1,2,3*}, Priscila Andrea Ortega Machado^{1,2,3}, Eduardo Sant'ana^{2,3}, Gastão Moura Neto^{2,3}, Renata Furquim Moura^{2,3}

¹ Dentistry Department, Quito, Ecuador.

² UNORP - University Center North Paulista - Sao Jose do Rio Preto, Sao Paulo, Brazil.

³ UNIPOS - Post graduate and continuing education, Sao Jose do Rio Preto, Sao Paulo, Brazil.

*Corresponding author: Jose David Aguayo Alban.

Quito, Ecuador. E-mail: davidmhx10@hotmail.com

DOI: <https://doi.org/10.54448/mdnt22S203>

Received: 10-08-2021; Revised: 12-10-2021; Accepted: 12-17-2021; Published: 03-28-2022; MedNEXT-id: e22S203

Abstract

Introduction: Anterior open bite is the lack of vertical contact or negative overbite between the anterior teeth of the upper and lower arches when the posterior teeth are in occlusion. Its etiology is multifactorial, including heredity, oral habits, unfavorable growth patterns, and increased lymphatic tissue along with mouth breathing and functional oral matrices. The characteristics of individuals with anterior open bite include excessive gonial, mandibular, and occlusal plane angles, mandibular small body, and ramus increased lower anterior facial height, decreased upper anterior facial height, retrusive jaw, Class II tendency, divergent cephalometric planes, lingual position, and inadequate lip seal. **Objective:** To carry out a concise systematic review of multi-segmented maxillary ortho-surgical treatment in class II patients with maxillary protrusion and open bite. **Methods:** Experimental and clinical studies (case reports, retrospective, prospective and randomized) with qualitative and/or quantitative analysis were included, following the rules of the systematic review-PRISMA. A total of 289 articles were initially found and, after selection, 17 articles were used to compose this study. **Results and conclusion:** Significant improvement in anterior occlusion can be expected in most patients when maxillary or mandibular surgery is used for Class II open bite correction. However, there will be individual patients in whom there will be considerable post-treatment changes in the anteroposterior and vertical dimensions. Although individual morphology needs to be taken into account, it appears that both short-term and long-term stability are likely to be greater after Le Fort I surgery compared to bilateral sagittal split osteotomy.

Keywords: Open bite. Maxillary protrusion. Malocclusion. Class II malocclusion. Orthodontics. Surgery.

Introduction

Anterior open bite (AOB) is the lack of vertical contact or negative overbite between the anterior teeth of the superior and inferior arches when the posterior teeth are in occlusion [1,2]. The AOB is an easily recognized malocclusion and presents only aesthetic and functional problems [2]. Its etiology is multifactorial, including heredity, oral habits, unfavorable growth patterns, and increased lymphatic tissue along with mouth breathing and functional oral matrices. It can occur in Class I, Class II, or Class III malocclusions [3].

Non-nutritive sucking habits can cause anterior open bite, however, not all patients develop malocclusion [2,3]. Thus, a deleterious habit can cause a malocclusion, as long as there is a direct interrelation of three factors: duration, frequency, and intensity [3]. There are studies related to the prevalence of anterior open bite, for example, Castro et al. [4] observed that a total of 24.44% of the patients in their sample had an anterior open bite.

Other authors found a prevalence of anterior open bite in the early mixed dentition of 17.0% [5]. Tibolla et al. [6], found a prevalence of 24.4% in mixed dentition. In the study by Lentini-Oliveira et al. [7], the prevalence ranged from 17.0% to 18.0% of children in mixed dentition, but when associated with sucking habits, it increased to 36.3%. However, in the sample by Shalish et al. [8], 6.7% had an anterior open bite, in the mixed

dentition phase.

The characteristics of individuals with anterior open bite include excessive gonial, mandibular, and occlusal plane angles, small mandibular body, and ramus increased lower anterior facial height, decreased upper anterior facial height, retrusive jaw, Class II tendency, divergent cephalometric planes, lingual position and inadequate lip seal [9,10]. Thus, several treatments have been proposed to correct malocclusion, but interventions are not supported by strong scientific evidence. Furthermore, some studies have reported high relapse rates [11-13].

In mixed and permanent dentures, it can be stated that AOB tends to self-correction [14]. This fact occurs due to the individual's development and growth, providing a physiological decrease in adenoids [9]. This fact, together with the abandonment of harmful habits that are so present in early childhood, will lead to self-correction of malocclusion [7]. AOB can be treated in deciduous and mixed dentition, but it is also possible to treat adult patients, but with greater difficulty, especially in maintaining stability [7].

In this context, the treatment of open bite involves preventive treatments, eliminating harmful habits, correcting the posture of soft tissues through the use of palatal grids or orthopedic appliances, passing through corrective mechanics, extractions, elastics, alignment, and leveling headgear, and orthognathic surgery [1].

The literature is controversial concerning definitions, etiology, and forms of treatment [1-4]. The lack of a consensus on the etiological factors was probably what led to the diversification of AOB treatment plans, explaining the high number of recurrences due to instability [2,3]. In this sense, if the etiology is of skeletal origin, the greater the difficulty of correction and the greater the difficulty in maintaining stability. This stability would be achieved if the professional knew which etiological factor would be leading to the development of AOB [5].

Tongue positioning is generally neglected by dentists, however, it is an important factor to be considered, as lingual posture is one of the most important factors that allow the development of AOB [1]. To achieve stability, there must be good occlusion after performing the open bite correction treatment, so the orthodontist should aim for excellent occlusion, with simultaneous bilateral contacts, in total harmony with the centric relationship, with the presence of disocclusion of posterior teeth, when in excursive movements of the mandible [1].

Molar intrusion is undoubtedly one of the most difficult movements in orthodontic practice. Often the use of conventional appliances for molar intrusion faces

some side effects, such as the extrusion of adjacent teeth, in addition to a long time to perform the intrusion procedure [6-8]. A Modified Transpalatine Bar with Nance Button of 04 helicoids was developed to control the extrusion of molars, and that the average time for tooth movement is 1.5 years [6]. The molar is the tooth that most contributes to the vertical increase of the face, so any device that hinders or prevents its full eruption will contribute to improving the growth of the vertical cementation of the face, reducing the risk of open bite [7].

The AOB should be treated as early as possible, however, the treatment becomes necessary when observed in mixed dentition, this need is necessary to avoid major changes in the stomatognathic structure, and also, because the later the interception of the problem, the more difficult the self-correction will be. The prognosis will be better with alveolar open bites, and the compensatory treatment will not always be enough to obtain a satisfactory final result [12-14].

Therefore, the present study performed a concise systematic review of the multi-segmented ortho-surgical treatment of the jaw in class II patients with maxillary protrusion and open bite.

Methods

Study Design

The present study was followed by a systematic literature review model, according to the PRISMA rules. Access available at: <http://www.prisma-statement.org/>

Data sources and research strategy

The search strategies for this review were based on the descriptors: "Open bite. Maxillary protrusion. Malocclusion. Class II malocclusion. Orthodontics. Surgery". The research was carried out from August 2021 to September 2021 and developed based on Google Scholar, Scopus, PubMed, Scielo, and Cochrane Library.

Study quality and risk of bias

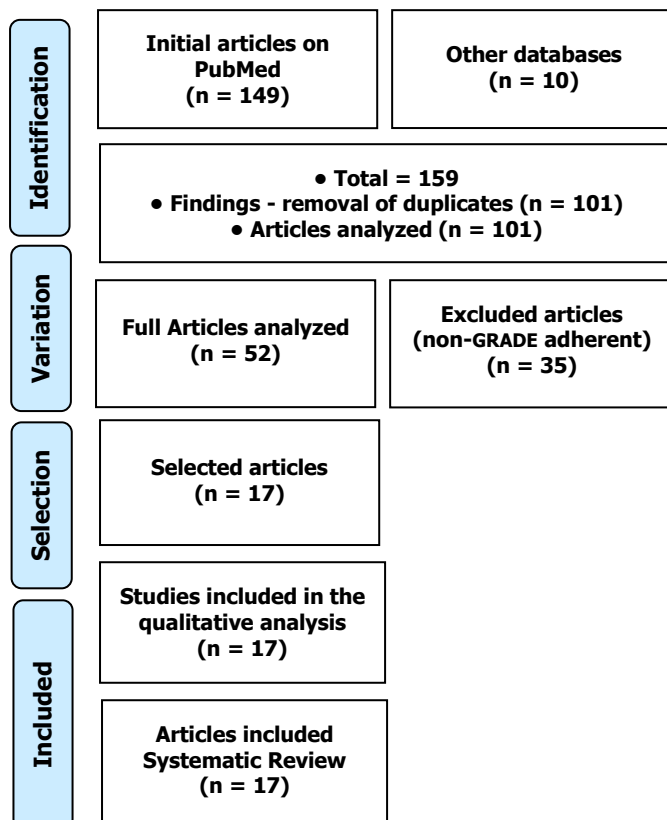
The quality of the studies was based on the GRADE instrument, with randomized controlled clinical studies, prospective controlled clinical studies, and studies of systematic review and meta-analysis listed as the studies with the greatest scientific evidence. The risk of bias was analyzed according to the Cochrane instrument.

Results and Discussion

A total of 159 articles was found involving class II

malocclusion and orthodontics. Initially, the existing title and duplications were excluded according to the interest described in this work. After this process, the abstracts were evaluated and a new exclusion was performed. A total of 52 articles were fully evaluated and 17 were included and discussed in this study (**Figure 1**).

Figure 1. The selection process of scientific articles.



Some authors define the AOB as the deviation in the vertical relationship between the maxilla and the mandible, others define it as the absence of negative overlap between the incisors of the upper incisors and the incisors of the lower incisors, however, the AOB can still be defined as the absence of contact between the incisors. of anterior teeth in centric relation [1-3]. The deleterious habits are the main etiological factors, and the etiology is multifactorial, but it can also be related to the lack of alveolar bone growth in the anterior region of the mandible or three other factors such as excessive posterior alveolar growth, shortening of the mandibular ramus, as well as increased mandibular angle [4].

As for the treatment, there is still no consensus on the ideal treatment and there is a wide range of options for performing AOB closure. However, the use of lingual spur glued Nogueira can be highlighted, on the palatal surface of the upper and lower incisors, to remove the habit of digital sucking and prevent interference of the tongue in the act of phonation and swallowing and installation of the expander Hyrax [5].

Thus, treatment can be carried out through preventive, interceptive, corrective, or even surgical treatments. Differentiated bonding of brackets on anterior teeth is also a very valuable resource for the treatment of AOB. With the advent of mini-implants, it becomes easier to carry out treatments, especially in the most severe cases, as they behave like skeletal anchorages [6-8].

The treatment can still be carried out through extractions. The orthodontist must analyze which extracted teeth will bring the best benefit to the case, as extractions are allowed in all teeth, especially in premolars, first molars, even second molars [9]. AOB closure occurs through the molar intrusion of anterior teeth extrusion, but intrusive movement behaves more stably. The etiology of anterior open bite is multifactorial and may have environmental and hereditary factors as its origin [10].

In this context, an observational and cross-sectional study compared linear and angular measurements of the skull base among individuals with skeletal open bite and different sagittal skeletal relationships, with 101 lateral radiographs of young patients with skeletal open bite. Skull base angles were significantly smaller (approximately 3° to 5°) in the Class III skeletal open bite group (BaSN = 127.97° ± 5.86°, ArSN = 120.19° ± 6.12°) when compared to the other groups. BaSN angle, Class I versus Class III (p<0.001), and Class II versus Class III (p<0.001). ArSN angle, Class I versus Class III (p = 0.005), and Class II versus Class III (p = 0.026). Multiple linear regressions showed that gender had a significant influence on both dimensions of the skull base, with men presenting higher values than women [15].

Also, a retrospective observational study compared 57 patient charts on treatment outcomes for anterior occlusion and vertical skeletal stability after maxillary or mandibular surgery to correct Class II malocclusion with a mild to moderate open bite. After surgery, 87% of Le Fort I patients and 63% of patients with bilateral sagittal split osteotomy had a positive overbite, and at the 6-month follow-up, the percentages were 90% and 74%, respectively. Three years after surgery, 74% of patients with Le Fort I and 42% of patients with bilateral sagittal split osteotomy had a positive overbite. Anterior facial height decreased in the Le Fort I subsample and increased in the bilateral sagittal split osteotomy subsample, and the mandibular plane angle decreased in both. The Le Fort I subsample generally remained stable, while clinically significant relapse of the mandibular plane angle (≥2°) occurred in 80% of the bilateral sagittal split osteotomy subsample [16].

Finally, a study quantified the three-dimensional condylar displacement due to bimaxillary surgery for

open bite correction in patients with class II and class III skeletal malocclusion. Pre-surgical (T1) and post-surgical (T2) cone-beam computed tomography scans were performed in 16 patients with skeletal class II (mean age 22.3 ± 9.47 years) and 14 patients with skeletal class III (age mean of 25.6 ± 6.27 years). Class II patients had significantly greater amounts of lateral and lower translation than class III patients. The magnitudes of condylar translational displacements were small for both groups. Skeletal class III patients had a predominantly medial and superior condylar translation. Skeletal class II patients had a higher counterclockwise condylar pitch than class III patients. Two-jaw surgery for open bite correction led to different directions and amounts of condylar rotational displacement in patients with skeletal class II malocclusion compared to class III malocclusion, with greater rotational than translational displacements [17].

Conclusion

Significant improvement in anterior occlusion can be expected in most patients when maxillary or mandibular surgery is used for Class II open bite correction. However, there will be individual patients in whom there will be considerable post-treatment changes in the anteroposterior and vertical dimensions. Although individual morphology needs to be taken into account, it appears that both short-term and long-term stability are likely to be greater after Le Fort I surgery compared to bilateral sagittal split osteotomy.

Acknowledgement

Not applicable.

Funding

Not applicable.

Data sharing statement

No additional data are available.

Conflict of interest

The authors declare no conflict of interest.

Similarity check

It was applied by Ithenticate@.

About the License

© The authors (s) 2022. The text of this article is open access and licensed under a Creative Commons Attribution 4.0 International License.

References

1. Cacucci L, Ricci B, Moretti M, Gasparini G, Pelo S, Grippaudo C. Surgical Orthodontic Treatment of a Patient Affected by Type 1 Myotonic Dystrophy (Steinert Syndrome). *Case Rep Dent.* 2017;2017:7957961.
2. Kassir C, Saade A. Nonsurgical Treatment of a Severe Skeletal Anterior Open Bite. *J Clin Orthod.* 2017 Feb;51(2):103-112.
3. Franzotti Sant'Anna E, Carneiro da Cunha A, Paludo Brunetto D, Franzotti Sant'Anna C. Camouflage of a high-angle skeletal Class II open-bite malocclusion in an adult after mini-implant failure during treatment. *Am J Orthod Dentofacial Orthop.* 2017 Mar;151(3):583-597.
4. Castro IO, valladares-Neto J, Estrela C. Prevalência de Malocclusão em Indivíduos que Solicitaram Tratamento Ortodôntico na Rede Pública de Saúde. *Rev Odontol Bras Central* 2010;19(51).
5. Góis EG, Vale MP, Paiva SM, Abreu MH, Serra-Negra JM, Pordeus IA. Incidence of malocclusion between primary and mixed dentitions among Brazilian children, A 5-year longitudinal study. *Angle Orthod.* 2012; 82:495-500.
6. Tibolla C, Rigo L, Nojima LI, Estacia A, Frizzo EG, Lodi L. Association between anterior open bite and pacifier sucking habit in schoolchildren in a city of southern Brazil. *Dental Press J Orthod.* 2012 Nov-Dec; 17(6):89-96.
7. Lentini-Oliveira DA, Carvalho FR, Rodrigues CG, YE Q, Hu R, Minami-Sugaya H, Carvalho LBC, Prado LBF, Prado GF. Orthodontic and orthopaedic treatment for anterior open bite in children. *Cochrane Database Syst Rev.* 2007 Apr 18;(2):CD005515.
8. Shalish M, Gal A, Brin I, Zini A, Ben-Bassat Y. Prevalence of dental features that indicate a need for early orthodontic treatment. *Eur. J. Orthod.* 35 2013; 454-459.
9. Feres MFN, Abreu LG, Insabralde NM, Almeida MR, Flores-Mir C. Effectiveness of the open bite treatment in growing children and adolescents. A systematic review. *Eur. J. Orthod.* 2015, 1-14.
10. Albogha, M.H.; Takahashi, I.; Sawan, M.N. Early treatment of anterior open bite: Comparison of the vertical and horizontal morphological changes induced by magnetic bite-blocks and adjusted rapid molar intruders. *Korean J Orthod* 2015; 45(1):38-46.
11. Van Dyck C, Dekeyser A, Vantricht E, Manders E, Goeleven A, Fieuws S, Willems G. The effect of orofacial myofunctional treatment in children

with anterior open bite and tongue dysfunction: a pilot study. *Eur. J. Orthod* 2015; 1–8.

12. Fialho MPN, Pinzan-Vercelino CRM, Nogueira RP, Gurgel JA. Relationship between facial morphology, anterior open bite and nonnutritive sucking habits during the primary dentition stage. *Dental Press J Orthod*. 2014 May-June;19(3):108-13.
13. Dimberg L, Lennartsson B, Söderfeldt B, Bondemark L. Malocclusions in children at 3 and 7 years of age: a longitudinal study. *Eur. J. Orthod*. 35 2013; 131–137.
14. Celli C, Santos-Pinto PR, Capelozza Filho L, Souza YS, Santos-Pinto G. Correção da mordida aberta anterior com a utilização do aparelho expansor removível com concha suspensa Celli-C. *Rev Clín Ortod Dental Press*. 2013 jun-jul;12(3):38-50.
15. Flores-Ysla A, Arriola-Guillén LE, Rodríguez-Cárdenas YA, Ruíz-Mora GA, Aliaga-Del Castillo A, Janson G. Skeletal open bite cranial base characteristics in young Latin-American individuals with class I, II and III malocclusions: An observational study. *Int Orthod*. 2020 Jun;18(2):237-245. doi: 10.1016/j.ortho.2020.01.002. Epub 2020 Feb 6. PMID: 32037207.
16. Torgersbråten N, Stenvik A, Espeland L. A comparison of Class II open bite correction by maxillary or mandibular surgery. *Am J Orthod Dentofacial Orthop*. 2020 May;157(5):631-640. doi: 10.1016/j.ajodo.2019.05.018. PMID: 32354436.
17. Zupnik JT, Ioshida M, Yatabe M, Ruellas ACO, Gomes LR, Aronovich S, Benavides E, Edwards SP, Paniagua B, Cevidanes LHS. Three-dimensional analysis of condylar changes in surgical correction for open bite patients with skeletal class II and class III malocclusions. *Int J Oral Maxillofac Surg*. 2019 Jun;48(6):739-745. doi: 10.1016/j.ijom.2019.01.004. Epub 2019 Feb 1. PMID: 30712988; PMCID: PMC6510631.