



# Ortho-surgical treatment of maxillary in Class III patients with severe mandibular protrusion and middle line deviation: a systematic review

Lizeth Nathaly Viana Solis<sup>1,2,3\*</sup>, Alexandre Benetton<sup>2,3</sup>, Renata Furquim Moura<sup>2,3</sup>, Gastão Moura Neto<sup>2,3</sup>

<sup>1</sup> Dentistry Department, Quito, Ecuador.

<sup>2</sup> UNORP - University Center North Paulista - Sao Jose do Rio Preto, Sao Paulo, Brazil.

<sup>3</sup> UNIPOS - Post graduate and continuing education, Sao Jose do Rio Preto, Sao Paulo, Brazil.

\*Corresponding author: Lizeth Nathaly Viana Solis.

Quito, Ecuador. E-mail: lizethviana89.lv@hotmail.com

DOI: <https://doi.org/10.54448/mdnt22S202>

Received: 10-12-2021; Revised: 12-13-2021; Accepted: 12-19-2021; Published: 03-28-2022; MedNEXT-id: e22S202

## Abstract

**Introduction:** In Brazil, malocclusion is found in ages between 7 and 15 years with a prevalence of 6%. In this scenario, Class III malocclusion affects between 5% and 15% of the entire Brazilian population. Orthodontics stands out due to its strong aesthetic compromise and unfavorable treatment prognosis, especially when there is a hereditary component. It is suggested that most cases of Class III malocclusion have maxillary retrusion or hypoplasia, which may or may not be associated with mandibular prognathism. Thus, several treatment modalities are proposed for the correction of Class III malocclusion. **Objective:** To explore the literary findings of the importance of knowing advances in orthodontics for the treatment of class III malocclusion.

**Methods:** Experimental and clinical studies (case reports, retrospective, prospective and randomized) with qualitative and/or quantitative analysis were included, following the rules of the systematic review-PRISMA. 289 articles were initially found and, after selection, 54 articles were used to compose this study.

**Results and conclusion:** According to the literary findings, the treatment of Class III should be fundamentally based on the diagnosis so that the treatment can be installed in order to correct the compromised structures instead of being compensated in places not affected by this malocclusion. In other words, the degree of involvement of the maxilla and mandible must be evaluated so that the treatment is directed to that bone base and really achieves its goals and impacts of facial improvement. Redirection of growth in Class III cases is indicated as soon as the anomaly is diagnosed, as the displacement processes that occur in the middle face can only be affected with treatment while the growth zones are able to respond

to the biomechanical stimulus. Therefore, the younger the Class III patient is treated, the better the facial correction effects.

**Keywords:** Malocclusion. Class III malocclusion. Orthodontics. Treatments.

## Introduction

In Brazil, malocclusion is found in ages between 7 and 15 years with a prevalence of 6% [1]. The greatest number of traumatic injuries in primary teeth occur between one and a half and three years of age and in permanent teeth between 7 and 10 years old, with boys being more prone to dental trauma than girls. In this scenario, Class III malocclusion affects between 5% and 15% of the entire Brazilian population [1].

Orthodontics stands out due to its strong aesthetic compromise and unfavorable treatment prognosis, especially when there is a hereditary component. It is suggested that most cases of Class III malocclusion have maxillary retrusion or hypoplasia, which may or may not be associated with mandibular prognathism [2]. Treatment of Class III malocclusion before late mixed dentition seems to induce more favorable craniofacial changes, with a significant increase in maxillary sagittal growth. However, a mandibular restriction effect can be achieved in later treatment [2]. Some studies report that disarticulation of circumaxillary sutures enhances orthopedic effects [3,4], however, the use of a face mask at a young age, even without palatal expansion, is effective for the correction of skeletal Class III.

Therefore, expansion should be indicated based on the clinical characteristics of the case. The harmonic functional aspect of the patient is important for the

stability of the results. The dental and skeletal modifications of Class III correction produce an improvement in the relationship between teeth, bone bases, and soft tissue [5].

Thus, several treatment modalities are proposed for the correction of Class III malocclusion [6]. Approaches include the use of a protraction face mask with rapid maxillary expansion, face mask without maxillary expansion, face mask with alternating expansion with maxillary constriction, face mask associated with mini-implants on the zygomatic pillar, use of mini-implants orthodontics in the lower arch as an anchorage for maxillary traction using a removable upper appliance, use of mini-implants in the retromolar region, use of mini-implants in the buccal region of the lower arch, posterior region, use of a chin cup, reverse chin cup, functional Fränkel regulator use of acrylic grid and stop, use of removable mandibular retractor, use of reverse twin block, and use of tandem traction bow appliance [7-11].

In this scenario, it is extremely important that the diagnosis is made as soon as possible since skeletal discrepancies are quite difficult to correct due to the complexity of the treatment and the lack of predictability in the patients' growth pattern [12,13]. It is well documented in the literature that, in patients with Class III malocclusions still with growth potential, the most used treatment protocol is the protraction face mask associated with rapid maxillary expansion. Several studies that seek to show other types of treatment use this therapeutic modality as a control group [14-16].

Therefore, this study aimed to explore the literary findings of the importance of knowing the advances in orthodontics for the treatment of class III malocclusion.

## Methods

### Study Design

The present study was followed by a systematic literature review model, according to the PRISMA rules. Access available at: <http://www.prisma-statement.org/>

### Data sources and research strategy

The search strategies for this review were based on the descriptors: "Malocclusion. Class III malocclusion. Orthodontics. Treatments". The research was carried out from August 2021 to September 2021 and developed based on Google Scholar, Scopus, PubMed, Scielo, and Cochrane Library.

### Study quality and risk of bias

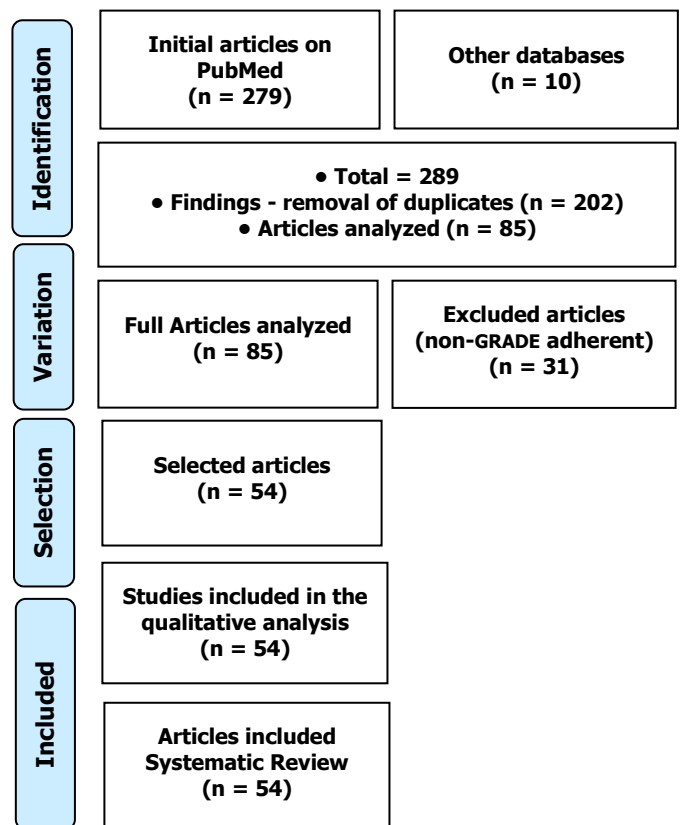
The quality of the studies was based on the GRADE instrument, with randomized controlled clinical studies,

prospective controlled clinical studies, and studies of systematic review and meta-analysis listed as the studies with the greatest scientific evidence. The risk of bias was analyzed according to the Cochrane instrument.

## Results

O total of 289 articles was found involving class III malocclusion and orthodontics. Initially, the existing title and duplications were excluded according to the interest described in this work. After this process, the abstracts were evaluated and a new exclusion was performed. A total of 85 articles were fully evaluated and 54 were included and discussed in this study (Figure 1).

**Figure 1.** The selection process of scientific articles.



The two most common dilemmas surrounding the treatment of Class III are the time of treatment and the type of appliance [18]. Various devices have been used to correct a Class III skeletal discrepancy, but little evidence is available about their long-term effectiveness. Likewise, early treatment of Class III malocclusion has been practiced with growing interest. However, there is no solid evidence of long-term benefits [18,19].

Thus, a meta-analysis study evaluated the effectiveness of orthodontic/orthopedic methods used in the early treatment of Class III malocclusion in the short and long term. Fifteen studies, 9 RCTs, and 6 CCTs were

included in this review. In the RCT group, only 3 of the 9 studies were assessed at low risk of bias, and the others were at high or unclear risk of bias. All 6 CCT studies were classified as high risk of bias. Three randomized controlled trials involving 141 participants analyzed the comparison between a protraction mask and untreated control. Results for reverse overjet (mean difference, 2.5 mm; 95% CI, 1.21-3.79;  $p=0.0001$ ) and ANB angle (mean difference, 3.90°; 95% CI, 3, 54-4.25;  $p<0.0001$ ) were statistically significant favoring the face mask group. All CCTs demonstrated a statistically significant benefit in favor of the use of each device. However, studies had a high risk of bias. Therefore, there is a moderate amount of evidence to show that early treatment with a face mask results in positive improvement for skeletal and dental effects in the short term. However, there was a lack of evidence on long-term benefits [20].

Also, Mandall et al. [17] tested the Class III treatment with the face mask associated with rapid maxillary expansion and concluded to be effective both skeletally and dentally. The only difference in the respective studies was the follow-up time after obtaining a Class I molar relationship, which ranged from 15 months to 36 months. Maxillary expansion prior to treatment with a face mask is used in most cases because it has the benefits of correcting the posterior crossbite when present, increasing the arch length, causing the bite to open, generating a loosening/activation of the circumaxillary sutures, and generate an initiation of movement of the maxillary complex downwards and forwards [21-25]. However, Vaughn et al. [26], in a randomized clinical trial, testing maxillary protraction in a group with expansion and in another without previous maxillary expansion concluded that the changes produced to the dentofacial complex were equivalent to an improvement in malocclusion Class III, and there is no change in the total treatment time. Maxillary expansion is only necessary in cases of posterior crossbite or space deficiency [27-38]. These data are also according to the systematic review conducted by Kim et al. [39].

In contrast to the use or not of maxillary expansion prior to treatment for maxillary protraction, Liu et al. [36] tested the expansion plus constriction protocol and observed that there were some statistically significant differences, such as better anterior movement of the maxilla and the rotation of the mandibular and palatal plane in the expansion/constriction group, but these changes did not demonstrate any clinical relevance, as they were less than 1 mm and 1°, respectively.

Chippers have been used to control mandibular protrusion in growing patients for nearly a century [40]. However, a deeper investigation in the literature

revealed controversies and contradictions regarding the methodology of use, such as the appropriate age to start treatment and magnitude of force used. The clinical effectiveness is widely debated by authors who use different protocols, obtaining different results [41-44].

Abdelnaby and Nassar [30] carried out a study in patients aged between nine and ten years with a chin cup with occipital pull using two magnitudes of force. The authors obtained as results a significant decrease in the SNB angle both by the clockwise rotation of the mandible and by the increase in the anterior facial height in the two treated groups when compared to the untreated one, data that is also in agreement with the systematic review elaborated by Chatzoudi et al. [45]. The results achieved with the use of this apparatus significantly improved the maxillomandibular relationship, however, with few skeletal effects, and the difference in force magnitude generated the same effects.

Faced with so many devices already used and tested for the treatment of Class III malocclusion, due to the fact that they are not very aesthetic, several authors seek to develop new devices that can facilitate their use and, consequently, the acceptance of patients. Showkatbakhsh et al. [29] developed a new device called a reverse chin strap, with the aim of making a maxillary protraction. In this randomized clinical trial, the age range of patients ranged from seven to ten years and aimed to compare its effectiveness with the face mask. In both treatments, an anterior movement of the maxilla was achieved, as well as a buccalization of the maxillary anterior teeth and a lingualization of the mandibular incisors. The authors mention that, as the face mask is bulky in size, children feel discouraged from using it, especially at school, due to shame and the discomfort it generates. Thus, they suggest that the use of the reverse chin cup, as it is an aesthetically more acceptable method, may be a better option for maxillary protraction.

The use of the lingual grid or the removable upper acrylic stop generates a pressure of the tongue on the bulkhead, causing this force to be transmitted to the maxilla, causing its movement to the anterior [46,47]. When comparing its effects with that of a face mask, the results are similar in moving the jaw forward. One advantage is that the lingual grid does not cause some unfavorable effects on the mandible (backward and downward rotation) for patients with a vertical growth pattern [47,48].

Also, orthopedic treatments with skeletal anchorage are becoming a new paradigm for the early treatment of Class III malocclusion [49-51]. Several studies cite the use of extraoral apparatus associated with this type of anchorage [52,53]. The use of mini-

implants installed bilaterally on the zygomatic pillar associated with a face mask or installed between the roots of the canines and lower first premolars by buccal associated with a removable upper appliance 28 with Class III hooks and elastics can be used to traction the jaw forward. Such treatment modalities, when compared with the use of a face mask, present similar results in the correction of maxillary deficiency. The fact of using devices of smaller size, causing a smaller aesthetic imbalance, can generate a better acceptance of the patient, making the treatment can be started earlier [54].

## Conclusion

According to the literary findings, the treatment of Class III must be fundamentally based on the diagnosis so that the treatment can be installed in order to correct the compromised structures instead of being compensated in places not affected by this malocclusion. In other words, the degree of involvement of the maxilla and mandible must be evaluated so that the treatment is directed to that bone base and really achieves its goals and impacts of facial improvement. Redirection of growth in Class III cases is indicated as soon as the anomaly is diagnosed, as the displacement processes that occur in the middle face can only be affected with treatment while the growth zones are able to respond to the biomechanical stimulus. Therefore, the younger the Class III patient is treated, the better the facial correction effects.

## Acknowledgement

Not applicable.

## Funding

Not applicable.

## Data sharing statement

No additional data are available.

## Conflict of interest

The authors declare no conflict of interest.

## Similarity check

It was applied by Ithenticate@.

## About the License

© The authors (s) 2022. The text of this article is open access and licensed under a Creative Commons Attribution 4.0 International License.

## References

1. Doriguêto PVT, Carrada CF, Scalioni FAR, et al. Malocclusion in children and adolescents with Down syndrome: A systematic review and meta-analysis. *Int J Paediatr Dent.* 2019;29(4):524-541. doi:10.1111/ipd.12491.
2. Watkinson S, Harrison JE, Furness S, Worthington HV. Orthodontic treatment for prominent lower front teeth (Class III malocclusion) in children. *Cochrane Database Syst Rev* 2013; (9):CD003451.
3. Seehra J, Fleming PS, Mandall N, Dibiasi AT. A comparison of two different techniques for early correction of Class III malocclusion. *Angle Orthod* 2012;82:96-101.
4. Liu ZP, Li CJ, Hu HK, Chen JW, Li F, Zou SJ. Efficacy of short-term chin cup therapy for mandibular growth retardation in Class III malocclusion. *Angle Orthod* 2011;81:162-8.
5. Kurt H, Alioglu C, Karayazgan B, Tuncer N, Kilicoglu H. The effects of two methods of Class III malocclusion treatment on temporomandibular disorders. *Eur J Orthod* 2011;33:636-41.
6. Saleh M, Hajeer MY, Al-Jundi A. Assessment of pain and discomfort during early orthodontic treatment of skeletal Class III malocclusion using the Removable Mandibular Retractor Appliance. *Eur J Paediatr Dent* 2013;14:119-24.
7. Angle EH. Classification of malocclusion. *Dent. Cosmos.* 1899;41:248-64.
8. Sanborn RT. Differences between the facial skeletal patterns of Class III malocclusion and normal occlusion. *Angle Orthod.* 1955;25:208-22.
9. Guyer EC, Ellis EE, McNamara JA, Behrents RG. Components of Class III malocclusion in juveniles and adolescents. *Angle Orthod.* 1986;56:7-30.
10. Ellis E 3rd, McNamara JA Jr. Components of adult Class III open-bite malocclusion. *Am J Orthod.* 1984;86:277-90.
11. Showkatbakhsh R, Jamilian A, Behnaz M, Ghassemi M, Ghassemi A. The short-term effects of Face mask and Fixed Tongue Appliance on Maxillary Deficiency in Growing Patients – A Randomized Clinical Trial. *Int J Orthod.* 2015;26(1)29-34.
12. Proffit WR. *Contemporary Orthodontics.* 4th ed. St Louis: CV Mosby; 2007.
13. Haynes S. The prevalence of malocclusion in English children aged 11–12 years. *Rep Congr Eur Orthod Soc.* 1970:89-98.



14. Cobourne M. Early treatment for class III malocclusion. *J Orthod.* 2016;43(3):159-160. doi:10.1080/14653125.2016.1215860.
15. Agostino P, Ugolini A, Signori A, Silvestrini-Biavati A, Harrison JE, Riley P. 2014. Orthodontic treatment for posterior crossbites. *Cochrane Database Syst Rev.* 8: CD000979.
16. Mandall N, Cousley R, DiBiase A, Dyer F, Littlewood S, Mattick R, et al. 2016. Early class III protraction facemask treatment reduces the need for orthognathic surgery. A multicentre, two-arm parallel randomised, controlled trial. *J Orthod.* 43: 164–175.
17. Mandall N, DiBiase A, Littlewood S, Nute S, Stivaros N, McDowall R, et al. 2010. Is early class III protraction facemask treatment effective? A multicentre, randomised, controlled trial: 15-month follow-up. *J Orthod.* 37: 149–161.
18. Thiruvengkatachari B, Harrison JE, Worthington HV, O'Brien KD. 2013. Orthodontic treatment for prominent upper front teeth (Class II malocclusion) in children. *Cochrane Database Syst Rev.* 11: CD003452.
19. Irie M, Nakamura S. Orthopedic approach to severe skeletal Class III malocclusion. *Am J Orthod.* 1975;67:377-92.
20. Woon SC, Thiruvengkatachari B. Early orthodontic treatment for Class III malocclusion: A systematic review and meta-analysis. *Am J Orthod Dentofacial Orthop.* 2017;151(1):28-52. doi:10.1016/j.ajodo.2016.07.017].
21. Baik HS, Han HK, Kim DJ, Proffit WR. Cephalometric characteristics of Korean Class III surgical patients and their relationship to plans for surgical treatment. *Int J Adult Orthodon Orthognath Surg.* 2000;15:119-28.
22. Chan GK. Class III malocclusion in Chinese: etiology and treatment. *Am J Orthod.* 1974;65:152–56.
23. De Toffol L, Pavoni C, Baccetti T, Franchi L, Cozza P. Orthopedic Treatment Outcomes in Class III Malocclusion A Systematic Review. *Angle Orthod.* 2008;78:561-73.
24. Turchetta BJ, Fishman LS, Subtelny JD. Facial growth prediction: a comparison of methodologies. *Am J Orthod Dentofacial Orthop.* 2007; 132:439-49.
25. Yoshida I, Yamaguchi N, Mizoguchi I. Prediction of post-treatment outcome after combined treatment with maxillary protraction and chin cup appliances. *Eur J Orthod.* 2006;28:89-96.
26. Vaughn GA, Mason B, Moon HB, Turley PK. The effects of maxillary protraction therapy with or without rapid palatal expansion: A prospective, randomized clinical trial. *Am J Orthod Dentofacial Orthop.* 2005;128:299-309.
27. Ge YS, Liu J, Chen L, Han JL, Guo X. Dentofacial effects of two facemask therapies for maxillary protraction: Miniscrew implants versus rapid maxillary expanders. *Angle Orthod.* 2012;82:1083-91.
28. Jamilian A, Haraji A, Showkatbakhsh R, Valaee N. The Effects of Miniscrew with Class III Traction in Growing Patients with Maxillary Deficiency. *Int Journal Orthod.* 2011;22:25-30.
29. Showkatbakhsh R, Jamilian A, Ghassemi M, Ghassemi A, Taban T, Imani Z. The Effects of facemask and reverse chin cup on maxillary deficient patients. *Journal of Orthod.* 2012;39:95-101.
30. Abdelnaby YL, Nassar EA. Chin cup effects using two different force magnitudes in the management of Class III malocclusions. *Angle Orthod.* 2010;80:957-62.
31. Showkatbakhsh R, Toumarian L, Jamilian A, Sheibaninia A, Mirkarimi M, Taban T. The effects of facemask and tongue plate on maxillary deficiency in growing patients: a randomized clinical trial. *Journal of Orthod.* 2013;40:130-36.
32. Ülgen M, Firatli S. The effects of Fränkel's function regulator on the class III malocclusion. *Am J Orthod Dentofacial Orthop.* 1994;105:561-67.
33. Atalay Z, Tortop T. Dentofacial effects of a modified tandem traction bow appliance. *Eur J Orthod.* 2010;32:655-61.
34. Arman A, Toygar, TU, Abuhijleh, E. Evaluation of maxillary protraction and fixed appliance therapy in Class III patients. *Eur J Orthod.* 2006;28:383-92.
35. Mandal NA, Cousley R, DiBiase A, Dyer F, Littlewood S, Mattick R. et al. Is early class III protraction facemask treatment effective? A multicentre, randomized, controlled trial: 3-year follow-up. *Journal of Orthod.* 2012;39:176-85.
36. Liu W, Zhou Y, Wang X, Liu D, Zhou S. Effect of maxillary protraction with alternating rapid palatal expansion and constriction vs expansion alone in maxillary retrusive patients: A single-center, randomized controlled trial. *Am J Orthod Dentofacial Orthop.* 2015;148:641-51.
37. Showkatbakhsh R, Jamilian A, Taban T, Golrokh M. The effects of Face mask and Tongue Appliance on Maxillary Deficiency in growing patients: A randomized clinical trial. *Progress in orthodontics.* 2012;13:266-72.
38. Seehra J, Fleming PS, Mandall N, DiBiase AT. A comparison of two different techniques for early

- correction of Class III malocclusion. *Angle Orthod.* 2012;82:96–101.
39. Kim JH, Viana MAG, Graber TM, Omerza FF, BeGole EA. The effectiveness of protraction facemask therapy: A meta-analysis. *Am J Orthod Dentofac Orthop.* 1999;115:675-85.
  40. Watkinson S, Harrison JE, Furness S, Worthington HV. Orthodontic treatment for prominent lower front teeth (Class III malocclusion) in children. *Cochrane Database of Systematic Reviews* 2013, Issue 9.
  41. Cordasco G, Matarese G, Rustico L, Fastuca S, Caprioglio A, Lindauer SJ et al. Efficacy of orthopedic treatment with protraction facemask on skeletal Class III malocclusion: a systematic review and meta-analysis. *Orthod Craniofac Res.* 2014;17:133-43.
  42. Foersch M, Jacobs C, Wriedt S, Hechtner M, Wehrbein H. Effectiveness of maxillary protraction using facemask with or without maxillary expansion: a systematic review and meta-analysis. *Clin Oral Invest.* 2015;19:1181-92.
  43. Morales-Fernández M, Iglesias-Linares A, Yañez-Vico RM, MendozaMendoza A, Solano-Reina E. Bone- and dentoalveolar-anchored dentofacial orthopedics for Class III malocclusion: New approaches, similar objectives? A systematic review. *Angle Orthod.* 2013;83:540-52.
  44. Ye C, Zhihe Z, Zhao Q, Ye J. Treatment Effects of Distal Movement of Lower Arch With Miniscrews in the Retromolar Area Compared With Miniscrews in the Posterior Area of the Maxillary. *J Craniofac Surg.* 2013;24:1974-79.
  45. Chatzoudi MI, Ioannidou-Marathiotou I, Papadopoulos MA. Clinical effectiveness of chin cup treatment for the management of Class III malocclusion in pre-pubertal patients: a systematic review and meta-analysis. *Progress in Orthodontics.* 2014;15:62.
  46. Yang X, Li C, Bai D, Su N, Chen T, Xu Y, et al. Treatment effectiveness of Fränkel function regulator on the Class III malocclusion: A systematic review and meta-analysis. *Am J Orthod Dentofacial Orthop.* 2014;146:143-54.
  47. Saleh M, Hajeer Y, Al-Jundi A. Short-term soft- and hard-tissue changes following Class III treatment using a removable mandibular retractor: a randomized controlled trial. *Orthod Craniofac Res.* 2013;16:75-86.
  48. Keim RG, Gottlieb EL, Nelson AH, Vogels DS 3rd. 2008 JCO study of orthodontic diagnosis and treatment procedures. Part 3: more breakdowns of selected variables. *J Clin Orthod.* 2009;43:22-33.
  49. McNamara JA JR, Brudon WL. *Orthodontics and dentofacial orthopedics.* Ann Arbor, Mich: Needham Press; 2001.
  50. Turley PK. Orthopedic correction of Class III malocclusion with palatal expansion and custom protraction headgear. *J Clin Orthod.* 1988;22:314-25.
  51. Tuncer BB, Kaygisiz E, Tuncer C, Yuksel S. Pharyngeal airway dimensions after chin cup treatment in Class III malocclusion subjects. *J Oral Rehab.* 2009;36:110-17.
  52. Liu C, Hou M, Liang L, Huang X, Zhang T, Zhang H, et al. Sutural distraction osteogenesis (SDO) versus osteotomy distraction osteogenesis (ODO) for midfacial advancement: A new technique and primary clinical report. *J Craniofac Surg.* 2005;16:537-48.
  53. Kircelli BH, Pektas ZO. Midfacial protraction with skeletally anchored face mask therapy: a novel approach and preliminary results. *Am J Orthod Dentofacial Orthop.* 2008;133:440-49.
  54. De Clerck HJ, Cornelis MA, Cevidanes LH, Heymann GC, Tulloch CJ. Orthopedic traction of the maxilla with mini- plates: a new perspective for treatment of midface deficiency. *J Oral Maxillofac Surg.* 2009;67:2123-29.

