



Investigation on the bisphosphonate and osseointegrated implants: a concise systematic review

Luis Alonso Romero Urdiales^{1,3,4*}, Daniel Alfonso Yaguana Galarraga^{2,3,4}, Régis Manzini^{3,4}

¹ ECUADENT CLINIC, Quito, Ecuador.

² ECUDENT CLINIC, Lorenzo de Garaicoa s4-06 y Humberto Mora, Quito, Ecuador.

³ UNORP - University Center North Paulista - Sao Jose do Rio Preto, Sao Paulo, Brazil.

⁴ UNIPOS - Post graduate and continuing education, Sao Jose do Rio Preto, Sao Paulo, Brazil.

*Corresponding author: Luis Alonso Romero Urdiales.

ECUADENT CLINIC, Quito, Ecuador.

E-mail: lucho121296@gmail.com

DOI: <https://doi.org/10.54448/mdnt22203>

Received: 11-09-2021; Revised: 02-11-2022; Accepted: 02-14-2022; Published: 03-30-2022; MedNEXT-id: e22203

Abstract

The most common bone disorder found by implant dentists is osteoporosis, which is a systemic skeletal disorder associated with aging, which is characterized by loss of bone mass, making bones fragile and more susceptible to fractures. The World Health Organisation has defined osteoporosis as a bone mineral density level greater than 2.5 standard deviations below the mean of young normal women. After 60 years of age, a third of the population has this disorder, it occurs twice as often in women than in men. It is estimated that 1.3 million fractures and 133,000 all hip fractures occur every year as a result of osteoporosis. The aim of this study was to discuss aspects of the pharmacological action of Bisphosphonates (BP) and their influence on the bone tissue when associated with treatment with dental implants. There are several types of treatments that prevent or prevent the progression of osteoporosis. So, BP, such as alendronate, are inhibitors of bone resorption. Act as controlling the development of osteoporosis by increasing the process of bone density and decreasing its reabsorption, often acting as supporting the process of osseointegration of dental implants.

Keywords: Bisphosphonate. Osseointegration. Dental implant. Osteoporosis. Osteonecrosis. Complications.

Introduction

The literature has shown that several patients with a history of bisphosphonate treatment appear to be at risk for medication-related osteonecrosis of the jaw (MRONJ) osteonecrosis of the jaw [1]. Thus, general and specialist dentists should exercise caution when

planning dental implant therapy in patients with a history of bisphosphonate drug therapy. It is important to emphasize that all patients with a history of bisphosphonates are declared in the informed consent obtained before implant placement [2,3].

In this context, it is estimated that the number of dental implants used in the United States increased by more than 10 times from 1983 to 2002 and another five times from 2000 to 2005 [4,5]. More than one million dental implants are performed each year [6]. The high need and use of treatments related to implants result from the combined effect of several factors and the most important are the aging population with longer life expectancy, and age-related dental loss [6].

In this sense, one of the major causes of osteopenia in women over 60 years of age is an estrogen deficiency. This deficiency associated with aging causes an osteoporotic picture. A hormone replacement is necessary for an adequate treatment of the symptoms of menopause and to prevent possible osteoporosis [5,6]. Some drugs help in the treatment of postmenopausal osteoporosis, they are calcitonin, bisphosphonates (BP), and the selective modulators of estrogen receptors [6]. Thus, BP has been the best drug associated with significant improvement in the quality of life of patients with bone diseases such as Paget's disease, bone metastases, osteogenesis imperfecta, hypercalcemia, and even severe osteoporosis [6].

These drugs are used worldwide in cancer patients and are given intravenously as zoledronic acid (Zometa®). They can also be administered orally, such as alendronate (Fosamax®) and risedronate (Actonel®) for the treatment of postmenopausal osteoporosis [Duarte, Nociti, (2004)]. In 2003, a side effect

associated with the use of BP with oral manifestation called Osteonecrosis Associated with BP was described for the first time [7].

In this context, osteoporosis is a prevalent global bone disease in human aging. BPs are commonly used as therapy because they influence the calcium metabolism of hard and soft tissues. Mucosal and dermal ulceration with exposure of the underlying bone results from incomplete epithelial recovery due to reduced desmosome formation due to lack of available calcium. However, pathological situations, such as BP-related jaw osteonecrosis, have been described. This hypothesis states other situations that require intact functional desmosomes such as skin healing over chronic pressure points leading to pressure ulcers and hemidesmosomes such as epithelial seals in contact with titanium surfaces will have a higher prevalence of collapse among patients treated with BP. This can be proven by the decreased modulation of calcium ions due to BP and its effect on intercellular communicating junction formation [4].

As yet another example of literary support, one paper reported a type of localized osteonecrosis that can occur in patients who had successfully osseointegrated implants for many years and then started anti-resorptive therapy [8-10]. Eleven female patients who successfully implanted but were placed on anti-resorptive therapy (BPs or denosumab) several years later and developed osteonecrosis around the implants were identified. In each case, osteonecrosis occurred only around the implants and not around the patient's remaining teeth. Implants from eight patients were removed with bone sequestration firmly attached to the implant. This is different from the normal pattern of implant failure. Implant failure can occur when patients with successfully integrated implants are subsequently placed on anti-resorption therapy, and osteonecrosis takes on a particular form where sequestration forms that remain adherent to the implant. Why the remaining adjacent teeth are not affected is unclear [5,11-13].

Therefore, the present study reviewed the literature analyzing the use of BP associated with dentistry. Because it is a possible alternative for the reduction of loss and increase in bone density, as well as for the possibility of osteonecrosis, which requires therapeutic and preventive measures in the involvement of invasive practices such as dental implants.

Methods

Study Design

The present study followed a systematic review model, following the rules of systematic review -

PRISMA (Transparent reporting of systematic review and meta-analysis, access available in: <http://www.prisma-statement.org/>).

Data Sources

The search strategy was performed in the PubMed, Scielo, Cochrane Library, Web of Science and Scopus, and Google Scholar databases, using scientific articles from 2002 to 2021.

Descriptors (MeSH Terms)

The main MeSH Terms used were "Bisphosphonate. Osseointegration. Dental implant. Osteoporosis. Complications". For greater specification, the description "osteonecrosis" for refinement was added during the searches, following the rules of the word PICOS (Patient; Intervention; Control; Outcomes; Study Design).

Selection Of Studies And Risk Of Bias In Each Study

Two independent reviewers (1 and 2) performed research and study selection. Data extraction was performed by reviewer 1 and fully reviewed by reviewer 2. A third investigator decided some conflicting points and made the final decision to choose the articles. Only studies reported in English were evaluated. The Cochrane Instrument was used to assess the risk of bias of the included studies, and GRADE was used to classify the quality of articles to the type of study and scientific evidence.

MeSH Terms

The descriptors included were Bisphosphonate. Osseointegration. Dental implant. Osteoporosis. Complications. The literature search was conducted through online databases: PubMed, Scopus, Web of Science e Embase, Cochrane, Ovid, Periodicos.com, Harvard Library and Google Scholar.

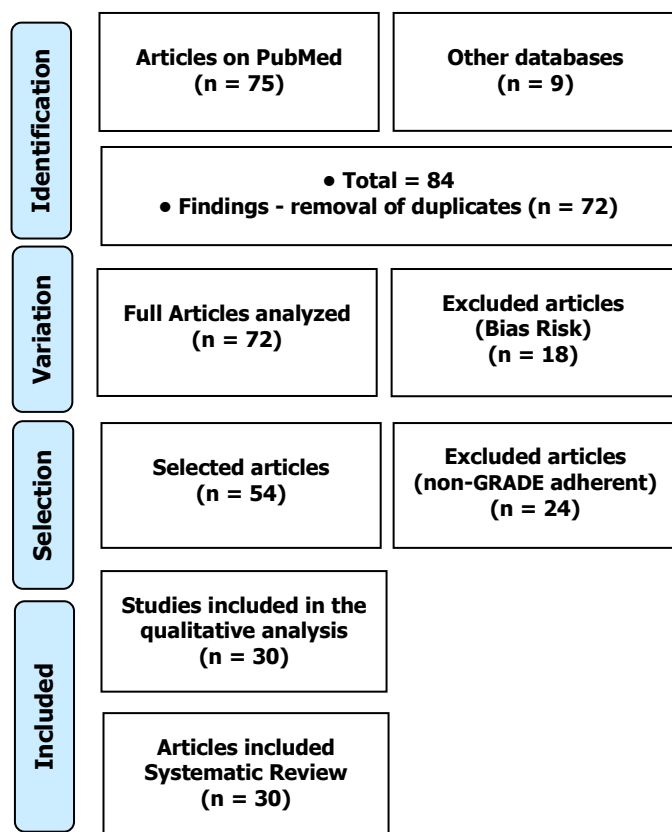
Results

Series of Articles And Eligibility

A total of 84 articles were found involving the MeSH Terms. Initially, it was held the exclusion existing title and duplications in accordance with the interest described this work. After this process, the summaries were evaluated and a new exclusion was held. A total of 45 articles were evaluated in full, and 30 were included and discussed in this study. Initially, the duplication of articles was excluded. After this process, the abstracts were evaluated and a new exclusion was performed, based on the elimination of articles with biases that

could compromise the reliability of the results, according to the rules of the Cochrane instrument, as well as articles that presented low quality in their methodologies, according to the GRADE classification (Figure 1).

Figure 1. Article selection.



Osteoporosis, Osseointegration and Dental Implants

Osteoporosis is defined as a systemic skeletal disorder, associated with aging, characterized by loss of bone mass, which makes the bone more fragile and more prone to fractures [14-19]. The World Health Organization defined osteoporosis as a level of bone mineral density greater than 2.5 standard deviations below the average of normal young women [20]. After 60 years of age, a third of the population has this disorder, it occurs twice more in women than in men and its diagnosis is made with greater prevalence from the third decade of life [21].

Among the systemic alterations, osteoporosis is one of the dysfunctions commonly found by implant dentists [22-25]. Osteoporosis acts by modifying the metabolism of the bone tissues, disorganizing the trabecular architecture of the cortical and alveolar bone, which are responsible for tooth support. It is estimated that 1.3 million of all fractures and 133,000 hip fractures occur each year as a result of osteoporosis [24].

Osteoporosis can be classified as type I and type

II. Type I (postmenopausal) occurs when there is loss of trabecular bone mass, resulting in fractures of the vertebrae and wrists, which may be more evident in the mandible and the alveolar bone, is associated with the aging and plasma decrease of estrogen in menopause, affecting mainly women; and Type II (senile), occurs when there is loss of trabecular bone mass that can affect both cortical and spongy bone, resulting in hip fractures, which can affect both sexes and in ages over 70 years [21].

There is a higher prevalence of the development of osteoporosis in women, and there are some risk factors that may explain this difference, such as early menopause, artificial menopause, nulliparous, and estrogen replacement [25-28]. For men, reduced testicular function (male hypogonadism) can be cited as a risk factor. Several other risk factors may predispose to both sexes: heredity, tobacco, alcohol, caffeine, obesity, absence of physical activity, ethnicity, changes in calcium levels, malnutrition, decreased levels of vitamin D, elevated Levels of parathyroid hormone and other hormones, all these factors may manifest in both men and women with osteoporosis [17,21].

The recommended intake of calcium is 800 mg day⁻¹, in women who have already gone through menopause, 1.5 g may be required to maintain a positive calcium balance [28,30]. For patients with established osteoporosis, there are drugs that, in general, act directly in the process of bone remodeling, seeking to reduce bone resorption, among them, BP, which are drugs of proven efficacy that act in the prevention and treatment of several Bone diseases [30].

In this sense, dental implants are defined as supports or structures of titanium metal, which through surgeries are fixed in the maxillary bone replacing the dental roots, thus allowing the artificial teeth to fit the metal. Dentistry uses several rehabilitation techniques for masticatory functions, and osseointegrated implants are considered safe, provided they are implanted in areas of good quantity and bone quality [15]. However, some systemic conditions may interfere with implant stability, such as osteoporosis. Implantology has shown increasing success rates when it presents a harmonious bone/implant relationship (osseointegration) [15].

The discovery of osseointegration occurred through studies of microcirculation in the bone marrow performed on the rabbit fibula, developed by Per-Ingvar Branemark. He verified in Branemark's studies that a titanium implant when inserted into the medullary space, under certain conditions, and remained immobile without mechanical trauma during the period of bone repair, ends up full of compact bone without the interference of other tissues [16-18].

In this context, osteoporosis is a factor that retards

the regeneration of maxillary bone in patients who have undergone implant surgery, prolonging the normal recovery time of maxillary bone that can vary from three to six months [29]. Therefore, it is necessary that people affected by this disease and who will receive dental implants need a longer time for bone repair [29]. Due to the increase in life expectancy, rehabilitation with implants in people over 60 years old is the most common age group in which there is a higher probability of metabolic pathologies [30].

To obtain osseointegration of the implant, which is the direct and structural unit of the bone tissue to the titanium and function, it is necessary to respect several principles, among them, those related to the surgical technique, respecting tissue physiology [28]. Thus, it is necessary to control the traumatogenic factors during surgery such as intensity, frequency, and duration of the milling (osteotomies), which can generate excessive trauma to the bone tissue, impairing the bone repair potential of the injured area. Facing situations where the traumatic stimulus exceeds its physiological limit, the implant may be involved by fibrous connective tissues, leading to the formation of a bone or fibrous per implant interface, without osseointegration [28].

For the success of osseointegrated implants, other factors must also be considered, not only related to the professional (surgical technique), but also the industry and the patient himself. In addition to performing the appropriate surgical technique, it is up to the professional to select the patient, evaluating it as a whole, from his complaint, including his expectation regarding the treatment, mainly comprising his pre-operative systemic and local conditions [29,30]. At the moment of preparation of the receptor bone bed for the subsequent installation of the osseointegrated implant, bone necrosis occurs, which will be replaced by new bone tissue. When there is osteoporosis, the process of bone remodeling can be compromised, preventing or delaying osseointegration [30].

Several authors Ourique et al. [21] have already reported on the importance of knowledge of systemic alterations so that necessary measures are taken to minimize or prevent eventual damages caused by osteoporosis in the anatomical, physiological and functional integrity of the alveolar bone. All care is necessary for the success of this process since the immediate benefit of the rehabilitative treatment with implants is observed in the improvement of the capacity to crush the food, in the physical and psychological well-being of the patient.

Also, Ishii et al. [15] state that although osteoporosis is a significant factor that can interfere with bone volume and density, it cannot be considered as an absolute contraindication for implant installation. It is

essential that during the anamnesis, all patients are questioned about their state of health, reporting the use of medications and the type of medical treatment they are undertaking so that a safe and effective treatment plan is drawn up for each case.

Bisphosphonate - Main Considerations

BP are a widely used drug group for various bone disorders and have been approved by the U.S. Food and Drug Administration for the treatment of osteoporosis, metastatic bone cancer and Paget's disease [28]. They were first used for industrial purposes in the 19th century to prevent corrosion in the textile, fertilizer and oil industries. In 1968, the first paper describing the use of BP in medicine was published, however in 2002 serious side effects of these medications were reported following dental surgery procedures. This includes osteonecrosis, avascular necrosis, osteomyelitis, osteochimionecrosis, and maxillary Biss-Phossy [28].

At the moment there are two main types of BP those containing nitrogen (oral: alendronate and risedronate, intravenous: pamidronate and zoledronate) and those that do not contain (etidronate, clodronate and tiludronate). BP act by suppressing and reducing bone resorption by osteoclasts, directly preventing the recruitment and function of osteoclasts, and indirectly stimulate osteoblasts to produce inhibitors of osteoclast formation [29].

Also, BP are drugs derived from inorganic pyrophosphate, which are present in the body and physiologically regulate calcification and bone resorption. Pyrophosphate also provides greater resistance to chemical and enzymatic hydrolysis [18]. Camargo, Minosso, Lopes, (2007) [9] report that therapeutic treatment should always combine an anti-resorptive agent with a non-pharmacological measure such as physical exercise and consumption of calcium and vitamin D by diet. Antireabsorption agents are described by Ishii (2009) [15] as estrogen replacement therapy, selective estrogen receptor modulators, BP and calcitonin and also describes bone formation stimulating agents such as parathyroid hormone.

Besides, Ourique et al. [21] have shown in their studies that calcium intake is associated with hormone replacement (estrogen), which leads to an increase in trabecular bone mass. Calcium when ingested alone is not able to definitively prevent the onset of osteoporosis. The authors also report that in addition to osteoporosis, age, sex, races, hormonal pattern, decreased vitamin D synthesis, inhibition of calcium absorption, parathormone increase, nicotine, fragile physical structure, renal deficiency, menopause, alcohol and low Consumption of calcium may jeopardize the

success of an implant.

Also, according to Ishii et al. [15], BP are anti-resorptive agents derived from pyrophosphonic acid that invalidate bone resorption. Ferreira Junior et al. [13] stated that BP can contain bone loss, increase bone density, and reduce the risk of fractures resulting from progressive loss of bone mass. In the BP group, alendronate is the most potent because it has an affinity for bone tissue. Another indication to prevent osteoporosis is calcitonin, which is a peptide derived from parafollicular thyroid cells, aiding bone resistance.

Furthermore, alendronate, for osteoporotic patients, can be administered orally at 10.0 mg/day or 70.0 mg/weekly, and cannot be exceeded because it causes gastrointestinal changes such as erosive esophagitis. It is necessary to use this medicine in fasting, for being little absorbed in the intestine, and to wait of 40 to 60 minutes to feed. It is a drug that deposits about 40-60% rapidly into the bone and the rest is released through the urine. The plasma half-life of BP is very short, ranging from thirty minutes to two hours, so after these medications are absorbed by the bone tissue, they may persist for more than 10 years in skeletal tissues [21].

Besides, a review study with Meta-Analysis included clinical human studies, randomized or not. A total of 18 publications were included in the review. Regarding implant failure, the meta-analysis found a risk ratio of 1.73 (95% confidence interval [CI] 1.21-2.48, $p = 0.003$) for BP patients when compared to patients who did not take the medicine. The probability of an implant failure in patients receiving BP was estimated at 1.5% (0.015, 95% CI 0.006-0.023, standard error [SE] 0.004, $p < 0.001$). BP cannot be suggested to affect marginal bone loss from dental implants due to a limited number of studies reporting this result. Due to lack of sufficient information, the meta-analysis for the outcome "postoperative infection" was not performed. The results of the present study cannot suggest that dental implant insertion in patients taking BP affects implant failure rates due to a limited number of published studies, all characterized by a low level of specificity, and most of them dealing with a limited number of cases without an adequate control group. Therefore, the real effect of BP on osseointegration and survival of dental implants is not yet well established [6].

Bisphosphonates - Major Complications

Ishii et al. [15] state that patients who use BP may have impaired healing of the damaged dental implant as it impedes bone remodeling and may lead to a condition called osteonecrosis, which is considered a side effect of this drug. Although there are much data on the

beneficial effects of BP in the treatment of advanced osseous diseases, numerous reports have documented the ability of these medications to cause local lesions of bone osteonecrosis mainly in the jaw [1,2].

Osteonecrosis may remain asymptomatic for weeks and possibly months, and lesions usually develop around tapered areas and prior surgical sites, including extractions, retrograde apical tetanus, periodontal surgery, and dental implant surgery. Symptoms include pain, soft-tissue edema, infection, tooth loss, and drainage. Radiographically, osteolytic changes are observed and tissue biopsy shows the presence of actinomyces [2,3,30]. In the dental office, the most common BP that the implant is exposed to is the oral ones that contain nitrogen, such as risedronate, ibandronate, and alendronate. Comprehensive anamnesis is essential before the initiation of any elective treatment, the risk versus benefits of dental treatment should be discussed in detail with the patient [28].

In this context, another study using the BP analyzed the factors related to obtaining effective mechanical and immunological adhesion, viability, epidermal collagen growth factor, and immunoglobulin synthesis were evaluated. The presence of BP culminated in lower cell adhesion to titanium discs, particularly for sodium alendronate (SA) at 5 μM (40%) and zoledronic acid (ZA) at all concentrations (30 to 50% according to increased concentrations). Reduced cell viability occurred after an exposure of these cells to ZA (40%); however, only 5 μM of SA-treated cells had decreased viability (30%). Reduced synthesis of growth factors and collagen was observed when cells were treated with ZA (20 and 40%, respectively), while about 70% of IgG synthesis was increased. BPs negatively affected adhesion and metabolism of oral mucosal cells, and this effect was related to BP type as well as concentration and treatment period. The negative effects of BPs on oral mucosa cells may hinder the formation of an effective biological seal in osseointegrated implants [7].

Also, a review study aimed to study the purpose of dental implant placement in patients who have been treated or are undergoing treatment with BP medication. Outcome measures included implant failure or implant-related jaw osteonecrosis. In total, 32 literature sources were reviewed, and 9 of the most relevant articles that fit the criteria were selected. Heterogeneity between studies was found and no meta-analysis could be performed. Five studies looked at intra-oral BP medication for implant placement, three studies looked at intravenous BP medication for implant placement, and one study evaluated the two types of medication administered for implant placement. Patients

with intraoral therapy appeared to have better implant survival (5 implants failed 423) rate of 98.8% versus intravenously treated patients (6 implants failed 68) by 91%; The control group compared with the intraoral BP group appeared with 97% success in implant survival rate (27 implants failed in 842), showing no significant difference in implant placement success. Patients treated with intravenous BP appear to have a greater chance of developing implant-related jaw osteonecrosis. The intraorally treated group of patients appeared to have more successful results. Implant placement in intraorally treated patients can be considered safe with precautions [8].

Conclusion

In the present research, osteoporosis is a metabolic condition that affects alveolar bone density, but does not present problems for the installation of osseointegrated implants, as long as there is sufficient bone mass in the region where the tooth will be implanted. It suggests to the dental surgeons the knowledge of the diagnosis so that it makes a careful evaluation, directing the professional to observe the quality of the bone through routine image examinations. Further, alendronate sodium is used to decrease bone resorption, the drug should be considered as an adjunctive therapeutic agent for the treatment of osteoporosis.

Acknowledgement

Not applicable.

Funding

Not applicable.

Data sharing statement

No additional data are available.

Conflict of interest

The authors declare no conflict of interest.

Similarity check

It was applied by Ithenticate@.

About the License

© The authors (s) 2022. The text of this article is open access and licensed under a Creative Commons Attribution 4.0 International License.

References

1. Sher J, Kirkham-Ali K, Luo JD, Miller C, Sharma D. Dental Implant Placement in Patients With a History of Medications Related to Osteonecrosis of the Jaws: A Systematic Review. *J Oral Implantol.* 2021 Jun 1;47(3):249-268. doi: 10.1563/aaid-joi-D-19-00351. PMID: 32699903.
2. Romero-Ruiz MM, Romero-Serrano M, Serrano-González A, Serrera-Figallo MÁ, Gutiérrez-Pérez JL, Torres-Lagares D. Proposal for a preventive protocol for medication-related osteonecrosis of the jaw. *Med Oral Patol Oral Cir Bucal.* 2021 May 1;26(3):e314-e326. doi: 10.4317/medoral.24197. PMID: 33037798; PMCID: PMC8141321.
3. Seki K, Namaki S, Kamimoto A, Hagiwara Y. Medication-Related Osteonecrosis of the Jaw Subsequent to Peri-Implantitis: A Case Report and Literature Review. *J Oral Implantol.* 2021 Dec 1;47(6):502-510. doi: 10.1563/aaid-joi-D-19-00385. PMID: 33270837.
4. Touyz LZG, Afrashtehfar KI. Implications of bisphosphonate calcium ion depletion interfering with desmosome epithelial seal in osseointegrated implants and pressure ulcers. *Med Hypotheses.* 2017 Sep;107:22-25. doi: 10.1016/j.mehy.2017.07.013. Epub 2017 Jul 18.
5. Pogrel MA, Ruggiero SL. Previously successful dental implants can fail when patients commence anti-resorptive therapy-a case series. *Int J Oral Maxillofac Surg.* 2018 Feb;47(2):220-222. doi: 10.1016/j.ijom.2017.07.012. Epub 2017 Aug 10.
6. Chrcanovic BR, Albrektsson T, Wennerberg A. Bisphosphonates and dental implants: A meta-analysis. *Quintessence Int.* 2016 Apr;47(4):329-42. doi: 10.3290/j.qi.a35523.
7. Basso FG, Pansani TN, Soares DG, Cardoso LM, Hebling J, de Souza Costa CA. Influence of bisphosphonates on the adherence and metabolism of epithelial cells and gingival fibroblasts to titanium surfaces. *Clin Oral Investig.* 2018 Mar;22(2):893-900. doi: 10.1007/s00784-017-2167-2. Epub 2017 Jul 8.
8. Gelazius R, Poskevicius L, Sakavicius D, Grimuta V, Juodzbaly G. Dental Implant Placement in Patients on Bisphosphonate Therapy: a Systematic Review. *J Oral Maxillofac Res.* 2018 Sep 30;9(3):e2. doi: 10.5037/jomr.2018.9302. eCollection 2018 Jul-Sep.
9. Camargo, E. P.; Minosso, M.; Lopes, L. C. Caracterização do Uso de Alendronato de Sódio no Tratamento de Osteoporose por Clínicos da Rede Privada de Duas Cidades do Interior de São Paulo. *Rev. Ciênc. Farm. Básica Apl.*, v.28, n.1, p.77-83, 2007.

10. Carvalho, P. S. P. et al. Principais Aspectos da Cirurgia Bucomaxilofacial no Paciente sob Terapia com Bifosfonatos. RFO UPF [online]. 2010, vol.15, n.2, pp. 183-189. ISSN 1413-4012.
11. Duarte, P. M.; Nociti Júnior, F. H. Impacto da Deficiência de Estrógeno e suas Terapias sobre o Tecido Ósseo ao Redor de Implantes de Titânio e na Periodontite Induzida em Ratas Ovariectomizadas. Tese (Doutorado) – Universidade Estadual de Campinas, Faculdade de Odontologia de Piracicaba. Piracicaba, 2004. XVII, 131p.
12. Embracher Filho, A. Projeto Colosso: Desenvolvimento de um sistema de implante osseointegrável. Da teoria a prática. Tese (Doutorado) - Faculdade de Odontologia de Araçatuba, UNESP, 2003.
13. Ferreira Júnior, C. D; Casado, P. L.; Barboza, E. S. P. Osteonecrose Associada aos Bisfosfonatos na Odontologia. R. Periodontia. v.1, n.4, dez., 2007.
14. Gegler A. et al. Bifosfonatos e Osteonecrose Maxilar: Revisão da Literatura e Relato de Dois Casos. Rev. Brasileira de Cancerologia 2006; 52(1):25-31.
15. Ishii, J. H. Osteoporose e os Implantes Dentários. São Paulo, 2009. 24 p.
16. Luize, D. S. et al. A Influência da Osteoporose na Implantodontia. Arquivos em Odontologia, Belo Horizonte, v.41, n.2, p.105-192, abr./jun. 2005.
17. Martins, M. A. T.; et al. Osteonecrose dos Maxilares Associada ao Uso de Bifosfonatos: Importante Complicação do Tratamento Oncológico. Rev. Bras. Hematol Hemoter 2009; 31(1):41-46.
18. Migliorati CA et al. O Tratamento de Pacientes com Osteonecrose Associada aos Bifosfonatos. Uma tomada de posição da Academia Americana de Medicina Oral. J American Dental Association 2006; 136(12).
19. Misch CE. Implantes Dentais Contemporâneos. Rio de Janeiro: Elsevier. 2008, 3rd.
20. WHO Scientific Group on the Prevention and Management of Osteoporosis (2000 : Geneva, Switzerland). (2003). Prevention and management of osteoporosis : report of a WHO scientific group. World Health Organization. <https://apps.who.int/iris/handle/10665/42841>
21. Ourique SAM, Ito AY, Suarez OF. Osteoporose em Implantodontia: O Estado Atual da Questão. Rev. Bras. Implantodontia e Prótese sobre Implantes, 2005; 12(47/48): 237-45.
22. Goiato MC, Santos DM, Rondon BCS, Moreno A, Baptista GT, Verri FR et al. Care Required When Using Bisphosphonates in Dental Surgical Practice. J. craniofac. surg. 2010; 21(6):1966-70.
23. Chadha GK, Ahmadiéh A, Kumar S, Sedghizaded PP. Osseointegration of dental osteonecrosis of the jaw in patients treated with bisphosphonates therapy: a systematic review. J. oral implantol. 2013;39(4):510-20.
24. Mellado-Valero A, Ferrer-García JC, CalvoCatalá J, Labaig- Rueda C. Implant treatment in patients with osteoporosis. Med. oral patol. oral cir. bucal. 2010; 15:52-7.
25. López-Cedrún JL, Sanromán JF, García A, Peñarrocha M, Feijoo JF, Limeres J, Diz P. Oral bisphosphonate-related osteonecrosis of the jaws in dental implant patients: a case series. Br. j. oral maxillofac. surg. 2012;51(8):874-9.
26. Kwon T-G, Lee C-O, Park J-W, Choi S-Y, Rijal G, Shin H-I. Osteonecrosis associated with dental implants in patients undergoing bisphosphonate treatment. Clin. oral implants res. 2012; 00:1- 9.
27. Yip JK, Borrell LN, Cho SC, Francisco H, Tarnow DP. Association between oral bisphosphonate use and dental implant failure among middleaged women. J. clin. periodontol. 2012;39:408- 14.
28. Memon S, Weltman RL, Katancik JA. Oral Bisphosphonates: Early Endosseous Dental Implant Success and Crestal Bone Changes. A Retrospective Study. Int. j. oral maxillofac. implants. 2012;279(5):1216-22.
29. Abtahi J, Tengvall P, Aspenberg P. A bisphosphonate-coating improves the fixation of metal implants in human bone. A randomized trial of dental implants. Bone. 2012;50(5):1148-51.
30. Jacobsen C, Metzler P, Rossle M, Obwegeser J, Zemann W, Gratz KW. Osteopathology induced by bisphosphonates and dental implants: clinical observations. Clin. oral investig. 2013;17:167-75.

