

**CASE REPORT****Covid-19 disease effect on diabetic foot ulcer management, a big challenge in its management: A case report & literature review**

Mohammad Hassani<sup>1</sup>, Samira Salajeghe<sup>2</sup>, Mustafa Nozarinia<sup>3</sup>, Sara Salajeghe\*<sup>3</sup>

1. *Assistant Professor of Vascular Surgery, Department of Vascular and Endovascular Surgery, Ayatollah Taleghani Hospital, Shahid Beheshti University of Medical Sciences, Tehran, Iran. ORCID: 0000-0002-8671-5191*
2. *Assistant Professor of Radiology, Department of Radiology, Pastroor Hospital, Bam University of Medical Sciences, Bam, Iran*
3. *Fellow of Vascular Surgery, Department of Vascular and Endovascular Surgery, Ayatollah Taleghani Hospital, Shahid Beheshti University of Medical Sciences, Tehran, Iran*

\*Corresponding Author:

Address: Department of Vascular and Endovascular Surgery, Ayatollah Taleghani Hospital, Shahid Beheshti University of Medical Sciences, Tehran, Iran.

Email: mahsoltan2@yahoo.com

ORCID: 0000-0002-5045-5818

*Date Received: March, 2020*

*Date Accepted: April, 2020*

*Online Publication: May 15, 2021*

**Abstract**

Covid-19, which is now pandemic in countries around the world, including Iran. It has shown to cause hypoxia, which can lead to impaired wound healing. In positive covid-19 patients, the patient and his companion's do not usually do appropriate washing of wounds. In addition, economic issues such as procurement and mask of personnel exposed to the patients with covid-19 disease are also an issue. In this article, Corona suspicious patient presented with a diabetic foot and required hospital admission. As such a patient with specific condition suspicion was required to admit, we needed to create a guideline for him and for upcoming similar cases. The patient was a 74-year-old diabetic man who did not respond to debridement. So the patient underwent below-knee amputation, which ended up to above the knee amputation due to a Klebsiella infection and failure to respond to non-invasive treatment of wound infection of stump of below-knee amputation and the patient's condition. The question is whether Corona-related hypoxia has exposed the patient to nosocomial infection, or the patient's lack of self-control at home as well as the medical staff lack of care due to fear of corona was the reason? In the period of the patient was under treatment, there was no significant complaint of shortness of breath. Conclusion: in patient with diabetic foot and covid-19 suspicion \_ especially in critically ill patient may benefit from aggressive approach such as early major amputation because of cost-benefit and minimizing covid-19 risk must consider.

**Keywords:** COVID-19, Diabetic foot, Wound infection

## Introduction

Covid-19 is a pandemic disease that has affected many patients globally. Iran is one of the countries with high prevalence that has proven to have higher rate. People with diabetes are immunocompromised and are less resistant to the infectious diseases. Furthermore, patients with diabetic foot ulcers are more at risk of covid-19, firstly due to lower hygiene and then the comorbidities caused by immobility as well as multiple referrals to crowded medical centers. Patients who go to health centers and have a history of atypical covid-19 presentations and mild symptoms, such as shortness of breath, may be considered a positive case if CT scan findings is suspicious.

The approach in diabetic foot ulcers in covid-19 patients is debatable for several reasons:

- 1- Is wound healing in patients with covid-19 similar to other people?
- 2- Are patients with covid-19 due to lymphopenia and other changes in the immune system prone to specific bacterial infection in his/her wounds?
- 3 - In patients with covid-19 due to the costs that is induced to health system, including masks, gowns, and the risk for personnel who may be exposed to patients with covid-19, is a more aggressive approach in a short time more affordable and better?
- 4- Due to the reduction of the quality of dressing and wound care at home by the companions of patients, is it better to treat patients more aggressively?
- 5- If patient suspicious to covid-19 and admitted to covid-19 ward, short time admission is it better for him/her due to the risk of involvement in negative corona virus patients.

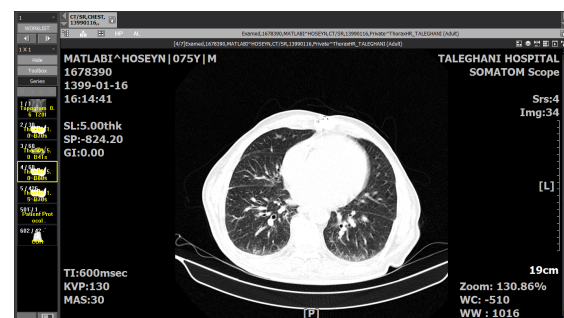
Most covid-19 patients had a history of close contact with people by covid-19 positive test. Complications such as pleural thickening, hydrothorax, pericardial effusion, and enlarged mediastinal lymph nodes were detected but only in rare cases. For the follow-up chest CT examinations, some patient 73% have changed very quickly, with an average of 3.5 days, 27% presented absorbed lesions, progression was observed in 46%, and 27% cases showed no significant changes (1).

Covid-19 has different abnormal signs and paraclinical changes such as anemia, lymphopenia, hypoxemia, abnormal kidney

and liver function, elevated creatine kinase and D-dimer, thrombocytopenia, and increased lactate dehydrogenase. Inflammatory markers like serum ferritin and c-reactive protein were raised (2).

## Case Presentation

Patient was a 74 years old man with a history of diabetes from 4 years ago who described the left foot ulcer from 6 months ago who had undergone left forefoot amputation and the wound has been completely healed. The patient also has a history of anemia and gastric ulcer. Although 5<sup>th</sup> finger in right foot had been amputated 4 months ago, he had referred due to the lack of healing and infected ulcer without ischemic statement as well as shortness of breath without a description of the patient's fever and cough. CT scan of the lung, which showed ground glass lesions in bases of both lungs consist with covid-19 disease, so he was transferred to the corona ward and after that he was transferred to the operating room for debridement. He underwent debridement, but couple of days later, when he was transferred to the operating room again, due to the lack of wound progression and malodour discharge from the wound, in addition of the patient's age and his global condition, below-knee amputation was performed. Two days later, the patient was discharged with oral medicine and consideration of quarantine in home. Two weeks later, he was admitted because of the infected stump wound. Stump debridement was performed in the operating room, but due to the lack of healing and progression of the wound, amputation was progressed to above-knee couple of days later. This wound culture was *Klebsiella pneumonia* sensitive to Amikacin.



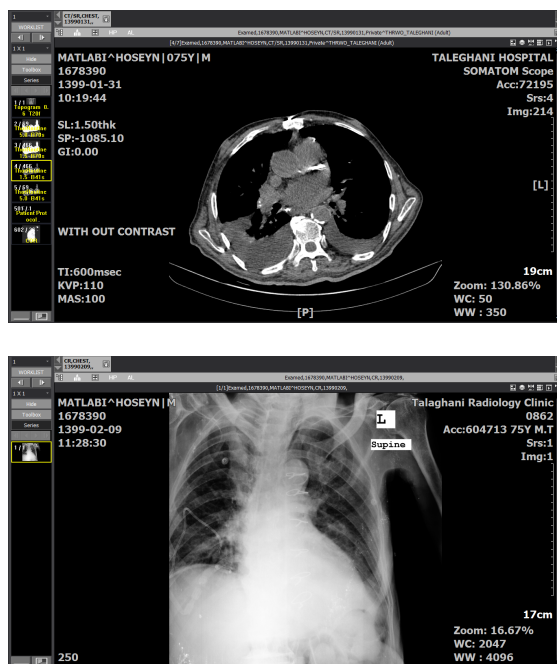


Figure 1-3. Graphics and CT scan of the lungs of a patient suspected of having a covid-19 disease. He had a history of diabetic foot from two months ago. He was admitted to hospital with lung lesions and was treated for diabetic foot ulcers and subsequent amputations. At the next visit, about two weeks later, the patient developed severe pleural effusion in the right lung. They underwent pleural catheter insertion and drainage fluid. Severe shortness of breath did not occur in this period and he did not require oxygen.

## Discussion

Initially, a few questions were raised in mind, if patients came to our hospital, should the medical staff provide more aggressive treatment as soon as possible? Could Klebsiella involvement be more prevalent in patients with covid-19? Does covid-19 disrupt wound healing and re-infection of stamp of amputations that have been uncommon in our ward? Does tissue hypoxia in covid-19 consist with delayed repair the wound?

Hypoxemia, caused by a disorder of blood perfusion, is a key factor in wound healing. Hypoxic correction using supplemental oxygen (O<sub>2</sub>) can have a beneficial effect on wound healing during in-hospital and outpatient settings. Beyond its role as a nutrient and antibiotic, O<sub>2</sub> may support vital processes such as vasodilation, cell motility,

and extracellular matrix formation. Recent discoveries highlight a new dimension to the role of O<sub>2</sub> in wound healing through the production of active oxygen species (ROS) (3).

A major modifier in the healing of the natural wound is oxygen. In fact, oxygen is a requirement for various wound healing processes, including collagen deposition, epithelialization, fibroplasia, angiogenesis, and resistance to infection. Therefore, restriction in O<sub>2</sub>-rich blood transfusion to wound tissue prevents physiological improvement.

Restrictions on oxygen delivery to the wound are often multifactorial. However, the end result is a microporous (non-oxygenated) microenvironment that has not been identified by adequate nutrients and oxygen delivery to the repair tissue (4).

Consist with this article, has hypoxia been induced by covid-19? It is a question that may patients with ulcers at risk of impaired wound healing a big problem in our patient. We recognized the limitations of health care provider system in such cases and have showed that additional studies are needed. Exposer of health care workers to virus, even with proper protection, could create fear in them and less attention to patient. Furthermore lower changing in wound dressing can lead to aggressive infections (5).

Another question was about Klebsiella infection - an opportunistic nosocomial infection - in covid-19 patients? The vast majority of Klebsiella infections nowadays, however, are nosocomial (6). As an opportunistic pathogen, Klebsiella primarily attacks immunodeficient individuals who are hospitalized and have severe underlying diseases. It is estimated that Klebsiella species cause 8% of all hospital-acquired infections (7). Klebsiella infections are found almost everywhere in the body, although urinary tract and respiratory infections are predominant.

Economic issues are another problem in patients with covid-19 disease. For one personnel that participate in operation \$2 must be spent. In each operation at least 6 personnel participate, so \$12 is spent in each operation procedure. In this economic situation in Iran, cost-benefit is considered a big problem in the health care system.

Finally, due to the fact that hypoxia in patients with covid-19 is especially silent (8), and the patient's condition is expected to be impaired wound healing, as mentioned in several articles (hypoxia plays a role in impaired wound healing). On the other hand, we expect increasing risk of wound infection in patients with covid-19 who have poor public health care and inadequate cooperation with the patient's companions for dressings. This wound infection included *Klebsiella* bacteria, a nosocomial infection and transmitted by health care staff. Corona-exposed personnel may not wash the wound well during the operation due to the fear of coronavirus to reduce contact time with the patient, and in addition may be due to barrier of the coverings worn by corona-exposed personnel. It is not possible to scrub the hands properly by these clothes before the operation. In addition, after surgery and in covid-19 ward, the staff may not change the wound dressing of patients with corona and do not wash their hands between each patient and reduce the accuracy of the work. On the other hand, in the corona ward and in the operating room, the cost per corona for each person and mask worn is about \$2-3 more than customary cost. In each operation, at least two anesthesia personnel, two operating room staff, a surgeon and one operating room technician are working. Therefore, at least six people are involved, which costs at least \$12-18 more than a normal operation. Due to the condition of the patients and the disorder in wound healing, inadequate washing and debridement and higher cost, we expect that the patient to be injured more often in the operating room and as well as other clinical wards. In addition, health care workers

involvement with coronavirus after exposure and their dysfunction, increase the cost of treatment. During the hospitalization of covid-19 positive patients in covid-19 ward, more cost was imposed to the health system. On the other hand, early discharge of the patient and early home quarantine may reduce the chance of wound infection and avoid sepsis. According to this definitive surgery, minimized admission in the hospital and wound care problems in home are important. Early amputation in special selective patients, for example, patients with knee contraction and bed-ridden situation can play a special role in reducing the costs of treatment, reducing sepsis in the patient and increasing wound healing rate. It also reduces the chance of staff contact with patients and reduces the prevalence of covid-19. In addition, in patients with suspected covid-19, early aggressive treatment will definitely save the patient from contact by covid-19 positive patients. Consequently Corona virus involvement in them is minimized and justifiable.

Our recommendation for patients with covid-19 who have comorbidities and lack of proper care at home, as well as knee contraction flexion and inability to walk, even after diabetic foot surgery, is early definitive treatment. Because multiple visits to the operating room for repeated debridement can harm the patient and the health care system.

#### **Conflict of interest**

Authors declare no conflict of interest.

**References:**

1. Xiaoming Li, Wenbing Zeng, Xiang Li, Haonan Chen, Linping Shi, Xinghui Li, Hongnian Xiang, Yang Cao, Hui Chen, Chen Liu & Jian Wang CT imaging changes of corona virus disease 2019(COVID-19): a multi-center study in Southwest China ,Journal of Translational Medicine volume 18, Article number: 154 (2020)
2. Indranill Basu-Ray; Michael P. Soos. Cardiac Manifestations Of Coronavirus (COVID-19) .Treasure Island (FL): StatPearls Publishing; 2020 Jan.
3. panelGayle MGordillo.aChandan KSenPh. Revisiting the essential role of oxygen in wound healing The American Journal of Surgery. Volume 186, Issue 3, September 2003, Pages 259-263.
4. Diego M. Castilla,<sup>1</sup> Zhao-Jun Liu,<sup>1,2</sup> and Omaid C. Velazquez<sup>1</sup> Adv Wound Care (New Rochelle). 2012 Dec; 1(6): 225–230. Oxygen: Implications for Wound Healing, doi: 10.1089/wound.2011.0319PMCID: PMC3625368.PMID: 24527310.
5. Kangqi Ng, MBBS, Beng Hoong Poon, MBBS, MPH, MMed (Family Med), COVID-19 and the Risk to Health Care Workers: A Case Report FREE ,Letters 16 Mar 2020, <https://doi.org/10.7326/L20-0175>
6. Hany Sahly Rainer, Podschun Uwe Ullmann, Klebsiella Infections in the Immunocompromised Host, The Biology and Pathology of Innate Immunity Mechanisms pp 237-249.
7. Prince, S., Dominger, K., Cunha, B., and Klein, N. (1997). Klebsiella pneumoniae pneumonia. Heart Lung 26, 413–7.
8. COVID-19 with silent hypoxemia :short case report .William Ottestad, Mari Seim, Jens Otto Mæhlen LØRDAG 23. MAI 2020. Published: 21 April 2020. Tidsskr Nor Legeforen 2020. doi: 0.4045/tidsskr.20.0299