

2022

Laparoscopic Placement of Peritoneal Dialysis Catheter with Selective Omentopexy and Routine Pelvic Fixation

Gina Scroggins

Rochester General Hospital, Gina.Scroggins@rochesterregional.org

Alexander Kurchin

Rochester General Hospital, Alexander.Kurchin@rochesterregional.org

Elizabeth Mamo

Rochester Regional Health, elizabeth.mamo@rochesterregional.org

Linda Fennell

Rochester General Hospital, Linda.Fennell@rochesterregional.org

Katherine Castro

Rochester General Hospital, Katherine.Castro@rochesterregional.org

Follow this and additional works at: <https://scholar.rochesterregional.org/advances>



Part of the [Medicine and Health Sciences Commons](#)

Recommended Citation

Scroggins G, Kurchin A, Mamo E, Fennell L, Castro K. Laparoscopic Placement of Peritoneal Dialysis Catheter with Selective Omentopexy and Routine Pelvic Fixation. *Advances in Clinical Medical Research and Healthcare Delivery*. 2022; 2(1). doi: 10.53785/2769-2779.1086.

ISSN: 2769-2779

This Article is brought to you for free and open access by RocScholar. It has been accepted for inclusion in *Advances in Clinical Medical Research and Healthcare Delivery* by an authorized editor of RocScholar.

Laparoscopic Placement of Peritoneal Dialysis Catheter with Selective Omentopexy and Routine Pelvic Fixation

Abstract

A technique of “double fixation” for placement of peritoneal dialysis (PD) catheters is described. It combines selective omentopexy with routine pelvic fixation of the catheter. We present specific criteria for omentopexy, which was performed in 18% of the 50 patients in our study. Follow-up focused on mechanical failure of the catheters, which occurred in eight patients. In all eight, laparoscopic revision was performed, with successful return of catheter function in four.

Keywords

Peritoneal dialysis, Omentopexy, Pelvic fixation of peritoneal dialysis catheter, Laparoscopic revision of occluded peritoneal dialysis catheter, Laparoscopic evaluation of omental length

Conflict of Interest Statement

The authors have no conflicts of interest.

Introduction

The detrimental effect of the omentum on PD catheter function was recognized in the early days of PD and it was generally accepted that separation of the catheter from the omentum is essential for good catheter function.¹ This is usually accomplished by placement of the catheter tip in the pelvis. However, in patients with a long omentum that can reach the pelvis, omentopexy is required as well.²

This paper describes our surgical approach to laparoscopic PD catheter placement, using routine pelvic fixation and selective omentopexy.

Material and Methods

Rochester General Hospital is a 500-bed tertiary care hospital in Rochester, NY, with an active PD service of about 70 patients. Over a 10-month period (February to December 2018), we conducted a prospective study on 50 consecutive patients in whom we placed PD catheters. We collected demographic, clinical, and operative data. Preoperative assessment included risk assessment for general anesthesia, specifically cardiac risk, and an abdominal evaluation for the presence of hernias. If present, hernias were usually repaired at the time of catheter placement. Follow-up data, including catheter use and function, were collected until July 2020, or earlier if the patient died, was converted to hemodialysis, or received a renal transplant.

Operative Technique

All procedures were performed laparoscopically by one of the authors (AK). A double-cuffed coiled Tenckhoff catheter (Covidien-Medtronic, Dublin, Ireland) was used. (Figure 1). The average net operative time was 40 minutes.

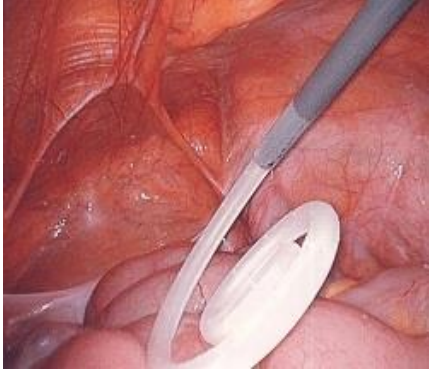

Figure 1



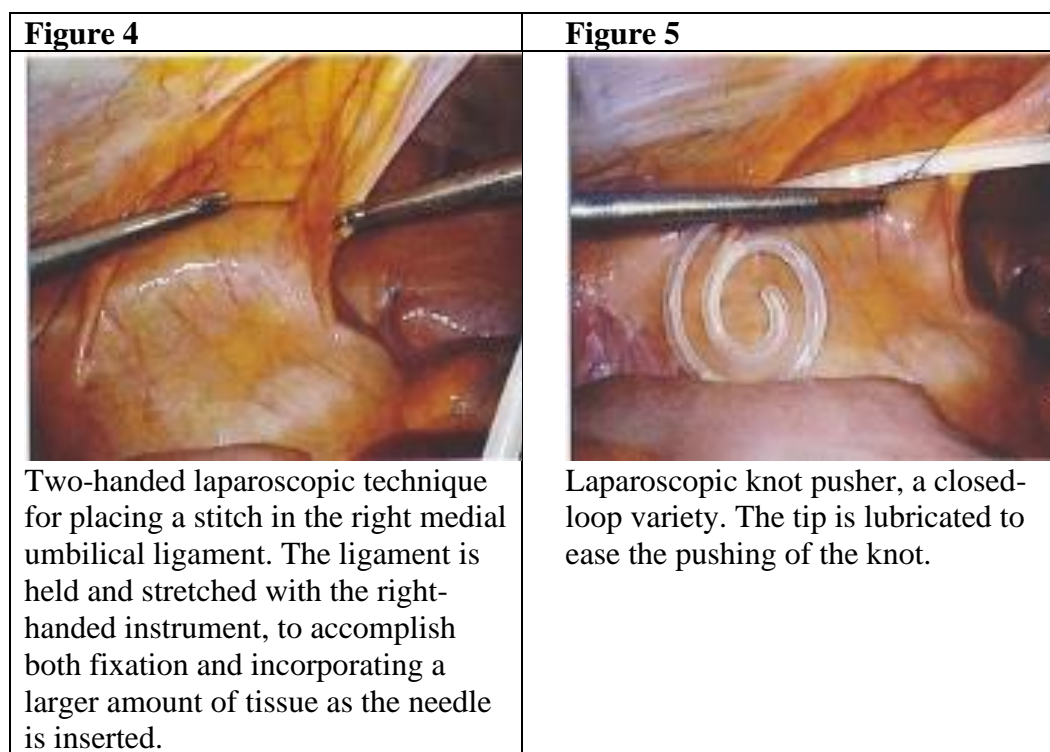
Double-cuffed coiled Tenckhoff catheter. This is probably the most commonly used type of catheter in the US. The distance between the two Dacron cuffs is about 7cm. The deep cuff is placed within the rectus sheath and the superficial cuff is placed subcutaneously.

The patient is placed in supine position. General endotracheal anesthesia with muscle relaxation is administered. An orogastric tube is placed to decompress the stomach. The left upper extremity is tucked to allow convenient position of the operator at the patient's left. The laparoscopic monitor is positioned at the foot of the bed. The initial entry to the peritoneal cavity is at the left upper quadrant, below the costal margin (Palmer's point) with a Veress needle.³ Three 5mm non-bladed trocars are placed in the epigastrium, left upper abdomen, and left mid-abdomen, allowing easy access for both pelvic fixation of the catheter and omentopexy if indicated. The position of the trocars and the insertion site of the catheter may be modified if adhesions are present.

The catheter insertion site is usually over the right rectus abdominis muscle, and determined by using the symphysis pubis as an anatomic reference point, placing the junction of the coiled and straight parts of the catheter over the upper aspect of the symphysis pubis.² This usually yields an insertion site above the umbilicus. The peritoneal entry for the catheter placement is done under laparoscopic vision with a 5mm non-bladed laparoscopic trocar placed at 30 – 45° to the abdominal wall, aiming towards the pelvis. This defines the course of the catheter in the abdominal wall, and serves as a dilator that eases the placement of the deep cuff into the rectus sheath. The wire of the introduction kit is placed through the trocar, and the trocar is removed, followed by standard Seldinger insertion technique. The catheter is placed intraperitoneally through the peel away sheath introducer (Figure 2), pushing its deep cuff into the peritoneum to determine its depth of insertion, and then pulling it back 1 – 2cm to ensure position within the rectus sheath (Figure 3).

Figure 2	Figure 3
 <p data-bbox="298 1570 737 1682">Peel away sheath introducer, in an intraperitoneal position. Seldinger technique is used.</p>	 <p data-bbox="776 1541 1317 1711">The deep Dacron cuff is visible within the peritoneal cavity. The desired position of the cuff within the rectus sheath is accomplished by pulling the catheter back 1-2cm.</p>

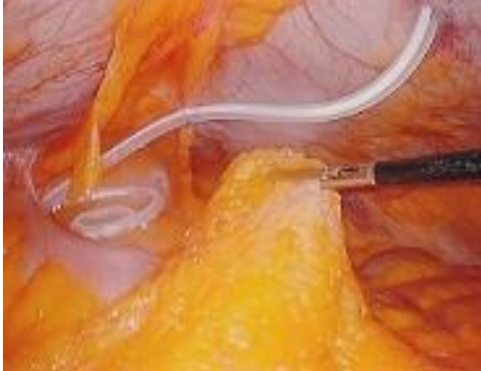

With an oblique positioning of the catheter within the rectus sheath, the coiled part of the catheter usually reaches the pelvis, behind the urinary bladder, but we do not consider this to be sufficiently reliable or sustainable. We proceed with pelvic fixation of the catheter to secure its position. This is done with a 3-0 Prolene stitch, double armed, on SH needle (Ethicon, Somerville, NJ), with one needle removed and one partially straightened to allow its passage through the 5mm trocar. The double-armed stitch has extra length that makes laparoscopic tying easier. With the laparoscope in the left upper quadrant port, the stitch is inserted through the left mid abdominal port. With a second needle holder placed in the epigastric port, and with a two-handed technique, (Figure 4) the stitch is passed through the right medial umbilical ligament and then around the shaft of the catheter in an encircling fashion. Tying is done with a laparoscopic knot pusher (Figure 5).




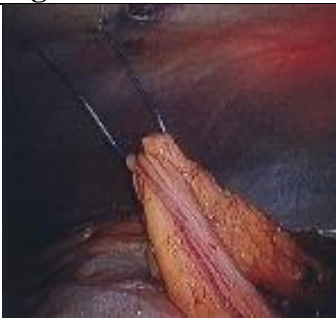

The external part of the catheter is tunnelized across the midline to the left, usually above the umbilicus. Saline is injected into the catheter to verify free flow and absence of kinks.

With the catheter tip secured in a pelvic position, the length of the omentum is assessed in relation to the catheter. The apex of the omentum is held with a laparoscopic grabber and moved caudad towards the coiled part of the catheter with

minimal force and tension. We refer to this as the “omental stretch test”, a maneuver which takes a few seconds. If the omentum contacts the upper part of the coiled segment of the catheter with minimal stretch force, indicating a potential for adhesions and catheter obliteration, we proceed with omentopexy (Figures 6 and 7).

Figure 6	Figure 7
 <p data-bbox="298 884 776 980">Negative “stretch test” – the omentum does not reach the catheter in its pelvic position.</p>	 <p data-bbox="808 884 1295 980">Positive “stretch test” – the omentum easily covers the coiled part of the catheter.</p>

The omentopexy is usually done to the site of the left mid-abdominal trocar, after the trocar is removed. The laparoscope remains at the left upper abdominal port. The omentum is handled through the epigastric port. The apex of the omentum is held with a laparoscopic grabber and brought to the site of the omentopexy. Fixation is done with a #0 Prolene stitch, making one or two passes through the apex of the omentum with a Carter-Thomason needle (CooperSurgical, Trumbull, CT). The stitch is tied tightly under laparoscopic view, to ensure contact of the omentum with the abdominal wall. (Figures 8, 9, 10). At this point, the pressure of the pneumoperitoneum may be decreased to make tying easier. The net time of the omentopexy is estimated to be 4-5 minutes.

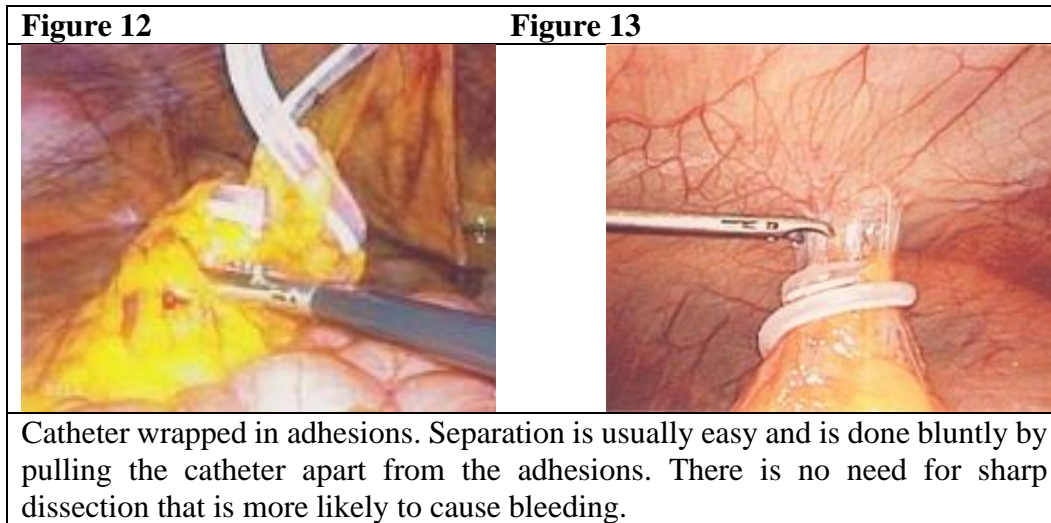
Figure 8	Figure 9	Figure 10
		
<p>Omentopexy: The apex of the omentum placed at omentopexy site.</p>	<p>Omentopexy: #0 Prolene stitch is placed through the omental apex, using Carter-Thomason needle.</p>	<p>Complete omentopexy. The omentum is fixated and positioned well away from the catheter.</p>

In some patients, omental adhesions to the anterior abdominal wall from previous surgery serve as “natural” omentopexy and are intentionally left intact (Figure 11).

Figure 11
 <p data-bbox="298 1360 1325 1430">“Natural” omentopexy – The omentum is fixated in the mid abdomen, away from the catheter, due to adhesions from previous surgery.</p>

Most patients are discharged a few hours after completion of the operation.

In patients with mechanical failure of the catheter, defined as impaired fluid exchange that does not allow dialysis, laparoscopic revisions are performed. This is done by inducing pneumoperitoneum through the existing catheter (this is usually successful, even in malfunctioning catheters, and makes trocar placement easier) and then placing three 5mm trocars in the upper abdomen in locations based on the distribution of the adhesions. A typical finding is that of the catheter encased in adhesions, which are taken down (Figures 12, 13).



Results

Demographics and clinical history are shown in Table 1.

Table 1: Pre-operative Data (total of 50 patients)	
Age	20-80 years old (mean 66)
Gender	Male 20, Female 30
Race	White 36, Black 11, Other 3
Previous abdominal surgery	34
Previous PD catheter	7
First catheter placement	43
Dialysis status	On hemodialysis 14, not on dialysis 36

Operative findings and procedures are shown in Table 2. A significant number of patients had undergone previous surgeries, and in many, adhesions were present. In four patients, extensive adhesions were present at the time of the original operation, obliterating a significant portion of the peritoneal cavity. While the prospects of accomplishing catheter function appeared limited, “desperate” lysis of the adhesions was performed, in an attempt to establish an open peritoneal cavity.

Table 2: Operative findings and procedure

Degree of adhesion	None	26
	Mild	10
	Moderate	10
	Extensive, obliterating much of the peritoneal cavity	4
Adhesion forming “natural” omentopexy		8
Adhesions requiring lysis		12 (4 of whom had extensive adhesions and the lysis was defined as “desperate”)
Omentopexy done		9 (18%)

Follow Up and Outcome

Follow-up was carried out by a combination of office visit, phone interview, and chart review. The focus was on detecting patients with mechanical failure of the catheter. At the time that follow-up was concluded, 18 patients were deceased and 31 were alive, 15 of them still on PD. One patient was lost to follow-up. Details of follow-up are shown in Table 3.

Table 3. Follow up

15 patients were converted to hemodialysis at an average time of 12 months, for the following reasons:

- Psychosocial – 7
- Mechanical failure with failed revision – 4
- Filtration failure – 1
- Calciphylaxis – 1
- Exit site leak – 1
- Exit site infection – 1

Two patients died from medical reasons shortly after catheter placement, the catheters were never used.

10 patients died with functioning catheters (at an average time of eleven months on therapy).

Six patients died after conversion to hemodialysis.

Three patients had kidney transplants, with catheters still functioning, at an average time of one year after catheter placement.

Revisions

In all eight patients with mechanical failure, revision was attempted. Four of these revisions were performed in the patients who were found to have extensive adhesions in the first operation, and underwent “desperate” lysis of adhesions. The catheters never functioned and the revisions failed. In the other four patients with less significant adhesions, revisions were successful. We consider three of these four patients to be failures of our “double fixation” protocol. One of these patients was judged to have a short omentum in the first operation and accordingly no omentopexy was done. However, upon revision, the omentum was adherent to the catheter, indicating a mistake in judgment in evaluating the omental length in the first operation. Successful lysis of adhesions and omentopexy were performed. In two other patients, the pelvic fixation of the catheter failed, and the catheter unraveled itself from the encircling pelvic stitch (an occurrence for which we have no clear mechanical explanation). It moved cephalad to the mid abdomen and became wrapped with adhesions. These adhesions were taken down, and pelvic fixation was redone. The fourth patient had non-omental adhesions that were successfully lysed. In all four patients, revision was successful and catheter function was reestablished.

Discussion

Adhesions, either preexisting or developing as a result of the catheter presence in the peritoneal cavity, are the main cause of mechanical failure of PD. While adhesions may form at any peritoneal surface, omental adhesions are a common occurrence, and are also the most preventable by surgical measures.

There are two important anatomic components in avoiding omental adhesions to the catheter: Securing the catheter in the pelvis, and keeping the omentum away from the catheter.

In the early days of PD, laparoscopic technology was not available, and catheter placement was done either by mini laparotomy or percutaneously. Both techniques were “blind,” as the peritoneal anatomy, extent and location of adhesions, length of the omentum, and exact catheter position could not be precisely assessed. Recognizing the capacity of the omentum (“the watchdog of the abdomen”) to obliterate the catheter orifices, but without the ability to evaluate omental anatomy accurately, some authors recommended routine omentopexy or omentectomy to improve the prospect of long-term catheter patency.^{4,5,6}

Laparoscopy revolutionized the procedure of PD catheter placement. It minimizes surgical trauma, allows accurate pelvic positioning of the catheter tip, and provides direct access to evaluate and handle the omentum and existing adhesions.

There is no consensus in the literature about the optimal approach to the two crucial anatomic elements in accomplishing catheter patency: Pelvic positioning of the catheter and separation of the omentum from it. Most surgeons use rectus sheath tunnelizing as the technique of choice for directing the catheter to the pelvis and do not do routine pelvic fixation.² We assume that the need to use one or two additional trocars and the perceived technical difficulty of laparoscopic suturing and tying are

the reasons for this preference. However, with today's laparoscopic techniques, these considerations have less weight.

We and others⁷ prefer the more direct approach of pelvic fixation for the following reasons:

1. It is simpler, requiring no special tunnelizing device and no incision to expose the fascia.²
2. We believe it is more reliable in accomplishing and maintaining long-term pelvic position.
3. It allows modifications and fine adjustments of pelvic position of the catheter if pelvic adhesions are present, or even suprapelvic position of the catheter if the pelvis is obliterated by adhesions.
4. It is performed by a completely laparoscopic technique, while rectus sheath tunnelizing is usually done by exposure of the anterior rectus sheath.²

The pelvic position of the catheter will usually keep it out of the reach of the omentum. Still, in a significant number of patients (18% in our study) the omentum was long enough to reach the pelvis and had the potential to obliterate the catheter. There are no standard techniques to evaluate the omental length and no consensus about when to perform omentopexy. Crabtree recommends omentopexy for a "redundant omentum that fills the pelvis", which we do not find specific enough.² While some authors recommend routine omentopexy,^{4,5} we advocate selective omentopexy, a well-established concept.^{8,2} The "omental stretch test" that we describe is a simple and reliable technique that helps determine the need for omentopexy. The procedure requires no specific skills and utilizes regular laparoscopic instruments. We believe that routine omentopexy is not indicated.

Our omentopexy rate is lower than others, where omentopexy is used in 30-40% of patients^{9,10} Ours was 18%. A possible explanation is that our specific "omental stretch test" better defines the omental anatomy and avoids unnecessary omentopexies in patients whose omentum is not long enough to reach the pelvis.

A few potential arguments against our technique are the following:

1. Pelvic fixation by suturing presumably makes removal of the catheter more difficult if required for infection, peritonitis, or for conversion to hemodialysis. However, we routinely remove catheters by the "pull technique", a nonsurgical approach that can be performed in the office or at the bedside. Pelvic fixation does not cause difficulty with catheter removal by this technique.¹¹
2. Potential risk of bleeding with the pelvic fixation or the omentopexy- we did not encounter this problem in our study, or additional few hundreds of patients not included in the study.
3. Additional operative time and anesthesia time due to the surgical steps of pelvic fixation and omentopexy- each of these takes about five minutes, with estimated additional anesthesia time of ten minutes, which is a minimal additional anesthetic risk, much less than the benefits of the procedure and potential avoidance of additional surgery.

All eight patients in our study with mechanical failure of the catheter underwent laparoscopic revision. In the four in whom we performed “desperate” lysis of adhesions at the time of the original operation, catheter function was never achieved and the revisions failed. In the other four the revision was successful. Three of these we considered to be failures of our “double fixation” approach. Since extensive lysis of adhesions has a certain risk of inadvertent enterotomies, there is a reasonable argument against trying to perform them.

Non-omental adhesions, pre-existing or postoperative, remain a major problem without a good surgical solution. When they are extensive and obliterate much of the peritoneal cavity, “desperate” lysis of adhesions may be attempted, but the success rate is low. In our series, both the original operation and the revision failed in this group of patients.

In conclusion, our approach combining pelvic fixation and selective omentopexy is appealing due to its simplicity and technical ease. In our series, the “double fixation” initially failed in three out of 50 patients, but in all three, laparoscopic revisions were successful.

Limitations of the Study

The number of patients in this study is small. Ideally, a prospective randomized study, checking the two elements emphasized in this paper, pelvic fixation and omentopexy, would have been done. However, such a study is unlikely to be undertaken. Our conclusions and recommendations are based on personal experience and opinion.

Conflict of Interest Statement

The authors have no conflicts of interest.

References

1. Swartz, R.D. Chronic peritoneal dialysis: mechanical and infectious complications. *Nephron*. 1985;40(1): 29-37. doi:10.1159/000183423
2. Crabtree, J. H., Fishman, A. A laparoscopic method for optimal peritoneal dialysis access. *Am Surg*. 2005;71(2):135-143. doi:10.1177/000313480507100209
3. Palmer, R. Safety in laparoscopy. *J Reprod Med*. 1974;13(1):1-5.
4. Keramati, M. R., Abbaszadeh-Kasbi, A., Keshvari, A. Laparoscopic Omentopexy, Rectus Sheath Tunneling and Implantation of the Peritoneal Dialysis Catheter Using a Peritoneal Dialysis Port. *Perit Dial Int*. 2018;38(3):187-191. doi:10.3747/pdi.2017.00195
5. Nicholson, M. L., Burton, P. R., Donnelly, P. K., Veitch, P. S., Walls, J. The role of omentectomy in continuous ambulatory peritoneal dialysis. *Perit Dial Int*. 1991;11(4): 330-332. doi:10.1177/089686089101100407
6. Pumford, N., Cassey, J., Uttley, W. S. Omentectomy with peritoneal catheter placement in acute renal failure. *Nephron*. 1991;68(3):327-328. doi:10.1159/000188394
7. Bar-Zohar, D., Sagie, B., Lubezky, N., Blum, M., Klausner, J., Abu-Abeid, S. Laparoscopic implantation of the Tenckhoff catheter for the treatment of end-stage renal failure and congestive heart failure: experience with the pelvic fixation technique. *Isr Med Assoc J*. 2006;8(3);174.
8. Attaluri, V., Lebeis, C., Brethauer, S., Rosenblatt, S. Advanced laparoscopic techniques significantly improve function of peritoneal dialysis catheters. *J Am Coll Surg*. 2010;211(6);699-704.
9. Crabtree, J. H., Burchette, R. J. Peritoneal dialysis catheter embedment: surgical considerations, expectations, and complications. *Am J Surg*. 2013;206(4):464-471. doi:10.1016/j.amjsurg.2013.03.006
10. Krezalek, M. A., Bonamici, N., Lapin, B., Carbray, J., Velasco, J., Denham, W., Linn, J., Ujiki, M., Haggerty, S. P. Laparoscopic peritoneal dialysis catheter insertion using rectus sheath tunnel and selective omentopexy significantly reduces catheter dysfunction and increases peritoneal dialysis longevity. *Surgery*. 2016;160(4):924-935. doi:10.1016/j.surg.2016.06.005
11. Grief, M., Mamo, E., Scroggins, G., & Kurchin, A. (2017). The 'Pull' Technique for Removal of Peritoneal Dialysis Catheters: A Call for Re-Evaluation of Practice Standards. *Perit Dial Int*. 2017;37(2);225-229. doi:10.3747/pdi.2016.00152