

Hypertensive Crisis in a Patient With an Undiagnosed Pheochromocytoma

Tanı Almamış Feokromositomalı Hastada Hipertansif Kriz

Züleyha Kazak

Asist. Professor of Anesthesiology and Reanimation
Ufuk University
kazakzuleyha@yahoo.com

Kamil Darcin

M.D., Anesthesiology and Reanimation
Ufuk University
drdarcin@yahoo.com

Kansu Kazbek

M.D., Anesthesiology and Reanimation
Ufuk University

Sumru Sekerci

Professor of Anesthesiology and Reanimation
Ufuk University
sumrusekerici@hotmail.com

Hikmet Süer

Professor of Anesthesiology and Reanimation
Ufuk University
ahsuer@hotmail.com

This study was presented at the XLIIth National Anesthesiology and Reanimation Congress, 29 October -02 December 2008, Antalya, Turkey.

Submitted : May 04, 2009
Revised : October 16, 2009
Accepted : December 23, 2010

Corresponding Author:

Yard. Doç. Dr. Züleyha Kazak
Ufuk Üniversitesi Tıp Fakültesi,
Anesteziyoloji ve Reanimasyon Anabilim Dalı,
Ankara- Turkey.

Phone : +90 - 3122044098
e-mail : kazakzuleyha@yahoo.com

Abstract

Pheochromocytoma is a catecholamine secreting tumor which originates in the chromaffin cells of adrenal medulla. Silent pheochromocytomas can become evident with hypertensive attack during anaesthesia. Here is presented a case of pheochromocytoma without high plasma or urinary levels of catecholamines, and without history of hypertension which was detected with hypertensive attack during surgical extirpation. With all the newest medications and techniques that have been developed the anesthetic management of undiagnosed pheochromocytomas are still sources of unexpected problems for the anesthetists. In this case it was a great chance that there were no complications despite the hypertensive crisis.

Key words: **Adrenal Gland Neoplasm; Catecholamines; Pheochromocytoma.**

Özet

Feokromositoma adrenal medullanın kromaffin hücrelerinden köken alan ve katekolamin salgılayan bir tümördür. Sessiz feokromositomalar anestezi sırasında ortaya çıkan hipertansif ataklarla kendilerini belli edebilirler. Bu olguda plazma ve idrar katekolamin seviyeleri normal olan, hipertansiyon hikayesi olmayan ve cerrahi sırasında tanı konan bir feokromositoma vakası sunulmaktadır. Tüm yeni ilaç ve tekniklere rağmen tanı konmamış feokromositomanın anestetik yönetimi anestezi için beklenmedik sorunlar oluşturmaktadır. Bu vakada hipertansif krize rağmen herhangi bir komplikasyonla karşılaşılmamış olması büyük bir şanstır.

Anahtar Sözcükler: **Adrenal Bez Tümörleri; Katekolaminler; Feokromositom.**

Introduction

Adrenal incidentalomas are adrenal masses detected during imaging performed for other than adrenal pathologies reasons (1). The incidence of adrenal incidentalomas in autopsy series varies between 1 and 8.7% (2). Statistically, the 1% incidence for the age of 30 rises up to 7% for the age of 70 (3). Pheochromocytoma is a tumour that secretes catecholamine and originates in the chromaffin cells of adrenal medulla (4). The incidence of pheochromocytoma is about 1-4/1,000,000 per year (5). Silent pheochromocytomas may occur with a hypertensive attack during surgery or anaesthesia. Mortality in hypertensive attack due to pheochromocytomas can be as high as 80% (6). Here is a pheochromocytoma case detected with hypertensive attack during surgical extirpation which had normal plasma or urinary levels of catecholamines and without a history of hypertension.

Case Report

A 38 years old male patient, presenting with dyspeptic complaints, applied to our general surgery department. Oesophagogastroduodenoscopy showed normal findings. As the abdominal ultrasonography yielded a hyperechogenic solid mass of 50x59 mm at the right adrenal gland, magnetic resonance imaging done and a 60x55 mm size solid mass with regular borders and showing heterogeneous contrast uptake was detected (Figure 1). The patient who had no history of hypertension, palpitation, tremor or loss of weight complaints had a normal physical examination. There was nothing to indicate pheochromocytoma in the family history.

In the laboratory tests, serum biochemical examination, electrolyte levels and complete blood count were found within normal limits. The plasma levels of cortisol, aldosteron and ACTH, plasma renin activity; and amounts of VMA, metanephrine and 5-HIAA in 24 hour urinary output were all within normal range (cortisol: 6.80 µg/dl [5-25 µg/dl], Plasma renin activity: 1.90 ng/ml/h [0.98-4.18 ng/ml/h], ACTH: 27.5 pg/ml [9-52 pg/ml] aldosteron: 2.66 pg/ml [2-16 pg/dl], VMA in 24 hour urinary output: 7.55 mg/day [1-10 mg/day], metanephrine: 0.78 mg/day [0-1 mg/day], 5-HIAA: 6.99 mg/day [2-10 mg/day]). ECG revealed normal sinus rhythm, 80 beats /min and no axis deviation, ST - T wave changes or premature ventricular beats. Chest radiogram was normal. After endocrinologic and urologic consultations, the diagnosis of incidentaloma was made and surgical operation was planned by the urology department.

The patient was accepted to the operating room and monitorization of ECG, noninvasive blood pressure and pulse oximetry was started. Induction of anaesthesia was done with 6mg/kg thiopental sodium, 75 µg fentanyl and 1 mg/kg vecuronium. The vitality signs of the patient were observed normal during the induction and intubation. Sevoflurane 2% in 50% O₂ and 50% N₂O was given for the maintenance of anaesthesia. Invasive blood pressure monitorization via radial artery was done all through the operation. On the position of the left lateral decubitus, upon opening the right retroperitoneal region, the blood pressure of the patient rose to 180/100 mmHg and the surgery was paused as a result. 100 mg propofol, 100 µg fentanyl, 2 mg vecuronium and a total of 30 mg glyceryl trinitrate (Nitro)[®] were given. Infusion of glyceryl trinitrate was started at a rate of 21 µg/kg/min but blood pressure control couldn't be achieved, and then Sodium nitroprussid (Nipruss)[®] infusion was started at a rate of 1 µg/kg/min. As the blood pressure could be lowered to 150/80 mmHg surgeons were allowed to resume the operation. To increase the depth of anaesthesia inhaled, sevoflurane concentration was increased. Despite the antihypertensives used, the blood pressure raised up to 330/120 mmHg when the tumor was touched by surgical team. As it was considered as a pheochromocytoma attack, the operation was not allowed to go on. Infusion of esmolol at a rate of 300 µg/kg/min was started in addition to the prior antihypertensive treatments. The patient was extubated when the blood pressure was 140/80 mmHg and the heart rate was 86 beats/min. The patient was transferred to the intensive care unit (ICU) with antihypertensive infusions. During the postoperative period, the 24 hour urine measurements of VMA: 44 mg/day, metanephrine: 3.28 mg/day, 5-HIAA: 48.8 mg/day and HVA: 60 mg/day confirmed the diagnosis of pheochromocytoma. The patient was supervised in the ICU until his blood pressure was within normal limits for 20 hours and then he was discharged with the prospects of preparing for the surgery. But patient did not return to hospital for pheochromocytoma excision. His good health status was learned through phone consultation.

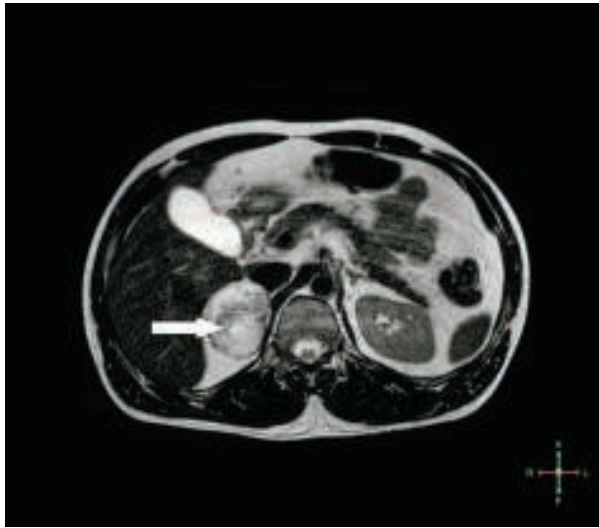


Figure 1. Abdominal MRI shows a solid mass of right adrenal gland with regular borders and heterogeneous contrast uptake.

Discussion

In a study in which 2000 incidentalomas were examined, of these masses 82% were found out to be nonfunctional adenomas, 5.3% subclinical Cushing syndromes, 5.1% pheochromocytomas, 1% aldosteron secreting adenomas, 4.7% adrenocortical carcinomas and 2.5% metastatic diseases (7) The clinical suspicion for diagnosis of pheochromocytoma is of primary concern. For all adrenal masses, a detailed hormonal screening prior to surgery is necessary. Even though the symptoms of pheochromocytoma may vary, the triad of hypertension, headache and diaphoresis are present in 40-80% of the patients (8).

Pheochromocytoma can be diagnosed by documenting the increase of plasma and urinary catecholamines and their products. The presence of catecholamines and their metabolites in the plasma and urine is evidence for presence of pheochromocytoma with 95% certainty. The most sensitive test in diagnosis is the measurement of free metanephrine levels of plasma (9). As seen in Table I, metanephrine in urine is 95% diagnostic, but it was within normal limits in this patient. The aim in the preoperative preparation of pheochromocytoma is to bring the blood pressure, heart rate and intravascular volume to normal. Roizen criteria (10) can be used to evaluate the adequacy of the preoperative preparation.

Table I. Diagnostic test in pheochromocytoma (11)

	Sensitivity	Specificity
Imaging criteria		
MRI	100%	
I-MIBG Scintigraphy	100%	
Computerised tomography	88%	
Ultrasonography	83%	
Biochemical criteria		
Plasma		
Free metanephrines	99%	89%
Catecholamines	84%	81%
Urine		
Fractioned metanephrines	97%	69%
Catecholamines	86%	88%
Total metanephrine	77%	93%
VMA	64%	95%

Effective premedication will reduce the risks of perioperative hypertension and tachycardia due to possible high levels of circulating catecholamines. While 50% of pheochromocytomas are diagnosed postmortem, some are diagnosed with high mortality hypertensive attacks. It should be kept in mind that the high plasma catecholamine levels may lead to vasoconstriction during operation and therefore patients can need volume replacement postoperatively.

The fact that the patients with adrenal masses are examined in detail with appropriate tests preoperatively and that they are prepared for the operation are crucial in terms of lowering the mortality and morbidity. In this patient, even though there was no evidence of pheochromocytoma in the preoperative tests, during the operation a life threatening hypertensive attack resistant to antihypertensive medications was encountered. Despite all the newest medications and techniques that have been developed, the anesthetic management of undiagnosed pheochromocytomas is still a source of unexpected problems for the anaesthetist. It was a great chance in this case that there were no complications in spite of the hypertensive crisis.

References

1. Kloos RT, Gross MD, Francis IR, Korobkin M, Shapiro B. Incidentally discovered adrenal masses. *Endocr Rev* 1995; 16:460–484.
2. Barzon L, Sonito N, Fallo F, Palu G, Boscaro M. Prevalence and natural history of adrenal incidentalomas. *Eur J Endocrinol* 2003; 149:273-285.
3. Ross NS, Aron DC. Hormonal evaluation of the patient with an incidentally discovered adrenal mass. *N Engl J Med* 1990; 323:1401-1405.
4. Pacak K, Eisenhofer G, Ahlman H, et al. Pheochromocytoma: recommendations for clinical practice from the First International Symposium. October 2005. *Nat Clin Pract Endocrinol Metab* 2007; 3:92–102.
5. Ilias I, Pacak K. A clinical overview of pheochromocytomas/paragangliomas and carcinoid tumors. *Nucl Med Biol.* 2008; 35:27-34.
6. O'Riordan JA. Pheochromocytomas and anaesthesia. *Int Anesthesiol Clin* 1997; 35:99-127.
7. Young WF Jr. Management approaches to adrenal incidentalomas. *Endocrinol Metab Clin North Am* 2000, 29:159–185.
8. Kaltsas GA, Papadogias D, Grossman AB. The clinical presentation (symptoms and signs) of sporadic and familial chromaffin cell tumours (phaeochromocytomas and paragangliomas). *Front Horm Res* 2004; 31:61–75.
9. Lenders JW, Pacak K, Walther MM, et al. Biochemical diagnosis of pheochromocytoma: which test is best? *JAMA* 2002; 287:1427–1434.
10. Roizen MF, Horrigan RW, Koike M, et al. A prospective randomized trial of four anesthetic techniques for resection of pheochromocytoma. *Anesthesiology* 1982;57:43.
11. Myklejord DJ. Undiagnosed Pheochromocytoma: The Anesthesiologist Nightmare. *Clin Med Res* 2004; 1:59-62.