



## IVIG- Responsive Multiple Cranial Neuropathy: a pharyngo-facial variant of Guillain-Barré Syndrome

Isin UNAL-CEVIK<sup>1</sup>, Mehmet Zulkuf ONAL<sup>1</sup>, Zeki ODABASI<sup>2</sup> and Ersin TAN<sup>3</sup>

<sup>1</sup>Ufuk University, Faculty of Medicine, Department of Neurology, Ankara; <sup>2</sup>Gulhane Military Medical Academy, Department of Neurology, Ankara and <sup>3</sup>Hacettepe University, Faculty of Medicine, Department of Neurology, Ankara, Turkey

### Abstract

We report a case with symptoms of facial swelling, bilateral facial paralysis, dysphagia and aspiration. On electrophysiological studies, the right facial nerve was not excitable. The left facial nerve compound muscle action potential (CMAP) amplitude was severely dispersed and latency was mildly prolonged, consistent with demyelination. Cerebrospinal fluid examinations were normal. Anti-ganglioside antibodies and tumor markers were negative. Bickerstaff brainstem encephalitis, stroke, diabetes mellitus, vasculitis, sarcoidosis, Sjögren's syndrome, Melkersson-Rosenthal Syndrome, trauma, infectious diseases, toxicity, neoplasm, facial onset sensory and motor neuropathy (FOSMN) and other degenerative diseases were excluded. Intravenous immunoglobulin therapy resolved symptoms of lower cranial nerve dysfunction. Clinically incomplete improvement of bilateral facial paralysis was observed. We conclude that IVIg therapy may improve the symptoms of multiple cranial nerve palsies due to pharyngo-facial variant of Guillain-Barré syndrome.

**Key words:** Bilateral facial diplegia; Guillain-Barré syndrome; dysphagia; neuropathy; intravenous immunoglobulin therapy.

### Introduction

Facial diplegia is characterized by loss of voluntary movements of bilateral facial muscles. Although unilateral facial or lower cranial nerve palsies may frequently be seen, multiple cranial neuropathies, involving bilateral facial and lower cranial nerves are rarely reported (Shuaib and Becker, 1987; Spillane *et al.*, 1991). Clinical localization may be due to diseases affecting the supranuclear structures, subarachnoid space, skull base, nuclear lesions, cranial nerves, the neuromuscular junction or the muscle. Usually post-infectious autoimmune diseases such

as Guillain-Barré Syndrome, diabetes mellitus, stroke, vasculitis, neoplasm, trauma, infectious diseases, toxicity, congenital or degenerative diseases may be the cause (Weintraub, 1976; Gorman *et al.*, 1977; Beal, 1990; Keane, 1994).

### Case report

An 82 years old housewife noticed swelling and weakness on her right eyelid and the right side of her face. Within 3 days she noticed the same symptoms on the left hemiface and started to have difficulty swallowing with occasional aspiration. Her medical history disclosed hypothyroidism. She denied any infection or taking any new medication within the last month. On examination she had facial swelling, facial drooping, bilateral ptosis and tongue was fissured. The patient was alert and oriented. Bilateral facial paresis prominent on the right and weakness of bilateral cranial nerves IX and X, with decreased gag reflex and dysarthria was noted. There was no sensory or motor deficit in her extremities. Deep tendon reflexes were normal. There was no pathological reflex. Brain MRI revealed multiple, non-specific, ischemic-gliotic lesions in the periventricular white matter. On electrophysiological studies, sensory potentials were absent in both sural nerves. Sensory nerve conduction velocities were slow in median and ulnar nerves (Table 1a). Distal motor latencies were prolonged and motor nerve conduction velocities were slow. The compound muscle action potential (CMAP) amplitude was low in the right peroneal nerve. The right facial nerve was inexcitable. CMAP amplitude was low in the left facial nerve (Table 1b). The left facial nerve CMAP amplitude was severely dispersed and latency was mildly prolonged (Fig. 1). There was total denervation of the right facial muscles and partial denervation of the left facial muscles.

Table 1a  
Sensory Nerve Conduction Studies

Nerve/Sites	SNAP ( $\mu$ V)	Normal values (antidromic SNAP- $\mu$ V)	CV m/s	Normal values (CV-m/s)
R MEDIAN Digit II-Wrist	15.6	20	34.3	41.3
L MEDIAN-Digit II-Wrist	15.1	20	32.1	41.3
R ULNAR-Digit V-Wrist	4.1	15	30.1	39.3
L ULNAR-Digit V-Wrist	10.4	15	30.6	39.3
R SURAL - Lat Malleolus-calf	NP	8		34.7
L SURAL - Lat Malleolus-calf	NP	8		34.7

CV (m/s): conduction velocity (meter/second), SNAP ( $\mu$ V): sensory nerve action potential (microvolt), NP: no potential, R: right, L: left.

Table 1b  
Motor Nerve Conduction Studies

Nerve/Sites	Latency (ms)	CMAP (mV)	CV m/s	Normal values (Latency-ms)	Normal values (CMAP-mV)	Normal values (CV-m/s)
R MEDIAN- ABP Wrist-Elbow	4.8	3.7	37	3.6	5	50
L MEDIAN- ABP Wrist-Elbow	5.35	4.9	43.1	3.6	5	50
R ULNAR- ADM Wrist- Elbow	4.15	5.9	46.0	2.5	5	50.6
L ULNAR- ADM Wrist- Elbow	3.55	7.6	42.6	2.5	5	50.6
R FACIAL-frontalis 1. Ant Ear	NP			3.1	2.2	
L FACIAL-frontalis 1. Ant Ear	5.15	1.3		3.1	2.2	
R FACIAL - Orb Oculi 1. Ant Ear	NP			3.1	2.2	
L FACIAL - Orb Oculi 1. Ant Ear	3.45	0.8		3.1	2.2	
R FACIAL-orb oris 1. Ant Ear	NP					
L FACIAL-orb oris 1. Ant Ear	4.5	0.7		2.7	3.5	
R COMMON PERONEAL - EDB Ankle- Fib Head	3.40	1.8	40.0	4.78	4	41.6

CMAP (mV): compound muscle action potential (millivolt), CV (m/s): conduction velocity (meter/second), NP: no potential, R: right, L: left. Normal values (Odabasi *et al.*, 1996).

There was chronic partial denervation of the right upper extremity distal muscles (Table 1c). Cerebrospinal fluid studies, performed 3 weeks after symptom onset, were normal. Routine blood tests, ESR, CRP, thyroid function tests, Vit B12, folic acid levels,

blood ACE and urine calcium level were normal. Thorax CT was negative for sarcoidosis. Vasculitis markers, tumor markers, VDRL, HIV, hepatitis, Lyme, Brucella, anti-ganglioside antibodies of anti-GM1, anti-GQ1b and anti-GD1b were negative. Skin

Table 1c  
Needle EMG

	Spontaneous					MUAP			Recruitment
	IA	Fib	PSW	Fasc	H.F.	Amp	Dur	PPP	Pattern
R Frontalis	N	2+	2+	None	None	N	N	N	No activity
R Orb Oculi	N	2+	1+	None	None	N	N	N	No activity
R Orb Oris	N	1+	None	None	None	N	N	N	Discrete
L Frontalis	N	1+	None	None	None	N	N	N	Reduced
L Orb Oculi	N	1+	1+	None	None	N	N	N	Discrete
L Orb Oris	N	None	None	None	None	N	N	N	Discrete
R First Digit Inteross	N	1+	1+	None	None	1+	1+	N	Reduced
R Ext Indicis	N	1+	1+	None	None	N	2+	N	N
R Biceps	N	None	None	None	None	N	N	N	N

IA: Insertional Activity, Fib: Fibrillation, PSW: positive sharp wave, Fasc: Fasciculation, H.F.: High frequency, MUAP: Motor unit action potential, Amp: Amplitude, Dur: duration, PPP: polyphasic potential, R: right, L: left.

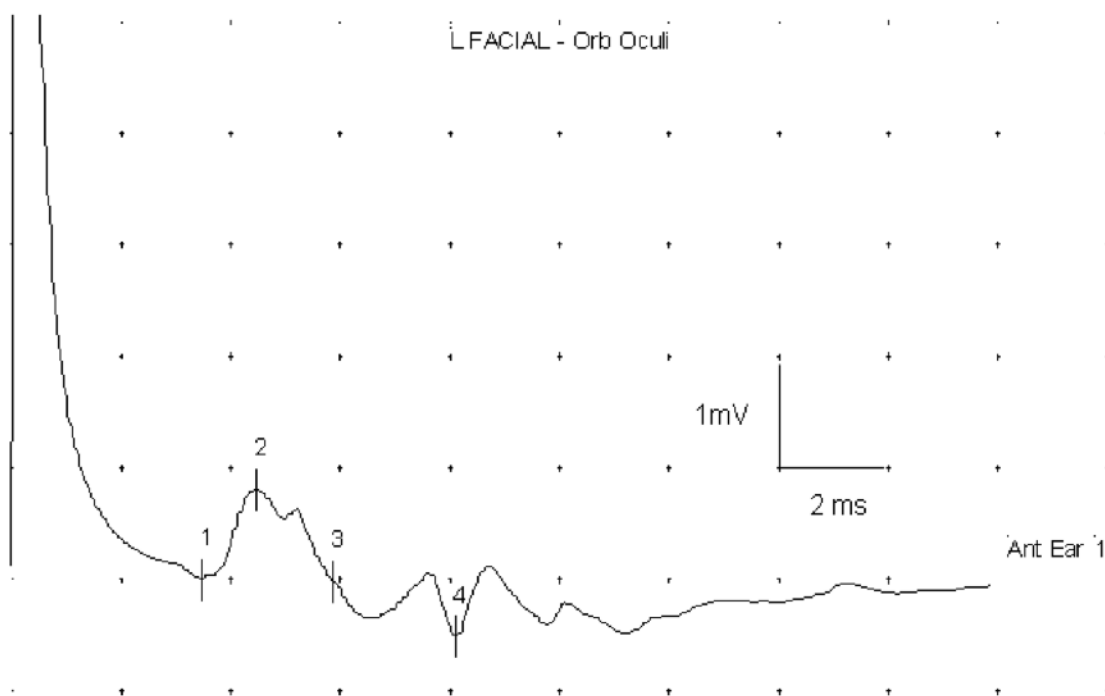


FIG. 1. — After stimulation of the left facial nerve, compound muscle action potential (CMAP) recorded from left orbicularis oculi amplitude is severely dispersed and latency was mildly prolonged, consistent with demyelination. (Scale of time: 2 milliseconds and amplitude: 1 milliVolt).

biopsy from right inferolateral angle of the orbit, revealed actinic (solar) keratosis, without any sign of specific inflammation, neoplasm nor granulomatosis.

The patient was fed enterally through a nasogastric tube. Due to acute onset of symptoms accompanied by demyelination, without any identi-

fiable cause, an immune-mediated process was considered. A five day course of intravenous immunoglobulin (IVIg) 0.4 g/kg/day was given. Two weeks later, she was able to eat foods and drink liquids without aspiration. Her facial diplegia partially responded to IVIg treatment. She was stable for the next 12 months.

## Discussion

Stroke, vasculitis, glial tumors, metastasis, infections, trauma, demyelination, and degenerative disease may produce clinical signs of supranuclear, nuclear or infranuclear involvement. Foix-Chavany-Marie (bi-ocular) syndrome is characterized by faciopharyngoglossomasticatory diplegia (Mariani *et al.*, 1980). Brain MRI of our patient did not display a lesion responsible for the clinical picture. GBS is an acutely evolving areflexic, demyelinating neuropathy with albuminocytologic dissociation. Variants of GBS may include asymmetric, pure motor, prominent sensory, preserved muscle stretch reflexes, pharyngeal-cervical-brachial, paraparetic, facial diplegia with paresthesia, pure sensory neuropathy, pure autonomic neuropathy, Miller-Fisher syndrome, axon loss variants, acute motor axonal neuropathy (AMAN) and acute motor and sensory axonal neuropathy (AMSAN) (Shuaib and Becker, 1987; Sinsawaiwong and Thampanitchawong, 2000; Levin, 2004; Curtis *et al.*, 2008). Isolated cranial nerve involvement without prominent signs of GBS is considered as rare variant of this disease (Dididze, 2009). The cranial, bulbar and sensory variants are usually associated with antibodies to the disialylated gangliosides (Willison and Yuki, 2002; Mas-Lazaro *et al.*, 2008). Bickerstaff's brainstem encephalitis causes motor axonal neuropathy of facial and bulbar muscles, consciousness disturbances, ophthalmoplegia and ataxia (Odaka *et al.*, 2003). Serum anti-GQ1b IgG is usually positive. Our patient had negative antiganglioside antibodies. CSF studies were normal. Contrast-enhanced brain MRI disclosed no sign of inflammation or neoplasm. We excluded the diagnosis of Bickerstaff's brainstem encephalitis, paraneoplastic diseases, diabetes mellitus, vasculitis and infectious diseases.

Melkersson-Rosenthal Syndrome causes facial swelling and facial palsy (Mukherjee and Dongre, 1973). Tongue is often fissured. An unusual case presenting with facial, glossopharyngeal and vagal nerve palsies is reported (Khandpur *et al.*, 2006). Our patient's skin biopsy did not support the diagnosis.

Facial onset sensory and motor neuronopathy (FOSMN) is characterized by paraesthesia and numbness in trigeminal distribution and slowly progressive weakness of head, neck and upper extremities as if a syringomyelia-like syndrome (Vucic *et al.*, 2006; Hokonohara *et al.*, 2008). The presenting feature of all cases was hypoesthesia and paraesthesia in the lower face and mouth. Within 2-6 years, the sensory symptoms progressed to involve entire face, scalp, upper extremities, upper back and chest.

Dysphagia was reported in half of the patients after 5 years of symptom onset. Facial nerve palsy of the lower motor neuron type was seen in one patient. Neurophysiologically generalized sensorymotor neuronopathy of caudally decreasing severity was demonstrated. All patients were treated with immunosuppressive or immunomodulatory therapy without any benefit. This syndrome is considered to be a slowly progressive neurodegenerative disorder (Vucic *et al.*, 2006). Interestingly, Hokonohara *et al.* reported a similar case who partially responded to immunotherapy (Hokonohara *et al.*, 2008). Responses to immunotherapies may be best explained by an immunological mechanism resembling chronic inflammatory demyelinating polyneuropathy (Kokubun and Hirata, 2007; Hokonohara *et al.*, 2008). Our patient only had acute onset of multiple lower cranial nerve palsies without any symptom in the trigeminal nerve, scalp, trunk or upper extremities resembling syringomyelia.

Therapeutic approach in cranial neuropathies is based on the underlying disease. Facial diplegia may affect patient's appearance and has a risk of corneal injury. Bilateral lower cranial nerve dysfunction has the increased risk of aspiration pneumonia, dehydration, electrolyte imbalance and malnutrition. IVIg treatment is a good choice for immune-mediated neuropathies (Nobile-Orazio and Terenghi, 2005). Based on electrophysiological studies and appropriate differential diagnosis, our patient has been treated early with IVIg. We believe that this patient had a pharyngo-facial variant of Guillain-Barré syndrome who responded to IVIg treatment.

## REFERENCES

- Beal MF. Multiple cranial-nerve palsies: a diagnostic challenge. *N Engl J Med.* 1990;322(7):461-463.
- Curtis CE, Barnes EV, Dupiche CA. Guillain-Barre syndrome variant: presenting with myalgias and acute facial diplegia. *Mil Med.* 2008;173(5):507-508.
- Dididze MN. Clinical variants of Guillain-Barre syndrome: some aspects of differential diagnosis. *Georgian Med News.* 2009;(166):48-51.
- Gorman JB, Nagler B, Botton JE. Facial diplegia and its causes. *Va Med.* 1977;104(8):544-546.
- Hokonohara T, Shigeto H, Kawano Y, Ohyagi Y, Uehara M, Kira J. Facial onset sensory and motor neuronopathy (FOSMN) syndrome responding to immunotherapies. *J Neurol Sci.* 2008;275(1-2):157-158.
- Keane JR. Bilateral seventh nerve palsy: analysis of 43 cases and review of the literature. *Neurology.* 1994;44(7):1198-1202.
- Khandpur S, Malhotra AK, Khanna N. Melkersson-Rosenthal syndrome with diffuse facial swelling