

# Giant megacolon caused by anterior displacement of the anus in a 71-year-old woman

Mehdi Farhangian<sup>1</sup>, Hadi Ahmadi-Amoli<sup>2</sup>, Ehsan Rahimpour<sup>2\*</sup>

1. Department of Surgery, Imam Khomeini Hospital Complex, Tehran University of Medical Sciences, Tehran, Iran.

2. Department of Surgery, Sina Hospital, Tehran University of Medical Sciences, Tehran, Iran.

\*Corresponding Author: Ehsan Rahimpour; Email: erahimpour@sina.tums.ac.ir

Published online: 2022-02-12

Cite this article as: Farhangian M, Ahmadi-Amoli H, Rahimpour E. Giant megacolon caused by anterior displacement of the anus in a 71-year-old woman. Front Emerg Med. In press.

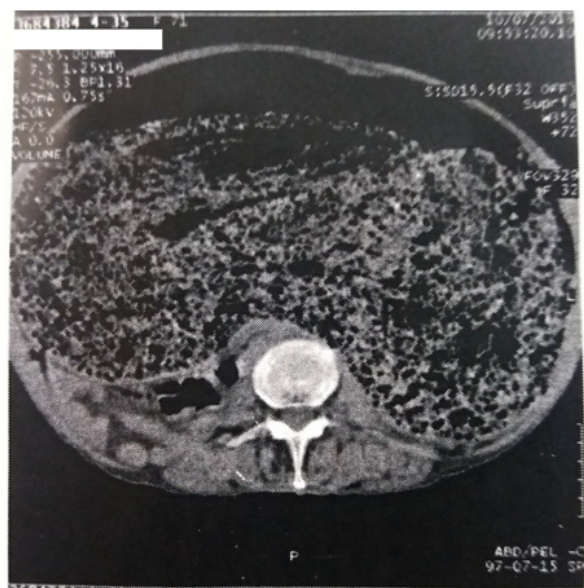
## 1. Case presentation

The patient was a 71-year-old woman who was referred to the general surgery clinic due to a severe colonic dilatation and a fecal mass that was found in her abdominopelvic CT scan, which was ordered by a nephrologist for approaching her right flank pain. The patient had experienced bloating and progressive abdominal distension in the year prior to the current visit. The last defecation had occurred approximately 20 days prior to the visit, and the last gas passage had occurred the day before the visit.

The patient was an abstainer and non-smoker who had been taking omeprazole and levothyroxine regularly for the past ten years for severe gastroesophageal reflux disease (GERD) and hypothyroidism. She also mentioned a history of appendectomy thirty years ago. There was no history of a similar problem in the other two siblings. She had suffered from extreme drug-resistant constipation since childhood. She had received conservative management for her constipation since her adolescence. However, her clinical condition remained unchanged, and the patient still suffered from persistent chronic constipation with episodes of severe diarrhea and fecal incontinence.

The patient's vital signs were stable and she was slightly cachectic. Her abdomen was obviously distended, soft, and without any tenderness. Due to extreme distention, organomegaly could not be assessed, but fecal masses were palpable from the abdominal wall in the left flank and the left lower quadrant of the abdominal region. Bowel sounds were decreased. On percussion, the abdomen was markedly tympanic. On examination of the genitalia, the anal orifice tended to be anterior to the normal position, the distance between the coccyx and the posterior fourchette of the vagina was 14 cm, and the distance between the anal orifice and the posterior fourchette of the vagina was 2 cm (anal position index (API) = 0.14). On rectal inspection, the anal sphincter also appeared normal, and there was fecal impaction in the rectal ampulla. The other organs were normal on examination.

On abdominopelvic CT, she had a severely dilated colon and signs of right kidney atrophy. There was no evidence of extraluminal air, which ruled out bowel perforation (Figure 1).



**Figure 1** Coronal view of Abdominopelvic CT scan; Dilated colon loops with a huge amount of fecal impaction, which completely filled the abdominal cavity

Pre-operative laboratory tests were all reported in normal range.

After general anesthesia, the patient underwent a laparotomy. The colon was severely dilated from the cecum to the rectum, occupying the entire abdominal cavity. The measured diameter of the cecum and transverse colon was greater than 25 cm (Figures 2 and 3), and the intestinal loops were displaced to the upper and posterior parts of the abdominal cavity. The patient underwent total colectomy and end ileostomy. The patient started oral feeding with water on the first day following surgery. The drainage volume of the ileostomy was about 300 ml on the first and second days and was green in color. Due to low hemoglobin on the first day, she also received two packed cells (Hb = 7.4). On the second day, the patient complained of abdominal distension with no tenderness.

Because of the abdominal distension, an abdominopelvic CT

scan was performed on the third day. Imaging revealed a visible pneumoperitoneum and mild free fluid in the abdominal cavity, which could be explained by the procedure she had undergone. Since the patient's general health was satisfactory, no further intervention was ordered and the patient was kept under observation. On the fourth day, the patient presented with ileus. Therefore, a nasogastric (NG) tube was placed, she became NPO, and conservative management was started. As a result of NPO and conservative therapy, the regular amount of ileostomy discharge increased. Finally, the patient was discharged from the hospital on the ninth post-operative day with good health conditions, stable vital signs and tolerance to normal solid diet.

## 2. Learning points

Chronic megacolon is characterized as colonic dilatation of more than 6 cm in one or more segments (1). Giant megacolon (GMC) is a severe form of chronic megacolon that occurs in a very small percentage of the population (2). Chronic constipation is the most common cause of megacolon, but it is unlikely to cause GMC without the presence of mechanical obstruction, congenital defects, or metabolic and endocrine disorders (3). Our aim is to present a case of GMC in a woman in her seventies caused by anterior displacement of the anus (ADA). It should be mentioned that, ADA is known as one of the etiologies of constipation in infants and is often diagnosed in early infancy, but not in elderly. According to the studies on ADA malformation, the average age of the patients rarely exceeds 6 years (4-6). Many believe that delayed diagnosis of anorectal malformations in younger patients is associated with serious complications and morbidities (7, 8), but the anomaly in the present patient was not diagnosed until her eighth decade of life!

Another noteworthy aspect of this case was the extent of the patient's megacolon compared to other adult cases of GMC in adults. We can claim that, this was the largest or one of the largest non-toxic GMCs ever recorded (2, 9).

## 3. Declarations

### 3.1. Acknowledgement

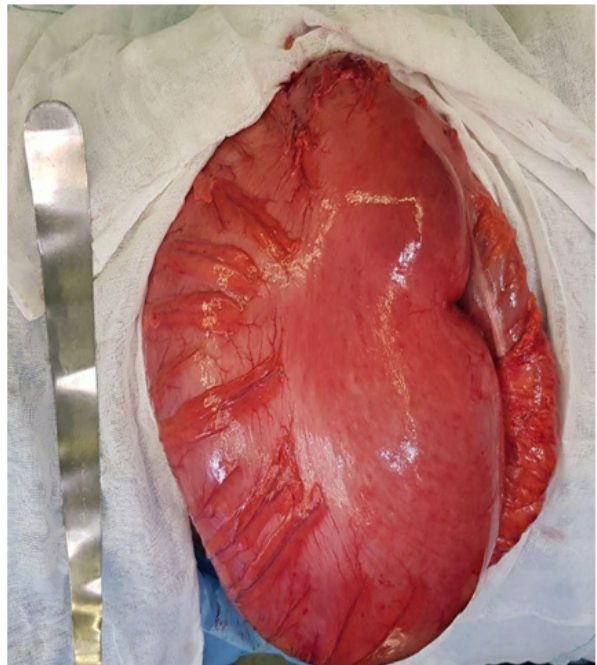
We acknowledge the patient because of her cooperation with us and permission to publish this paper.

### 3.2. Authors' contribution

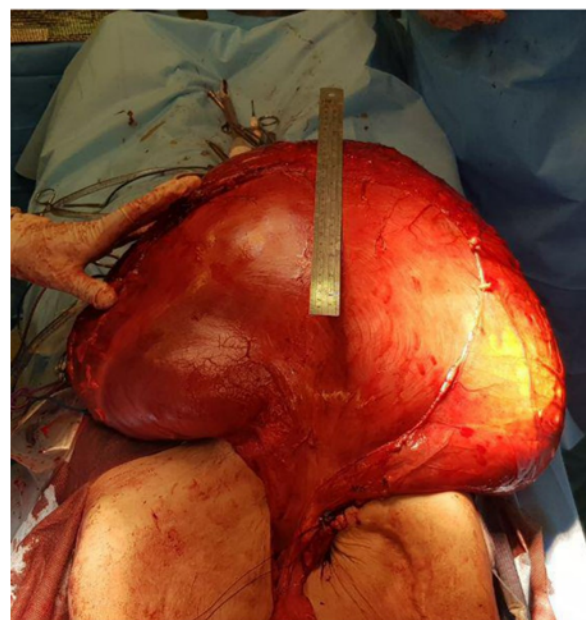
ER and MF interpreted the patient's data regarding the past medical records and physical examinations. All authors cooperated in the patient's operation. MF was the major contributor in writing the manuscript and HA was the supervisor of the project. All authors read and approved the final manuscript.

### 3.3. Conflict of interest

Authors declare no conflicts of interest.



**Figure 2** Giant megacolon with palpable fecal masses after laparotomy



**Figure 3** Giant megacolon with palpable fecal masses after laparotomy. A 50-cm sterile ruler is placed on the colon for comparison

### 3.4. Funding

Authors declare no funding support for this study.

### 3.5. Consent for publication

Written informed consent was obtained from the patient for publication of this case report and any accompanying images.

## References

1. Gan SI, Beck P. A new look at toxic megacolon: an update and review of incidence, etiology, pathogenesis, and management. *Am J Gastroenterol.* 2003;98(11):2363-71.
2. Wojda TR, Yanagawa F, Wallner A, Terzian WH, Smith EA, Stawicki SP, et al. Giant megacolon: An unusual surgical emergency. *Int J Acad Med.* 2017;3(1):194-6.
3. Khawaja MR, Akhavan N, Chiorean M. Chronic constipation with megacolon. *J Gen Intern Med.* 2011;26(8):938.
4. Herek Ö, Polat A. Incidence of anterior displacement of the anus and its relationship to constipation in children. *Surg Today.* 2004;34(2):190-2.
5. Nachulewicz P, Woźniak MM, Brodzisz A (2021) Congenital Abnormalities of the Pelvic Floor: Assessment and Management. In: Santoro GA, Wieczorek AP, Sul-tan AH (eds) *Pelvic Floor Disorders.* Springer, Cham. [https://doi.org/10.1007/978-3-030-40862-6\\_89](https://doi.org/10.1007/978-3-030-40862-6_89).
6. Samuk I, Amerstorfer EE, Fanjul M, Iacobelli BD, Lisi G, Midrio P, et al. Perineal groove: an anorectal malformation network, consortium study. *J Pediatr.* 2020;222:207-12.
7. Lindley RM, Shawis RN, Roberts JP. Delays in the diagnosis of anorectal malformations are common and significantly increase serious early complications. *Acta Paediatr.* 2006;95(3):364-8.
8. Sinha SK, Kanojia RP, Wakhlu A, Rawat J, Kureel S, Tandon R. Delayed presentation of anorectal malformations. *J Indian Assoc Pediatr Surg.* 2008;13(2):64-8.
9. Rajagopal A, Martin J. Giant fecaloma with idiopathic sigmoid megacolon. *Dis Colon Rectum.* 2002;45(6):833-5.