

Frequency of accessory mental foramen and anatomical variability of mental nerve anterior loop in a Peruvian population: A retrospective cone-beam computed tomography study.

Frecuencia de foramen mentoniano accesorio y variabilidad anatómica del asa anterior del nervio mentoniano en una población peruana: estudio retrospectivo de tomografía computarizada de haz cónico.

José Heberth Tofiño-Medina.¹
Luis Ernesto Arriola-Guillén.^{1,2}
Yalil Augusto Rodríguez-Cárdenas.¹
Aron Aliaga-Del Castillo.³
Gustavo Armando Ruíz-Mora.^{1,4}
María Eugenia Guerrero.^{5,1}

Affiliations:

¹Division of Oral and Maxillofacial Radiology, School of Dentistry, Universidad Científica del Sur, Lima, Perú.

²Division of Orthodontics and Division of Oral and Maxillofacial Radiology, School of Dentistry, Universidad Científica del Sur, Lima, Perú.

³Department of Orthodontics, Bauru Dental School, University of São Paulo, Bauru, Brazil.

⁴Division of Orthodontics, Faculty of Dentistry, Universidad Nacional de Colombia, Bogotá D.C, Colombia.

⁵Medico-Surgical Department, Faculty of Dentistry, Universidad Nacional Mayor de San Marcos, Lima, Perú.

Corresponding author: María Eugenia Guerrero. Universidad Nacional Mayor de San Marcos, Calle Germán Amézaga 375, Lima -Perú. Phone: (511) 6197000. **E-mail:** mguerreroac@unmsm.edu.pe

Receipt : 11/11/2019 **Revised:** 05/07/2020
Acceptance: 09/07/2020

Cite as:

Tofiño-Medina JH, Arriola-Guillén LE, Rodríguez-Cárdenas YA, Aliaga-Del Castillo A, Ruíz-Mora GA & Guerrero ME.

Frequency of accessory mental foramen and anatomical variability of mental nerve anterior loop in a Peruvian population: A retrospective cone-beam computed tomography study.

J Oral Res 2020; 9(3):202-211.

Doi:[10.17126/joralres.2020.037](https://doi.org/10.17126/joralres.2020.037)

Abstract: Objective: To evaluate the frequency of accessory mental foramen (AMF) and anatomical variants of the mental nerve anterior loop using cone-beam computed tomography (CBCT) in a Peruvian population.

Material and methods: This retrospective cross-sectional study evaluated 80 hemi-mandibles from 40 subjects using CBCT. The sample included 38 females and 42 males, with an average age of 25 ± 4.45 years. A 3D multi-planar reconstruction was performed to identify the location and presence of accessory mental foramina, their morphological characteristics (oval or circular), their position with respect to the mental foramen (MF), anterior loop (AL) path and other anatomical landmarks including lengths and angles. Statistical analyses included chi square and t-tests. The significance level was $p < 0.05$. **Results:** The frequency of AMF was 17% and the average distance AL-MF was 4.76 ± 1.97 mm. The measurements of the anterior border of AL and MF to the inferior mandibular border showed significant differences according to the sex ($p < 0.001$ and $p = 0.009$, respectively). **Conclusion:** The AMF prevalence was approximately 17%. There is no association between the AMF position and its morphology, sex or side evaluated. The distances from the anterior border of the AL and from the inferior border of the MF to the inferior mandibular border were greater in males. These findings should be considered when planning implant or mini-implant placement in this region.

Keywords: Anatomic landmarks; anatomic variation; cone-beam computed tomography; mandibular nerve; mental foramen; mandible.

Resumen: Objetivo: Evaluar la frecuencia de foramen mentoniano accesorio (AMF) y variantes anatómicas del asa anterior del nervio mentoniano mediante tomografía computarizada de haz cónico (CBCT) en una población peruana.

Material y Métodos: Este estudio transversal retrospectivo evaluó 80 hemimandíbulas de 40 sujetos utilizando CBCT. La muestra incluyó 38 mujeres y 42 hombres, con una edad promedio de $25\pm 4,45$ años. Se realizó una reconstrucción en 3D multiplanar para identificar la ubicación y presencia del foramen mentoniano accesorio, sus características morfológicas (ovaladas o circulares), su posición con respecto al foramen mentoniano (MF), trayectoria del asa anterior (AL) y otros hitos anatómicos incluyendo longitudes y ángulos. Los análisis

estadísticos incluyeron pruebas de chi cuadrado y t de Student. El nivel de significancia fue de $p < 0,05$. **Resultados:** La frecuencia de AMF fue del 17% y la distancia promedio AL - MF fue de $4,76 \pm 1,97$ mm. Las medidas del borde anterior de AL y MF al borde inferior mandibular mostraron diferencias significativas según el sexo ($p < 0,001$ y $p = 0,009$, respectivamente). **Conclusión:** La prevalencia de HMA fue aproximadamente del 17%. No existe asociación entre la posición del AMF y su morfología, sexo o lado evaluado. Las

distancias desde el borde anterior del AL y desde el borde inferior del MF al borde inferior mandibular fueron mayores en los varones. Estos hallazgos deben tenerse en cuenta al planificar la colocación de implantes o mini-implantes en esta región.

Palabra Clave: Puntos anatómicos de referencia; variación anatómica; tomografía computarizada de haz cónico; nervio mandibular; foramen mental; mandíbula.

INTRODUCTION.

The mental foramen (MF) is an important landmark for surgical procedures on the mandibular bone. Its most frequent location is apically to the second lower premolar or between premolar apexes. However, its location may vary in range from lower canine to first molar.¹⁻³

The knowledge of the exact three-dimensional position of the MF with its accessory ducts and possible anatomical variations of the anterior loop (AL) of the mental nerve is essential for the clinician, since any intervention in this area without image exploration, can lead to temporary or permanent injury of the mental nerve.⁴

Due to the overlap and distortion of anatomical structures, and the technical aspects of the acquisition of conventional images, the MF is often not clearly identified, and its linear measurements need to be adjusted. Cone-beam computed tomography (CBCT) is the most effective and accurate radiological diagnostic tool to evaluate and locate the MF.¹⁻⁷

In addition, it provides 1:1 real-time images, and allows measurements at high resolution, low radiation dose and lower cost than conventional CT.⁸

The presence of accessory mental foramen (AMF) has been related to accessory branches of the mandibular nerve (MN). Its prevalence varies according to population,⁴⁻⁷ ranging from 3.92% on dissected adult mandibles to 14.3% on CBCT evaluations. Nerve injury can be very disturbing to the patient, possibly causing mild paresthesia to complete anesthesia.⁹⁻¹¹

Ritter *et al.*,¹⁰ reported loops of the inferior dental nerve in one-third of patients and indicated that the longer the loops, the greater the risk of involvement of the inferior dental nerve is when implants are placed in this area. These considerations reinforce the need to expand the morphological knowledge of this area, taking advantage of CBCT.

Therefore, the objective of this study was to evaluate the frequency of accessory mental foramen and anatomical variants of the anterior loop of the mental nerve using CBCT in a Peruvian population.

MATERIALS AND METHODS.

This retrospective cross-sectional study was approved by the Ethics Committee of the School of Dentistry, Universidad Científica del Sur. The sample was obtained from Peruvian patients who visited the Diagnostic Imaging Center in Lima, Perú during the years 2014-2015, for CBCT assessment, and were referred from different dentistry areas.

For sample calculation, a formula to estimate one mean (distance from the anterior border of the mental nerve loop to the inferior border of the mandible) was used, and was set to 95% confidence level, test power 80%, 0.5mm of precision, 3.88mm of variance, resulting in a minimum sample size of 60 hemi-mandibles.

Therefore, 80 hemi-mandibles from 40 subjects were used. Inclusion criteria were: CBCTs of both sexes, with bilateral presence of all maxillary and mandibular permanent teeth up to the second molars, with Hispanic surnames, and born in Peru, and excluding patients with orthodontic treatment, history of trauma, periapical lesions, tumors, implanted devices or maxillofacial surgery in this region.

Image Acquisition

CBCT images were taken using the Picasso Master 3D equipment (Vatech, Hwaseong, South Korea) with exposure p -values of 8mA and 90 Kv. The patient was correctly positioned with teeth in maximum intercuspation. The DICOM images obtained were processed with PointNixt RealScan 2.0 1.0.4.7 software (Vatech, Hwaseong, South Korea) with a field of view of 20cmx19cm and a voxel resolution of 0.3mm \times 0.3mm \times 0.3mm.

Mental foramen evaluation

The morphological analysis of the MF region was performed with 3D multiplanar reconstruction (MPR) on both sides to find its location (Figure 1A) to observe the presence of accessory foramen, its morphological characteristics (oval or circular), and its position with relation to the MF. For this purpose, eight areas were considered from the sagittal view to the horizontal plane: superior, inferior, postero-superior, postero-medial, postero-inferior, antero-superior, antero-medial and antero-inferior. (Figure 2)

In the vertical plane the landmarks were selected according to the lower teeth axis. The presence of the anterior path of the mental nerve or loop was determined by obtaining images of three orthogonal planes of the MPR in the region of interest, and measurements related to loop position were made on the 3D base with the tools of the PointNixt RealScan 2.0 1.0.4.7 (Vatech, Hwaseong, South Korea) with anatomical landmarks identified in the sagittal, coronal and axial planes. (Table 1 and Figure 3A, 3B and 3C)

Once the AL was located in the MPR, the MF was not displayed in the sagittal plane. Therefore, to define the anatomical point of the anterior border of MF and to

take its horizontal measurement with relation to the MF in this plane, the line of the coronal section was located exactly on the anterior edge of the axial plane. (Figure 1B, Figure 2B, Figure 4, Figure 5A and 5B)

Reliability

Intra-examiner reliability was evaluated with the Kappa index, obtaining values greater than 0.81 for all qualitative parameters (95% confidence interval, 0.810-1.000). Quantitative measurements were evaluated using the intraclass correlation coefficient (ICC), obtaining values greater than 0.90 for all measurements (95% confidence interval, 0.9-0.99).

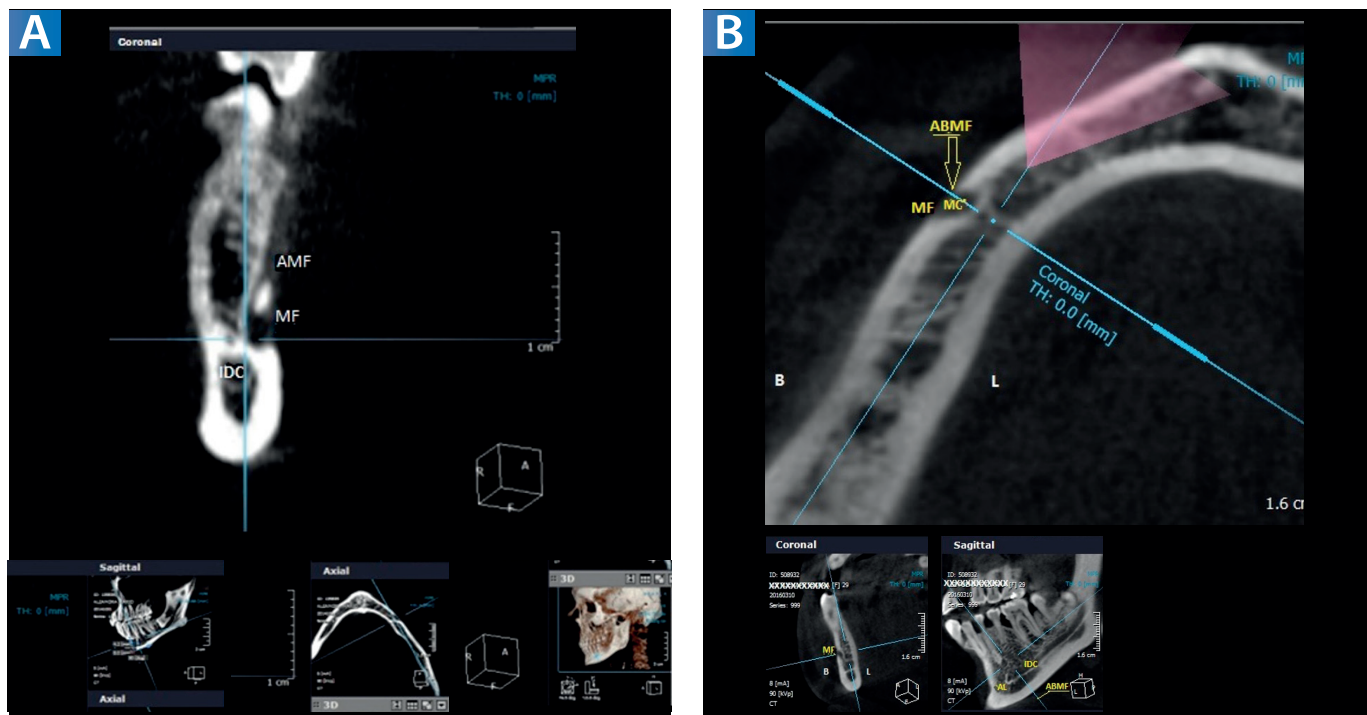
Random error of reproducibility, calculated by Dahlberg's formula was less than 1 for all measurements and repeated with an interval of 4 weeks.

Statistical analysis

Statistical analyses were performed using the SPSS software (Version 23.0; IBM SPSS, Chicago, Ill). Normal distribution was confirmed using the Shapiro-Wilk test. Linear and angular measurements between sex and sides were compared with t-test.

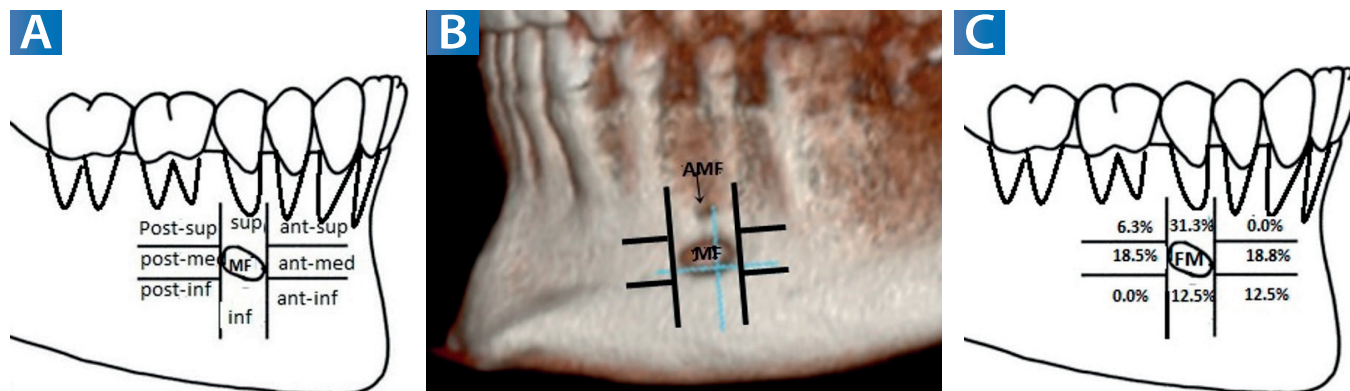
Associations between qualitative variables were evaluated using chi square test. The significance level was set at $p < 0.05$.

Figure 1. 3D multiplanar reconstructions.



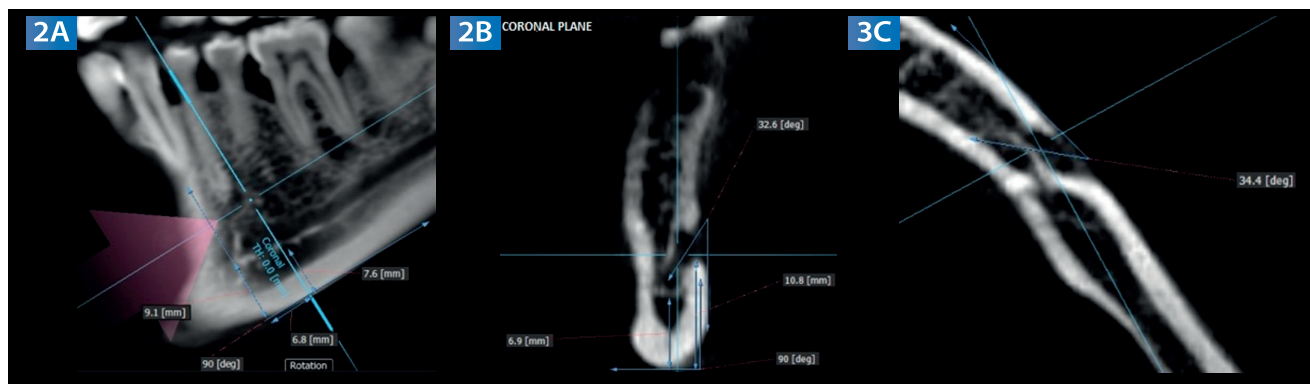
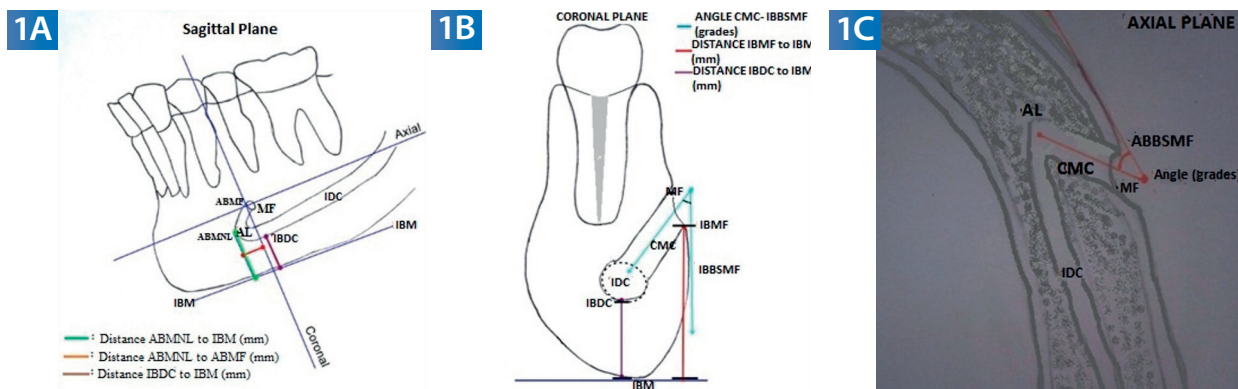
A. Multiplanar reconstruction of accessory foramen findings. Coronal view of an accessory foramen (AMF) in a superior position relative to the mental foramen (MF). IDC, inferior dental canal.
B. Multiplanar reconstruction in the axial plane to locate the anterior border of the mental foramen (ABMF) and refer it to the coronal cut line after the anterior loop (AL) was located in the sagittal plane and the mental foramen (MF) in the coronal plane.

Figure 2. Anatomical reference landmarks for accessory foramina location related to mental foramen (MF).



A. Diagram of 8 landmarks to describe anatomical position of accessory foramina. B. 3D representation illustrating an accessory foramen (AMF) in a superior position to MF (arrow). C. AMF results according to their position with respect to the MF.

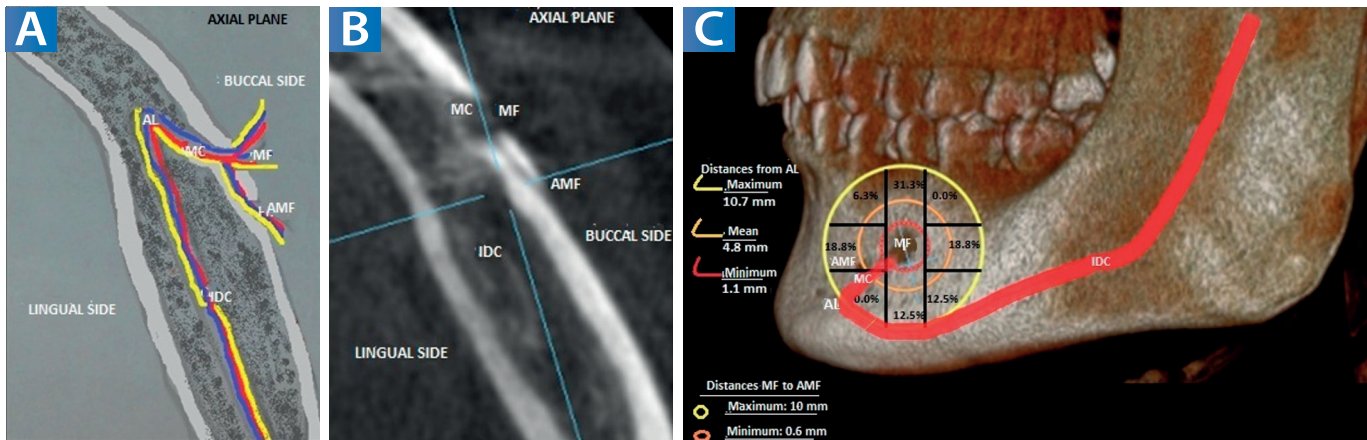
Figure 3. A. Sagittal plane of mental nerve anterior loop position (AL) respect to the mental foramen (MF) and other anatomical landmarks. B. Coronal plane showing IBMF and IBDC distances to IBM and the angle between the IBBSMF and CMC lines. C. Axial plane of the angle between the ABBSMF line and the CMC line.



3.A1. Sagittal diagram of the measurements. 3.A2. Sagittal view measurements. 3.1B. Coronal diagram of the measurements. 3.2B. Coronal view measurements. 3.1C. Axial diagram of the measurements. 3.2C. Axial view measurements.

ABMNL: Anterior border of the mental nerve loop. ABMF: Anterior border of mental foramen. IBM: inferior border of the mandible. IBDC: inferior border of the dental canal. MF: Mental foramen. IBMF: Inferior border of mental foramen. CMC: Center of the mental canal. IBBSMF: Inferior buccal bone surface of the mental foramen. ABBSMF: Anterior buccal bone surface of the mental foramen. AL: Anterior loop.

Figure 4. Diagram illustration of accessory mental foramen (AMF) and mental canal (MC) and associated measurements and anatomical positions.



A. Illustration of accessory mental foramen (AMF) in communication with the mental canal (MC) as its origin with possible neurovascular content. **B.** Axial view of the present study with a finding of AMF posterior to MF. The MC origin can be appreciated. **B.** Measurements of the present AL study relative to MF and percentage of AMF findings according to their anatomical position. Diagram illustration (red, orange and yellow circles) of a safety margin to be taken into account for pre-surgical analysis in this area using previous studies measurements of MF distance to AMF.

Table 1. Definition of the variables evaluated in this study.

Variable	Definition
ABMNL	anterior border of the mental nerve loop.
ABMF	anterior border of mental foramen.
IBM	inferior border of the mandible.
IBDC	inferior border of the dental canal.
IBMF	Inferior border of mental foramen.
IBBSMF	Inferior buccal bone surface of the mental foramen
CMC	Center of the mental canal
ABBSMF	Anterior buccal bone surface of the mental foramen

Table 2. Sample Distribution by sex and age.

		N	Mean	Age		Minimum	Maximum
				SD			
SEX	Males	42	25.38	4.42		16	30
	Females	38	24.63	4.47		15	30
TOTAL		80	25.00	4.45		15	30

Table 3. Association between accessory foramina versus sex and side.

Accessory Foramina	N	%	Males	N	%	Females	N	%	p-value
Missing	66	82.5		33	78.6		33	86.8	0.621
One	11	13.75		7	16.7		4	10.5	
Two	3	3.75		2	4.8		1	2.6	
Total	80	100		42	100		38	100	
			Right side			Left side			
Missing	66	82.5		33	82.5		33	82.5	0.809
One	11	13.75		6	15.0		5	12.5	
Two	3	3.75		1	2.5		2	5.0	
Total	80	100		40	100		40	100	

Table 4. Association between position of accessory foramina and sex or side.

Position	N	%	Males	N	%	Females	N	%	p-value
Superior	5	31.3		4	40.0		1	16.6	
Inferior	2	12.5		1	10.0		1	16.6	
Antero-superior	0	0.0		0	0.0		0	0.0	
Antero-medial	3	18.8		2	20.0		1	16.6	
Antero-inferior	2	12.5		1	10.0		1	16.6	0.601
Postero-superior	1	6.3		1	10.0		0	0.0	
Postero-medial	3	18.8		1	10.0		2	33.3	
Postero-inferior	0	0.0		0	0.0		0	0.0	
Total	16	100		10	100		6	100	
			Right side			Left side			
Superior	5	31.3		2	25.0		3	37.5	
Inferior	2	12.5		0	0.0		2	25.0	
Antero-superior	0	0.0		0	0.0		0	0.0	
Antero-medial	3	18.8		2	25.0		1	12.5	
Antero-inferior	2	12.5		2	25.0		0	0	0.353
Postero-superior	1	6.3			0.0		1	12.5	
Postero-medial	3	18.8		2	25.5		1	12.5	
Postero-inferior	0	0.0		0	0.0		0	0.0	
Total	16	100		8	100		8	100	

Table 5. Association between accessory foramina morphology of and sex or side.

Accessory foramen morphology	N	%	Males	N	%	Females	N	%	p-value
Round	9	56.3		6	60.0		3	50.0	
Oval	7	43.7		4	40.0		3	50.0	0.577
Total	16	100		10	100		6	100	
			Right side			Left side			
Round	9	56.3		5	62.5		4	50.0	
Oval	7	43.7		3	37.5		4	50.0	0.593
Total	16	100		8	100		8	100	

RESULTS.

The initial characteristics of the sample according to sex and age are summarized. (Table 2)

The total incidence of AMF was 17.0% (25.0% in males and 13.1% in females). However, these differences were not statistically significant ($p=0.621$). Table 3

Side differences were not statistically significant ($p=0.809$). No associations were found between the AMF position, sex and side. (Table 4 and Table 5)

Summarizes the measurements related to the mental

nerve AL position respect to the mental foramen and other anatomical landmarks, according to sex and side. (Table 6)

The distance from the anterior border of the mental nerve loop (ABMNL) to the inferior border of the mandible (IBM) and the distance from the inferior border of the mental foramen (IBMF) to the inferior border of the mandible (IBM) were greater in men ($p<0.001$ and $p=0.009$, respectively). The remaining measurements showed no significant differences.

Table 6. Evaluation of the anterior loop position of the mental nerve in relation to the mental foramen and other anatomical points according to sex and side.

Condition	Measurements	N	Mean	SD	Minimum	Maximum	p-value
Males	Distance ABMNL to ABMF	42	4.76	1.97	1.10	10.70	0.793
	Distance ABMNL to IBM	42	11.41	1.89	7.20	14.9	<0.001*
	Distance IBDC to IBM	42	8.57	2.24	5.00	13.20	0.536
	Distance IBMF to IBM	42	14.10	2.07	9.50	18.70	0.009*
	IBBSMF Angle and Coronal CMC	42	48.59	16.43	21.60	88.20	0.539
	ABBSMF angle and axial CMC	42	34.21	9.90	19.50	65.30	0.627
Females	Distance ABMNL to ABMF	38	4.87	1.71	1.40	8.10	
	Distance ABMNL to IBM	38	9.93	1.19	7.30	13.10	
	Distance IBDC to IBM	38	8.29	1.71	5.80	11.50	
	Distance IBMF to IBM	38	12.97	1.58	10.60	16.50	
	IBBSMF Angle and Coronal CMC	38	50.79	15.25	25.90	77.80	
	ABBSMF angle and axial CMC	38	33.14	9.69	15.20	53.50	
Right side	Distance ABMNL to ABMF	40	5.02	2.08	1.10	10.70	0.302
	Distance ABMNL to IBM	40	10.48	1.70	7.20	14.60	0.249
	Distance IBDC to IBM	40	8.40	2.02	5.00	11.90	0.872
	Distance IBMF to IBM	40	13.60	1.73	9.50	18.20	0.882
	IBBSMF Angle and Coronal CMC	40	48.52	14.95	25.90	78.70	0.531
	ABBSMF angle and axial CMC	40	32.28	9.16	15.20	54.70	0.194
Left side	Distance ABMNL to ABMF	40	4.00	1.56	1.70	7.90	
	Distance ABMNL to IBM	40	10.94	1.79	7.30	14.90	
	Distance IBDC to IBM	40	8.47	1.99	5.20	12.80	
	Distance IBMF to IBM	40	13.53	2.13	10.50	18.70	
	IBBSMF Angle and Coronal CMC	40	50.75	16.76	21.60	88.20	
	ABBSMF angle and axial CMC	40	35.13	10.23	18.30	65.30	

ABMNL: anterior border of the mental nerve loop. **ABMF:** anterior border of mental foramen. **IBM:** inferior border of the mandible. **IBDC:** inferior border of the dental canal. **IBMF:** Inferior border of mental foramen. **IBBSMF:** Inferior buccal bone surface of the mental foramen. **CMC:** Center of the mental canal. **ABBSMF:** Anterior buccal bone surface of the mental foramen. **SD:** Standard deviation.

DISCUSSION.

The objective of this study was to evaluate the characteristics of the AMF and anatomical variants of the AL of mental nerve, using CBCT. Specifically, the prevalence of AMF, its location and shape, as well as the evaluation of the distances between MF, the AL of the mental nerve and the adjacent anatomical reference landmarks were evaluated.

Accessory mental foramen (AMF)

In the present study, the prevalence of AMF was 17.0%, higher than the prevalence found in similar studies on Caucasians.⁶ The difference could be related to ethnic variation since the present study evaluated a Latin-American population. Regarding the position of the AMF

in relation to MF, the superior area was the most frequent (31.3%), followed by the antero-medial and postero-medial areas (18.8%), and a smaller proportion in the inferior and antero-inferior areas (12.5%). It is important to emphasize the absence of AMF in the antero-superior and postero-inferior areas in this sample.

Otherwise, Naitoh *et al.*,⁷ reported higher AMF findings in the antero medial region. However, the areas of absence coincide with the ones reported in this study.

Iwanaga *et al.*,¹² reported that the AMF is commonly found in the posterior region, but is in agreement with the low incidence in the postero-inferior area, as well.

It has been reported in anatomical studies that the AMF may be compressed by a neurovascular package, or by an

isolated nerve or artery, and greater openings tend to be located anterior or superior and proximal to the mental foramen when an artery is usually found, whereas smaller openings tend to be located more superior and distal to the MF.⁶ Studies that measured the distances between MF and AMF show ranges from 0.67mm to 10.0mm.^{7,11}

In this study, associations between the AMF prevalence, position and morphology, according to sex and side were not significant, as reported in previous studies.^{6,7} In general, AMFs are unilateral and are evident in single, double or triple forms.

Bilateral AMFs frequency has been reported between 6.0-8.0%.^{13,14} In the present study, one bilateral case and three unilateral double foramen cases were found.

Mental nerve anterior loop

When the inferior alveolar nerve arises in the anterior part of the mandible within the inferior mandibular canal and extends backwards, up and out to open in the MF, it is known as the anterior loop (AL).¹⁵ Other authors describe it as a mental neuronal bundle that crosses below and in front of the MF to bend and return in the way-out direction of the MF.

However, Jalbout *et al.*,¹⁶ described it as an anterior extension of the inferior alveolar nerve, overpassing the MF limit before going back and forward through the mental channel (MC). This description is in agreement with the one observed in the present study, in which the IDC goes down and in front of the MF, to bend and return in a posterior, superior and lateral direction to the same MF in 100% of the cases.

However, this finding does not coincide with Neiva *et al.*,¹⁷ research on a Caucasian population, who found its presence in 88% of the cases. Li *et al.*,¹⁸ used helical computed tomography and found a prevalence of 83.1% of AL in a Chinese population. Uchida *et al.*,¹⁹ reported a 71% prevalence on 140 Japanese hemi-mandibles.

Von Arx *et al.*,² reported its presence in 70.1% of cases. Filo *et al.*,²⁰ studied a Swiss population and reported a prevalence of 69.7%. De Oliveira-Santos *et al.*,²¹ reported a low frequency of AL (22%) on 100 cases analyzed by CBCT, but their visualization was not clear in 11% of the cases. All previous reports and the results of the present study demonstrate a great variability regarding the presence of the anterior loop of the mental nerve in different populations. Distances of the AL path have been reported in ranges from 0.0mm to 11.0mm.^{5,17,19,21-23}

Our findings (4.76 mm) are similar to those of Neiva

et al.,¹⁷ (4.13 mm), but are different from the values reported on a Brazilian population by Rosa *et al.*,²⁴ and Rodrigues *et al.*,²⁵ who found an average length of 2.41 mm and 3.14 mm respectively.

These differences are common in the literature and can be attributed to the application of different methodologies and the lack of a clear and specific definition of AL.²¹

Studies on cadavers have been questioned because the AL was identified by inserting probes through the MF, which can be introduced into the anterior continuity of the mandibular canal, on the mandibular incisive canal.²

Distance from ABMNL to IBM

In this study, the distance between the anterior border of the mental nerve loop and the inferior border of the mandible (IBM) was larger in males (11.41mm) than in females (9.93mm). This confirms the expected differences between sexes on mandibular skeletal sizes. This aspect can be interpreted as a dimorphic feature. Unfortunately, there are no studies reporting this measure to compare or discuss with. Therefore, this should be investigated in future studies.

Distance from IBMF to IBM

The results of the present study coincide with von Arx *et al.*,² and Kalender *et al.*²⁶ This distance did not differ between sides, but was significantly greater in males (14.10mm) than in females (12.97mm). In cadaver studies, mean values ranged from 12mm to 15.6mm; however, some studies used the center of the MF instead of its lower margin as a landmark for the measurement.^{2,17}

Distance of IBDC to IBM

In these measurements on the vertical axis of the MF, no significant differences on sex and side were found, as reported in previous studies. The two previous measurements have surgical importance because it confirms that the inferior mandibular canal (IMC) usually courses below the MF, passes forward and then returns to form the mental nerve anterior loop to become the mental canal (MC) with posterior, superior and external direction to the same MF.

Mental canal angles in the coronal and axial planes

In the CBCT coronal plane the average of the angle formed between the center of the mental canal (CMC) and the inferior buccal bone surface of the MF (IBBSMF) was 49.69° indicating an ascending path; the average in the axial plane was 33.67° which shows a posterior direction and confirms its posterior-superior trajectory within the mandible, before emerging to the MF.

These results were similar to those reported by von

Arx *et al.*² However, it is important to clarify that in their study the buccal side to define this angle was the upper one in the coronal plane and the posterior buccal side in the axial plane. No significant differences were found in the evaluation according to sex and side. In the present study angular measurements of all the mental canals that leave the MF showed an ascending path course in the coronal plane and posterior-superior path in the axial plane.

The study of the mesial extension of the mental nerve AL and the prevalence of AMF has great clinical relevance mainly for dental implantology, for the evaluation of bone volume available for the insertion of implants; and in orthodontics when the use of mini implants in the anterior region of the mandible is planned.

Therefore, the anatomical variability on the MF peripheral area should be taken into account for treatment planning and to maintain a margin of safety. For this purpose, CBCT is the most reliable method of previous evaluation.

Differences in the prevalence of mental nerve AMF and AL may be related to ethnic and geographic variability, and as well to different methodologies selection.

CONCLUSION.

A AMF was present approximately in 17% of the studied population. There is no association between the AMF position or its morphology, *versus* sex or side evaluated. The distance from the AL anterior border and from the MF inferior border to the inferior mandibular border was greater in males. These results should be considered when implants or mini-implants are to be placed in this region.

Conflict of interests: The authors declare that they have no conflict of interest.

Ethics approval: Approved by the Ethics Committee of the School of Dentistry, Universidad Científica del Sur, Lima, Perú.

Funding: Self-financed.

Authors' contributions: All the authors of this manuscript participated in its preparation.

Acknowledgements: None.

REFERENCES.

1. do Carmo Oliveira M, Tedesco TK, Gimenez T, Allegrini S Jr. Analysis of the frequency of visualization of morphological variations in anatomical bone features in the mandibular interforaminal region through cone-beam computed tomography. *Surg Radiol Anat.* 2018;40(10):1119-31.
2. Von Arx T, Friedli M, Sendi P, Lozanoff S, Bornstein MM. Location and dimensions of the mental foramen: a radiographic analysis by using cone beam computed tomography. *J Endod.* 2013;39(12):1522-8.
3. Panjnoush M, Rabiee ZS, Kheirandish Y. Assessment of Location and Anatomical Characteristics of Mental Foramen, Anterior Loop and Mandibular Incisive Canal Using Cone Beam Computed Tomography. *J Dent.* 2016;13(2):126-32.
4. Chen Z, Chen D, Tang L, Wang F. Relationship between the position of the mental foramen and the anterior loop of the inferior alveolar nerve as determined by cone beam computed tomography combined with mimics. *J Comput Assist Tomogr.* 2015; 39(1):86-93.
5. Prados-Frutos JC, Salinas-Goodier C, Manchón Á, Rojo R. Anterior loop of the mental nerve, mental foramen and incisive nerve emergency: tridimensional assessment and surgical applications. *Surg Radiol Anat.* 2017;39(2):169-75.
6. Iwanaga J, Watanabe K, Saga T, Tabira Y, Kitashima S, Kusakawa J, et al. Accessory mental foramina and nerves: Application to periodontal, periapical, and implant surgery. *Clin Anat.* 2016;29(4):493-501.
7. Naitoh M, Hiraiwa Y, Aimiya H, Gotoh K, Ariji E. Accessory mental foramen assessment using cone-beam computed tomography. *Oral Surg Oral Med Oral Pathol Oral Radiol Endod.* 2009;107(2):289-94.
8. Prados-Frutos JC, Salinas-Goodier C, Manchón Á, Rojo R. Anterior loop of the mental nerve, mental foramen and incisive nerve emergency: tridimensional assessment and surgical applications. *Surg Radiol Anat.* 2017;39(2):169-75.
9. Sahl E, Alqahtani A, Alqahtani NM, Gallez F. Partial Explantation of Failed Dental Implants Placed in Mandibular Canal: A Case Report. *J Oral Implantol.* 2018;44(6):456-61.
10. Ritter L, Neugebauer J, Mischkowski RA, Dreiseidler T, Rothamel D, Richter U, et al. Evaluation of the course of the inferior alveolar nerve in the mental foramen by cone beam computed tomography. *Int J Oral Maxillofac Implants.* 2012;27(5):1014-21.
11. Sener E, Onem E, Akar GC, Govsa F, Ozer MA, Pinar Y, Mert A, Baksi Sen BG. Anatomical landmarks of mandibular interforaminal region related to dental implant placement with 3D CBCT: comparison between edentulous and dental mandibles. *Surg Radiol Anat.* 2018;40(6):615-623.
12. Iwanaga J, Saga T, Tabira Y, Nakamura M, Kitashima S, Watanabe K, Kusakawa J, Yamaki K. The clinical anatomy of accessory mental nerves and foramina. *Clin Anat.* 2015;28(7):848-56.
13. de Oliveira-Santos C, Souza PH, De Azambuja Berti-Couto S, Stinkens L, Moyaert K, Van Assche N, Jacobs R. Characterization of additional mental foramina through cone beam computed tomography. *J Oral Rehab.* 2011;38(8):595-600.
14. Sekerci AE, Sisman Y. Bilateral accessory mental foramina and canals: Report of an extremely rare anatomical variation. *J Dent Implant.* 2014;4:101-4.
15. Kuzmanovic DV, Payne AG, Kieser JA, Dias GJ. Anterior loop of the mental nerve: a morphological and radiographic study. *Clin Oral Implants Res.* 2003;14(4):464-71.
16. Jalbout Z, Tabourian G. *Glossary of Implant Dentistry.* Upper Montclair, NJ: International Congress of Oral Implantologists; 2004:16.95.
17. Neiva RF, Gapski R, Wang HL. Morphometric analysis of implant-related anatomy in Caucasian skulls. *J Periodontol.* 2004;75(8):1061-7.
18. Li X, Jin ZK, Zhao H, Yang K, Duan JM, Wang WJ. The prevalence, length and position of the anterior loop of the inferior alveolar nerve in Chinese, assessed by spiral computed tomography. *Surg Radiol Anat.* 2013; 35(9): 823-30.
19. Uchida Y, Noguchi N, Goto M, Yamashita Y, Hanihara T, Takamori H, Sato I, Kawai T, Yosue T. Measurement of anterior loop length for the mandibular canal and diameter of the mandibular incisive canal to avoid nerve damage when installing endosseous implants in the interforaminal region: a second attempt introducing cone beam computed tomography. *J Oral Maxillofac Surg.* 2009;67: 744-50.
20. Filo K, Schneider T, Locher MC, Kruse AL, Lübbers HT. The inferior alveolar nerve's loop at the mental foramen and its implications for surgery. *J Am Dent Assoc.* 2014;145: 260-9.
21. de Oliveira-Santos C, Souza PH, de Azambuja Berti-Couto S, Stinkens L, Moyaert K, Rubira-Bullen IR, et al. Assessment of variations of the mandibular canal through cone beam computed tomography. *Clin Oral Investig.* 2012;16(2): 387-93.
22. Kuzmanovic DV, Payne AG, Kieser JA, Dias GJ. Anterior loop of the mental nerve: a morphological and radiographic study. *Clin Oral Implants Res.* 2003;14(4): 464-71.
23. Uchida Y, Yamashita Y, Goto M, Hanihara T. Measurement of anterior loop length for the mandibular canal and diameter of the mandibular incisive canal to avoid nerve damage when installing endosseous implants in the interforaminal region. *J Oral Maxillofac Surg.* 2007;65(9): 1772-9.
24. Rosa MB, Sotto-Maior BS, Machado V de C, Francischone CE. Retrospective study of the anterior loop of the inferior alveolar nerve and the incisive canal using cone beam computed tomography. *Int J Oral Maxillofac Implants.* 2013;28(2): 388-92.
25. Rodrigues P, de Holanda RJ, de Oliveira BP, Golcalves BC, da Cruz NC. Analysis of anatomical landmarks of the mandibular interforaminal region using CBCT in a Brazilian population. *Braz. J Oral Sci.* 2014;13: 4-12.
26. Kalender A, Orhan K, Aksoy U. Evaluation of the mental foramen and accessory mental foramen in Turkish patients using cone-beam computed tomography images reconstructed from a volumetric rendering program. *Clin Anat.* 2012;25(5):584-92.