

# We are IntechOpen, the world's leading publisher of Open Access books Built by scientists, for scientists

5,800

Open access books available

142,000

International authors and editors

180M

Downloads

Our authors are among the

154

Countries delivered to

TOP 1%

most cited scientists

12.2%

Contributors from top 500 universities



WEB OF SCIENCE™

Selection of our books indexed in the Book Citation Index  
in Web of Science™ Core Collection (BKCI)

Interested in publishing with us?  
Contact [book.department@intechopen.com](mailto:book.department@intechopen.com)

Numbers displayed above are based on latest data collected.  
For more information visit [www.intechopen.com](http://www.intechopen.com)



# Paranasal Sinuses Anatomy and Anatomical Variations

*Hardip Singh Gendeh and Balwant Singh Gendeh*

## Abstract

Anatomical variations of the sinuses are common and may lead to obstruction to the ventilation and drainage of the sinuses. This may lead to osteomeatal complex disease refractory to medications. A preoperative CT of the paranasal sinuses acts as road map guide to identify vital anatomical variations and its relationship to the orbit, skull base, neurological and vascular structures, to prevent iatrogenic injuries. To control intraoperative bleeding, it is critical to identify the anterior and posterior ethmoidal artery indentations and sphenopalatine artery in the anterior and lateral nasal walls. It is essential for the surgeon to familiarize with the anatomy of the ethmoid region, lateral nasal wall, sphenoid sinus, sella and parasellar region and pterygopalatine/infratemporal fossa before embarking on these approaches. The advent of CT scans and state-of-the-art FESS instrumentation has made surgery of the paranasal sinuses less of a mystery for the surgeon. Therefore, identifying and addressing these anatomical variations during FESS is crucial in restoring ventilation and drainage.

**Keywords:** paranasal sinus, anatomy, anatomical variations, endoscopic surgery

## 1. Introduction

The birth of Endoscopic Sinus Surgery (ESS) in the early 1900 in Graz, Austria, under the teachings of Messerklinger has led to an understanding of the drainage of the paranasal sinuses. Messerklinger introduced the world to tailored endoscopic sinus surgery owing to his work in the frontal recess and ethmoidal infundibulum for drainage of sinuses [1, 2]. This was then popularized by Stammberger and Kennedy with the term functional endoscopic sinus surgery (FESS) being introduced. FESS involves ventilating and draining of the sinuses with preservation of the mucosa [3]. In the advent of FESS, nasal radiograph was constrained in identifying anatomical variations of the sinuses and paranasal sinuses. The use of high-resolution computed tomography (CT) scans with 2–3 millimeters slices has allowed for better spatial resolution of the anatomical structures.

Prior to performing an ESS, one must obtain a high-resolution CT of the sinuses and paranasal sinuses for diagnosis and to identify anatomical variations present, both of which are essential for surgical planning. This is useful to direct the course of the endoscopic operation in relieving obstructions and drainage of the sinuses. The surgeon will also become aware of anatomical variations such as a low-lying base of skull to prevent iatrogenic injuries, reduce complications, and avoid failure of surgery. Coronal images are particularly important and give information of the vast anatomy of the paranasal sinuses.

Prior to leaping into the radiological images of such variations, one must first understand the development of the sinuses to appreciate the acceptable differences between a pediatric and adult sinus. Both the maxillary and ethmoidal sinuses are present at birth. The maxillary sinuses reach adult size by 15 years, while the ethmoidal sinuses are earlier at 12 years. The maxillary sinus can be appreciated radiologically at several months after birth and ethmoidal later at approximately 12 months [4]. The frontal and sphenoid sinuses are not present and begin development after birth. The frontal sinuses invaginate into the frontal recess from the age of 4 and continues to expand until the age of 20. The sphenoid sinus attains its full size by 15 years [4].

These anatomical variations may obstruct the drainage and ventilation of the sinuses resulting in sinusitis with or without headaches [5]. Anatomical variations of the middle meatus such as paradoxical middle turbinate, pneumatization and Haller's cells are the most common. This may lead to osteomeatal complex (OMC) diseases and will be required to be addressed if symptoms are persistent. O'Brien et al. 2016 have suggested a mnemonic CLOSE: cribriform plate, lamina papyracea, onodi cell, sphenoid sinus pneumatization, and ethmoidal artery (anterior) for critical structures that are often overlooked and underreported [6].

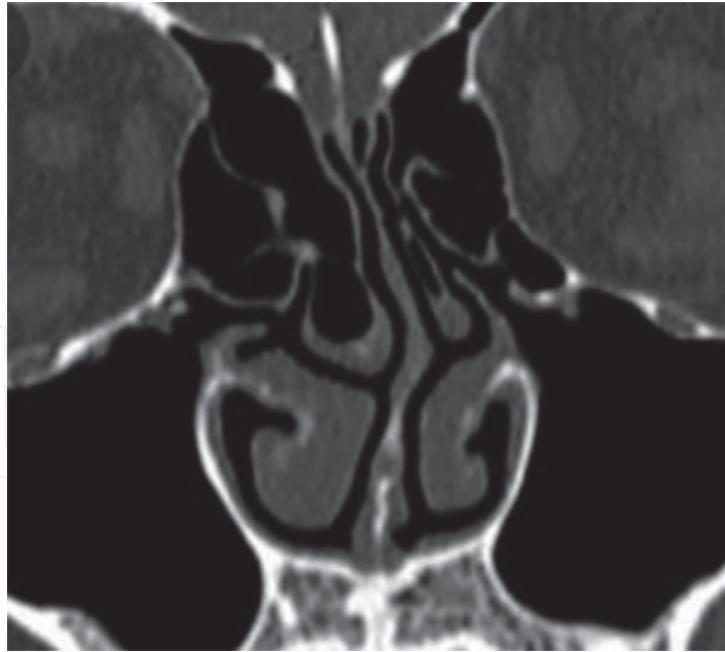
Variations in anatomy are more of a rule than an exception. Nature has customized different anatomies for every individual. Therefore, one must be aware of these possible variations before any surgical interventions. Air in the nose and paranasal sinuses acts as natural contrast; therefore, CT scan in bone and soft tissue windows is sufficient to diagnose anatomical variations and pathology in most cases of chronic rhinosinusitis. Although useful for a quick identification of pertinent variations, this chapter will introduce you to further variations that one may encounter when dealing with the sinuses and paranasal sinuses.

## **2. Nasal septum**

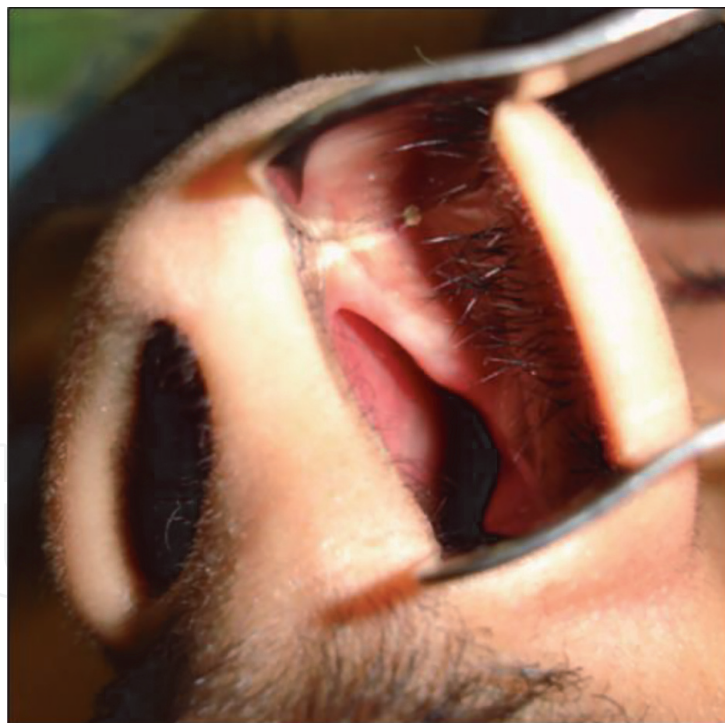The nasal septum forms the medial wall and separates the left and right nasal cavities, respectively. It also provides projection to the nose. It consists of three parts being the anterior cartilaginous septum formed by the quadrangular cartilage; posterior perpendicular plate of the ethmoid consisting of the perpendicular plate of ethmoid and vomer; and the most anterior membranous septum in between the quadrangular cartilage and the columella [7].

### **2.1 Nasal septal deviation**

A deviated septum refers to a septal divergent from the midline (**Figure 1**). In general terms, an anterior deviation refers to the cartilaginous septum, while posterior involves the bony septum. Deviated nasal septum may cause compression and lateralization of the ipsilateral middle turbinate, often obstructing the ipsilateral OMC (**Figure 1**). This may lead to OMC disease causing obstruction to the drainage of the frontal, maxillary, and anterior ethmoidal sinus. Septal deviations may occur up to 36 and 4% of births having anterior cartilage deformity believed to be due to maxillary molding from pressure exerted within the birth canal [8, 9]. Shpilberg et al. 2014 reported 98.4% of 192 patients had a deviated nasal septum but 61.4% had a deviation more than minimal [10]. Hence, it is a common entity. The septum may be kinked to form a septal spur. Prominent septal spurs may have a dry mucosa and bleed due to increased surface area exposed to airflow. Some patients may have a mild deviation and are asymptomatic, while some may be symptomatic. Pathology

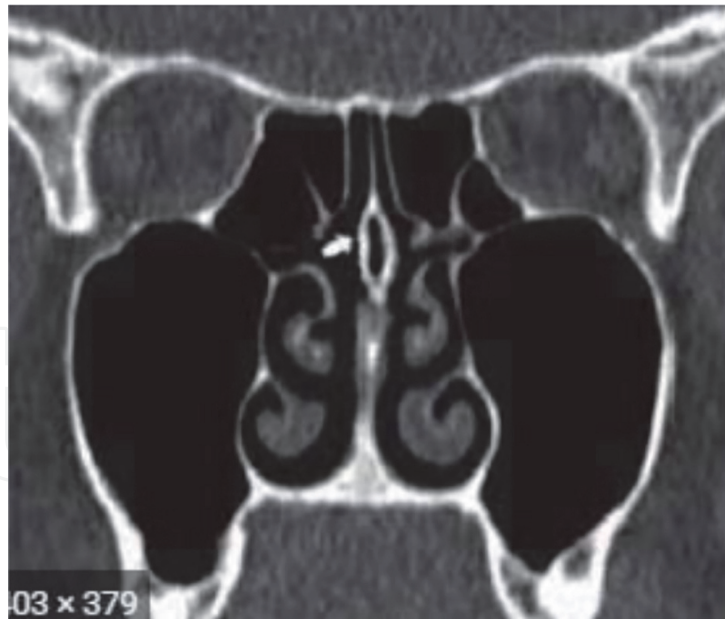

**Figure 1.**  
*A coronal view of CT of the paranasal sinus demonstrating a deviated left membranous nasal septum resulting in a hypoplastic left middle turbinate. The left middle turbinate is also pushed laterally and appears to be obstructing the left OMC. The contralateral right inferior turbinate is hypertrophied and larger than the left due to the larger right nasal cavity.*



**Figure 2.**  
*Photograph showing an exposed anatomy of the normal nasal valve using thudicum's forceps. The nasal valve is boundary by the septum (medial), pyriform aperture (superior), upper lateral cartilage (lateral) and nasal floor (inferior).*

in the nasal valve region (**Figure 2**) determines whether the patient will benefit from open (rhinoplasty) or closed septoplasty. Anterior nasal septal deviation involving the nasal valve causes valve collapse and airflow obstructions. These cohorts of patients will often benefit from a septorhinoplasty with a valve reconstruction [11].



**Figure 3.**  
*A pneumatized cartilaginous nasal septum (white arrow) with surrounding calcification.*

## 2.2 Pneumatized nasal septum

Pneumatization of the nasal septum is a rare entity (**Figure 3**). It may be due to trauma resulting in splitting of the cartilaginous or bony septum with a space in between. It may occur together with a nasal septal osteoma. It can be easily confused with a septal turbinate or septal polyp also known as *intumescentia septi nasi anterior*, which is a septal mucosal inflammation appreciated on endoscopic examination [12, 13]. Some have also referred to it as a pneumatized septal turbinate. It can be corrected with a septoplasty if there is significant obstruction.

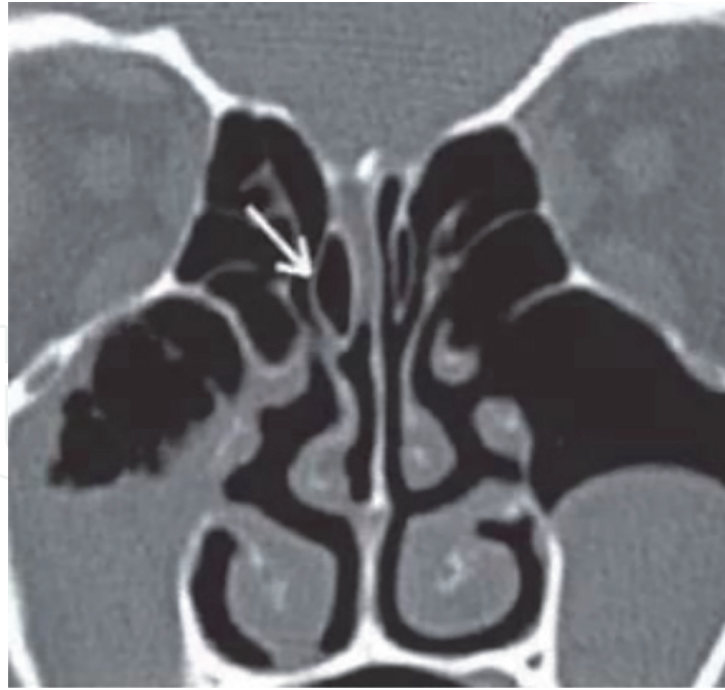
## 3. Nasal turbinates

### 3.1 Hypoplasia of nasal turbinates

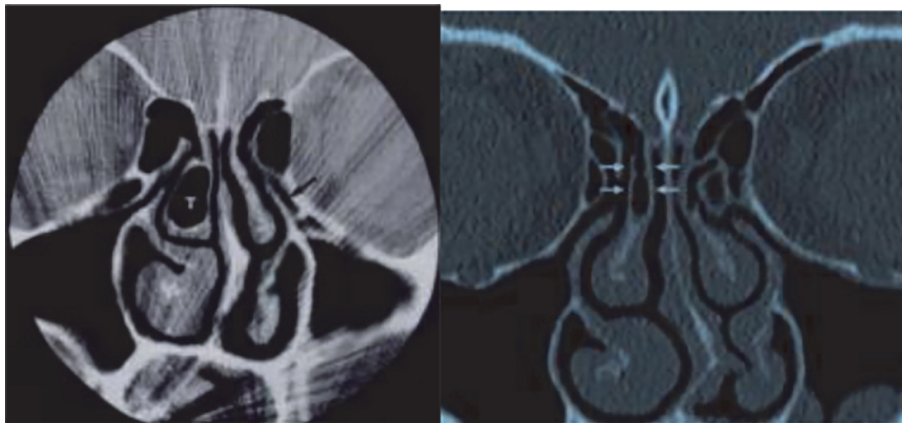
Hypoplasia of the turbinates is the result of the underdevelopment or reduced size due to reduced number of cells, in the small curved bones that extend horizontally along the lateral wall of the nose.

### 3.2 Pneumatization of the turbinates

Superior turbinate is a small bony projection in the lateral wall of the nose and forms the boundary of superior meatus and contributes to the formation of sphenoidal recesses. Therefore, it plays a significant role in the drainage of the posterior ethmoidal and sphenoid sinuses. Pneumatization of the superior turbinate is rare and the incidence of it causing sinusitis is low compared with middle turbinate pneumatization (**Figure 4**). Extensive pneumatization of the middle turbinate (*concha bullosa* or *bullous middle turbinate*) is known to be one of the possible etiologic factors in nasal obstruction, recurrent sinusitis, and headaches (**Figure 5**). On the other hand, pneumatization of inferior turbinate is a very rarely encountered variation. Extensive turbinate pneumatization may cause turbinate enlargement and result in persistent nasal obstruction (**Figure 6**).



**Figure 4.**  
*A serial coronal CT scan of the paranasal sinuses showing pneumatization of right superior turbinate (arrow) with bilateral maxillary sinus pathology.*



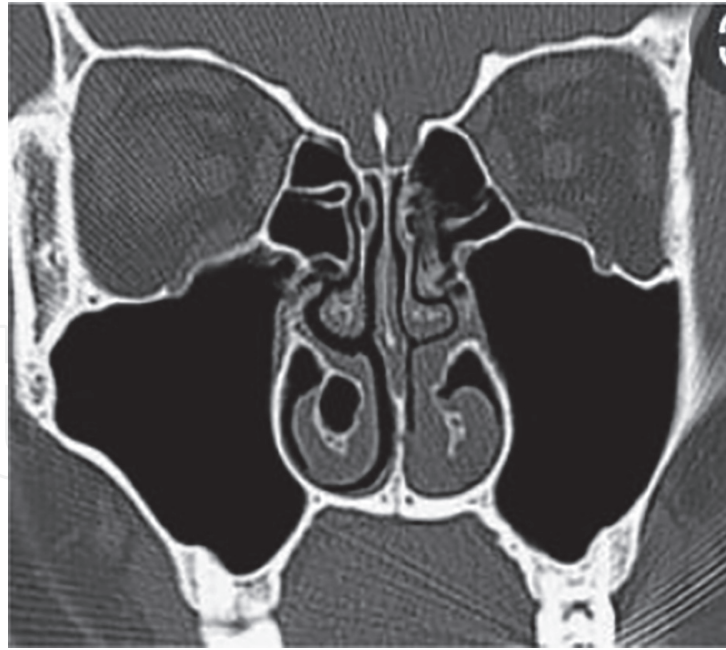**Figure 5.**  
*Serial coronal CT scans of the paranasal sinuses showing a) pneumatization of right middle turbinate and B) pneumatized basal lamella (interlamellar cell of Grunwald) limited to vertical part of middle turbinate not causing narrowing of ostiomeatal complex.*

### 3.3 Paradoxical turbinate

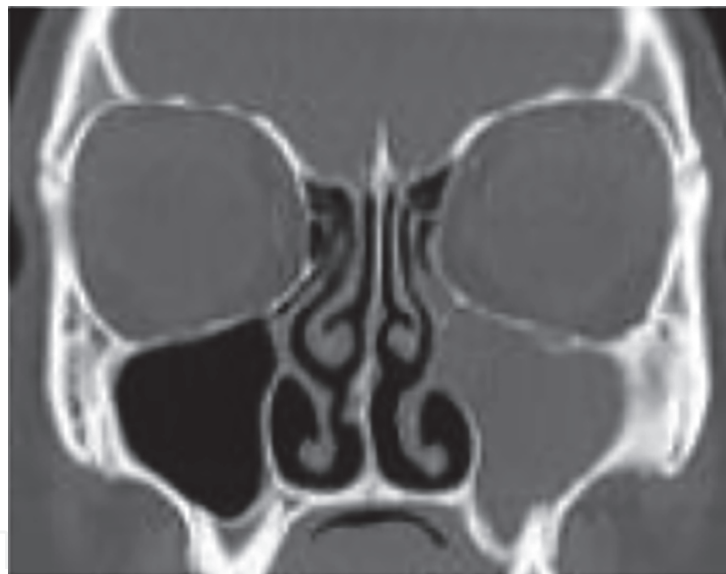
The superior, middle, and inferior turbinate (conchae) are present in the lateral wall of the nasal cavity. Paradoxical middle turbinate is a rare developmental condition and refers to an inferior medially curved middle turbinate edge with the concave surface facing the nasal septum and usually occurs bilaterally. Once again, it may impede sinus ventilation and drainage *via* the OMC, resulting in sinusitis (**Figure 7**).

### 3.4 Nasal septum turbinate

Nasal septal turbinate (NST) is structurally located in the anterior part of the septal part of nasal cavity and limits laterally the nasal valve (**Figure 8**). It presents a fusiform area of erectile tissue, similar in structure and function to nasal turbinate, and consists of mucosa, erectile tissue, blood vessels, and secretory glands. Its main



**Figure 6.**  
*A serial coronal CT scan of paranasal sinuses showing pneumatization of inferior turbinate.*



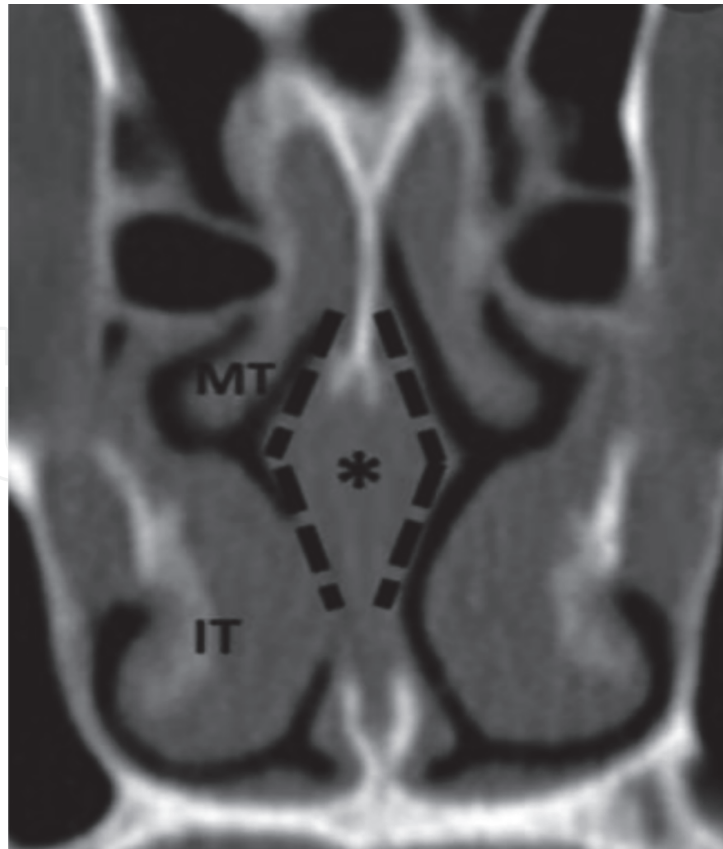
**Figure 7.**  
*A serial coronal CT scan of the paranasal sinuses showing paradoxical bilateral middle turbinates with an opaque left maxillary sinus.*

function is to direct the airflow toward the nasal turbinate and the osteomeatal complex and humidification of air at the beginning of inspiration [14].

## 4. Uncinate process

### 4.1 Attachment of uncinate

The uncinate process (UP) is an important landmark for sinus surgery. It is a crescent-shaped bony projection forming a vital structure of the OMC unit, projecting from anterior superior in the posterior inferior direction. Its function is said to deflect and prevent contaminated inspired air from gaining access to the maxillary, anterior ethmoidal, and frontal sinus which it drains. The hiatus semilunaris, a two-dimensional structure, is bordered by the uncinate anterior



**Figure 8.**  
*A serial coronal CT scan of the paranasal sinuses showing nasal septum turbinates (asterisk).*

inferiorly and ethmoidal bulla posterior superiorly. The hiatus semilunaris continues laterally to form the ethmoidal infundibulum, which is a three-dimensional conical structure with its apex lying laterally to form the maxillary sinus drainage pathway. The uncinate lateral border is attached to the frontal process of the maxilla while its free edge lies medially. Its breadth, length, and thickness vary from one to another. The uncinate is attached to the maxillary process superiorly, which curves laterally. The inferior process arises from the inferior edge being in contact with the inferior turbinate.

There are several attachments of the uncinate process. Although there are several others, the three main variations in attachments are [15].

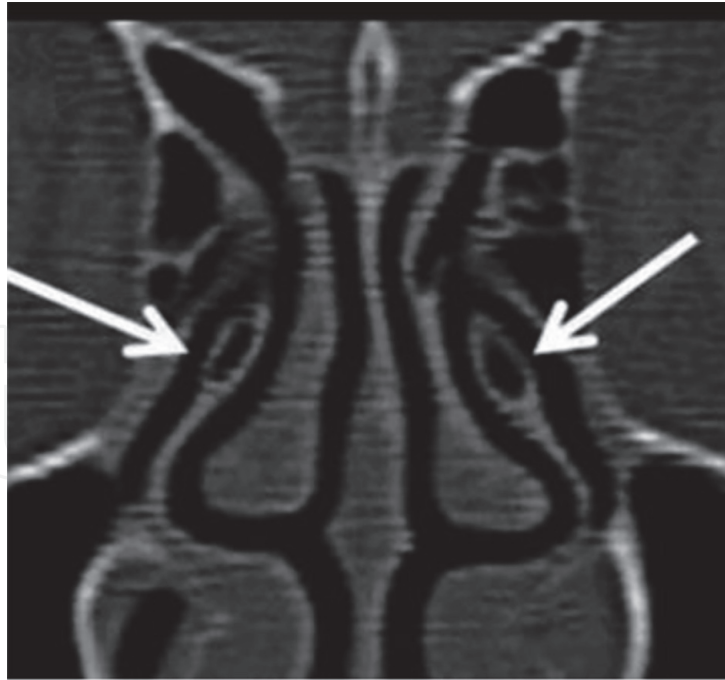
1. **Lamina papyracea.** Attachment to the lamina papyracea allows the frontal sinus to drain just medial to the uncinate into the middle meatus, while the area between the uncinate and lamina papyracea forms the recess terminalis, which is a blind recess.
2. **Lateral aspect of the middle turbinate.** Its attachment allows the frontal sinus to drain medially and directly into the ethmoidal infundibulum
3. **Skull base.** Frontal sinus drainage is similar to 2 above.

Other anatomical variations of the uncinate process are described.

#### **4.2 Pneumatized uncinate**

The pneumatized or aeration of the uncinate process also known as a bulla may obstruct the OMC and result in diseases of the paranasal sinuses (**Figure 9**). It is



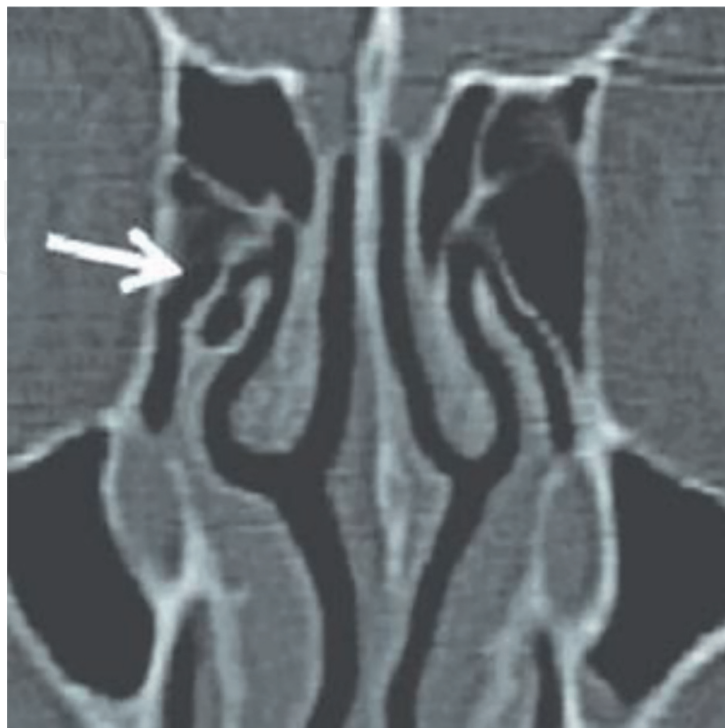


**Figure 9.**  
*Bilateral aeration of uncinate process.*

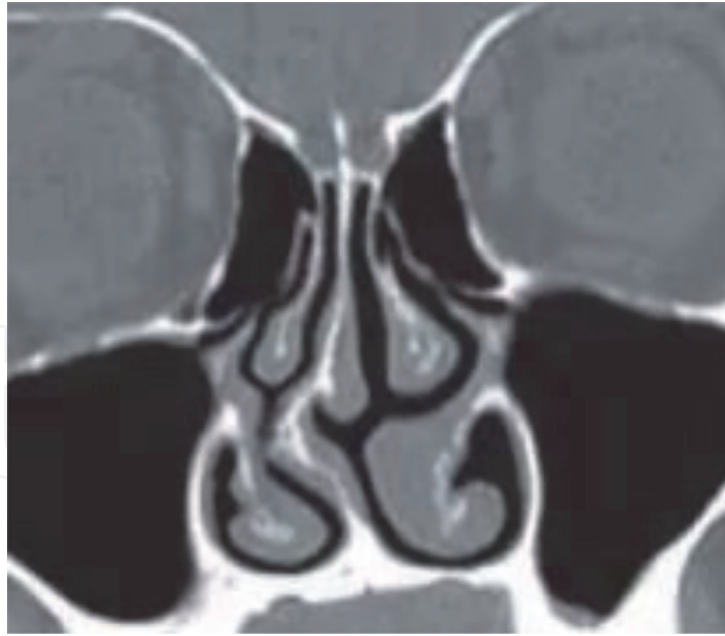
believed that the uncinate bulla may be a continuation of the agar nasi (anterior most ethmoidal air cell) from above [16]. It should not be mistaken with a Haler cell of the maxillary sinus.

#### 4.3 Bifid uncinate

A bifid uncinate has two superior bony projections, its significance unknown and rare (**Figure 10**) [16].



**Figure 10.**  
*A bifid right uncinate process.*



**Figure 11.**  
*A curved uncinata process.*

#### **4.4 Curved uncinata**

A curved uncinata can either be located horizontally or vertically (**Figure 11**). A horizontally located uncinata is often seen together with a large bulla ethmoidalis. It may curve medially to form a Kaufmann's double middle turbinate [16, 17].

#### **4.5 Atelectatic uncinata**

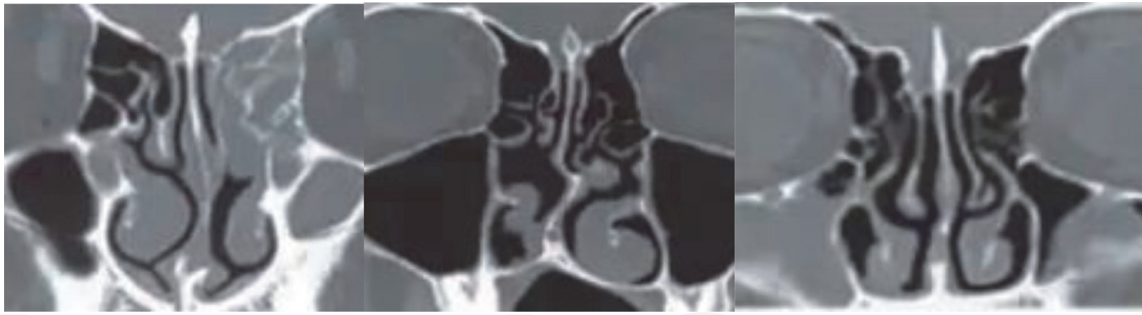
An atelectatic uncinata is one that is not developed and hypoplastic and may be adherent to the medial wall of the orbit or lamina papyracea. It should be identified radiologically to avoid violation to the lamina papyracea. Otherwise, one may assume the lamina papyracea is the uncinata process and attempt to remove it resulting in orbital complications. It is associated with maxillary sinus hypoplasia or silent sinus syndrome [16].

### **5. Olfactory fossa**

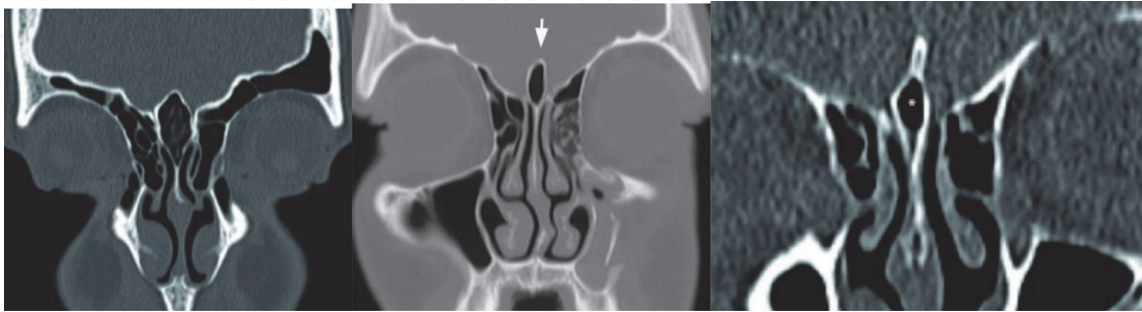
The olfactory fossa is a depression of the anterior cranial cavity formed by the cribriform plate, thus discontinuing the nasal cavity beneath from the cranial fossa above. The crista galli forms the medial boundary and lateral lamella of the cribriform forms the lateral boundary. The lateral lamella is the thinnest bone and may be dehiscent. The olfactory fossa contains olfactory nerves. A three-tier classification of the depth of the olfactory fossa was performed by Keros on 450 samples (**Figure 12**). It should be measured at the coronal view [18]. Beware of asymmetry within the right and left.

Keros Type 1.

Depth of OF is 1–3 mm. The cribriform is almost in level with the roof of the ethmoid. Eyeballing a coronal section of the CT scan, the cribriform is often above an imaginary horizontal line connecting the center of both eyeballs. It is the second most common variation.



**Figure 12.** Coronal view of the CT of the paranasal sinuses demonstrating a) Keros type 1, b) Keros type 2, and c) Keros type 3.



**Figure 13.** Pneumatization of crista galli from left a) small; b) moderate, and c) large.

#### Keros Type 2.

Depth of OF is 4–7 mm. The cribriform is lower than that of type 1 resulting in a higher vertical length of the lateral lamella. Eyeballing a coronal section of the CT scan, the cribriform is just above the imaginary horizontal line connecting the centers of both eyeballs. It is the most common variation.

#### Keros Type 3.

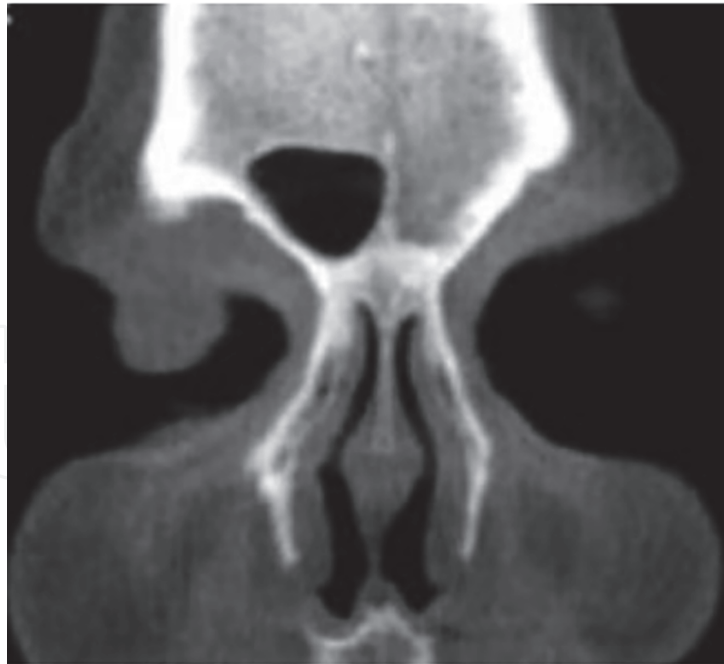
Depth of OF is 8–16 mm. The cribriform is even lower than 1 and 2 with an even higher vertical length of the lateral lamella predisposing to greater risk of penetration if the surgeon is not careful during an endoscopic sinus surgery. This may lead to CSF leaks, meningocele, encephalocele, bleeding, and meningitis. It has been termed as the dangerous ethmoid. Eyeballing the coronal section of the CT scan, the cribriform is approximately at the level of the imaginary horizontal line joining the center of both eyeballs. It is the least common variation.

## 6. Crista galli

Crista galli is the outpouching of the ethmoid bone into the anterior cranial fossa. It sits in the center and divides the olfactory bulbs into the right and left. A pneumatized crista galli (**Figure 13a–c**) is thought to be caused by extension of aeration from the ethmoid bones and classified as small, moderate or large. However, there is strong evidence that pneumatization of the frontal sinus instead may extend into the crista galli [19]. Its incidence is less than 5%. The pneumatization can be surrounded by bony walls or spongy bones, which has been associated with chronic inflammation of the sinuses and in rare cases, a mucocele within [20].

## 7. Frontal sinus

The frontal sinus is the only sinus not present at birth. Pneumatization starts at the age 2 and reaches the orbital roof by age 5 to 7 years and attains adult size by 12 years.



**Figure 14.**  
*Serial view of coronal CT scan paranasal sinuses showing asymmetry of the frontal sinuses with a rudimentary left frontal sinus.*

The frontal sinus comprises two sinuses extending in the squamous part of the temporal bone and is separated by bony septum. Since each separated sinus (right and left) develops independently, they are expected to be asymmetrically pneumatized (**Figure 14**). Most commonly the larger sinus passes over the midline and overlaps the other [3].

The anterior and posterior walls of the sinuses are called the outer and inner tables. Unlike the thick bony wall of the outer table, the relatively thin inner table bony plate separates the frontal sinus from the cranial fossa posteriorly. The foramina of Breschet that consists of venous drainage channels is found on the inner table of the sinus and is the source of infection spread from the sinus intracranially. These foramina are sites of mucosal invagination within the bone, and the outcome of incomplete mucosal removal from these sites during sinus obliteration procedure predisposes to the development of mucocele.

Frontal sinus ostium is located at the posteromedial portion of the sinus's floor. The narrowest path of the frontal sinus drainage pathway (an hourglass shape) corresponds to the frontal beak, which represents the frontal sinus ostium. Anatomically, the frontal sinus lies superior to the beak and the frontal recess inferior to the beak. The size and patency of the frontal sinus ostium is determined by the thickness of the frontal beak (frontonasal process of maxilla).

A large agger nasi cell results in a small frontal beak and a wider frontal sinus ostium. On the contrary, a small agger nasi cell results in a prominent frontal beak and a narrow ostium. A larger agger nasi cell may compromise the frontal sinus drainage pathway at the level of the frontal recess inferiorly.

### **7.1 Hypoplastic frontal sinus**

Hypoplastic frontal sinus is found in 4% and aplasia in 5% of the population [21].

## 7.2 Frontoethmoidal cell

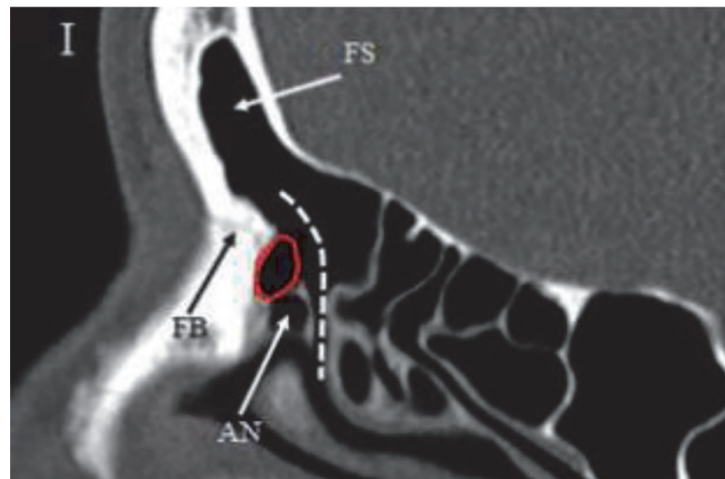
Frontal sinuses may contain air cells as projections from the ethmoidal sinus. The modified Wormald classification of the frontoethmoidal cell (frontal cells) classifies them into several types [22].

**Type 1 frontal cell**—single frontal recess cell above agger nasi cell but below frontal ostium (Figure 15).

**Type 2 frontal cells**—two or more frontal recess cells above agger nasi cell but below frontal ostium (Figure 16).

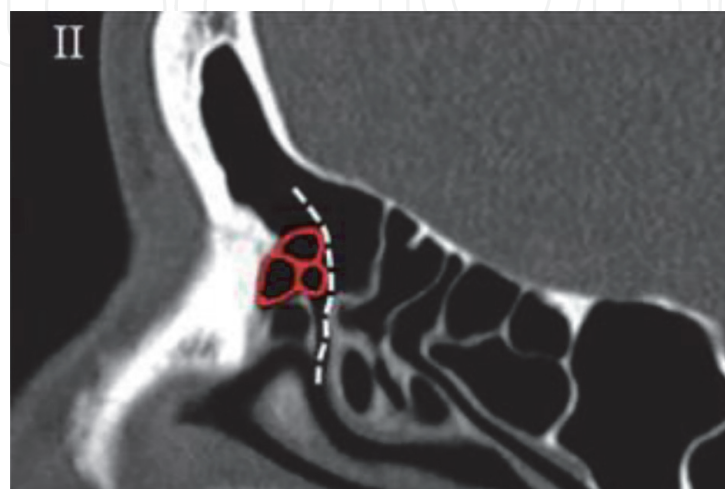**Type 3 frontal cell**—single cell above the agger nasi with extension into the frontal sinus through the frontal ostium but not exceeding 50% vertical height of the ipsilateral frontal sinus (Figure 17).

**Type 4 frontal cell**—either single cell above the agger nasi with extension into the frontal sinus through the frontal ostium and exceeding 50% vertical height of the ipsilateral frontal sinus or an isolated cell within the frontal sinus (Figure 18).



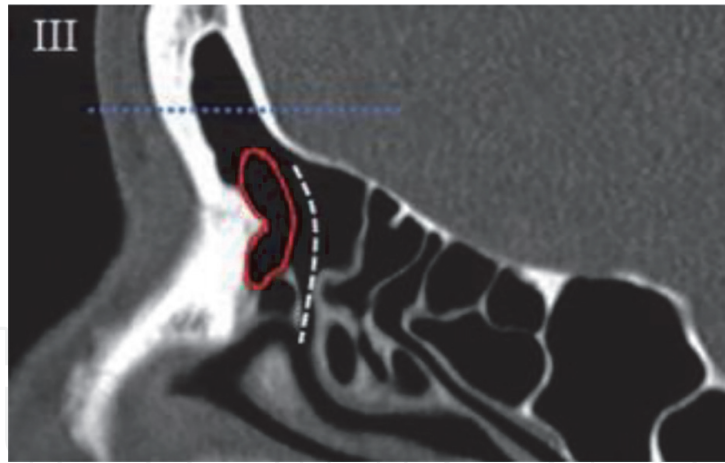
**Figure 15.**

Parasagittal view demonstrating type 1 frontal cell in red, FS (frontal cell), FB (frontal beak corresponding to frontal ostium), AN (agger nasi cell), white-dashed line represents the midway of the frontal sinus vertical line.

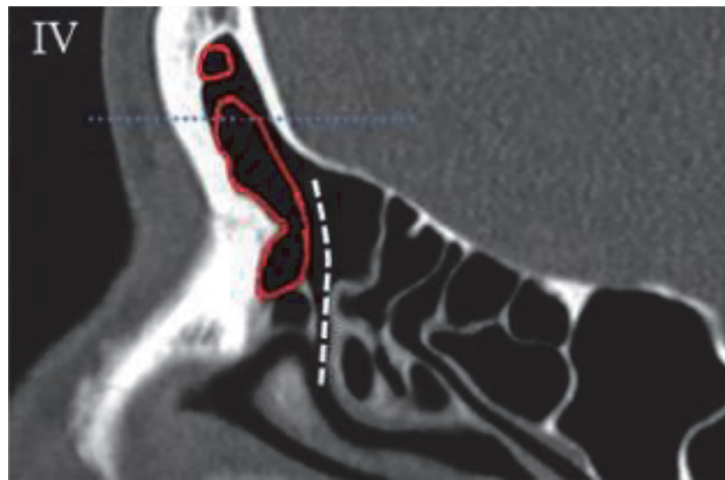


**Figure 16.**

Parasagittal view demonstrating type 2 frontal cells in red, white-dashed line represents the midway of the frontal sinus vertical line.



**Figure 17.**  
*Parasagittal view demonstrating type 3 frontal cell in red, white-dashed line represents the midway of the frontal sinus vertical line.*



**Figure 18.**  
*Parasagittal view demonstrating type 4 frontal cell in red, white-dashed line represents the midway of the frontal sinus vertical line.*

### 7.3 Frontal bullar cell

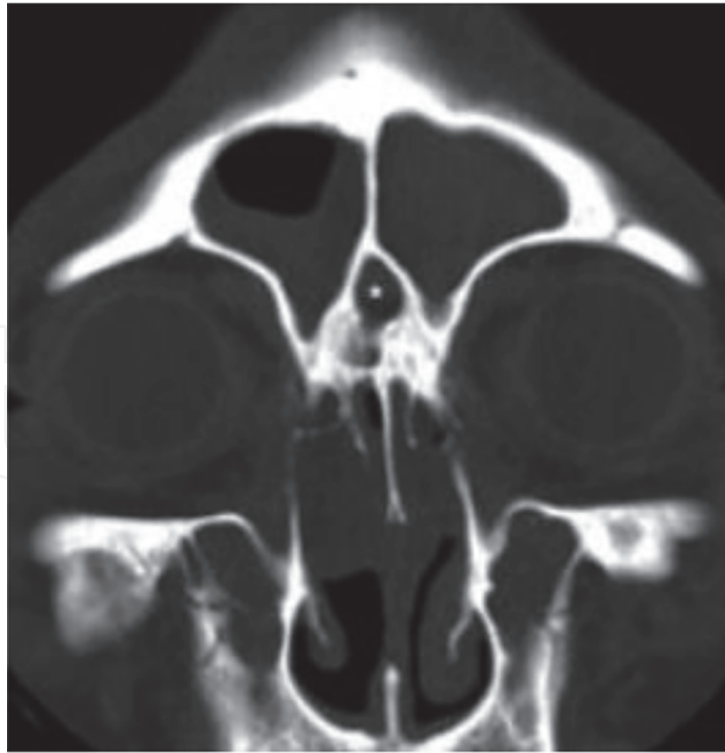
It consists of a single cell that extends from suprabullar region into frontal sinus superiorly along the posterior wall of frontal recess. This is unlike the suprabullar cell that does not extend into the frontal sinus. Its anterior wall is related to frontal sinus and its posterior to anterior cranial fossa. One should be cautious during surgery while opening this cell, not to cause unintentional trauma to anterior skull base.

### 7.4 Frontal intersinus septal cell

This occurs when an intersinus septum is pneumatized and may communicate with either one of the frontal sinuses or could be completely an isolated air cell, which may compromise the frontal sinus ostium patency (**Figure 19**).

## 8. Maxillary sinus and natural ostium

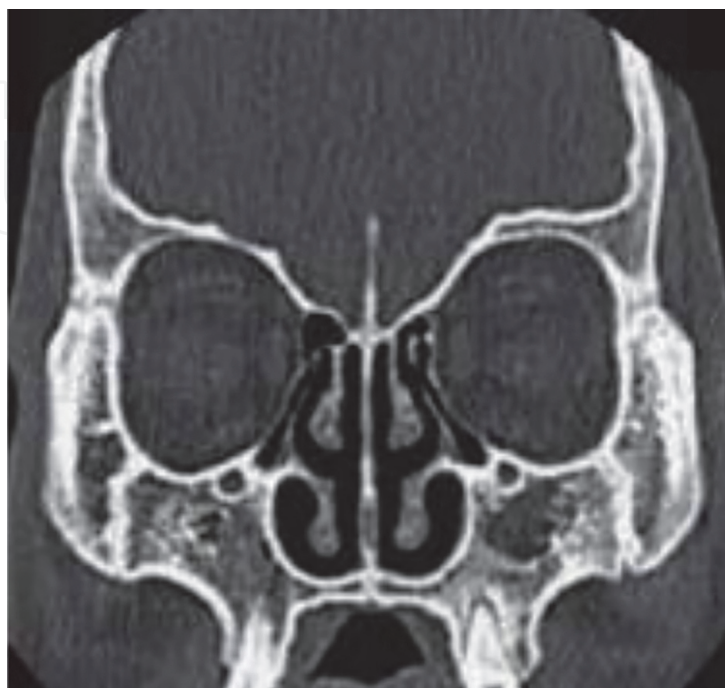The maxillary sinus is present at birth. By 12 weeks *in utero*, the ethmoid maxillary recess projects out pouches laterally to form the maxillary sinus. At 3 months, ventrodorsal dimensions are 2.5 mm and by birth it is 7 mm [23].



**Figure 19.**  
*Serial view of coronal CT scan paranasal sinuses showing a frontal intersinus septum (asterisk).*

### 8.1 Agenesis/hypoplasia

Although maxillary sinus hypoplasia and agenesis is common, it is often asymptomatic and identified incidentally on imaging (**Figure 20**). It may be unilateral or bilateral. In higher grades of hypoplasia, the uncinate follows suit and it becomes more difficult to identify the natural ostia. Postulations of hypoplasia include congenital failure of development, chronic infection halting growth, and failure of



**Figure 20.**  
*Serial view of coronal CT scan of paranasal sinuses showing agenesis of the maxillary sinuses.*

development of the uncinate process affecting that of the maxillary sinus [22]. Therefore, hypoplasia of the maxillary sinus can be classified into three [23]:

- I. Normal uncinate and infundibular process with mild sinus hypoplasia and mucosal thickening,
- II. Hypoplastic or absent uncinate and infundibular process with significant sinus hypoplasia and total opacification of sinus,
- III. Absent uncinate process with profound hypoplasia and shallow cleft at lateral nasal wall.

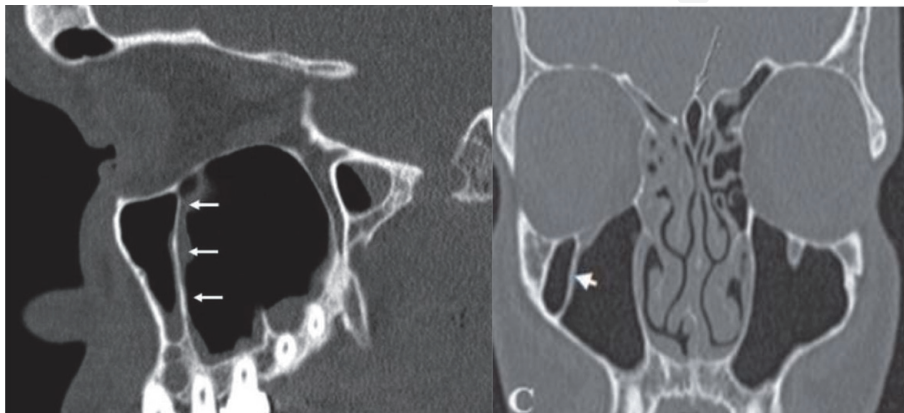
Therefore, preoperative identification of hypoplasia and poorly developed uncinate processes is crucial to prevent iatrogenic trauma to the lamina papyracea.

## 8.2 Silent sinus syndrome

Although a syndrome, silent sinus syndrome (SSS) may cause an anatomical abnormality to the maxillary sinus. It is a phenomenon whereby a normally developed maxillary sinus is reabsorbed. This is believed to be due to chronic maxillary sinusitis atelectasis whereby the absence of ventilation causes the sinus to reabsorbed over time. It is believed that a large fluffy uncinate acts as a one-way air outflow valve mechanism within the OMC resulting in maxillary atelectasis [24]. The orbital floor will bow into the maxillary sinus often entrapping orbital muscles resulting in enophthalmos, sunken orbital sulci, and double vision in a previously normal individual. There may or may not be a history of rhinosinusitis symptoms. Unlike a maxillary sinuses agenesis or hypoplasia, SSS is not congenial and is acquired resulting in progressive changes over months in an individual with a normally developed maxillary sinus prior. Besides that, its criteria include no major nasal pathology, previous trauma, and with no previous congenital deformity [24]. Imaging in confirmatory and treatment involves a FESS with considerations of orbital floor reconstruction.

## 8.3 Intersinus septa

The maxillary intersinus septum may occur in 21.6 to 66.7% of patients (Figure 21). Many have tried to classify it based on its location in relation to the premolars and molars. It may obstruct mucosa flow and result in sinusitis. It is



**Figure 21.**  
*Serial views of sagittal and coronal CT scan of paranasal sinuses showing right intersinus maxillary septa.*



considered if it is more than 2.5 mm in height. It is said to be more common in adentulous patients [25].

#### **8.4 Accessory ostium**

An accessory ostium is one which is located away from the hiatus semilunaris. It occurs in less than 20% of individuals. Accessory ostium is more frequently located within the posterior fontanelle but existence within the anterior fontanelle is possible. It is often less than 1.5 mm in diameter. In a virgin nose, an encounter of a maxillary ostium within the posterior fontanelle is most likely an accessory ostium. The presence of an accessory ostium may cause looping of air within the natural and accessory ostium resulting in recirculation syndrome whereby the patient develops maxillary sinusitis due to inadequate ventilation of the maxillary sinus. In such instances, the surgeon should make a communication between the natural and accessory ostium to form a common cavity during a middle meatal antrostomy [3, 23].

#### **8.5 Haler cell (infraorbital cell)**

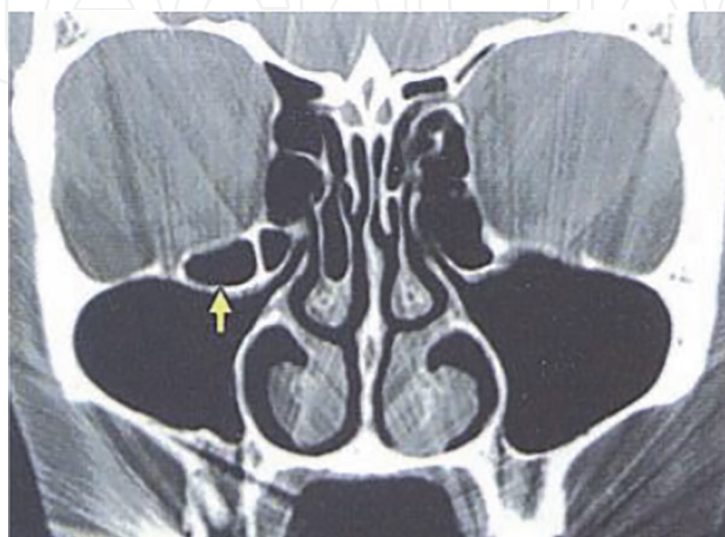
A Haler cell is an anterior inferior projection of an ethmoidal air toward the underside of the orbit. It may cause obstruction of the infundibulum and ventilation of the maxillary sinus (**Figure 22**).

### **9. Infraorbital nerve**

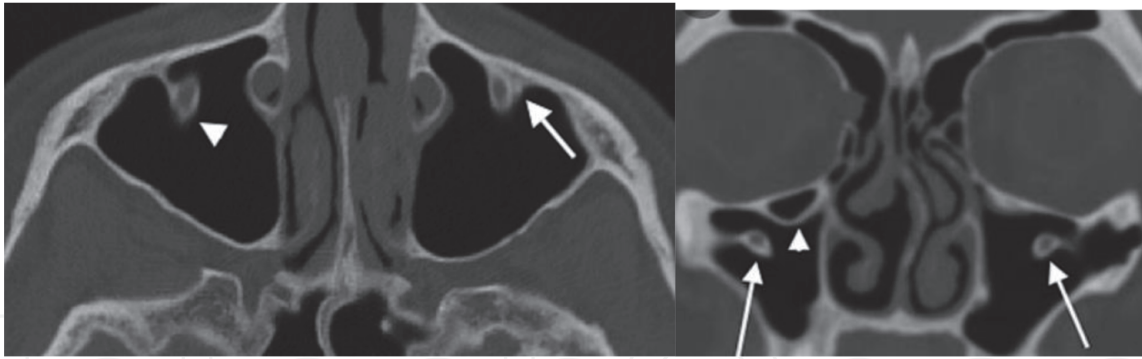
The infraorbital nerve or V2 is the terminal branch of the maxillary division of the trigeminal nerve. It often runs within the infraorbital foramen, situated inferior to the infraorbital rim, and supplies the sensation of the cheek. Its course within the infraorbital foramen from the orbit to the cheek may vary (**Figure 23**). It is often at risk during a Caldwell-Luc procedure. Ference et al. 2015 have classified the variations into three [26]:

*Type 1:* Nerve within the sinus roof,

*Type 2:* Nerve just below the roof and juxtaposed to it,



**Figure 22.**  
*A coronal CT scan of paranasal sinuses showing a right infraorbital cell.*



**Figure 23.**  
Serial view of axial and coronal CT paranasal sinuses showing infraorbital nerve variations.

**Type 3:** Nerve descended into the sinus lumen, suspended within a septation of an infraorbital ethmoid cell.

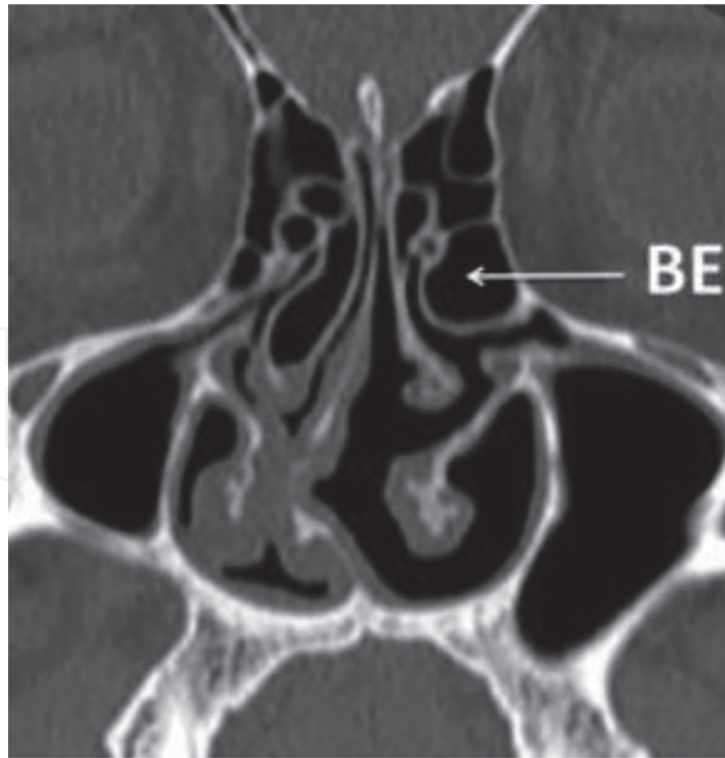
Type 3 constitutes approximately 12.5% of the population with an 8.6 mm average below the roof of the maxillary sinus [26]. Preoperative identification of its dehiscent course from the maxillary sinus roof should be identified, and if maxillary sinus surgery is performed, its identification during surgery is crucial for preservation. Although endoscopic sinus surgery poses less risk, care should be taken when stripping of the maxillary sinus mucosa in cases of benign tumors such as inverted papilloma and breaking of septations of the maxillary sinus. It may also be damaged during trauma to the midface or cheek. Trauma to the infraorbital nerve may cause paresthesia to the region of the ipsilateral cheek.

## 10. Ethmoidal sinus

The anterior ethmoidal sinus is present at birth, while the posterior is initially fluid filled and continues to develop until the age of 12 [27]. It is formed by the ethmoidal bone forming multiple pyramidal air cells. It is bounded laterally by the eyes, which is being separated from the nasal cavity by the thin lamina papyracea. Posteriorly is the face of the sphenoid, and anterior is the agar nasi cell. With reference to the base of skull, the axilla of the middle turbinate divides the base of skull to the cribriform plate medial to it and fovea ethmoidalis (roof of ethmoid) lateral to it. Hence, the medial borders of the ethmoidal sinus bilaterally are the axilla of the middle turbinate [27]. It is important to appreciate that the skull base slopes inferiorly from the anterior to posterior direction. The basal lamella of the middle turbinate forms the separation between the anterior and posterior ethmoidal air cells. The anterior ethmoids have smaller and greater number of air cells compared with the posterior. The anterior ethmoidal air cells drain into the osteomeatal complex, while the posterior ethmoidal air cells drain into the sphenothmoidal recess posteriorly.

### 10.1 Ethmoid bulla

The degree of pneumatization of the ethmoidal bulla may vary, with failure to pneumatized in 8% population (torus ethmoidalis or totus lateralis) [7]. On the contrary, a giant bulla fills out the entire middle meatus encroaching the space between the uncinate process and the middle turbinate, with lamina papyracea forming its lateral relationship. The ethmoidal bulla may fuse superiorly with the skull base forming the posterior wall of frontal recess, failing which a small

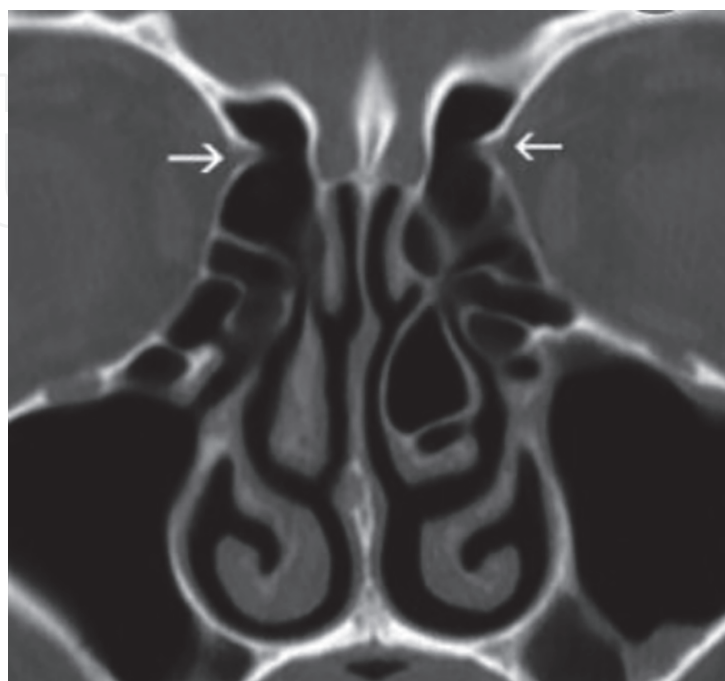


**Figure 24.**  
*Serial coronal view of the paranasal sinuses showing a prominent left bulla ethmoidalis (BE).*

suprabullar recess may connect anteriorly to the frontal recess. Posteriorly, it may fuse with the ground lamella over a variable length. The ethmoidal bulla is superior to the ethmoidal infundibulum on coronal CT images (**Figure 24**).

### **10.2 Anterior ethmoidal artery**

The anterior ethmoidal artery, a branch of the ophthalmic artery, crosses the orbit, the ethmoid labyrinth, and the anterior fossa of the skull. It enters the olfactory fossa through the lateral lamella of the cribriform plate (anterior ethmoidal sulcus),



**Figure 25.**  
*Serial coronal view of the paranasal sinuses showing bilateral anterior ethmoidal artery notch (arrows).*

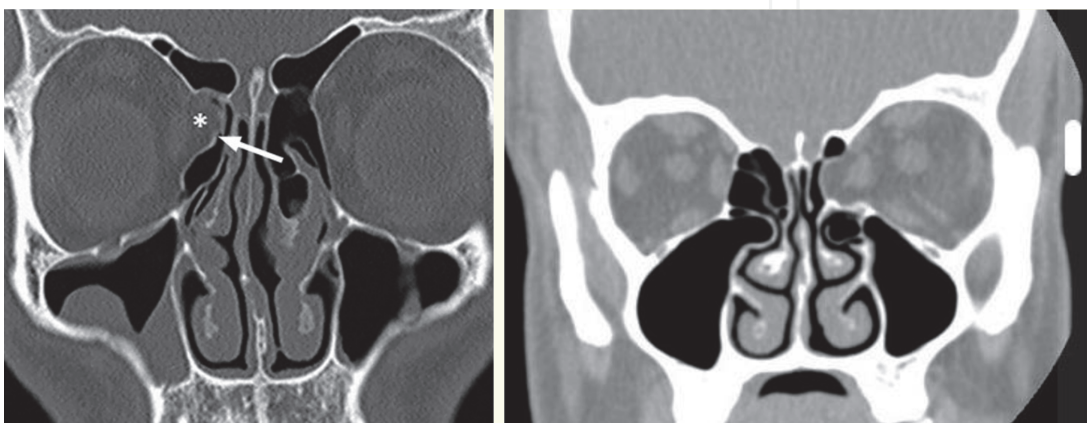
where the bone is extremely thin and at highest risk in nasal endoscopic surgery (**Figure 25**). The course of the anterior ethmoidal artery is relatively variable in the ethmoidal roof and is vulnerable to injury during surgical procedures.

## 11. Lamina papyracea

The lamina papyracea is the thin bone that forms the medial wall of the orbit and lateral wall of the ethmoidal sinus. It is also known as the orbital lamina of the ethmoidal bone. Dehiscence of the lamina papyracea may occur and can be as a result of trauma, infection, or tumor. Its dehiscence may be small or may extend posteriorly to the basal lamella. Some may contain infraorbital fat, while some contain mucosa of the ethmoidal sinus. Chronic nasal polyposis may exert pressure to the thin bone and weaken it resulting in dehiscence and protuberance of orbital content. Its protuberance may cause invagination of periorbita with or without the medial rectus, which may mimic ethmoiditis (**Figure 26a and b**). Its presence is of concern especially during endoscopic sinus surgery where injury to the periorbita and the medial rectus may occur [28].

## 12. Sphenoid sinus

The vomer usually joins the sphenoid sinus in the midline, and this is a very reliable surgical landmark. The sphenoid sinus occupies the body of the sphenoid. Anatomically, there are two asymmetrical sinuses separated off-midline by intersphenoid bony septum. The sphenoid sinus drains into the sphenoethmoidal recess through the solitary sphenoid ostium located in the anterior wall of the sinus, which opens medially to superior turbinate. The ostium is located more medially toward the rostrum, about 10 to 12 mm superior to the upper border of the choana, and about 7 cm from anterior nasal spine at an angle of 30 degree to the nasal floor. The ostium is ideally superomedial to the tail of the superior turbinate. The posterior septal artery crosses the sphenoid face from the lateral nasal wall to the posterior end of the nasal septum. In 65% of cases, it bifurcates into the superior or inferior branches before crossing, and in 35% cases, it bifurcates after crossing, inferior to the ostium. The posterior septal artery is about 5 mm below the ostium. On widening the ostium, it is safer to widen it horizontally and superiorly.



**Figure 26.** A serial coronal CT scan of the paranasal sinuses showing a) a right extraconal fat protrusion into the anterior ethmoidal sinus (arrow) and B) a left periorbital fat and medial rectus protrusion into the anterior ethmoidal sinus.

The vital structures surrounding the sphenoid sinus are the pituitary gland, optic nerves, cavernous sinuses and carotid arteries, maxillary divisions (V2) of trigeminal nerves within the foramen rotundum, and vidian canals. These structures are easily seen as indentations on the sinus's roof and walls internally, which are related to the degree of pneumatization of the sinus.

Posterior to the sinus lie the pons and the posterior cranial fossa and the roof is related to the pituitary gland and middle cranial fossa. On the posterior wall of the sinus bilaterally, the optic nerve crosses the border formed by the roof and the lateral wall. The cavernous segment of the internal carotid canals can be seen as bony prominences on the posterolateral walls of the sinus. The maxillary division of trigeminal nerves passes through the foramina rotunda toward the pterygopalatine fossa bilaterally within the lateral sphenoid walls. Within the vidian or pterygoid canals, the vidian nerve crosses the lateral sides of the sinus floor.

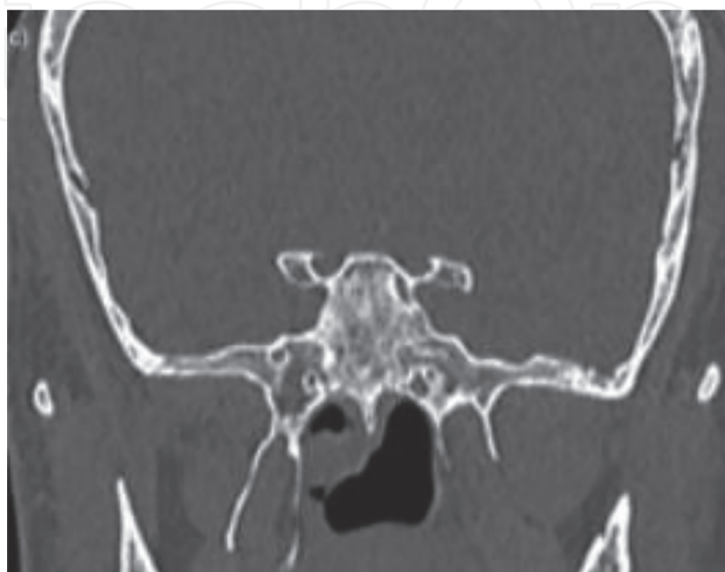
### 12.1 Agenesis or hypoplasia

Sphenoid sinus agenesis (**Figure 27**) is a rare entity and usually associated with syndromes such as craniosynostosis, osteodysplasia, Down Syndrome, and Hand-Schuler-Christain Disease [29].

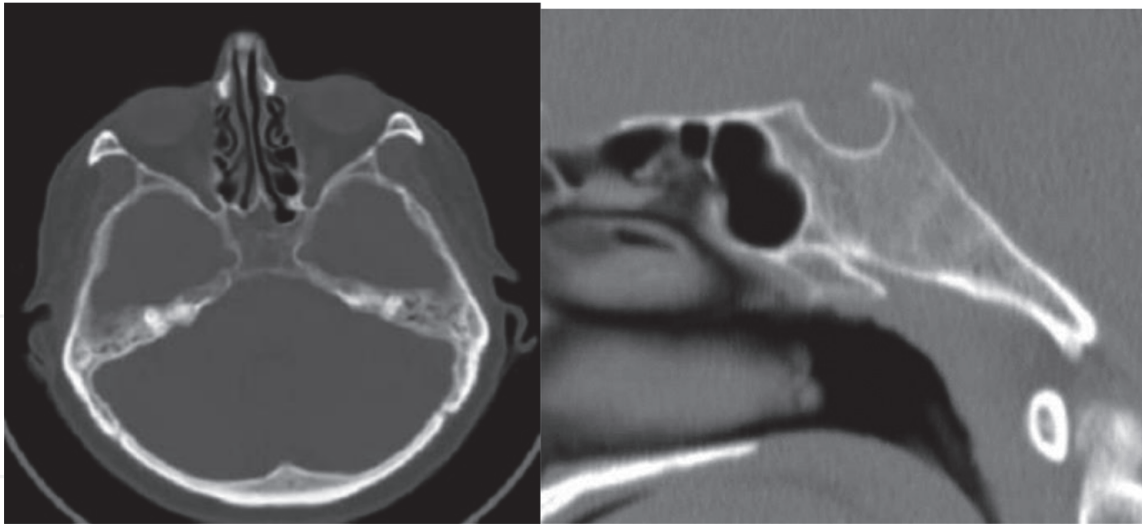
### 12.2 Pneumatization of sphenoid sinus

Depending on the degree of pneumatization, the sphenoid sinus is classified into three types as illustrated in the figures below:

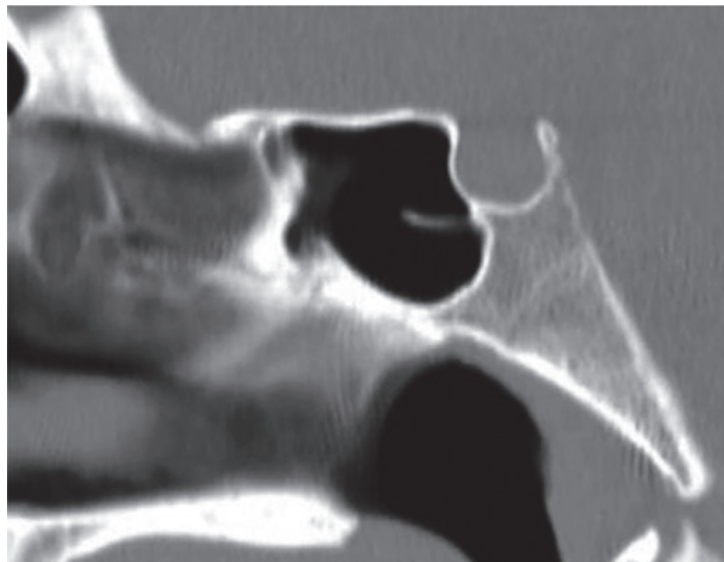
1. Conchal: Sphenoid sinus agenesis or the conchal type occurs in a non-pneumatized sinus (0.7%) and is a relative contraindication for endoscopic trans-sphenoid skull base approach (**Figure 28**)
2. Presellar (**Figure 29**)
3. Sellar (**Figure 30**)



**Figure 27.**  
*Left periorbital fat and medial rectus protrusion into the anterior ethmoidal sinus.*



**Figure 28.**  
*Conchal type: A serial axial and coronal CT scan paranasal sinus showing the degree of pneumatization is limited to the anterior portion of the sphenoid body and not reaching the level of the anterior wall of Sella turcica (1–4%).*



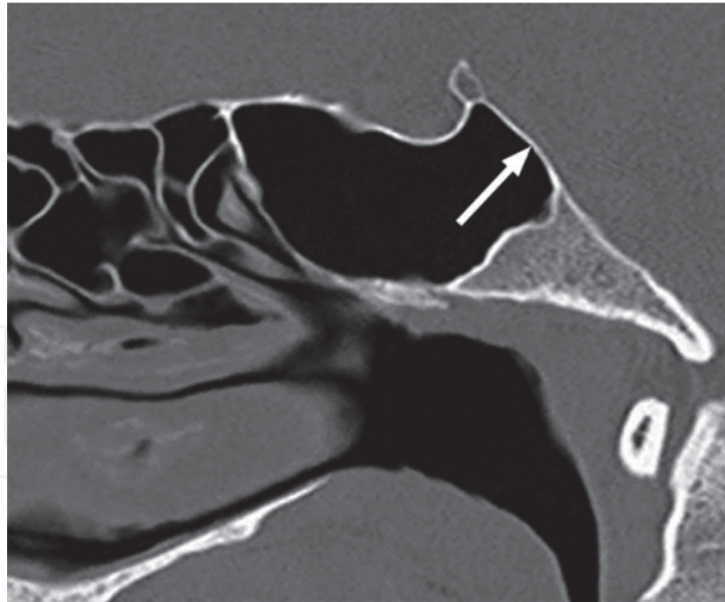
**Figure 29.**  
*Presellar type: A serial sagittal CT scan paranasal sinus showing pneumatization, which extends up to the vertical level of the anterior wall of the Sella turcica but not beyond it (35–40%).*

### 12.3 Optic nerve dehiscence

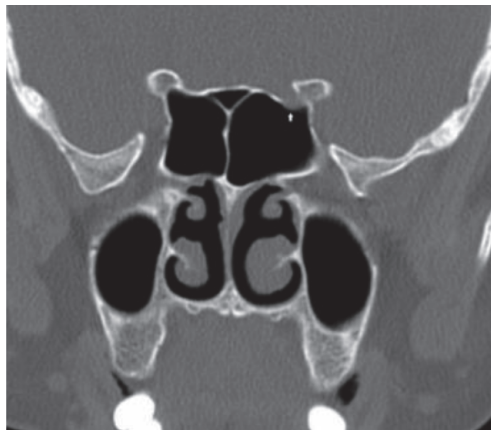
Optic nerve canal dehiscence occurs in 4% cases where the bony canal is having a focal dehiscence and only sinus mucosa with neural sheath is separating the nerve from the sinus (**Figure 31**). The thickness of the wall of the optic canal that separates it from the sinus is less than 0.5 mm in 78% of cases.

### 12.4 Internal carotid artery dehiscence

Internal carotid artery dehiscence occurs when the region of the medial side of the bony canal separating the sinus from the artery is defective, exposing the internal carotid artery at risk during the endoscopic sphenoid surgery with an incidence of 8 to 25% of this variant (**Figure 32**) [30].



**Figure 30.**  
*Sella type: A serial sagittal view of paranasal sinuses showing pneumatization extending beyond the level of the anterior wall of the Sella turcica below the pituitary fossa and may reach posterior to the Sella turcica known as postsellar type (55–60%).*



**Figure 31.**  
*A serial coronal view of paranasal sinuses showing dehiscence involving the left optic nerve cana (arrow).*

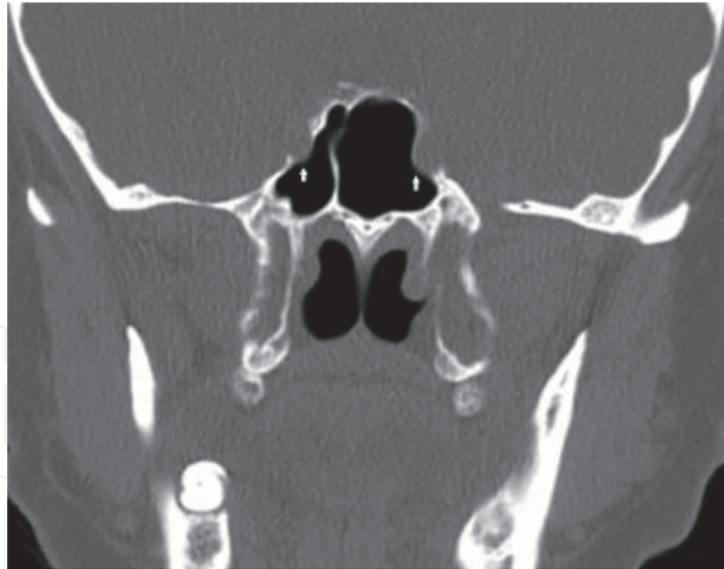
### 12.5 Sphenoid sinus septation

The inter-sinus sphenoid septum may deviate off the midline and has an insertion into the internal carotid artery bony canal (**Figure 33**) or the optic canal. To avoid avulsion of the bony wall, excessive traction on the septum should be avoided in these cases especially in endoscopic pituitary surgery [31].

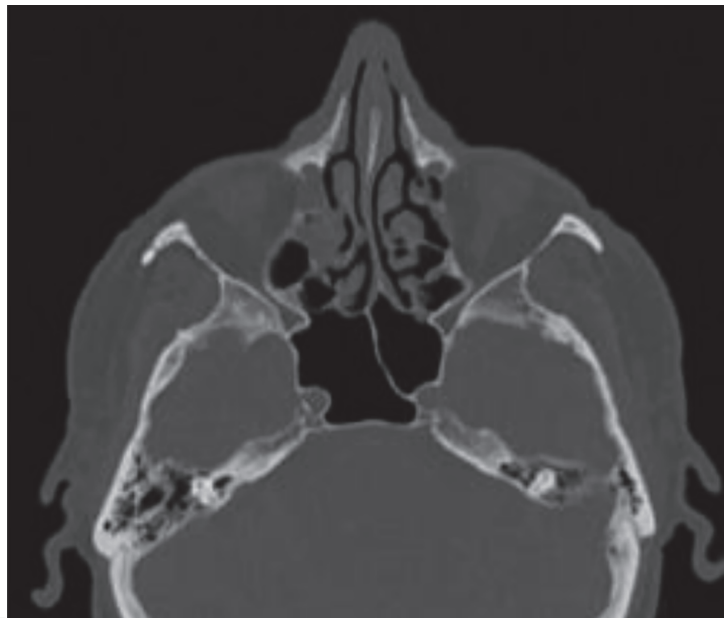
### 12.6 Sphenoid pneumatization

A pneumatized posterior nasal septum may occur from an extension of air from the sphenoid sinus or crista Galli, which rarely causes narrowing of the sphenoethmoidal region.

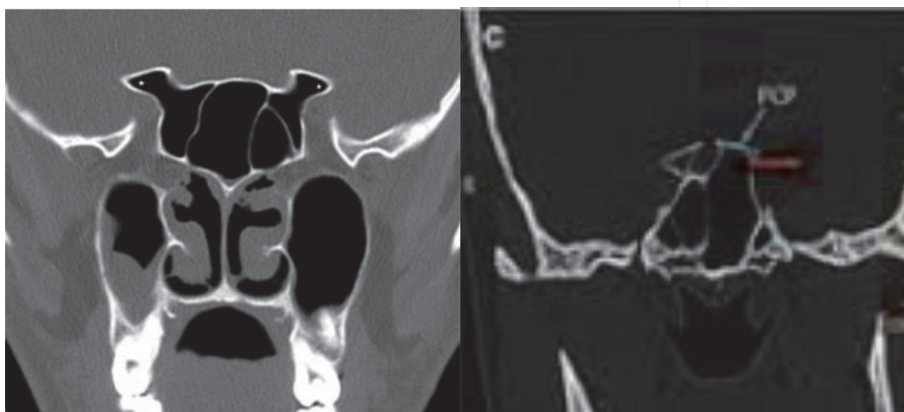
Supraoptic and infra-optic recess occurs in hyperpneumatized sphenoid sinus when pneumatization reaches superiorly (**Figure 34**) and inferiorly to the optic canal, resulting in these two recesses, respectively. The infra-optic recess or the opticocarotid recess lies between the optic canal and the internal carotid artery.



**Figure 32.**  
*A serial coronal view of paranasal sinuses showing dehiscence of bilateral internal carotid artery (arrows).*

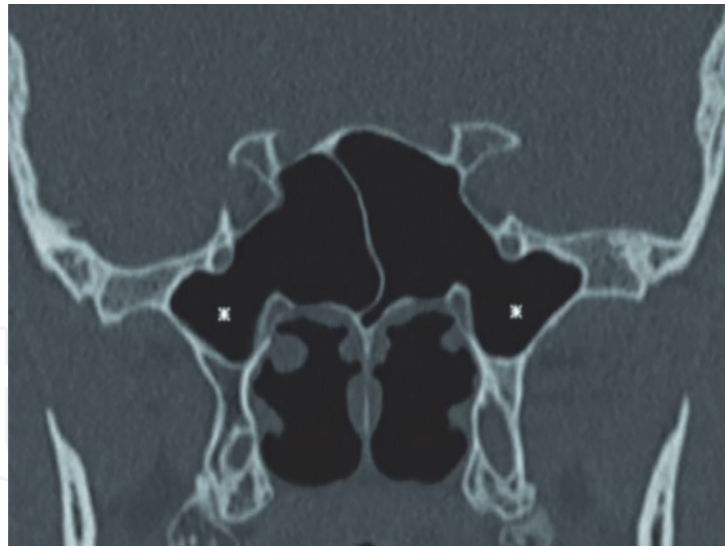


**Figure 33.**  
*A serial axial view of paranasal sinuses showing insertion of the inter-sinus septum into the left internal carotid artery bony canal.*

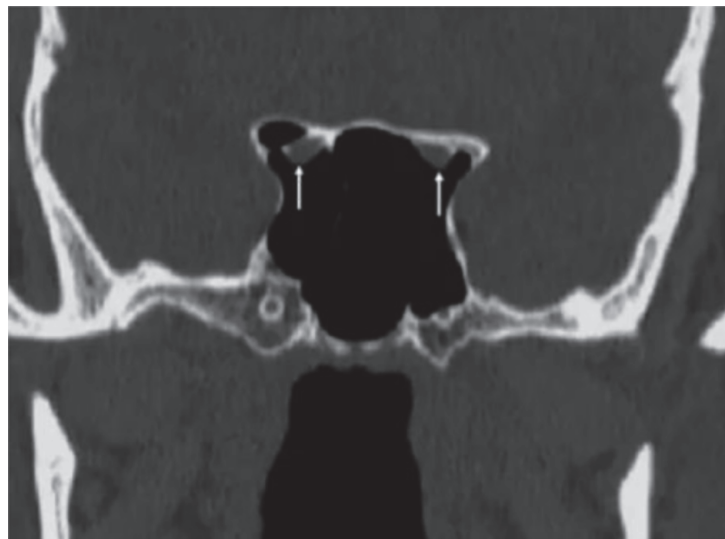


**Figure 34.**  
*Serial coronal views of paranasal sinuses showing bilateral pneumatization of anterior clinoid process (arrows) and posterior clinoid process (red arrow).*





**Figure 35.**  
*A serial coronal view of paranasal sinuses showing extensive pneumatization between the maxillary (V2) and the vidian nerve resulting in pneumatized pterygoids (arrows).*



**Figure 36.**  
*Coronal view of paranasal sinuses showing bilateral Onodi cells (arrows).*

Furthermore, the pneumatization may extend from the infra-optic recess to the anterior clinoid process.

Lateral recess occurs when pneumatization extends extensively inferolaterally between the maxillary (V2) and the vidian nerve (**Figure 35**).

### 12.7 Posterior ethmoid air cell

This is also known as Onodi cell, which refers to the extension of the posterior most ethmoidal cells superolateral to the sphenoid sinus into the anterior clinoid process (**Figure 36**). If they become infected or due to poor judgment by endoscopic surgeon, it can lead to injury to the optic canal.

## 13. Conclusion

The advent of CT scans and FESS has made the sinuses and its paranasal sinuses less of a mystery to us. More anatomical variations, its formation and functions will

be discovered with time. Due to the presence of variations and its relationship to the orbit, skull base, neurological and vascular structures, a preoperative CT of the paranasal sinuses is vital for its identification and to prevent iatrogenic injuries. Coupled with the endoscopic findings, identification of anatomical variations may also give clues to the cause, appropriate identification, and treatment to the symptoms and pathology (such as sinus infection) faced by the patients.

IntechOpen

### **Author details**


Hardip Singh Gendeh<sup>1</sup> and Balwant Singh Gendeh<sup>1,2\*</sup>

1 Department of Otorhinolaryngology, Head and Neck Surgery, Universiti Kebangsaan Malaysia Medical Center, Kuala Lumpur, Malaysia

2 Pantai Hospital Kuala Lumpur, Kuala Lumpur, Malaysia

\*Address all correspondence to: [bsgendeh@gmail.com](mailto:bsgendeh@gmail.com)

### **IntechOpen**

© 2022 The Author(s). Licensee IntechOpen. This chapter is distributed under the terms of the Creative Commons Attribution License (<http://creativecommons.org/licenses/by/3.0>), which permits unrestricted use, distribution, and reproduction in any medium, provided the original work is properly cited. 

## References

- [1] Kane KJ. The early history and development of functional endoscopic sinus surgery. *The Journal of Laryngology and Otology*. 2020;**134**(1): 8-13
- [2] Messerklinger W. Technique and possibilities of nasal endoscopy [in German]. *HNO*. 1972;**20**:133-135
- [3] Gendeh BS. *Endoscopic Sinus Surgery: State of the Art Technique*. Bangi: Universiti Kebangsaan Malaysia Publication; 2004
- [4] Dhingra PL, Dhingra S. *Diseases of Ear, Nose and Throat & Head and Neck Surgery*. 7th ed. India: RELX India Pvt. Ltd.; 2018
- [5] Bolger WE, Butzin CA, Parsons DS. Paranasal sinus bony anatomic variations and mucosal abnormalities: CT analysis for endoscopic sinus surgery. *The Laryngoscope*. 1991; **101**(1):56-64
- [6] O'Brien WT Sr, Hamelin S, Weitzel EK. The preoperative sinus CT: Avoiding a "CLOSE" call with surgical complications. *Radiology*. 2016;**281**(1): 10-21
- [7] Alsaied AS. Paranasal sinus anatomy: What the surgeon needs to know. In: Gendeh BS, editor. *Paranasal Sinuses*. Intect: Croatia; 2017
- [8] Arslan H, Aydınlioğlu A, Bozkurt M, Egeli E. Anatomic variations of the paranasal sinuses: CT examination for endoscopic sinus surgery. *Auris, Nasus, Larynx*. 1999;**26**(1):39-48
- [9] Gray LP. Deviated nasal septum. Incidence and etiology. *The Annals of Otology, Rhinology & Laryngology*. Supplement. 1978;**87**(50):3-20
- [10] Shpilberg KA, Daniel SC, Doshi AH, Lawson W, Som PM. CT of anatomic variants of the paranasal sinuses and nasal cavity: Poor correlation with radiologically significant rhinosinusitis but importance in surgical planning. *AJR. American Journal of Roentgenology*. 2015;**204**(6):1255-1260
- [11] Gendeh BS, Tan VES. Open septorhinoplasty: Operative technique and grafts. *The Medical Journal of Malaysia*. 2006;**62**(1):13-18
- [12] Yenigun A, Ozturan O, Buyuk PN. Pneumatized septal turbinate. *Auris, Nasus, Larynx*. 2014;**41**(3):310-312
- [13] Azman M, Gendeh BS. Septal turbinates: An entity with physiological importance. *Brunei International Medical Journal*. 2011;**7**(3):168-172
- [14] Stammberger H, Koop W, Dekornfeld TJ. Special endoscopic anatomy. In: Stammberger H, Hawke M, editors. *Functional Endoscopic Sinus Surgery: The Messerklinger Technique*. Philadelphia, PA: BC Decker; 1991. pp. 61-90
- [15] Güngör G, Okur N, Okur E. Uncinate process variations and their relationship with ostiomeatal complex: A pictorial essay of multidetector computed tomography (MDCT) findings. *Polish Journal of Radiology*. 2016;**20**(81):173-180
- [16] Cagici CA, Ozer C, Yilmaz I, Bolat FA, Cakmak O. Solitary polyps of the uncinate process. *Ear, Nose, & Throat Journal*. 2007;**86**(2):94-96
- [17] Tan HM, Chong VFH. CT of the paranasal sinuses: Normal anatomy, variants and pathology. *CME Radiology*. 2001;**2**:120-125
- [18] Keros P. On the practical value of differences in the level of the lamina cribrosa of the ethmoid. *Zeitschrift fur*

Laryngologie, Rhinologie, Otologie und Ihre Grenzgebiete. 1962;**41**:809-813

[19] Som PM, Park EE, Naidich TP, Lawson W. Crista galli pneumatization is an extension of the adjacent frontal sinuses. *American Journal of Neuroradiology*. 2009;**30**(1):31-33

[20] Mladina R, Antunović R, Cingi C, Muluk NB, Skitarelić N, Malić M. An anatomical study of pneumatized crista galli. *Neurosurgical Review*. 2017;**40**(4): 671-678

[21] Khanduri S, Singh N, Bhadury S, Ansari AA, Chaudhary M. Combined aplasia of frontal and sphenoid sinuses with hypoplasia of ethmoid and maxillary sinuses. *Indian Journal of Otolaryngology and Head & Neck Surgery*. 2015;**67**(4):434-437

[22] Wormald PJ, Hoseman W, Callejas C, Weber RK, Kennedy DW, Citardi MJ, et al. The international frontal sinus anatomy classification (IFAC) and classification of the extent of endoscopic frontal sinus surgery (EFSS). *International Forum Allergy & Rhinology*. 2016;**6**(7): 677-696

[23] Bolger WE, Woodruff WW, Morehead J, Parsons DS. Maxillary sinus hypoplasia: Classification and description of associated uncinata process hypoplasia. *Otolaryngology-Head and Neck Surgery*. 1990;**103**(5): 759-765

[24] Bossolesi P, Autelitano L, Brusati R, Castelnuovo P. The silent sinus syndrome: Diagnosis and surgical treatment. *Rhinology*. 2008;**46**(4): 308-316

[25] Maestre-Ferrín L, Galán-Gil S, Rubio-Serrano M, Peñarrocha-Diago M, Peñarrocha-Oltra D. Maxillary sinus septa: A systematic review. *Medicina Oral, Patología Oral y Cirugía Bucal*. 2010;**15**(2):383-386

[26] Ference EH, Smith SS, Conley D, Chandra RK. Surgical anatomy and variations of the infraorbital nerve. *The Laryngoscope*. 2015;**125**(6):1296-1300

[27] Ogle OE, Weinstock RJ, Friedman E. Surgical anatomy of the nasal cavity and paranasal sinuses. *Oral and Maxillofacial Surgery Clinics of North America*. 2012;**24**(2):156-166

[28] Moulin G, Dessi P, Chagnaud C, Bartoli JM, Vignoli P, Gaubert JY, et al. Dehiscence of the lamina papyracea of the ethmoid bone: CT findings. *AJNR. American Journal of Neuroradiology*. 1994;**15**(1):151-153

[29] Anik I, Anik Y, Koc K, Ceylan S. Agenesis of sphenoid sinus. *Clinical Anatomy*. 2005;**18**(3):217-219. DOI: 10.1002/ca.20096

[30] Padhye V, Valentine R, Wormald PJ. Management of carotid artery injury in endonasal surgery. *International Archives of Otorhinolaryngology*. 2014;**18**(Suppl 2): S 173-S 178

[31] Lum SG, Gendeh BS, Husain S, Izaham A, Tan HJ, Gendeh HS. Internal carotid artery injury during endoscopic sinus surgery: Our experience and review of the literature. *Acta Otorhinolaryngologica Italica*. 2019;**39**(2):130-136