

We are IntechOpen, the world's leading publisher of Open Access books Built by scientists, for scientists

5,800

Open access books available

142,000

International authors and editors

180M

Downloads

Our authors are among the

154

Countries delivered to

TOP 1%

most cited scientists

12.2%

Contributors from top 500 universities



WEB OF SCIENCE™

Selection of our books indexed in the Book Citation Index
in Web of Science™ Core Collection (BKCI)

Interested in publishing with us?
Contact book.department@intechopen.com

Numbers displayed above are based on latest data collected.

For more information visit www.intechopen.com



Chapter

Current Concepts: Pediatric Dog Bite Injuries

Katlin VanDerhoef and Jeffrey P. Louie

Abstract

Dog bite wounds are an increasingly common occurrence, particularly in children. Providers must be able to manage bite injuries, as well as identify wound infections and how to treat them. This chapter discusses common dog bite injuries, immediate and delayed sequelae of a bite wound, wound closure, and antibiotic treatment regimens. Facial injuries are common in pediatrics and may require surgical consultation. Knowledge of the immunization status of the patient and dog is essential in the prevention and sequela of tetanus and rabies. The subsequent information is essential for any physician working with children and their families, particularly in the emergency setting.

Keywords: dog bites, wound infection, bite management, antibiotics, trauma, rabies and tetanus vaccinations

1. Introduction

According to the American Veterinary Medical Association, over 48 million households in the United States own a pet dog. This equates to 38.4% of all Americans owning a dog. The estimated total number of dogs in the United States is approximately 76.8 million [1]. With these statistics in mind, it is not surprising that an estimated 4.5 million dog bites occur each year [1, 2]. Of these, approximately 800,000 seek medical attention and 386,000 require treatment in the Emergency Department [3].

Over the past 16 years, canines killed 568 Americans [2]. Pit bulls constitute 6.2% of the total US dog population but accounted for 380 (67%) of these fatalities [2]. Rottweilers had the second-largest contribution with 51 (9%) fatalities [2]. The other breeds implemented included American bulldogs, German shepherds, Mastiffs, Bull Terriers, Cane Corso, Belgian Malinois, Labrador retriever, and mixed-breeds [2].

In 2020, there were 46 fatalities from dog bites [2]. Pit bulls accounted for 33 (72%) of these deaths [2]. Of the dogs whose gender was known, 82% were male [2]. Fatal dog attacks involving multiple dogs accounted for 43% (20) of the victims [2]. Of these 20 attacks, 14 (70%) involved two or more pit bulls [2]. The data also showed that 20% (9) of dog bite fatalities involved dogs with a known history of human aggression and 13% (6) had a history of animal aggression [2].

In addition, the majority of dog bite victims were over 19 years of age (61%) [2]. Among the pediatric cohort of children 18 years or younger, 53% were infants less than 12 months of age [2]. Unfortunately, family dogs resulted in 59% (27) of the

fatalities over the past year [2]. Of the 33 deaths inflicted specifically by pit bulls, 55% (18) were family members while 45% (15) were non-family members [2].

Location of dog bite injuries, laceration, or puncture wounds, is an important discussion point among children. Recent studies have reported that the average age of children who receive a dog bite is about 5 years of age [4, 5]. The most severe injuries requiring repair in an operating room involve children less than 3 years of age and tend to be above the clavicle [5, 6]. Rupture globes, avulsed ears, lips, nose, and eyelids have all been reported. The location of dog bite injuries appears to correlate with the child's age. As mentioned, younger children have a higher risk of sustaining injuries to their facial structures, scalp, and neck [5, 6]. Older children, because they are taller, are more likely to have injuries to their hands, feet, and extremities [5, 6]. One study reported that up to 92% of all dog bites in children are located in the head and neck region, followed by the extremities (15.7%) and the trunk (4.9%) [5]. The majority of children are bitten in only one anatomic location [6]. The most common setting for sustaining a dog bite injury was the home [5]. A parent was present at the time of injury for almost half of the cases (43.6%) [5]. The circumstances surrounding an attack, when documented, identified 39.2% of children were playing with the dog [5]. Other scenarios included no initiated interaction (18.9%), attacks related to food, especially disturbing a dog when it is eating (13.5%), territorial encounters (9.5%), intervening between fighting animals (5.4%), playing with another person (5.4%), and disturbing a dog while asleep (4.1%) [5].

2. Trauma management/advanced trauma life saving

No matter the method of injury, Emergency Medicine (EM) physicians should always adhere to the Advanced Trauma Life Support (ATLS) protocol when initially assessing a patient. Studies have shown that patient outcomes are significantly improved when trauma teams follow the ATLS guidelines [7, 8]. Beginning with the primary survey, physicians should immediately assess the most vital and basic aspects of the patient's status [7, 8].

Airway: Determine the patency of the airway. Be aware of any tongue swelling, blood, or other possible causes of occlusions. Injuries or deformities of the neck and foreign bodies embedded in the soft tissue can also cause obstruction. Placement of a hard cervical collar if deemed necessary. Consider intubation if significantly occluded and all attempts to alleviate obstruction fail (jaw thrust maneuver, manual removal of any foreign body, etc) and bag-valve-mask technique is partial or ineffective. Preparation for a surgical airway may be indicated.

Breathing: Assess for difficulties with respiration as this may indicate an injury to the chest wall or pneumothorax. Palpate and visually inspect the chest wall for tenderness, crepitus, or deformity. If stable, consider imaging of the lung fields during the secondary survey.

Cardiovascular: Check central and peripheral pulses. Inspect the skin for color, warmth, and compromised blood flow. If there is an openly bleeding wound, apply pressure and/or tourniquet. During the primary survey, consider an ultrasound per FAST exam protocol. Follow the Advanced Cardiac Life Support (ACLS) protocol if the cardiac injury is suspected.

Disability: Using the Glasgow Coma Scale (GCS), determine the neurologic status of the patient. Assess the pupillary size, pupillary response, and consider Head/Cervical Spine CT (computer tomography) if concerns are present. Consult

neurosurgery if there are alterations from baseline or alarming findings (Cushing's triad, asymmetric pupils, focal neurologic deficits).

Exposure: Remove all articles of clothing to obtain full inspection of any deformities, lacerations, bruising, or excoriations. Ensure the patient's core temperature remains stable.

Once the primary survey has been completed, the secondary survey can begin. The provider can gather specific details about the event, particularly involving the history of both the dog and patient. For the patient, ask questions about the medical history, surgical history, and immunization status. In particular, when did the patient receive their last tetanus vaccine, and if they have ever been vaccinated against rabies. Determine if the patient has any comorbidities including immunodeficiency, immunocompromised status, vaccine status, surgical/dental implants, or diabetes mellitus. Lastly, inquire about drug allergies, particularly to penicillin, given antibiotics are often required. Other necessary questions include the events leading up to the attack, was it provoked or unprovoked, how many dogs were present, time of injury, how much time has elapsed since the bite, what was done before presenting to the ED to clean the wound, the last time they ate/drank, and the location of the attack (for example, was it in a home, at a park, etc). If available, determine the dog breed, rabies vaccine status, and if the dog has a previous record of biting humans.

3. Basic wound management

Determining whether a wound should have primary versus delayed closure remains controversial [3, 9]. Traditionally, it was suggested that wounds should be left open for fear of the increased risk of wound infection when sutured closed [3, 9]. Treatment initially involved daily dressings with antibacterial ointment or hydrogen peroxide, followed by secondary closure 2–7 days later [3]. However, other more recent studies have found that there was no significant difference in infection rate between primary and delayed closure of dog bite wounds [3]. These studies advocate that early washout, debridement, and primary wound closure leads to similar infection rates but improvement in cosmetic and functional results [3, 9]. Two particular scenarios universally recommend delayed closure: if the bite is a puncture wound rather than a laceration, and if more than 12 hours has elapsed before the patient is seen by a medical professional [3].

3.1 Antibiotic regimen

Antibiotic prophylaxis is recommended for high-risk bites. These include presentation 8+ hours after the bite, moderate to severe wounds, patients who are immunocompromised or diabetic, deep puncture wounds, or bites involving the hand or face [3]. No prophylaxis is necessary for scratch wounds. Some studies suggest the use of antibiotic prophylaxis for infants and patients older than 50 years, irrespective of the appearance of the wound [3]. The first-line therapy (see **Table 1**) for both prophylaxis and treatment of dog bites is oral amoxicillin-clavulanate [3, 4, 9]. If the patient has a penicillin allergy, oral extended-spectrum cephalosporins (ceftriaxone, cefotaxime) or trimethoprim-sulfamethoxazole plus clindamycin is recommended [3, 4, 9]. For more severe wounds, consider intravenous ampicillin-sulbactam or meropenem [3, 4, 9]. If the patient seems to be worsening under the coverage of ampicillin-sulbactam, consider adding MRSA coverage with either trimethoprim-sulfamethoxazole or clindamycin

Injury type	Time course	Antibiotic	PCN allergy
Prophylactic	3–5 days	PO Amoxicillin-clavulanate	PO cefpodoxime or trimethoprim-sulfamethoxazole PLUS clindamycin
Cellulitis/soft tissue infection	7–10 days	PO Amoxicillin-clavulanate or IV Ampicillin-sulbactam	PO cefpodoxime or trimethoprim-sulfamethoxazole PLUS clindamycin
Severe cellulitis/soft tissue infection	10–14 days	IV Ampicillin-sulbactam + Vancomycin	IV Ceftriaxone or trimethoprim-sulfamethoxazole PLUS clindamycin OR meropenem alone

PCN, penicillin; PO, Oral; IV, Intravenous.¹Source: Adapted from references 3, 4, and 9.

Table 1.
Antibiotic management of dog bite injuries based on type of infection¹.

based on the hospital's local resistant patterns [4]. If the patient requires hospitalization, vancomycin would be the additional antibiotic of choice for MRSA coverage [4]. The length of time recommended for prophylactic treatment is 3- to 5-days, with close follow-up in 24–48 hours to monitor for signs of developing infection [4]. For a soft tissue infection, a 7- to 10-day course of therapy is typically sufficient [4, 9]. However, a 10- to 14-day course may be warranted for more severe infections [4, 9].

3.2 Wound care

Approximately 5–25% of all dog bite wounds in children become infected [10]. The bites most likely to become infected include deep (puncture) contaminated wounds; areas marked with tissue destruction, poor perfusion, or edema; attacks to the hands, feet, face, or genitals; and wounds with joint involvement [9–11]. Wound infections after a dog bite are usually polymicrobial and consist of both aerobic and anaerobic bacteria from the mouth flora of the biting animal [9–11]. An average of 2–5 different bacterial isolates per culture were reported in a series of infected wounds caused by dog bites [9, 11]. *Pasteurella spp.* are the most common pathogen isolated and are found to have high carriage rates in the oropharynx, making bite wounds an easily transmittable method for infection [9–11]. Other pathogens identified in dog bites include, but are not limited to, *Corynebacterium* group G, *Neisseria weaveri*, *Capnocytophaga canimorsus*, *Fusobacterium nucleatum*, *Bacteroides tectus*, *Prevotella heparinolytica*, *Propionibacterium acnes*, *Peptostreptococcus anaerobius*, *Streptococcus pyogenes*, *Staphylococcus aureus*, and *Moraxella catharralis* [9, 11]. *Pasteurella* species were found to have the shortest latency period between bite and onset of infection [11]. They are also more commonly cultured from abscesses compared to the other species listed above [11]. The second most common bacterium isolated from dog bites was a tie between *Staphylococcus* and *Streptococcus* species [11]. Both were notable for being found most frequently in nonpurulent wounds, such as cellulitis and lymphangitis [11].

Signs of infection can present within hours to days of the initial bite and may include pain, erythema, and/or swelling of the affected area [9–11]. A multicenter, prospective study of 50 dog bite wounds found that the majority of infections were purulent without abscess formation (58%), followed by nonpurulent wounds with cellulitis, lymphangitis, or both (30%), and abscess formation resulting in the smallest number of presenting infections (12%) [11].

Treatment of the wound should begin with gentle irrigation using normal saline. The amount depends on the size and nature of the wound but typically ranges from 250 to 500 mL, or 50 to 100 mL/cm of laceration [4, 10, 11]. A 20 mL or larger syringe or catheter should be used to ensure enough pressure is applied to properly clean the wound [4, 10, 11]. If the wound is large or complex, surgical evaluation may be necessary to fully examine the wound for neurovascular, muscular, and soft tissue damage. A radiograph may be necessary if there is a concern for fractures or broken teeth or deeper puncture wounds concerning the development of osteomyelitis [4, 10].

3.3 Wound closure

Based upon the nature and characteristics of the injury, there are multiple options for wound closure. As previously discussed, there is intense debate surrounding primary vs. secondary closure of dog bite injuries. Once a decision has been made if or when the closure is necessary, there are several options on the technique of closure. The gold standard for wound closure is suturing [12]. Non-absorbable sutures are more applicable for partial-thickness wounds that can be easily released after healing [12]. Absorbable sutures are used for deeper or full-thickness wounds as a double-layer of closure and to decrease the tension on the primary sutures above [12]. Once the type of suture has been determined, the technique for suturing needs to be decided. Simple interrupted sutures tend to be more cosmetically appealing and allow for a better approximation of the wound edges [12]. However, if there is a need for rapid hemorrhage control or an extensive wound, running sutures allow for quick application but have a greater risk of dehiscence [12]. Finally, mattress stitches should be applied to deeper wounds due to their ability to employ deeper penetration with greater strength of wound closure [12]. In children, the use of an adhesive such as skin glue or skin tape can be considered but remains controversial in the context of dog bite wounds [12]. These options are excellent for percutaneous wounds and allow for less painful procedures, both with placement and removal. Another option for wound closure are staples, which can be placed quickly and are most useful in settings with brisk bleeding [12]. If there are multiple non-facial lacerations, staples are an efficient, cost-effective, and simple technique but may not be ideal for cosmesis.

3.4 Scar management

There are varying opinions on the appropriate recommendations for scar prevention and management. However, the initial step is to ensure proper primary suturing technique with the absence of tension on the wound and accurate approximation of the wound edges [12–15]. The wound should be closed with as little traction as possible and force should be minimized to cause further tissue damage [13–15]. Refer to **Table 2** for recommendations on when sutures should be removed for complete healing [12–15, 16]. Skin tape can be applied to the area to continue to reduce tension and antibiotic ointment is no longer needed [12]. The following days to weeks after the initial injury, wound hydration becomes crucial [13–15]. Daily to every other-day dressing changes and cleaning with saline or tap-water is vital [13–15]. Never use alcohol or iodide solutions because of their cytotoxic nature, which inhibits healing and increases scar formation [13–15]. Silicone gel sheeting has also been shown to be effective in the treatment and prevention of scars by increasing hydration and decreasing collagen deposition [14, 15]. If there is a concern that keloid formation will occur, referral to a dermatologist for further management is recommended. There,

Location	Removal time (days)
Face*	3–5
Chest/Abdomen	8–10
Arm/Leg**	8–12
Fingertip	10–12
Foot	12–14

*Scalp removal 6–8 days.
 **Add 2–3 days if a joint is affected.
¹Source: adapted from reference [17].

Table 2.
 Suture removal recommendations based on location of injury¹.

they may recommend intralesional steroid injections, laser therapy, or antimetabolic drugs to help prevent or treat keloid and scar formation [15].

3.5 Severe wound management

When determining which patients are most likely to require hospitalization after being bitten by a dog, there are a few potential risk factors. Male children are more likely to sustain a dog bite than their female counterparts, which also makes them more likely to sustain a bite that requires hospitalization [17]. Additionally, non-Hispanic White children were more likely than their Black, Hispanic, and Asian peers to be hospitalized after a dog bite [17]. The summer months have the highest rate of dog bite hospitalization compared to any other season [17]. Of the children that were hospitalized, approximately 1/3rd required a major surgical procedure consisting of either debridement with suturing of the wound, skin grafting, plastics’ surgical intervention, or tissue reconstruction [17]. Overall, the predominant description of children requiring hospitalization after a dog bite were of Caucasian ethnicity, male, less than 10 years of age, and received deep, extended, or multiple sites of injury [17].

3.5.1 Facial

A 20-year review of dog bites to the head and neck region found that 49.33% were 18 years of age or younger [18]. The majority of the lesions were sustained in the upper lip (32%), cheek (27%), and nose (20%) [18]. Periorbital or orbital wounds were rare [18]. The majority of the wounds were closed with primary methods using either sutures or adhesive strips (63%) due to their uncomplicated nature [18]. However, determining the method of closure should be based on the depth and underlying involvement of the wound. Please see the *Lackmann classification of injury* below for further details on how to classify the extent of a facial lesion. By classifying the lesion using the Lackmann system, it can help a provider to determine prognostic status and best method(s) for management of the wound. A transposition flap or reconstructive surgery was required in a small subset (6.7%) and skin grafting in an even smaller portion (3%) with more severe injuries [18]. Secondary wound infections were reported in only 2.24%, based on the theory that blood flow is enhanced to the face and neck regions leading to decreased incidence of infection [18]. However, it should be noted that prophylactic antibiotics were prescribed in 95% of cases likely contributing to the low infection rate [18].

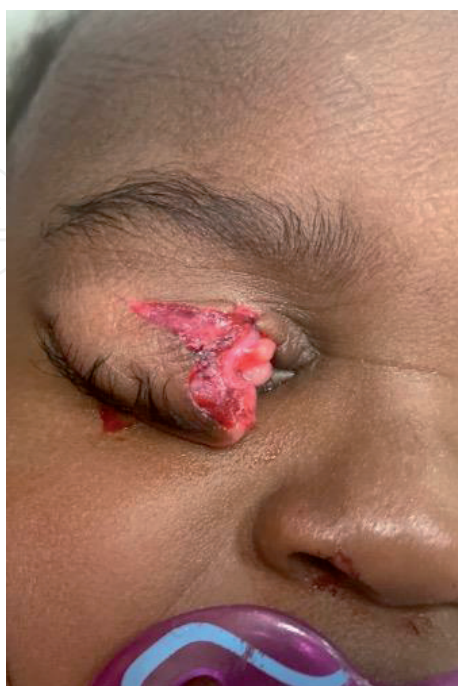A second review detailing the otolaryngology perspective on head and neck injuries details that 26.8–56.5% of dog bites occur to the head or neck [19]. Infection rates are reported to be as low as 5.7% due to the vascularized nature of the tissue [19]. The current recommendation is primary closure of head and neck wounds unless the results would be cosmetically displeasing [19]. ENT/OMFS and/or Plastics specialists should be consulted to help with esthetics and determination of closure technique. Additionally, current recommendations require amoxicillin-clavulanate therapy for 3–5 days whenever dog bites involve the face [19]. If signs of infection develop, the course should be extended to 7–14 days [3–4, 9, 19].

3.5.2 Lackmann classification of facial injury

- i. Superficial lesion without muscular involvement
- ii. Deep lesion with muscular involvement
- iii. Deep lesion with muscular involvement and tissue defect
- iv. Class III + vascular damage or neural lesions
- v. Class III + bony damage or organ involvement

3.5.3 Orbital

The majority of periocular or orbital involvement in dog bite wounds are eyelid lacerations (**Figure 1**) or eyelid marginal lacerations [19]. Experts recommend primary closure within 24 hours and prophylactic antibiotics with amoxicillin-clavulanate [19].



Courtesy of Jeffrey Louie, M.D.

Figure 1.
Full thickness laceration to superior eyelid. Courtesy of Jeffrey Louie, M.D.

Ensure that there is no corneal abrasion, orbital fractures, or ruptured globe associated with the injury [19, 20]. Use a woods lamp with fluorescein, unless a suspected ruptured globe is suspected, to visualize any corneal abrasions [19, 20]. If a ruptured globe is high on the differential, obtain facial CT which would show a deflated orbit if positive for globus rupture [19, 20]. Consider an additional head CT if there are further concerns for cranial injury or the patient has altered mental status [19, 20].

3.5.4 Genitalia

Copious irrigation with normal saline, debridement, and primary closure are the recommended steps in correcting dog bite lesions of the genitalia [21]. One of the biggest concerns for male genitalia wounds is the unilateral or bilateral loss of the testis. If this occurs, an ultrasound to look for torsion or hematocele formation is necessary after the attack, and an urgent urology consult is recommended [21]. Urethral injuries must also always be excluded in the cases of genitalia involvement [21]. Placement of a foley or cauterization for urine is contraindicated. Urethral endoscopy is the recommended next step after physical examination or known ureteral damage before surgical intervention [21].

3.5.5 Dental

Although not much research has been conducted on dental injuries secondary to dog attacks, it can be assumed that tooth avulsion or gingival laceration can occur [19, 22]. This is particularly relevant in cases of facial injury [19, 22]. If a patient presents with an avulsed tooth, the medium found to keep the tooth most viable is milk [23]. Current data suggest the tooth may only be viable for 30–60 minutes, thus reimplantation by the EM or dental specialist should occur as soon as possible. Gingival lacerations should always be inspected and repaired by the dental specialist.

4. Tetanus and Rabies

In addition to causing a localized infection, dog bites may also transmit pathogens that can cause a systemic illness. The most commonly considered sequelae are tetanus and rabies [4, 9, 24, 25].

4.1 Tetanus

The management of tetanus prophylaxis in dog bites is based upon the immunization status of the affected patient (see **Table 3**). If the child has received less than 3 doses of the tetanus toxoid-containing vaccine or the vaccination status is unknown, human tetanus immunoglobulin should be administered as well as a dose of tetanus toxoid-containing vaccine [24]. For those that have completed a 3-dose series, determine if/when the last dose was administered and if they have undergone any booster shots. If the last tetanus vaccine was 5 or more years ago, it is recommended that they receive a booster dose of the age-appropriate tetanus vaccine [24].

4.2 Rabies

Fortunately, rabies infections are a rare occurrence. Prevention is critical, particularly when the outcome is approximately 100% mortality when infection

Received doses of tetanus toxoid	Received doses of DTap, Tdap, or Td	Administer DTap, Tdap, or Td	Administer TIG
<3 doses or unknown		YES	YES
3 or more doses	≤ 5 years since last tetanus toxoid containing vaccine	NO	NO
	>5 years since last tetanus toxoid containing vaccine	YES	NO

¹Source: adapted from reference 25.

Table 3.
 Guideline for tetanus vaccines and immunoglobulin¹.

develops [9, 25]. Post-exposure rabies prophylaxis is provided to approximately 40,000 people per year [9]. Between 1 and 3 people die per year in the United States from a rabies infection [25]. When an animal infected with rabies bites a person, the saliva containing the rabies is deposited into the tissues and incubates for 20 to 90 days [4, 25]. The virus then travels to the central nervous system where it causes the rapid development of symptoms [4, 25]. The first step in determining what type of rabies prophylaxis is needed is to evaluate the health of the dog. If the pet is healthy and able to be observed for 10 days, then prophylaxis only needs to be administered if the animal begins exhibiting signs of rabies development [9, 25]. If the dog is known or suspected to be rabid, rabies immunization and rabies immunoglobulin should be administered as soon as possible [9, 25]. The animal itself should be euthanized and tested for rabies as soon as possible [9, 25]. Immunization can be discontinued if there are negative test results [9, 25]. If the status of the animal is unknown, consult the local public health department for guidance.

Use of both active and passive prophylaxis is warranted once wound care has been completed and the patient is categorized as needing postexposure prophylaxis [9, 25]. Unvaccinated or immunocompetent children need the full 4-dose series of rabies vaccinations along with the human rabies immune globulin [9, 25]. Rabies immunoglobulin should be administered around the wound and given only on day 0 [9, 25]. The vaccinations should be scheduled on days 0, 3, 7, and 14 of wound infliction [9, 25]. Children who have previously undergone rabies vaccination should receive only a vaccine booster shot and do not require rabies immunoglobulin [9, 25]. All animal bites should be reported to the county and state health department and local animal control for record maintenance [25].

5. Further considerations

5.1 Animal control

Dog “perpetrators” are not commonly reported unless a police or animal control report is filed. A dog with multiple offenses may go undetected to law enforcement unless victims report their injuries, provide the name or address of the dog owner, and breed of dog. At our institution, all dog bites are reported to the county animal control agency. Potentially, a dog owner with a record of multiple reports could be reprimanded with fees or have their dog removed from the house.

5.2 Prevention and anticipatory guidance to dog owners

As previously discussed, the majority of dog bites are caused by household pets or animals known to the victim [2, 26]. Many of the attacks occur in or around the family home [2, 26, 27]. By nature, dogs are social animals that navigate within a pack hierarchy [26]. Communication is relayed through both vocal means and body language, which can be missed or misinterpreted by their human counterparts [26]. The posture, tail movements, facial features, and noises made by the dog can often provide information on an imminent attack [26]. Of course, this is not to say that the victim is to blame for a dog attack. Rather, dog owners should be made aware of signs of aggression and how to properly respond to them. There are plenty of resources available through the internet or local canine training programs for owners to learn techniques of de-escalating signs of aggression. Additionally, children should never be left unsupervised with a dog. Some tips to help prevent dog bites include:

- Do not disturb any dog caring for puppies, eating, or sleeping
- Never reach through or over a fence to pet a dog
- Do not run away from or chase after a dog
- Teach children to move slowly and pet gently
- Always allow the dog to sniff your hand before petting them
- Never approach an unfamiliar dog
- If an unfamiliar dog approaches, stand still with your arms at your side. Allow it to sniff you and move on. No sudden moves.

5.3 Psychological Sequelae of dog bites

Although poorly reported, the psychological impact of dog bites can range from avoidance behaviors to formally diagnosed post-traumatic stress disorder (PTSD) [27–29]. One study reports that nearly one-third of all children that suffered a dog bite injury developed a new fear or avoidance of dogs [29]. The same study found that 5% were diagnosed with PTSD at three months post-injury [29]. Symptoms of PTSD included numbness, apathy, avoidance behaviors, increased arousal, hypervigilance, and vivid recollections of the event [27–29]. These can present anywhere from immediately after the event to months later [27–29]. Additionally, an overwhelming 85% of parents whose children sustained a dog bite injury reported changes in their own emotional state [29]. Approximately two-thirds reported feelings of guilt and half reported fear and anger surrounding the event [29].

The first step toward recovery after a traumatic event is recognizing the effects it has had on the victim and those around them. Informing family members of the signs and symptoms of trauma is essential for identifying when professional help is needed [28–29]. As providers, referral to a psychiatrist or psychologist for therapeutic intervention is appropriate after any incidence of the dog attack, even if there are no apparent stress disorder symptoms [28, 29]. Particularly important for early

intervention are children who sustained multiple or severe dogs bite wounds, which has been shown to increase the risk of PTSD development [29].

6. Conclusion

An estimated 4.5 million dog bites occur each year with approximately 800,000 requiring medical attention [1–3]. As the number of households with pet dogs continues to rise, the incidence of dog bite injuries will grow. Physicians must be prepared to care for children with dog bite injuries. A number of retrospective studies of dog bite injuries in children have found that the most common age to sustain a bite is 5–9 years old [4, 5]. The majority of bite wounds are inflicted by the pit bull breed and occur in the home setting [1–3]. Fortunately, mortality is rare and there were only 46 cases of death secondary to dog bite injury in the year 2020 [2]. Location of the injury has been found to correlate with age; younger children sustain bites to the head and neck while older children tend to be bitten on the hands and upper extremities [5, 6]. The most extreme injuries requiring surgical intervention tend to occur in children less than 3 years of age [5, 6].

When acutely managing a dog bite, the first step is to follow the Advanced Trauma Life Saving (ATLS) guidelines. Begin with a primary survey of the airway, breathing, and circulation [7, 8]. Additionally, determine the neurologic status of the patient and determine any required immediate interventions. After stabilization, complete a secondary survey to gather specific details of the event and the medical history of the patient. In order to address the wounds, decide whether primary vs. secondary closure is warranted. As stated previously, there continues to be controversy over primary vs. delayed closure but recent studies have found that there is no significant difference in infection rate between the two methods [3]. Cosmetic and functional results can help to drive the decision, as well as any professional input from plastic surgery, otolaryngology, or dermatology. No matter which method of closure is decided upon, begin by irrigating the wound with normal saline using 250 mL–500 mL with a 20 mL syringe to ensure adequate pressure. Debride any necrotic tissue. Contact surgery for large, complex wounds.

Antibiotic prophylaxis is warranted for any high-risk bites, such as presentation 8+ hours after the bite, moderate to severe wounds, patients who are immunocompromised or diabetic, deep puncture wounds, or bites involving the hand or face [3]. Wound infections are usually polymicrobial, with the most common bacteria being *Pasteurella* spp. [9–11]. The first-line therapy for both prophylaxis and treatment of an infected dog bite is oral amoxicillin-clavulanate or parenteral ampicillin-sulbactam, depending on the severity [3, 4, 9]. If the patient has a penicillin allergy, oral extended-spectrum cephalosporins (ceftriaxone, cefotaxime) or trimethoprim-sulfamethoxazole plus clindamycin is recommended [3, 4, 9]. The prophylactic treatment course is 3–5 days; soft tissue infections should be treated for 7–10 days [3, 4, 9]. A 10–14 day course of therapy may be necessary for more severe infections, and up to 6 weeks for osteomyelitis [3, 4, 9].

In addition to localized infection, physicians should think about other possible sequelae of dog bites: tetanus and rabies. The management of tetanus prophylaxis and the decision to provide post-exposure rabies prophylaxis can be determined using the CDC guidelines or as stated above [9, 24, 25]. If the rabies vaccination status of the dog is unknown, contact a veterinarian or department of health agency for further guidance.

In conclusion, dog bite injuries to children are a common and potentially fatal issue. Physicians must know how to stabilize and treat these injuries, as well as methods of preventing dog bites. Each family, with or without a pet dog, should have a brief discussion regarding dog bite prevention in the primary care setting. If a bite has occurred, both family members and physicians should be aware of the potential psychological sequelae of dog bites and how to treat them.

Conflict of interest

The authors declare no conflict of interest.


Author details

Katlin VanDerhoef and Jeffrey P. Louie*

Division of Emergency Medicine, Department of Pediatrics, University of Minnesota Masonic Children's Hospital, Minneapolis, Minnesota, United States of America

*Address all correspondence to: matt532@umn.edu

IntechOpen

© 2022 The Author(s). Licensee IntechOpen. This chapter is distributed under the terms of the Creative Commons Attribution License (<http://creativecommons.org/licenses/by/3.0>), which permits unrestricted use, distribution, and reproduction in any medium, provided the original work is properly cited. 

References

- [1] U.S. Pet Ownership Statistics. 2017-2018 U.S. Pet Ownership & Demographics Sourcebook. American Veterinary Medical Association, Veterinary Economics Division Schaumburg, IL; 2017-2018. Available from: <https://www.avma.org/resources-tools/reports-statistics/us-pet-ownership-statistics>
- [2] Dog Bite Fatality Statistics. 2020. Dogsbite.org. Available from: <https://www.dogsbite.org/dog-bite-statistics-fatalities-2020.php>
- [3] Aziz H, Rhee P, et al. The current concepts in management of animal (dog, cat, snake, scorpion) and human bite wounds. *Journal of Trauma and Acute Care Surgery*. 2015;**78**(3):641-648
- [4] Bula-Rudas F, Olcott J. Human and Animal Bites. *Pediatrics in Review*. 2018;**39**(10):490-500. DOI: 10.1542/pir.2017-0212
- [5] Abraham J, Czerwinski M. Pediatric dog bite injuries in central Texas. *Journal of Pediatric Surgery*. 2019;**54**(7):1416-1420
- [6] Golinko M, Arslanian B, Williams J. Characteristics of 1616 consecutive dog bite injuries at a single institution. *Sage Journals: Clinical Pediatrics*. 2017;**56**(4):316-325
- [7] Carter E, Waterhouse L, et al. Adherence to ATLS primary and secondary surveys during pediatric trauma resuscitation. *Resuscitation*. 2013;**84**(1):66-71. DOI: 10.1016/j.resuscitation.2011.10.032
- [8] James D, Pennardt A. *Trauma Care Principles*. Treasure Island, FL: StatPearls Publishing LLC; 2021. Available from: <https://www.ncbi.nlm.nih.gov/books/NBK547757/>
- [9] Hurt J, Maday K. Management and treatment of animal bites. *Journal of the American Academy of Physician Assistants*. 2018;**31**(4):27-31. DOI: 10.1097/01.JAA.0000531049.59137.cd
- [10] Rothe K, Tsokos M, et al. Animal and human bite wounds. *Deutsches Arzteblatt International Journal*. 2015;**112**(25):433-443. DOI: 10.3238/arztebl.2015.0433
- [11] Abrahamian F, Goldstein E. Microbiology of animal bite wound infections. *Clinical Microbiology Reviews*. 2011;**24**(2):231-246. DOI: 10.1128/CMR.00041-10
- [12] Azmat C, Council M. *Wound Closure Techniques*. Treasure Island, FL: StatPearls Publishing LLC; 2021. Available from: <https://www.ncbi.nlm.nih.gov.ezp1.lib.umn.edu/books/NBK470598/>
- [13] Son D, Harijan A. Overview of surgical scar prevention and management. *Journal of Korean Medical Science*. 2014;**29**(6):751-757. DOI: 10.3346/jkms.2014.29.6.751
- [14] Grabowski G, Pacana M, et al. Keloid and hypertrophic scar formation, prevention, and management: standard review of abnormal scarring in orthopaedic surgery. *Journal of the American Academy of Orthopaedic Surgeons*. 2020;**28**(10):408-414. DOI: 10.5435/JAAOS-D-19-00690
- [15] Kerwin L, El Tal A, et al. Scar prevention and remodeling: A review of the medical, surgical, topical, and light treatment approaches. *International Journal of Dermatology*. 2014;**53**(8):922-936. DOI: 10.1111/ijd.12436

- [16] Trott A. Wounds and Lacerations: Emergency Care and Closure. 4th ed. Saunders. Philadelphia, PA: Elsevier; 2012
- [17] McLoughlin R, Cournoyer L, et al. Hospitalizations for Pediatric Dog Bite Injuries in the United States. *Journal of Pediatric Surgery*. 2020;**55**(7):1228-1233. DOI: 10.1016/j.jpedsurg.2019.06.025
- [18] Piccart F, Dormaar J, et al. Dog bite injuries in the head and neck region: A 20-year review. *Craniofacial Trauma Reconstruction*. 2019;**12**(3):199-204. DOI: 10.1055/s-0038-1660441
- [19] Mendoza J, Chi J. Reconstruction of animal bite injuries to the head and neck. *Current Opinion in Otolaryngology & Head & Neck Surgery*. 2019;**27**(5):407-412. DOI: 10.1097/MOO.0000000000000564
- [20] Lackmann G, Draf W, et al. Surgical treatment of facial dog bite injuries in children. *Journal of Craniofacial Surgery*. 1992;**20**(2):81-86. DOI: 10.1016/S1010-5182(05)80472-X
- [21] Bertozzi M, Appignani A. The Management of Dog Bite Injuries of Genitalia in Pediatric Age. *African Journal of Pediatric Surgery*. 2013;**10**(3):205-210
- [22] Mannion C, Graham A, et al. Dog bites and maxillofacial surgery: What can we do? *British Journal of Oral and Maxillofacial Surgery*. 2015;**53**(6):522-525. DOI: 10.1016/j.bjoms.2015.02.022
- [23] Adnan S, Lone M, et al. Which is the most recommended medium for the storage and transport of avulsed teeth? A systematic review. *Dental Traumatology*. 2018;**34**(2):59-70. DOI: 10.1111/edt.12382
- [24] Tetanus: For Clinicians. Centers for Disease Control and Prevention, National Center for Immunization and Respiratory Diseases, Division of Bacterial Diseases. Atlanta, GA: US Department of Health and Human Services; 2020. Available from: <https://www.cdc.gov/tetanus/clinicians.html>
- [25] Rabies H. Centers for Disease Control and Prevention. National Center for Emerging Zoonotic and Infectious Diseases, Division of High-Consequence Pathogens and Pathology. Atlanta, GA; 2021. Available from: https://www.cdc.gov/rabies/location/usa/surveillance/human_rabies.html
- [26] Munnynck K, Van de Voorde W. Forensic approach of fatal dog attacks: A case report and literature review. *International Journal of Legal Medicine*. 2002;**116**:295-300. DOI: 10.1007/s00414-002-0332-9
- [27] Dixon C, Mistry R. Dog bites in children surge during coronavirus disease-2019: A case for enhanced prevention. *Journal of Pediatrics*. 2020;**225**:231-232. DOI: 10.1016/j.jpeds.2020.06.071
- [28] Jakeman M, Oxley J, et al. Pet dog bites in children: management and prevention. *The BMJ: Pediatrics Open*. 2020;**4**:1. DOI: 10.1136/bmjpo-2020-000726
- [29] Peters V, Souttiar M, et al. Posttraumatic Stress Disorder After Dog Bites in Children. *The Journal of Pediatrics*. 2004;**144**(1):121-122. DOI: 10.1016/j.jpeds.2003.10.024