

We are IntechOpen, the world's leading publisher of Open Access books Built by scientists, for scientists

5,800

Open access books available

142,000

International authors and editors

180M

Downloads

Our authors are among the

154

Countries delivered to

TOP 1%

most cited scientists

12.2%

Contributors from top 500 universities



WEB OF SCIENCE™

Selection of our books indexed in the Book Citation Index
in Web of Science™ Core Collection (BKCI)

Interested in publishing with us?
Contact book.department@intechopen.com

Numbers displayed above are based on latest data collected.
For more information visit www.intechopen.com



Chapter

Chikungunya Neurological Manifestations: A Systematic Literature Review

*Jucier Gonçalves Júnior, Marília de Oliveira Bringel,
Leonardo Rodrigues de Morais,
Luiz Fernando de Castro Malinverno,
Giselle Vasconcelos Liberato,
Myllena Maria de Morais Pereira, Modesto Leite Rolim Neto,
Leonardo de Oliveira Cavalcante and Estelita Lima Cândido*

Abstract

Although the most common Chikungunya (do not capitalize the disease unless it is named after a proper noun such as Zika, Ebola or Carrion's Disease) manifestations are osteoarticular, those which bring the most morbidity and mortality are neurological, where thorough mapping through studies with a methodological outline have not yet been well structured. Therefore, the objective was to review the literature to identify neurological manifestations of CHIKV. We used the Virtual Health Library (VHL) and PubMed with the following descriptors: #1 "Chikungunya" [MeSH]; #2 "neurological manifestations" [MeSH] and their equivalents in the Portuguese language, selecting literature published between July 2007 to January 2018. From the 180 studies that were found, 30 were selected. Findings were divided into two subcategories: "Chikungunya: Typical Neurological Manifestations" and "Chikungunya: Severe Neurological Manifestations". The studies show that headaches were characterized as the most common symptom in adult patients affected by CHIKV, followed by meningeal involvement. Meningeal involvement is also a more serious clinical scenario associated with encephalitis, convulsions, polyneuropathies such as Guillain-Barré syndrome and death. CHIKV is a public health problem for many reasons including its chronic potential complications. Given the neurological symptoms, this disease is concerning in age extremes, for patients with comorbidities and for patients with more than one viral infection by arboviruses, in whom the most severe neurological manifestations are more common.

Keywords: Arboviruses, Chikungunya, Clinical Practice, Neurology, Systematic Review

1. Introduction

“In a true and perfect form, imperturbability is indissolubly associated with wide experience and an intimate knowledge of the varied aspects of disease”
(Sir William Osler)

Chikungunya virus is an *alphavirus* transmitted by arthropods, especially by mosquitos from the *Aedes* genus, being endemic in tropical areas in Africa and Asia. The virus is capable of causing large outbreaks in regions where the population has not previously immunized [1]. (Given the fact that there is not a currently available vaccine, is “immunized” the right term to use. I understand that immunity can occur through previous infection, but “immunized” often implies intentional vaccination.) In Brazil, the first autochthonous cases of the disease were identified in Oiapoque, state of Amapá (North), and Feira de Santana, state of Bahia (Northeast), in September 2014 [2]. According to data from the Brazilian Ministry of Health, in 2017 up until epidemiological week 25, 131,749 probable cases of CHIKV were registered in the country with an incidence rate of 63.9 cases/100,000 inhabitants; of these, 66,576 (50.5%) were confirmed in the state of Ceará (893.0 cases/100,000 inhabitants) [3]. During the year of 2018, Brazil registered 87,867 probable cases of Chikungunya in Brazil, with the Northeast region presenting 11,287 (12.9%) of these and the state of Ceará having an incidence of 17.6/100,000 inhabitants [4]. Chikungunya can evolve in three phases: acute with persistent symptoms up to 14 days, subacute with the sustainment of symptoms for up to three months and chronic, a phase in which symptoms last for more than three months [5]. Chikungunya commonly presents with symmetrical arthralgia and/or polyarthritits, disabling of hands, wrists, ankles, knees and feet and the associated symptoms of asthenia, myalgia, headache, nausea/vomiting, diarrhea, photophobia, retro-orbital pain, conjunctivitis, pruritic maculopapular rash, facial/peripheral edema and lymphadenopathy [6].

Between 20% and 50% of patients infected with CHIKV develop chronic arthralgia. Predicting who will develop chronic diseases is difficult because there are no markers for these [7]. The frequency of serious cases is 0.3%, being associated with a higher age (>65 years old) and the presence of comorbidities [8]. The most concerning manifestations are neurological (encephalitis, meningoencephalitis, myelitis, Guillain Barré syndrome), and bullous cutaneous and myocarditis [9]. Thus, although Chikungunya is frequently described as a self-limiting disease, rare, more severe disease forms have been observed with CHIKV, some being associated with deaths [1].

Therefore, the purpose of this study was to perform a systematic review to determine the typical and serious neurological manifestations caused by Chikungunya. Our hypothesis is that, despite advances and epidemiological studies, as well as screening, neurological manifestations are more disabling and serious, and therefore require more attention from the scientific community.

2. Material and methods

A systematic review of the literature using the Virtual Health Library (VHL), which hosts recognized databases, and PubMed was performed. Initially, the following descriptors were used: #1 "*Chikungunya*" [MeSH]; #2 "*neurological manifestations*" [MeSH], as well as their equivalents in the Portuguese language.

The period reported in the literature ranged from July 2007 to January 2018 due to the scarcity of articles on the subject. Compilation of the data was performed in January and November of 2018. Manuscript selection occurred primarily through the analysis of titles and abstracts. Article analysis followed the eligibility criteria:

Authors (year)	Sample (N)	Main findings
Khatri [10]	One (64-year-old male)	Encephalomyelitis with quadriparesis and urinary retention
Hossain et al. [11]	1,326	Headache 165 in confirmed cases and 860 in probable cases
Hamilton and Cruickshank [12]	One (77-year-old woman)	T2 Weighted Imaging Fluid Attenuated Inversion Recovery (T2WI/FLAIR) changes in the right medial temporal lobe one year left for the acute infection
Huits et al. [13]	269	Headache (124) and the joints involved 45 are spine
Mahto et al. (2018)	Two	One patient had Guillain-Barré syndrome (GBS) with bilateral lower motor facial nerve palsy, and meningoencephalitis with epidermal necrosis
Mehta et al. [14]	Five	Paraesthesia and tripareisis, hyperreflexic; urinary retention; confusion, dysarthria, headache, neck stiffness; spastic paraparesis; extensor plantars, palmomental reflex. Confusion, 1 x seizure, drowsiness, dysarthria. GSB. Hemiparesis. Confusion, impaired speech and swallow; flaccid hyporeflexic quadraparesis
Puccione-Soler et al. (2018)	One (69-year-old woman)	Slow thinking, inattention, and mild confusion
Cerny [15]	1196	encephalitis, optic neuropathy, neuroretinitis, and GBS
Méndez et al. [16]	830	Headache (633), photophobia (48), lethargia (1)
Sá et al. [17]	Four	Two patients had generalized tonic convulsive crises and a diminished level of consciousness. In third patient the ct revealed bilateral frontal hypoattenuation, whereas abnormal cellularity and elevated protein levels were detected in a csf analysis. The fourth patient had decreased level of consciousness and uncontrollable movements.
Acevedo et al. [18]	11	GBS. Symmetric motor polyneuropathy. Motor and sensory axonal neuropathy. Meningitis and Encephalitis. Meningoencephalitis
Langsjoen et al. [19]	194	Headache (7)
Torres et al. [20]	1069 (newborns)	Hyperalgesia/allodynia (97), Meningoencephalitis (12).
Macpherson et al. [21]	493	Headache (265)
Pinheiro et al. [22]	Three articles	One case of Encephalitis, one case of Meningitis and one case of GBS
Feldstein et al. [23]	1,929	Headache (316)
Kageguka et al. (2016)	381	Headache (92)
Mohite and Agius-Fernandez [24]	One (69-year-old woman)	Acute unilateral optic neuropathy as a delayed complication of Chikungunya virus (CHIKV) infection
Peper et al. (2016)	One (39-year-old female)	Headache and photophobia
Marimoutou et al. (2015)	646	Headache 39 in confirmed cases
Anderson et al. [25]	One (36-year-old)	Headache
Malik et al. [26]	10,715	Headache (5464)
Ramanchandran et al. (2014)	403	Headache (261)
Thiberville et al. [27]	76	Headache (38)

Authors (year)	Sample (N)	Main findings
Taraphdar et al. [28]	550	Headache (53)
Dupuis-Maguiraga [29]	876 (adults, children, and newborns)	Headache (613), Meningoencephalitis (140), SGB (8), Convulsion (192), encephalitis (52)
Mohan et al. [30]	2602	Headache (319), Consciousness altered (4), Photophobia (36)
Sissoko et al. [31]	1154 participants being 318 had confirmed chikungunya	Headache (258)
Singh et al. [32]	Ten cases of flaccid limb weakness following symptoms and signs suggestive of CHIKV	Four cases of flaccid limb weakness confirmed (4)
Ganesan et al. (2008)	AJNR Am J Neuroradiol	Three patients with CHIKV in CNS

Label: Guillain-Barré syndrome = GBS.

Table 1.
Main findings.

(1) At least a combination of the terms described in the search strategy were present in the title: (colon) (2) Articles were written in English, Portuguese or Spanish; (3) Articles addressed Chikungunya neurological manifestations; (4) Original articles with the full text available through the CAPES (Coordination of Personal Improvement of Higher Level) Periodicals Portal, a virtual library created by the Brazilian Ministry of Health where content is restricted to authorized users. Revision studies, letters to the editor, prefaces, brief communications corrections/recalls, comments, editorials, monographs, dissertations and theses were excluded. (It seems that corrections or recalls would be important if any addressed the manuscripts cited in the review.) Manuscripts that were repeated in more than one of the databases were counted only once. Some articles were excluded because they generally addressed arboviral disease symptomatology and/or showed *in vitro* or animal alterations. Since this is a systematic review, Resolution 510/16 of the Brazilian National Health Council (CNS) ensures the dispensation of submission to a Human Beings Research Ethics Committee.

To ensure trustworthiness of the findings, data collection was performed individually by two researchers with divergences being solved by a third senior researcher.

Each sample article was thoroughly read and the information was inserted in a spreadsheet (**Table 1**), including the author and publishing year; study sample and main study findings (PICOS). This review followed the Prism Protocol (<http://www.prisma-statement.org/>).

3. Results

According to the search strategy, from the 234 articles found, 30 were selected after the eligibility criteria were applied (**Figure 1**). These were then input in **Table 1**. The findings were then divided into two subcategories: “Chikungunya: Typical Neurological Manifestations” and “Chikungunya: Severe Neurological Manifestations”.

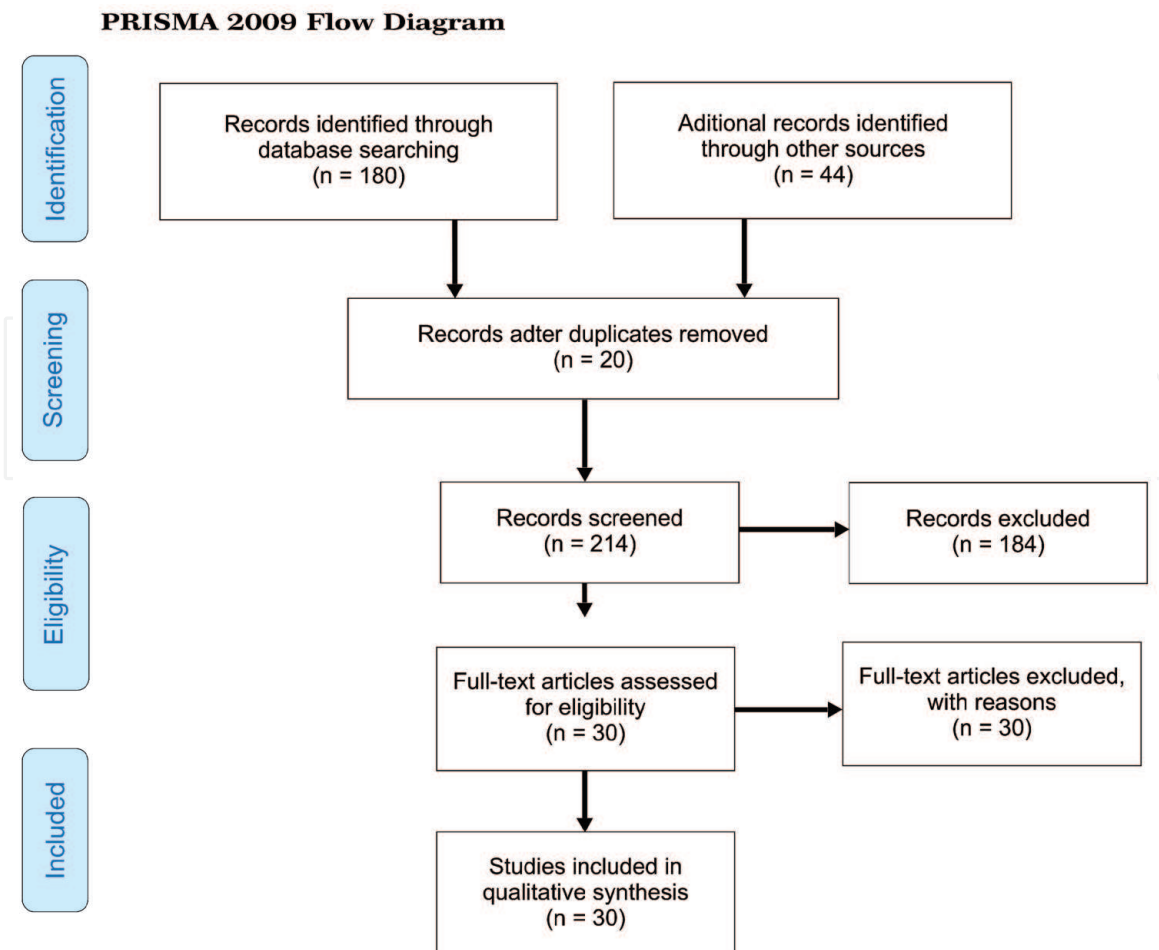


Figure 1.
PRISMA flow diagram (reproduced by Moher et al., 2009).

The studies [11, 14, 16, 19, 21, 23, 25–28, 30, 33–35] have shown that headache has been characterized as the most common symptom in adult patients with CHIKV, followed by meningeal involvement (meningitis or meningoencephalitis) [18, 20, 22], changes in consciousness level [17, 30, 36] and visual changes such as photophobia [16, 30, 33].

The most serious symptoms in patients exposed to CHIKV infection were central nervous system involvement: meningitis, encephalitis, meningoencephalitis [10, 14], seizures [12, 17]; and effects on the peripheral nervous system such as polyneuropathy - Guillain Barré syndrome [32] in addition to deaths [17, 18].

4. Discussion

4.1 Chikungunya: typical neurological manifestations

Our findings are in accordance with recent clinical studies published in Dehli [37]. Headache was the most common manifestation observed in the clinic, followed by meningoencephalitis which was consistent with the study by Huits et al. [13]. According to the authors, 73% of patients with CHIKV reported headache as a symptom. Sissoko et al. [31] reported a similar prevalence of headaches (81.4%) in a field evaluation during a Chikungunya outbreak in Mayotte.

Because Chikungunya is a febrile syndrome, it is common for a systemic cytokine elevation to displace the hypothalamic thermostat and thereby cause systemic signs of acute febrile infection. According to Chow et al., during an acute infection

arising from viremia, the production of alpha-interferon and IL-6, IL-1Ra, IL-12, IL-15, IP-10 and MCP-1 is observed. These cytokines cause collapse accompanied by a decrease in viral load, usually within 14 days [38].

On the other hand, studies in India and the Reunion Islands and Calcutta, the French colony in the Pacific Ocean, presented meningoencephalitis as the most common manifestation. Interestingly, other authors have also shown increased incidences of encephalitis in Asia [39, 40]. In Ecuador, 37.5% of patients with CHIKV viral RNA samples in their cerebrospinal fluid (CSF) had meningitis or encephalitis and 18.7% GBS [18]. A study carried out in the city of Rio de Janeiro, Southeastern Brazil, showed that of 212 cases of arboviruses (Zika and Chikungunya), 24.1% presented meningoencephalitis [18].

The involvement of the central nervous system seems to be associated with the patient's previous comorbidities [14, 15, 18, 41] and to the extremes of age [12, 29].

Studies with newborns have demonstrated hyperalgesia as the main symptom of neonates exposed to vertical transmission with an incidence ranging from 53–94% [20]. According to Castro, Lima and Nascimento [42], peripheral neuropathy with the predominance of a sensory component is the most common presentation in CHIKV, rarely being motor, and this would be explained in large part by the nervous compression process caused by CHIKV thus manifesting as pain and/or paresthesia.

4.2 Chikungunya: serious neurological manifestations

The most serious CHIKV cases are believed to be associated with tropism of the virus by to central nervous system (CNS) cells and, once again, with the extremes of age. According to recent data from experimental studies, CHIKV may attack the CNS by two mechanisms: direct injury and immune-mediated injury. Oligodendrocyte and astrocyte cultures displayed high susceptibility levels to CHIKV [22]. CHIKV has also previously shown tropism to the choroid plexus, cerebrospinal fluid, meninges and epididymal cells of fetuses, as well as extrauterine life. An increase in the incidence of encephalopathy in fetuses of mothers exposed to the virus during pregnancy has also been previously reported. In addition, its presence is believed to induce an immune mediated response by IL-6, G-CSF, GM-CSF, MCP1, TNF- α , CXCL9, CCL2 and CXCL10 resulting in immune response lesions [38]. The theory is that glial cells may have several pattern recognition receptors involved in viral particle detection, which would make them more sensitive to the virus's presence; in contrast, they may also have the potential production of antibodies which could cause great damage, providing an expressive synthesis of cytokines and chemokines in the presence of CHIKV [22]. An indication of this is the report of an acute unilateral optic neuropathy case as a late complication of CHIKV viral infection published in 2015 [24].

Another important factor which has been observed is the presence of co-infections by other arboviruses such as dengue and Zika [18]. In these cases, the aforementioned process is probably intensified, increasing therefore, the potential for CNS injury.

5. Final considerations

Chikungunya is a public health problem due to its capacity to develop chronic complications, causing morbidity and mortality given the severity of atypical manifestations. In the context of neurological manifestations, it appears that meningitis, meningoencephalitis and encephalitis are both common and severe complications, which indicate a worrying deleterious potential of this disease to the CNS,

especially in more vulnerable groups: extremes of age; patients with comorbidities; and patients with more than one viral infection by arboviruses.

Acknowledgements

We are grateful to the Medical Residency Program in Internal Medicine. We would also like to thank the School of Medicine, Federal University of Cariri (UFCA).

Conflicts of interests

The authors declare that there is no conflict of interests in this study.

Funding

The authors declare that they do not have funding resources.

Authors' contributions

JGJ, ELC, LOC, LFCM, LRM, MOB, MMMP, MLRN and GVL were responsible for the study design, conducting the systematization and analysis of the data. All authors read and approved the final manuscript.

Author details

Jucier Gonçalves Júnior, Marília de Oliveira Bringel¹,
Leonardo Rodrigues de Moraes¹,
Luiz Fernando de Castro Malinverno¹, Giselle Vasconcelos Liberato¹,
Myllena Maria de Moraes Pereira², Modesto Leite Rolim Neto^{2*},
Leonardo de Oliveira Cavalcante¹ and Estelita Lima Cândido²

¹ Departament in Internal Medicine, Santa Casa de Misericórdia de Fortaleza, Fortaleza, CE, Brazil

² School of Medicine, Universidade Federal do Cariri – UFCA, Barbalha, Ceará, Brazil

*Address all correspondence to: modesto.neto@ufca.edu.br

IntechOpen

© 2021 The Author(s). Licensee IntechOpen. This chapter is distributed under the terms of the Creative Commons Attribution License (<http://creativecommons.org/licenses/by/3.0>), which permits unrestricted use, distribution, and reproduction in any medium, provided the original work is properly cited. 

References

- [1] Yactayo S, Staples JE, Millot V, Cibrelus L, Ramon-Pardo P. Epidemiology of Chikungunya in the Americas. *J Infect Dis.* 2016;214 (suppl 5):S441-S445.
- [2] Silva NM, Teixeira RAG, Cardoso CG, Siqueira Junior SB, Coelho GE, Oliveira ES. Vigilância de chikungunya no Brasil: desafios no contexto da Saúde Pública. *Epidemiol. Serv. Saude, Brasília,* 27(3): e2017127, 2018.
- [3] Brasil. Ministério da Saúde. Secretaria de Vigilância em Saúde. Monitoramento dos casos de dengue, febre de chikungunya e febre pelo vírus Zika até a Semana Epidemiológica 25, 2017. 48(2017) pp. 1-10. Acess February, 15 2019. Available in: http://combateaedes.saude.gov.br/images/boletins-epidemiologicos/Boletim-2017_020-Monitoramento-dos-casos-de-dengue-febre-de-chikungunya-e-febre-pelo-Zika.pdf HYPERLINK "http://combateaedes.saude.gov.br/images/boletins-epidemiologicos/Boletim-2017_020-Monitoramento-dos-casos-de-dengue-febre-de-chikungunya-e-febre-pelo-Zika.pdf".
- [4] Brasil. Monitoramento dos casos de dengue, febre de chikungunya e doença aguda pelo vírus Zika até a Semana Epidemiológica 52 de 2018. 50 (2019), pp.1-14. Acess February, 15 2019. Available in: <http://portalarquivos2.saude.gov.br/images/pdf/2019/janeiro/28/2019-002.pdf>
- [5] Chopra A, Anuradha V, Ghorpade R, Saluja M. Acute chikungunya and persistent musculoskeletal pain following the 2006 Indian epidemic: a 2-year prospective rural community study. *Epidemiol Infect.* 2012;140:842-850.
- [6] Madariaga M, Ticona E, Resurrecion C. Chikungunya: bending over the Americas and the rest of the world. *Braz J Infect Dis.* 2016;20:91-98.
- [7] Anfasa F, Provacia L, GeurtsvanKessel C, Wever R, Gerstenbluth I, Osterhaus ADME et al. Hyperferritinemia is a potential marker of chronic chikungunya: A retrospective study on the Island of Curaçao during the 2014-2015 outbreak. *J Clin Virol.* 2016;18(86):31-38.
- [8] Marques CDL, Duarte ALBP, Ranzolin A, Dantas AT, Cavalcanti NG, Gonçalves RSG et al. Recomendações da Sociedade Brasileira de Reumatologia para diagnóstico e tratamento da febre chikungunya. Parte 1 – Diagnóstico e situações especiais. *rev bras reumatol.* 2017;57(S2):S421–S437.
- [9] Donalísio MR, Freitas ARR. Chikungunya no Brasil: um desafio emergente. *Rev Bras Epidemiol.* 2015;18(1): 283-285.
- [10] Khatri H, Shah H, Roy D, Tripathi KM. A Case Report on Chikungunya Virus- Associated Encephalomyelitis. *Case Rep Infect Dis.* 2018:8904753.
- [11] Hossain MS, Hasan MM, Islam MS, Islam S, Mozaffor M, Khan MAS, et al. Chikungunya outbreak (2017) in Bangladesh: Clinical profile, economic impact and quality of life during the acute phase of the disease. *PLoS Negl Trop Dis* 2018;12(6): e0006561.
- [12] Hamilton PL, Cruickshank G. Delayed central nervous system manifestation of Chikungunya virus with magnetic resonance T2 weighted imaging high signal changes—a case report. *Journal of Surgical Case Reports,* 2018;6, 1-3.
- [13] Huits R, Kort J, Berg RVD, Chong L, Tsoumanis A, Eggermont K et al. Chikungunya virus infection in

Aruba: Diagnosis, clinical features and predictors of post-chikungunya chronic polyarthralgia. *PLoS One*. 2018; 13(4): e0196630.

[14] Mehta R, Soares CN, Medialdesa-Carrera R, Ellul M, Silva MTT, Rosala-Hallas A, et al. The spectrum of neurological disease associated with Zika and chikungunya viruses in adults in Rio de Janeiro, Brazil: A case series. *PLoS Negl Trop Dis*. 2018;12(2):e0006212.

[15] Cerny T, Schwarz M, Schwarz U, Lemant J, Gérardin P, Keller E. The Range of Neurological Complications in Chikungunya Fever. *Neurocrit Care*. 2017;27(3):447-457.

[16] Méndez N, Baeza-Herrera L, Ojeda-Baranda R, Huchim-Lara O, Gómez-Carro S. Perfil clínicoepidemiológico de la infección por Chikungunya en casos hospitalarios atendidos en 2015 en Mérida, México. *Rev Panam Salud Publica* 2017; 41: e91.

[17] Sá PKO, Nunes MM, Leite IR, Campelo MGLC, Leão CFR, Souza JR, et al. Chikungunya virus infection with severe neurologic manifestations: report of four fatal cases. *Rev Soc Bras Med Trop* 2017; 50(2):265-268.

[18] Acevedo N, Waggoner J, Rodriguez M, Rivera L, Landivar J Pinsky B, et al. Zika Virus, Chikungunya Virus, and Dengue Virus in Cerebrospinal Fluid from Adults with Neurological Manifestations, Guayaquil, Ecuador. *Front Microbiol*. 2017; 8: 42.

[19] Langsjoen RM, Rubinstein RJ, Kautz TF, Auguste AJ, Erasmus JH, Kiaty-Figueroa L, Gerhardt R, et al. Molecular Virologic and Clinical Characteristics of a Chikungunya Fever Outbreak in La Romana, Dominican Republic, 2014. *PLoS Negl Trop Dis*. 2016; 10(12): e0005189.

[20] Torres JR, Falleiros-Arlant L, Dueñas L, Pleitez-Navarrete J, Salgado DM, Castillo JBD. Congenital and perinatal complications of chikungunya fever: a Latin American experience. *Int J Infect Dis*. 2016; 51:85-88.

[21] Macpherson C, Noel T, Fields P, Jungkind D, Yearwood K, Simmons M, Widjaja S, et al. Clinical and Serological Insights from the Asian Lineage Chikungunya Outbreak in Grenada, 2014: An Observational Study. *Am J Trop Med Hyg*. 2016;95(4):890-893.

[22] Pinheiro TJ, Guimarães LF, Silva MTT, Soares CN. Neurological manifestations of Chikungunya and Zika infections. *Arq Neuropsiquiatr*. 2016;74(11):937-943.

[23] Feldstein LR, Ellis EM, Rowhani-Rahbar A, Halloran ME, Ellis BR. The First Reported Outbreak of Chikungunya in the U.S. Virgin Islands, 2014-2015. *Am J Trop Med Hyg*. 2016;95(4):885-889.

[24] Mohite AA, Agius-Fernandez A. Chikungunya fever presenting with acute optic neuropathy. *BMJ Case Rep*. 2015;2015: bcr2015210081

[25] Anderson KB, Pureza V, Walker PF. Chikungunya: Acute Fever, Rash and Debilitating Arthralgias in a Returning Traveler From Haiti. *J Travel Med*. 2014;21(6):418-420.

[26] Malik MR, Mnzava A, Mohareb E, Zayed A, Al Kohlani A, Thabet AA et al. Chikungunya outbreak in Al-Hudaydah, Yemen, 2011: epidemiological characterization and key lessons learned for early detection and control. *J Epidemiol Glob Health*. 2014;4(3):203-211.

[27] Thiberville SD, Boisson V, Gaudart J, Simon F, Flahault A, de Lamballerie X. Chikungunya fever: a clinical and virological investigation of

outpatients on Reunion Island, South-West Indian Ocean. *PLoS Negl Trop Dis*. 2013;7(1):e2004.

[28] Taraphdar D, Sarkar A, Mukhopadhyay BB, Chatterjee S. A comparative study of clinical features between monotypic and dual infection cases with Chikungunya virus and dengue virus in West Bengal, India. *Am J Trop Med Hyg*. 2012;86(4):720-723.

[29] Dupuis-Maguiraga L, Noret M, Brun S, Le Grand R, Gras G, Roques P. Chikungunya disease: infection-associated markers from the acute to the chronic phase of arbovirus-induced arthralgia. *PLoS Negl Trop Dis*. 2012;6(3):e1446.

[30] Mohan A, Kiran DH, Manohar IC, Kumar DP. Epidemiology, clinical manifestations, and diagnosis of Chikungunya fever: lessons learned from the re-emerging epidemic. *Indian J Dermatol*. 2010;55(1):54-63.

[31] Sissoko D, Ezzedine K, Moendandzé A, Giry C, Renault P, Malvy D. Field evaluation of clinical features during chikungunya outbreak in Mayotte, 2005-2006. *Trop Med Int Health*. 2010;15(5):600-607.

[32] Singh SS, Manimunda SP, Sugunan AP, Sahina, Vijayachari P. Four cases of acute flaccid paralysis associated with chikungunya virus infection. *Epidemiol Infect*. 2008;136(9):1277-1280.

[33] Pepper SM, Monson BJ, Van Schooneveld T, Smith CJ. That Which Bends Up: A Case Report and Literature Review of Chikungunya Virus. *J Gen Intern Med*. 2016;31(5):576-581.

[34] Kajeguka DC, Kaaya RD, Mwakalinga S, Ndossi R, Ndaro A, Chilongola JO, Mosha FW et al. Prevalence of dengue and chikungunya virus infections in north-eastern

Tanzania: a cross sectional study among participants presenting with malaria-like symptoms. *BMC Infect Dis*. 2016; 16: 183.

[35] Ramachandran V, Kaur P, Kanagasabai K, Vadivoo S, Murhekar M V. Persistent arthralgia among Chikungunya patients and associated risk factors in Chennai, South India. *J Postgrad Med* 2014;60:3-6.

[36] Puccioni-Sohler M, Farias LC, Cabral-Castro MJ, Zalis MG, Kalil RS, Salgado MCF. Cerebrospinal Fluid Immunoglobulins as Potential Biomarkers of Chikungunya Encephalitis. *Emerg Infect Dis*. 2018;24(5):939-941.

[37] Anand KS et al. Spectrum of neurological complications in chikungunya fever: experience at a tertiary care centre and review of literature. *Tropical Doctor*. 49 (2019),sp.

[38] Almino MIR, Dantas JMC, Silva AKA, Silva IBM, Gonçalves Júnior J, Oliveira MDR. Por quais mecanismos o vírus da Chikungunya atua no Sistema Nervoso Central de fetos?. In: XXVIII Congresso Brasileiro de Anatomia / XXXIX Congresso Chileno de Anatomia / IV Encontro das Ligas Estudantis de Morfologia, 2018, João Pessoa - PB. *Anatomia: A Arte na Essência da Vida*. São Paulo - SP: Sociedade Brasileira de Anatomia - SBA, 2018. v. 23.

[39] Chandak NH, Kashyap RS, Taori GM, Dagainawala HF. Neurological complications in Chikungunya infection. *BMC Proc*. 2008;2 Suppl 1:11.

[40] Rampal SM, Meena H. Neurological complications in Chikungunya Fever. *J Assoc Physicians India*. 2007;55:765-769.

[41] Pinheiro TJ, Guimarães LF, Silva MTT, Soares CN. Neurological manifestations of Chikungunya and

Zika infections. *Arq Neuro-Psiquiatr*,
2016; 74(11), 937-943.

[42] Castro APCR, Lima RA,
Nascimento JS. Chikungunya: a visão
do clínico de dor. *Rev Dor*, 2016;17(4):
299-302.

IntechOpen

IntechOpen