

*Actinic keratosis treated by topical Aloe barbadensis Mill.
(Aloe Vera) leaf gel*

Rosa Direito
João Boavida Ferreira
Ricardo Boavida Ferreira
Ana Lima

Introduction

Aloe vera is a cactus-resembling, succulent, watery plant, extensively used by the cosmetic and food industries[1]. Actinic keratosis, a dysplastic skin lesion commonly found in low Fitzpatrick skin type individuals[2] associated with chronic UV exposure[3,4], is defined by a scaly, keratotic or pigmented papule on an erythematous base[5].

The precursor to skin field cancerization is actinic keratosis, which is an area of photo-damaged skin containing subclinical genetic changes, a direct consequence of intraepithelial UV-induced damage[6,7]. Actinic keratosis, as a precancerous lesion, can develop into an invasive squamous cell carcinoma (ISCC)[6]. There is no way to predict which lesions will progress to ISCC, with guidelines recommending treatment of all actinic keratosis lesions[8-11].

Field-directed therapies are used to treat multiple actinic keratosis lesions and contiguous field cancerization subclinical lesions[12].

Case Report

A 56-year-old woman without a relevant medical history, presented in 2016 with a skin lesion on her right leg (having appeared 1 year before) growing progressively to around 1 cm long. The lesion was painless, non-itchy, dermis-deep with distinct, indurated borders, a necrofibrinotic center, and a watery exudate was present (**Fig. 1a**).

The patient was seen by a dermatologist in the United Kingdom on March 1, 2016. Dermatoscopy was performed revealing actinic keratosis. No skin biopsy was performed. The patient was prescribed a 5% 5-fluorouracil (5-FU) cream and a fusidic acid/betamethasone cream for daily application.

After 1 week of applying 5-FU and fusidic acid/betamethasone creams, lesion progression ensued (**Fig. 1b**), with size approximately doubling and with a central seropurulent discharge now appearing. Returning to the doctor after 3 weeks, the patient was told to reinforce the application of the fusidic acid/betamethasone cream. Unsatisfied with this recommendation, the patient decided to alternate between the 5-FU and the fusidic acid/betamethasone creams. By May, the seropurulent discharge had become abundant and the peripheral erythema had increased.

On a trip to Portugal during the first week of May, the patient decided to cease daily application of both creams and began a gel application of *Aloe barbadensis* Mill. (commonly *Aloe vera*) extracted directly from the leaf of an *Aloe vera* plant, taken from the existing collection of *Aloe* plants at the *Instituto Superior de Agronomia*, University of Lisbon, Portugal. At night the patient would sleep with an adhesive bandage around her leg with a slice of an unpeeled *Aloe vera* leaf in direct contact with the skin lesion. In the morning, after showering, the patient would massage the lesion with gel extracted directly from the plant's leaf. After just 1 week, the seropurulent discharge had stopped and the lesion's center had become fully necrotic. Peripheral erythema and edema had also effectively decreased (**Fig. 1c**). By late June 2016 there were clear signs that the lesion was rapidly healing (**Fig. 1d**).

Returning to London for a follow-up medical appointment on the 28th of June 2016, it was verified that a complete healing of the actinic keratosis had occurred. In November of 2016 new photos were taken of the lesional skin (**Fig. 1e** and **Fig. 1f**).

In March 2017, a new actinic keratosis lesion appeared in the patient's right leg, close to where the previous lesion had been. This time the patient immediately started using either a slice of *Aloe vera* leaf cut straight from the plant or the gel extracted from its leaves applied directly to the lesion. Application was done every morning after showering starting on March 9, 2017 until April 12, 2017. **Figs. 2a-f** show how the slice/gel of *Aloe vera* was applied and how the actinic keratosis remitted. Progressive resolution of the actinic keratosis was

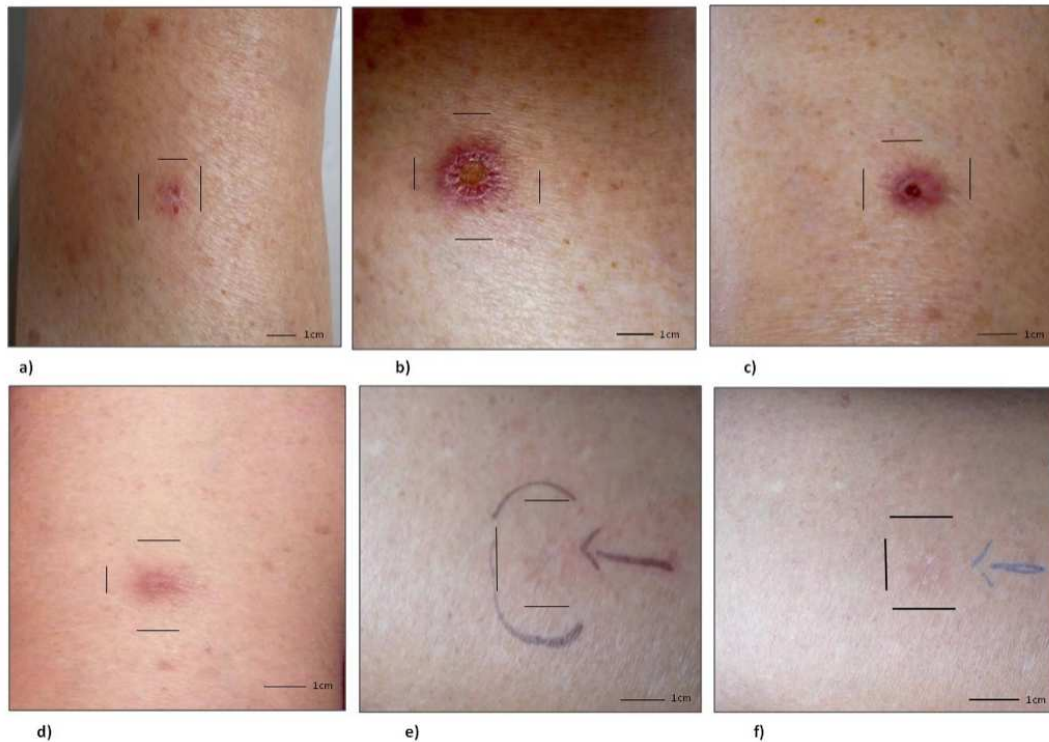


Figure 1 - Skin lesion on leg from March to November 2016: a) lesion pre-treatment; b) 1 week of applying 5-FU and fusidic acid/betamethasone creams; c) after 1 week of ceasing treatment with creams and changing to Aloe vera gel application; d) 2 months of gel application; e-f) 5 months after wound healing.

registered. After the first 4 days of treatment there was already a reduction in erythema and desquamation and drying up of the lesion. Treatment was stopped after 39 days on April 12th 2017, with only mild erythema showing. The lesion eventually disappeared completely. As of today, no lesions are visible, and no sequelae scarring or changes in skin pigmentation can be seen on the spots where the two actinic keratoses stood.

Discussion

Treatment with 5-FU, once started, must be continued until a marked inflammatory reaction appears. Full remission might take 1-2 months and lesions in the lower limbs are harder to treat[13]. In the first event, treatment with *Aloe vera* gel was followed by full remission of the

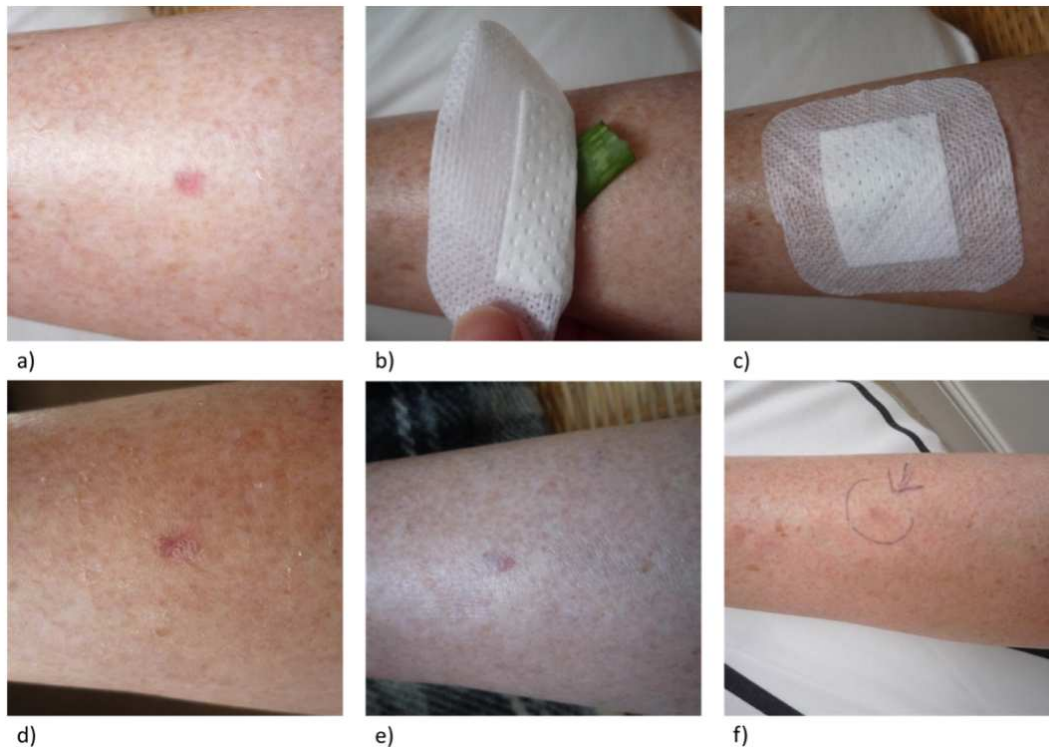


Figure 2 – Skin lesion from 9th March 2017 until 12th April 2017: a) 5th March 2017, a new actinic keratosis lesion appeared in the patient’s right leg, 1x0.5cm wide, 20cm below the knee, close to where the previous lesion was; b-c) Image 2b – A slice of Aloe vera plant (gel taken from the plant) was applied directly onto the actinic keratosis lesion every morning for about 1.5 months, a bandage was used to cover and secure the Aloe vera slice/gel extract; d) 9th March 2017, 4 days later there was already a reduction in erythema and desquamation and drying of the lesion developing; e) 25th March 2017, 25 days later the lesion has diminished in size, now being 0.5x0.5cm wide, treatment ensued; f) 22nd May 2017, treatment stopped 12th April 2017, after 39 days of daily application of Aloe vera, this image was captured on 22nd May 2017, 40 days after treatment had finished, lesion is now barely visible, with mild erythema still showing, the arrow drawn on the patient’s skin points to the actinic keratosis lesion.

actinic keratosis lesion. It remained, with the first lesion, to be determined whether *Aloe vera* was effective on its own, if treatment with 5-FU was effective but with help from aloe gel to curb side effects, or if both *Aloe vera* and 5-FU had a synergistic effect.

The second lesion was treated successfully with *Aloe vera* only. This provided a demonstration of the efficacy of *Aloe vera* in treating actinic keratosis. The time needed to treat the second lesion with *Aloe vera* was 39 days, a little over 5 weeks.

It would be interesting to look for histological changes in the cancerization field at pre-5-FU treatment, pre-aloe gel treatment and post-treatment stages.

The generalized, off-the-counter use of *Aloe* spp. without a scientific background plus the phenotypic similarities among species being extremely high, lead to improper/unsuitable species being used. As such, allergic reaction and toxic effects may occur, and studies can incur in an erroneous assessment of the real benefits of aloes[14-16]. Furthermore, different results should be expected across studies, given the fact that the composition of the *Aloe vera* gel varies not only between species, but also according to the origin of each species including climate, region, and processing method. It would also be worth studying the potential of *Aloe vera* to prevent the progression of premalignant lesions to cancer, both in actinic keratosis and in the cancerization field.

References

1. Moriyama M, Moriyama H, Uda J, Kubo H, Nakajima Y, Goto A, et al. Beneficial Effects of the Genus Aloe on Wound Healing, Cell Proliferation, and Differentiation of Epidermal Keratinocytes. *PloS one*. 2016;11(10):e0164799.
2. Rossi R, Mori M, Lotti T. Actinic keratosis. *International journal of dermatology*. 2007;46(9):895-904. 10.1111/j.1365-4632.2007.03166.x
3. Green AC. Epidemiology of actinic keratoses. *Actinic Keratosis: Karger Publishers*; 2015. p. 1-7.
4. Criscione VD, Weinstock MA, Naylor MF, Luque C, Eide MJ, Bingham SF, et al. Actinic keratoses: natural history and risk of malignant transformation in the Veterans Affairs Topical Tretinoin Chemoprevention Trial. *Cancer*. 2009;115(11):2523-30.
5. Röwert-Huber J, Patel M, Forschner T, Ulrich C, Eberle J, Kerl H, et al. Actinic keratosis is an early in situ squamous cell carcinoma: a proposal for reclassification. *British Journal of Dermatology*. 2007;156:8-12.
6. Ratushny V, Gober MD, Hick R, Ridky TW, Seykora JT. From keratinocyte to cancer: the pathogenesis and modeling of cutaneous squamous cell carcinoma. *The Journal of clinical investigation*. 2012;122(2):464-72.
7. Goldenberg G. Treatment considerations in actinic keratosis. *Journal of the European Academy of Dermatology and Venereology*. 2017;31:12-6.
8. Pellacani G, Neri L, Longo C. Comment to: 'Evidence and consensus based (S3) Guidelines for the Treatment of Actinic Keratosis'. 2016.
9. Hofbauer GF, Anliker M, Boehncke W-H, Brand C, Braun R, Gaide O, et al. Swiss clinical practice guidelines on field cancerization of the skin. *Swiss medical weekly*. 2014;144:w14026.
10. Werner R, Stockfleth E, Connolly S, Correia O, Erdmann R, Foley P, et al. Evidence-and consensus-based (S3) guidelines for the treatment of actinic keratosis—International League of Dermatological Societies in cooperation with the European Dermatology Forum—short version. *Journal of the European Academy of Dermatology and Venereology*. 2015;29(11):2069-79.

11. Peris K, Calzavara-Pinton P, Neri L, Girolomoni G, Malara G, Parodi A, et al. Italian expert consensus for the management of actinic keratosis in immunocompetent patients. *Journal of the European Academy of Dermatology and Venereology*. 2016;30(7):1077-84.
12. Berman B, Cohen DE, Amini S. What is the role of field-directed therapy in the treatment of actinic keratosis? Part 2: Commonly used field-directed and lesion-directed therapies. *Cutis*. 2012;89(6):294-301.
13. Efudix Cream 5% SPC 2015. [19 March 2017]; Available from: <http://www.medicines.org.uk/emc/medicine/6219>.
14. He Z, He T, Weng S, HUANG Y-q, LIANG N-c. Effect of Aloe emodin on metastatic abilities of human high metastatic breast cancer MDA-MB-231 cells in vitro. *Chinese Pharmacological Bulletin*. 2013;29(8):1114-8.
15. Yang HN, Kim DJ, Kim YM, Kim BH, Sohn KM, Choi MJ, et al. Aloe-induced toxic hepatitis. *Journal of Korean medical science*. 2010;25(3):492-5. Epub 2010/03/02. 10.3346/jkms.2010.25.3.492
16. Guo X, Mei N. Aloe vera: A review of toxicity and adverse clinical effects. *Journal of environmental science and health Part C, Environmental carcinogenesis & ecotoxicology reviews*. 2016;34(2):77-96. Epub 2016/03/18. 10.1080/10590501.2016.1166826