



## Article

# Methotrexate - A Potential Risk Factor for Delayed Healing and Medication-Related Osteonecrosis of the Jaw Following Dental Extractions - A Case Study Aiming to Raise Awareness in Clinical Practice

Caga, Daniel Coskun and Barrak, Fadi N

Available at <http://clock.uclan.ac.uk/41177/>

*Caga, Daniel Coskun and Barrak, Fadi N ORCID: 0000-0002-3906-9174 (2021) Methotrexate - A Potential Risk Factor for Delayed Healing and Medication-Related Osteonecrosis of the Jaw Following Dental Extractions - A Case Study Aiming to Raise Awareness in Clinical Practice. International Journal on Oral Health . ISSN 2770-0631*

It is advisable to refer to the publisher's version if you intend to cite from the work.

10.51626/ijoh.2021.01.00010

For more information about UCLan's research in this area go to <http://www.uclan.ac.uk/researchgroups/> and search for <name of research Group>.

For information about Research generally at UCLan please go to <http://www.uclan.ac.uk/research/>

All outputs in CLoK are protected by Intellectual Property Rights law, including Copyright law. Copyright, IPR and Moral Rights for the works on this site are retained by the individual authors and/or other copyright owners. Terms and conditions for use of this material are defined in the [policies](#) page.

# Methotrexate – A Potential Risk Factor for Delayed Healing and Medication-Related Osteonecrosis of the Jaw Following Dental Extractions – A Case Study Aiming to Raise Awareness in Clinical Practice

Case report

Volume 1 Issue 2- 2021

## Author Details

Daniel Caga<sup>1</sup>, Fadi Barrak<sup>2</sup>

<sup>1</sup>General Dental Practitioner, University of Central Lancashire, UK

<sup>2</sup>Specialist Oral Surgeon, University of Central Lancashire, UK

## \*Corresponding author

Fadi Barrak, BDS, FDS RCS (Eng.), MB BS, Dip Imp Dent RSC (Edin.), FHEA, MSc. Specialist Oral Surgeon, Academic Lead of the MSc Clinical Implantology University of Central Lancashire, Founding CEO VSS Academy, London, UK

## Article History

Received: August 30, 2021 Accepted: September 10, 2021 Published: September 14, 2021

**Abstract:** A case report documenting how a routine atraumatic extraction of a lower right second premolar in a female patient with rheumatoid arthritis taking methotrexate, hydroxychloroquine, certolizumab pegol and pain relief medication, resulted in the sequestration of bone in the coronal aspect of the socket, inflammation, suppuration, and delayed healing mimicking medication-related osteonecrosis of the jaw. Treatment of the lesion involved a methotrexate drug holiday (after consulting with her rheumatologist), antibiotics, chlorhexidine and saltwater rinses as well as surgical curettage of the lesion under local anaesthesia. This case report highlights to the general dental practitioner an important potential link between methotrexate and medication-related osteonecrosis of the jaw and is strengthened by case studies from the literature. An emphasis on liaising with other health care professionals such as the rheumatologist is also made.

## CPD/Clinical Relevance

A case study raising awareness in general dental practice of a potential link between methotrexate, delayed healing, and medication-related osteonecrosis of the jaw. General dental practitioners should be aware of the evidence base surrounding this topic due to methotrexate being commonly prescribed for inflammatory conditions such as rheumatoid arthritis and where necessary discuss such medications with patients and their medical physicians prior to invasive treatments such as tooth extractions.

## Introduction

The 2009 Adult Dental Health Survey highlighted that in England, Wales and Northern Ireland, 94% of the population were dentate; meaning they had retained at least one natural tooth [1]. However, the survey demonstrated that the mean number of retained teeth

fell gradually with age, from 23.2 teeth in 55-64 year old patients, to 14.0 teeth amongst patients aged 85 and above [1]. All dentate adults aged 16-24 years had 21 or more natural teeth compared with 91% of dentate 45-54-year-olds and just 40% of dentate adults aged 75-84 [2]. Dental extractions provided under both local and general anaesthesia approaches are still a common treatment experienced by patients. There are risks of post-operative complications following all forms of exodontia. A significant risk during dental extractions is that of osteonecrosis of the jaw (ONJ). Traditionally, it has been associated with the use of bisphosphonate drugs; classified as bisphosphonate-related osteonecrosis of the jaw (BRONJ); which is described as: 'progressive destruction and death of bone that affects the mandible and/or maxilla of patients, exposed to treatment particularly with nitrogen containing bisphosphonates, in the absence of a previous radiation treatment' [3].



A more recent description is that of medication-related osteonecrosis of the jaw (MRONJ); which has been described as: ‘a condition where exposed bone is detected through an intraoral or extraoral fistula/e in the maxillofacial region, does not heal within 8 weeks and occurring in a patient who has received a bone-modifying agent (BMA) or an angiogenesis inhibitor, with no history of head and neck radiation [4]. Medication related osteonecrosis of the jaw was first described in 2003 [5]; it is considered a rare condition but can be very serious [6] with numerous drugs having become associated with it. It is thought MRONJ may develop due to issues relating to (i) inhibition of bone remodelling, (ii) infection and inflammation, (iii) immunological reasons, (iv) soft tissue toxicity and (v) impairments in angiogenesis [7]. The most common cause of MRONJ in dentistry is invasive procedures such as a tooth extraction [4].

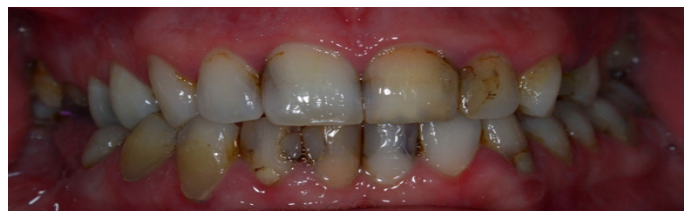The case study discussed in this article highlights to the readers, the potential link between MRONJ and methotrexate (MTX). Methotrexate is an antifolate drug that functions by inhibiting dihydrofolate reductase (DHFR); it has several clinical uses; (i) as a cytotoxic agent at high doses to treat leukaemia and (ii) as an immunomodulatory agent at low doses, to treat inflammatory conditions. One of the most common conditions MTX is used to treat is that of rheumatoid arthritis (RA); a chronic inflammatory autoimmune disorder. Rheumatoid arthritis has a prevalence in western societies of 0.5-1.0% in white individuals [8,9]; and the reader may well have a patient with RA, being treated by amongst other medications, MTX. Therefore, raising awareness within the dental profession of the potential link between MTX and MRONJ is vital.

### Case Report

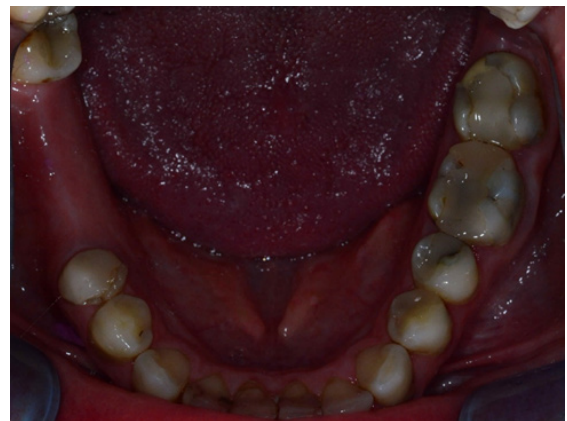A female patient was referred by her general dental practitioner (GDP) to the University Central Lancashire (UCLan) dental clinic for an implant assessment. The patient was a regular attender at her GDP. She reported quitting cigarette smoking 5 years previously, having smoked 15-20 daily. Medically, the patient reported suffering from RA and was taking MTX, hydroxychloroquine, certolizumab pegol [an anti-tumour necrosis factor (anti-TNF) drug] and pain relief medication.

She presented with a heavily restored dentition (Figure 1), with a bounded saddle in the lower right quadrant (LRQ) missing her lower right second and first molars (LR76) (Figure 2). Her GDP has referred her in for an implant assessment in the LR76 as well as for an opinion on the upper left first premolar region (UL4) which had a retained unrestorable root. Several marginally stained and discoloured composites were noted (Figure 1). Furthermore, caries was present in the upper left first molar (UL6); which was due to be restored by her GDP. Her basic periodontal assessment was 111/121. Unfortunately, the lower right second premolar, which had been endodontically treated, fractured and was deemed unrestorable by her GDP (Figure 3). It was suggested the planned implant therapy in the LRQ could now potentially include this tooth. This was agreed upon by the UCL an team and the LR5 was subsequently taken out uneventfully under local anaesthesia (Figure 4). Nearly one month later, the patient returned to the clinic for an emergency complaining of tenderness, swelling and infection around the extraction site. A periapical radiograph was taken and revealed bone sequestration and a ring of bone loss at the coronal aspect (Figure 5). The clinician was unable to remove the bony sequestrae at this appointment due to the acute infection. The patient was advised to use a chlorhexidine and saltwater mouth rinses and was prescribed cefuroxime 500mg bidaily for 7 days. A review appointment was made, and her specialist rheumatologist was contacted with a view to reduce her immunosuppressants. The antibiotic regime was then swapped to co-amoxiclav 625mg, however the patient reported being sick after the second dose and had a headache. A further change in antibiotic prescription was made; the patient was given doxycycline 200mg loading dose plus 100mg once daily for 14 days. The patient returned to the clinic 6-days later, having had a drug holiday from

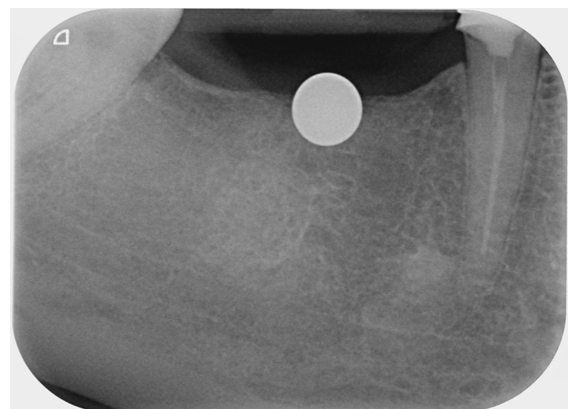
her immunosuppressants. At this appointment the swelling had significantly reduced, no suppuration or lymphadenitis were noted. The region was tender to pressure however. The patient consented to having the extraction site curetted under local anaesthesia; this was completed and 3 sequestrae were removed, a 10mm x 3-5mm fragment from the buccal aspect was removed, and two sequestrae of 3mm and 5mm diameter were removed lingually. The socket was irrigated with sterile saline and 2 x 4.0 vicryl rapid sutures were placed. The socket was open to drain. The patient continued the doxycycline, chlorhexidine and saltwater mouth rinses and was reviewed 2-weeks later, feeling much better and reported slight tenderness in the socket region. Clinically, the extraction site was healing well, no obvious lymphadenopathy, suppuration or infection. Interestingly, the patient had an upper retained root extracted previously without any complications.



**Figure 1:** Showing an anterior retracted view of the patient, note heavily restored dentition with some marginally stained and discoloured composites.



**Figure 2:** The mandibular view showing a heavily restored dentition, especially LR5 and the bounded saddle in the LR76 region.



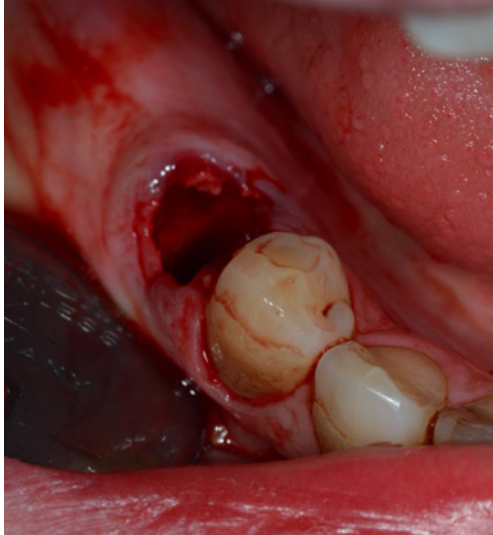
**Figure 3:** A periapical radiograph with a metal calibration ball used to enable accurate measurements of the alveolar bone height, as well as showing the endodontically treated LR5.

### Discussion

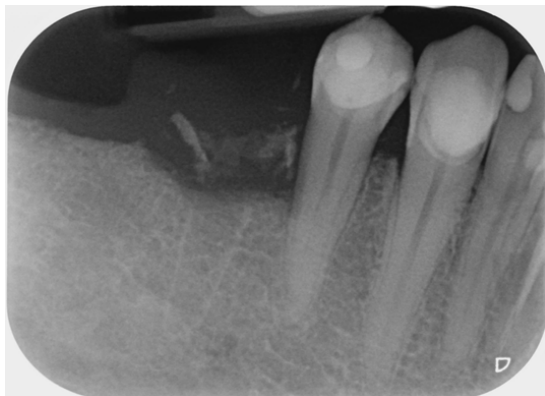
The case discussed above highlighted the importance of a detailed medical history and an understanding of the potential influence drugs such as MTX may have on healing extraction sockets. Methotrexate



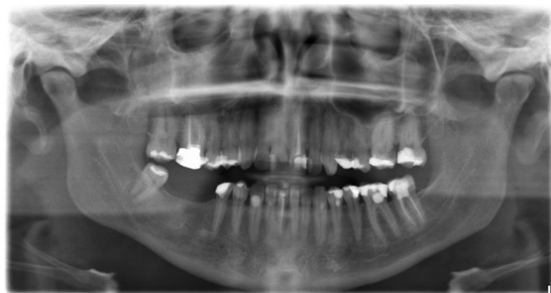
was first used in the treatment of RA in 1951 [10], becoming officially licenced for use in the 1980s [11,12]. However, one side effect of MTX is MTX-induced osteopathy; which develops at both high and low dosage regimens. It was first described in rheumatology in 1983 [13]. Methotrexate is an immunosuppressant and studies have also demonstrated its inhibitory effects on osteoclastogenesis and suppressive effects on bone marrow function [14,15].



**Figure 4:** Postoperative view of LR5 having been extracted a traumatically and uneventfully.



**Figure 5:** A periapical radiograph showing bony sequestration and bone loss around the LR5 extraction socket.



**Figure 6:** OPG demonstrating no obvious apical pathology associated with LR5, caries associated with UL6 and a heavily restored dentition.

Several case reports have been published in the literature linking MTX and ONJ. The European League Against Rheumatism (EULAR), in 2016 recommended that RA management should include MTX and short-term glucocorticoids prescriptions [16]. Because of the MTX-osteopathy and glucocorticoid use, RA patients often take bisphosphonate (BPs) drugs such as alendronic acid.

Many of the case studies in the literature discuss BRONJ in RA patients taking both BPs and MTX. Alsalleeh et al 2014 reported

BRONJ recurrence following methotrexate therapy in a 66-year old female patient who had her upper left first molar (UL6) extracted [17]. The patient was receiving alendronic acid once weekly (for 4 years), paracetamol and a narcotic for joint pain, promethazine and with codeine for a cough and folic acid [17]. The patient had her upper left second premolar (UL5) endodontically retreated by an endodontist who then referred her on due to issues in the ULQ. Endodontic surgery was then completed on UL5 as a sinus tract traced back to this tooth. Five months after the surgery, she was still symptomatic, and the operative site remained open. Nine months after endodontic therapy, UL5 was extracted. The patient received a 2-month amoxicillin prescription before the extraction; reporting improvements in pain and wound healing. However, at her 3-month recall, there was evidence of bone exposure, inflamed gingival tissues and suppuration in the UL6 region. The patient had been receiving 12.5 mg MTX once daily for the previous 2-months. The wound fully healed after 18-months, and the patient stopped taking MTX after discussing this with her general medical physician (GMP) and received another 3-month course of amoxicillin, strict oral hygiene instructions and a 0.12% chlorhexidine mouth rinse [17]. The interesting aspect of this case was that the delayed healing and BRONJ seemed to worsen once MTX therapy was initiated.

A 2016 observational, multicentre case series was published by Di Fede et al. [18]. Eighteen patients with both RA and osteonecrosis of the jaw across 3 centres in Italy were included in the study. Two patients were not receiving treatment for RA, 9 of 18 were being treated with steroids, 3 with MTX and 4 with other bone medications. In their conclusion the authors hypothesized that RA patients may be more susceptible to ONJ due to their medications. They also highlighted the lack of any randomised controlled trials (RCTs).

Mathai et al. [19] reported case studies in 3 female patients (between 50-70 years of age) who suffered with both RA and osteoporosis (OP). Their patients received oral BPs (for less than 1-year) and MTX (for 4-10-years) and developed BRONJ within 2-5 months of undergoing traumatic dental procedures (extractions and deep scaling) [19]. No history of steroid use was reported.

The above case studies [17-19] all reported ONJ developing in patients taking MTX as well as other medications such as BPs. However, there are articles in the literature reporting ONJ in patients taking MTX in the absence of anti-resorptive and anti-angiogenic medications. Agahlou and Tetradis reported 6 cases of ONJ in the absence of such medications [20]. One of their cases involved an 83-year-old female patient, who was a past smoker and suffered from RA, hypertension and hyperlipidaemia. She presented with a poorly healing site in the URQ in the maxilla following placement of two crowns and root planning. Her medication included MTX, which she had taken for 5-years [20].

Henien et al reported two cases of ONJ in patients with long-standing arthritis treated with MTX without any anti-resorptive or anti-angiogenic medications or lymphoproliferative disorders [21]. The first case involved a 66-year female patient, who presented with a non-healing extraction socket 18-months after the non-surgical removal of a periodontally involved UL7 [21]. Bony sequestra were removed by her GDP at 18 and 36-months. The patient was a previous smoker and her medication included MTX for RA, folic acid, leflunomide, amlodipine, omeprazole and paracetamol. The second case involved a 54-year old male patient, non-smoker who did not drink alcohol. His medications included MTX for psoriatic arthritis, folic acid, leflunomide, amlodipine and lansoprazole [21]. Recently, Leoh et al investigated MRONJ by analysing the range of implicated drugs from the Database of Adverse Event Notifications (DAEN) from the Therapeutic Goods Administration (TGA) in Australia [6]. This search covered the years 1971 to 2019 and in total 419 cases were found. One case was noted to be associated with MTX therapy.



## Conclusion

With respect to the LR5 case discussed above; the tooth was endodontically treated with no signs of recurrent apical pathology on the periapical or orthopantomograph (OPG) radiographs (Figure 6). It was extracted having fractured and was deemed unrestorable due to insufficient tooth structure for a post-crown. A differential diagnosis of the cause of the post-operative infection could have been periapical pathology that progressed into osteomyelitis; however, the lack of apical pathology reduced the likelihood of this. Furthermore, the extraction was performed atraumatically, with no records of a difficult extraction or bony involvement noted. The clinical presentation involved the sequestration of the coronal ring of bone.

The literature is sparse for definitive causative evidence linking MTX to MRONJ. However, especially given the case studies of ONJ in the absence of anti-resorptive and anti-angiogenic discussed above, alongside those associated with patients taking BP drugs and the case in which ONJ progressed following MTX initiation, the authors felt that this case provided a vital opportunity to raise awareness in the dental profession. General dental practitioners in particular should become more aware of a potential link between MTX therapy, delayed healing and MRONJ because MTX is a widely prescribed medication. Furthermore, seeking clarification on the potential need for a MTX drug holiday from the patient's rheumatologist should be emphasized.

## Compliance with Ethical Standards

Conflict of interest: The authors declare no conflict of interest. Consent was gained for use of the clinical photographs in the case at the UCLan clinic.

## References

- Fuller E, Steele J, Watt R, Nuttall N (2011) Oral health and function - a report from the Adult Dental Health Survey 2009.
- Steel JG, Treasure ET, O'Sullivan I (2012) Adult Dental Health Survey 2009: transformations in British oral health 1968-2009. *Br Dent J* 213(10): 523-527.
- Bedogni A, Fusco V, Agrillo A (2012) Learning from experience. Proposal of a refined definition and staging system for bisphosphonate-related osteonecrosis of the jaw (BRONJ). *Oral Dis* 18(6): 621-623.
- Ruggiero SL, Dodson TB, Fantasia J (2014) American Association of O, Maxillofacial S. American Association of Oral and Maxillofacial Surgeons position paper on medication-related osteonecrosis of the jaw – 2014 update. *J Oral Maxillofac Surg* 72: 1938-1956.
- Marx RE (2003) Pamidronate (Aredia) and zoledronate (Zometa) induced avascular necrosis of the jaw: a growing epidemic. *J Oral Maxillofac Surg* 61(9): 1115-1117.
- Teoh L, Moses G, Nguyen AP (2021) Medication-related osteonecrosis of the jaw: Analysing the range of implicated drugs from the Australian database of adverse event notifications. *Br J Clin Pharmacol* 87(7): 2767-2776.
- Lombard T, Neirinckx V, Rogister B, Gilon Y (2016) Medication-related osteonecrosis of the jaw: New insights into molecular mechanisms and cellular therapeutic approaches. *Stem Cells Int* 2016: 8768162.
- Myasoedova E, Crowson CS, Kremers HM (2010) Is the incidence of rheumatoid arthritis rising?: results from Olmsted County, Minnesota 1955-2007. *Arthritis and Rheum* 62(6): 1576-1582.
- Tobon GJ, Youinou P, Saraus A (2010) The environment, geo-epidemiology and autoimmune disease: rheumatoid arthritis. *J Immunol* 35(1): 1-14.
- Gubner R, August S, Ginsberg V (1951) Therapeutic suppression of tissue reactivity. II. Effect of aminopterin in rheumatoid and psoriasis. *Am J M Sc* 221(2): 176-182.
- Weinblatt ME, Coblyn JS, Fox DA (1985) Efficacy of low-dose methotrexate in rheumatoid arthritis. *New Eng J Med* 312: 818-822.
- Williams HJ, Willkens RF, Samuelson Jr CO (1985) Comparison of low-dose oral pulse methotrexate and placebo in the treatment of rheumatoid arthritis. A controlled clinical trial. *Arthritis and Rheum* 28(7): 721-730.
- Visentin M, Zhao R, Goldman ID (2012) The antifolates. *Hematol. Oncol. Clin North Am* 26: 629-648.
- Lee CK, Lee EY, Chung SM (2004) Effects of disease-modifying antirheumatic drugs and anti-inflammatory cytokines on human osteoclastogenesis through interaction with receptor activator of nuclear factor kappaB, osteoprotegerin, and receptor activator of nuclear factors kappaB ligand. *Arthritis and Rheum* 50(12): 3831-3843.
- Sosin M, Handa S (2003) Lose dose methotrexate and bone marrow suppression. *BMJ* 326: 266-267.
- Smolen JS (2017) EULAR recommendations for the management of rheumatoid arthritis with synthetic and biological disease-modifying antirheumatic drugs: 2016 update. *Ann Rheum Dis* 76: 960-977.
- Alsalleeh F, Keippel J, Adams L (2014) Bisphosphonate-associated osteonecrosis of jaw recurrence after methotrexate therapy: a case report. *J Endod* 40: 1505-1507.
- Di Fede O, Bedogni A, Giancola F (2016) BRONJ in patient with rheumatoid arthritis: a multicentre case series. *Oral Dis* 22: 543-548.
- Mathai PC, Andrade NN, Aggarwal N (2018) Low-dose methotrexate in rheumatoid arthritis: a potential risk factor for bisphosphonate-induced osteonecrosis of the jaw. *Oral Maxillofac Surg* 22: 235-240.
- Agahloo TL, Tetradis S (2017) Osteonecrosis of the jaw in the absence of antiresorptive or antiangiogenic exposure: a series of 6 cases. *J Oral Maxillofac Surg* 75: 129-142.
- Henien M, Carey B, Hullah E (2017) Methotrexate associated osteonecrosis of the jaw: a report of two cases. *Oral Surg Oral Med Oral Pathol Oral Radiol and Endod* 124: e283-e287.

