

Characteristics of mucocutaneous vascular malformations drawn from a decade of a multidisciplinary committee experience

Andrea Estébanez¹  | Miguel Puche-Torres² | Juan Manuel Sanchis García³ | Alberto Cuñat⁴ | María Isabel Pinazo Canales¹ | María Francisca Rausell Félix¹ | Salvador Campos⁴ | Juan Márquez Cañada⁵ | Jose María Martín Hernández¹

¹Department of Dermatology, Clinical University Hospital, Health Research Institute, University of Valencia, Valencia, Spain

²Department of Oral and maxillofacial Surgery, Clinical University Hospital University of Valencia, Valencia, Spain

³Department of Interventional Radiology, Clinical University Hospital, University of Valencia, Valencia, Spain

⁴Department of Radiology, Clinical University Hospital, University of Valencia, Valencia, Spain

⁵Department of Plastic Surgery, Clinical University Hospital, University of Valencia, Valencia, Spain

Correspondence

Andrea Estébanez, Dermatology, Clinical University Hospital, Valencia, Spain.
Temporary address: Avenida Blasco Ibañez 17, 46010, Valencia, Spain.
Email: andreaestebanez_7@hotmail.com

Abstract

Vascular malformations (VM) are congenital, benign, and relatively frequent lesions. Scant data have been published about the epidemiology, clinical presentation, and treatment of VM from a dermatologist's perspective. The substantial differences between subtypes, broad range of specialists consulted and confusing nomenclature used over previous years may hamper a correct diagnosis. The main objective of this study is to describe VM epidemiology. As a secondary endpoint we evaluate clinical characteristics, clinical-radiological correlation and treatment approaches. We carried out an observational, descriptive, retrospective study. Cases presented to the multidisciplinary committee of our hospital from 2009 to 2019 were retrieved. Electronic medical records, monthly committee reports and the iconographic archive were reviewed and statistically analyzed. Overall, venous malformations (VeM) are the most frequent VM, followed by capillary malformations (CM), arterioVeM and lymphatic malformations (LM). Considering only patients under 16, CMs are the most frequent ones. Capillary and LMs are larger than venous or arteriovenous. While CMs are usually asymptomatic, symptomatic cases are threefold more frequent in the other subtypes. Decisions on active or conservative management depend on VM size but not location or patient age. CMs are mainly treated with laser therapy; venous with sclerotherapy or surgery; arteriovenous with surgery and lymphatic with surgery or sirolimus. Dermatologists play an important role in VM diagnosis and management. Our 10-year multidisciplinary experience should contribute to the literature and represent a practical resource for clinicians and researchers.

KEYWORDS

arteriovenous, capillary, ISSVA, lymphatic, vascular malformations, venous

This is an open access article under the terms of the Creative Commons Attribution License, which permits use, distribution and reproduction in any medium, provided the original work is properly cited.

© 2021 The Authors. *Dermatologic Therapy* published by Wiley Periodicals LLC.

1 | INTRODUCTION

Vascular anomalies are divided into vascular tumors and vascular malformations (VM). VM are benign lesions derived from a vasculogenesis failure, without endothelial proliferation, unlike vascular tumors. Although congenital, they may not become evident until adulthood.

VM comprise a wide range of entities, and current terminological confusion is partly attributable to previous classifications. The International Society for Vascular Anomalies (ISSVA) was founded in 1992, and from this year onwards classification of vascular anomalies has been reviewed every 2 years, with its latest update in May 2018¹ and a recently proposed new clinical classification for capillary malformations (CM).² Here we report the epidemiological, clinical, radiological and therapeutic characteristics of more than 200 VM evaluated in our hospital over 10 years, exploring differences between the main subtypes to help advance knowledge in the field.

1.1 | VM subtypes

VM are due to mosaic mutations, most of them involving the Ras-MAP-kinase or PI3K pathways. VM are divided into simple (CM, venous malformations (VeM), lymphatic malformations (LM), and arterioVeMs (AVM)) and combined if two or more type of vessels are involved.

1.2 | Capillary malformations

These malformations have seven major patterns which differ in clinical presentation, prognosis and possible associated findings.² **Nevus simplex or flammeus** usually presents as pale pink to bright red macules located in middle face or head.² **Port-wine stains** present as pink, red or purple stains varying in size; however, the most common presentation is large, unilateral well demarcated patches with segmental distribution. **Geographic CM** are typically blue to purple, well demarcated stains, often associated with veno-LMs and limb overgrowth, such as in Klippel-Trenaunay syndrome, CLOVES, Proteus or CLAPO syndromes. **Small multiple CM** are usually associated with CM-arterioVeM syndrome.³ **Reticulated CM** are characterized by reticulated, poorly defined, pale pink to light red vascular stains. These lesions can be isolated or associated with overgrowth such as in diffuse CM with overgrowth syndrome or in Macrocephaly-CM syndrome. **Cutis marmorata telangiectatica congenita** is characterized by a congenital stain with blue to purple tone and a livedoid pattern with frequent focal atrophy or ulceration. **Telangiectasia** is a very heterogeneous group characterized by dilated capillary vessels. Although, according to ISSVA, telangiectasias are classified as CMs, most of them (such as in Rendu Osler Weber syndrome) present as high flow lesions.⁴

1.3 | Venous malformations

VeM are rare congenital low-flow VMs with a prevalence of 1%.⁵ Clinically they present as soft nodules or masses with a blue to

purple color and increase in size with the Valsalva maneuver. Pain (secondary to thrombosis or nervous compression), functional limitations and bleeding are common. There are several different subtypes. **Common VeM** is the most frequent. **Blue rubber bleb nevus syndrome** consists of multiple VeM involving the skin, mucosa and gastrointestinal tract with frequently secondary bleeding. **GlomoVeMs** present as pink, red or blue coalescing nodules forming plaques with a segmental distribution. Characteristically, these lesions are painful, do not have localized intravascular phenomenon, do not develop febolits and do not increase D-Dimer. **Verrucous VeM** present as a purple, well demarcated stain and evolves into a scaly, keratotic lesion prone to bleeding and ulceration. Other subtypes include **familial cutaneo-mucosal** and **cerebral cavernous malformation**.

1.4 | Lymphatic malformations

LM are congenital low-flow VM consisting of fluid-filled channels or spaces caused by abnormal development of the lymphatic system. They are divided into: **microcystic** (multiple vesicles or small cysts), **macrocytic** (subcutaneous nodules or masses) or **mixed LM**. Several rare conditions have been reported with extensive or generalized LM; as well as nonclassified VM with lymphatic component such as angiokeratoma and multifocal lymphoendotheliomatosis with thrombocytopenia.¹

1.5 | ArterioVeMs

AVM are fast-flow VM caused by an abnormal connection between artery and vein, which represent between 10% and 15% of all VM.⁶ Typically, they present as reddish macules or patches similar to CM but with fast-flow Doppler vessels (stage I Schobinger's clinical classification⁶). As they evolve, they present with thrill, ulceration, bleeding, pain or necrosis or even heart failure. The reason why some AVM stay stable while others quickly progress is not clear, although genetics could play an important role.

2 | METHODS

We carried out an observational, descriptive, retrospective study. We collected VM patient cases discussed between January 2009 and December 2019 in the multidisciplinary committee of the Clinical University Hospital in Valencia (CUHV). The CHUV Committee for Vascular Anomalies is composed of maxillofacial, plastic, vascular and pediatric surgeons; dermatologists; radiologists; otolaryngologists and pediatricians. It was founded in 2002 and has met monthly since then. The ethics committee of our hospital approved this study and all patients with confirmed VM who agreed to participate and signed the informed consent were included, making a total of 202 patients (including both children and adults). Data were

collected from electronic medical records, monthly digital committee reports and the iconographic archive. Complementary exams and posttreatment images were reviewed.

All data were statistically analyzed, using the nonparametrical Pearson's chi-squared (Chi²) test in the case of two categorical variables and performing Bonferroni correction for Post hoc analysis for more than two categories in any variable. To determine whether data distribution among different categories (such as sex, size, or tone) was balanced, we performed Pearson's Chi² test for a single variable. To compare a continuous variable with nonnormal distribution or an ordinal variable we used different tests depending on the second variable: for categorical variables with two possible categories, we used Mann Whitney U test, while the Kruskal-Wallis test was used for categorical variables with more than two categories. To compare two continuous variables with nonnormal distribution we used Spearman's rank correlation coefficient (ρ), and to evaluate the concordance level between ultrasound and MRI results we used Cohen's kappa coefficient (κ).

3 | RESULTS

3.1 | Epidemiology

3.1.1 | Subtypes of VM

In total, 202 VM cases were included in our study, of which VeM were the most frequent (38%), followed by CM (32%), AVM (23%) and LM (7%). We also added five patients with malformations of major named vessels. Combined malformations were classified according to their main vascular component.

3.1.2 | Sex distribution

Overall, we found a nonstatistically significant difference between VM subtype and patient sex ($p = 0.605$), although in the fast-flow VM subtype females outnumbered males twofold ($p = 0.011$) (Table 1).

TABLE 1 Sex, size, and location according to VM subtypes

		VM subtype										Overall p value (Chi ²)		
		Total		CM		VeM		LM		AVM			Major named	
		N	%	N	%	N	%	N	%	N	%		N	%
Sex	Total	202	100.0%	64	100.0%	74	100.0%	14	100.0%	45	100.0%	5	100.0%	0.605
	Males	79	39.1%	25	39.1%	32	43.2%	5	35.7%	14	31.1%	3	60.0%	
	Females	123	60.9%	39	60.9%	42	56.8%	9	64.3%	31	68.9%	2	40.0%	
Subtype-specific p values (Chi ²)				0.080		0.245		0.285		0.011		0.655		
Size	Total	202	100.0%	64	100.0%	74	100.0%	14	100.0%	45	100.0%	5	100.0%	<0.0001
	≥ 5 cm ²	87	43.1%	39	60.9%	32	43.2%	8	57.1%	8	17.8%	0	0.0%	
	<5 cm ²	115	56.9%	25	39.1%	42	56.8%	6	42.9%	37	82.2%	5	100.0%	
Subtype-specific p values (Chi ²)				0.080		0.245		0.593		<0.0001		(*)		
Head and neck	Total	202	100.0%	64	100.0%	74	100.0%	14	100.0%	45	100.0%	5	100.0%	0.035
	No	82	40.6%	31	48.4%	24	32.4%	9	64.3%	18	40.0%	0	0.0%	
	Yes	120	59.4%	33	51.6%	50	67.6%	5	35.7%	27	60.0%	5	100.0%	
Subtype-specific p values (Chi ²)				0.803		0.003		0.285		0.180		–		
Trunk	Total	202	100.0%	64	100.0%	74	100.0%	14	100.0%	45	100.0%	5	100.0%	<0.0001
	No	172	85.1%	45	70.3%	70	94.6%	8	57.1%	44	97.8%	5	100.0%	
	Yes	30	14.9%	19	29.7%	4	5.4%	6	42.9%	1	2.2%	0	0.0%	
Subtype-specific p values (Chi ²)				0.001		<0.0001		0.593		<0.0001		–		
Upper extremities	Total	202	100.0%	64	100.0%	74	100.0%	14	100.0%	45	100.0%	5	100.0%	0.125
	No	158	78.2%	46	71.9%	64	86.5%	11	78.6%	32	71.1%	5	100.0%	
	Yes	44	21.8%	18	28.1%	10	13.5%	3	21.4%	13	28.9%	0	0.0%	
Subtype-specific p values (Chi ²)				<0.0001		<0.0001		0.033		0.005		–		
Lower extremities	Total	202	100.0%	64	100.0%	74	100.0%	14	100.0%	45	100.0%	5	100.0%	0.448
	No	169	83.7%	52	81.3%	60	81.1%	11	78.6%	41	91.1%	5	100.0%	
	Yes	33	16.3%	12	18.8%	14	18.9%	3	21.4%	4	8.9%	0	0.0%	
Subtype-specific p values (Chi ²)				<0.0001		<0.0001		0.033		<0.0001		(*)		

Note: *empty cells.

$p > 0.05$.

3.1.3 | Age distribution

Considering only pediatric patients (under the age of 16, $n = 88$) the distribution of VM changed: CM were the main group (50%), followed by VeM (29%), AVM (11%) and LM (10%). Concerning onset of VM we found statistically significant differences between subtypes: CM were evident at an earlier age, followed by LM, VeM, and AVM ($p < 0.0001$) (Figure 1).

3.1.4 | Medical and obstetrical history

We found a nonstatistically significant link between presence of a relevant medical or surgical background (defined as interatrial communication, brain aneurysms or neurofibromatosis) and VM subtype. Concerning obstetrical history, there was no association between VM subtype and weeks of pregnancy at delivery date, previous miscarriages, insemination mode (natural or artificial), or mode of childbirth delivery (vaginal or caesarean); however, 50% of LM were postterm pregnancies (defined as $>40 + 6$ weeks of pregnancy).

3.2 | Clinical manifestations

3.2.1 | Size

We divided VM into two groups ($<5\text{cm}^2$ or $\geq 5\text{cm}^2$). VM size was different according to subtype ($p < 0.0001$); moreover, AVM $< 5\text{cm}^2$ were five times more frequent than those $\geq 5\text{cm}^2$ ($p = 0.011$) (Table 1).

3.2.2 | Location

Anatomical distribution by subtype is represented in Figure 2. Statistically significant differences were found between head-neck and trunk location and VM subtype ($p = 0.035$ and $p < 0.0001$ respectively) (Table 1). For VM located in head and neck, the most frequent subtype was VeM, whereas in trunk the most common were CM and LM.

3.2.3 | Color

The color distribution for each subtype is represented in Figure 3. We found differences between VM subtypes in terms of color ($p < 0.001$).

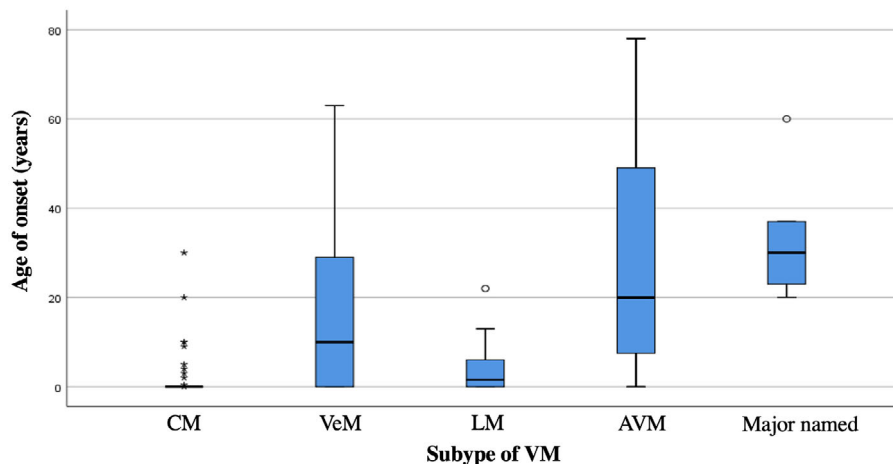


FIGURE 1 Dot plot representing age of onset according to vascular malformations (VM) subtype

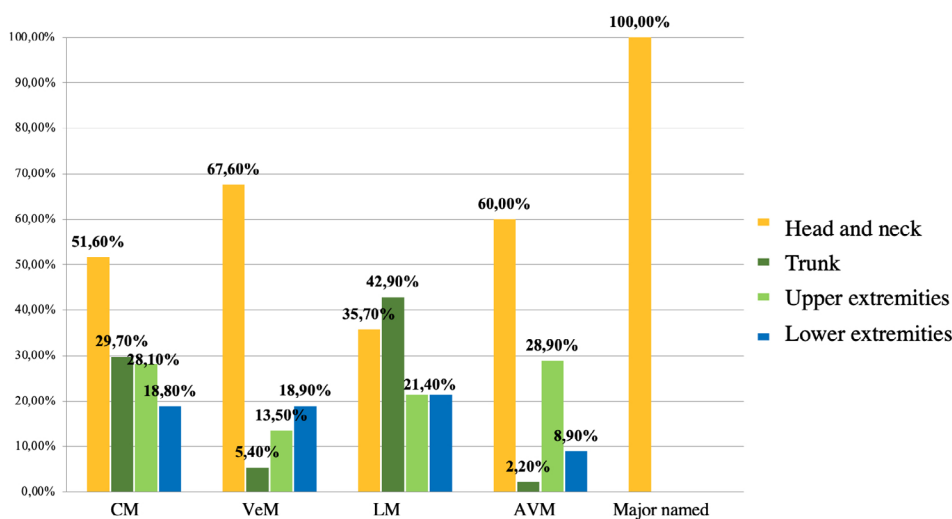


FIGURE 2 Representation of location according to vascular malformations (VM) subtype

In cases of VM with the same color as adjacent skin, LM were the most frequent; for pink to red, CM and for blue to purple, VeM.

3.2.4 | Signs and symptoms

There are differences between clinical manifestations and subtypes of VM ($p < 0.0001$), as CM were tenfold less likely to be symptomatic than the other subtypes.

- For CM, symptomatic cases (7,8%) included ophthalmologic involvement (glaucoma, buphthalmos and exotropia) and hypertrophic growth-related bleeding in nontreated patients.
- In VeM, symptomatic cases represented 81% of total. Pain (43%), bleeding (12%) and frequent changes in size or volume (47%) were the most related symptoms. Coagulation disorders (D-dimer >300 ng/ml) were present in 8% of VeM, with ultrasound-confirmed deep vein thrombosis in 50% of those cases. All cases

with coagulation disorders but no thrombosis were extensive VeM affecting joint mobility.

- For LM, symptomatic cases were far more frequent than asymptomatic (85.7%), the most common being pain (57%), bleeding (21%), and volume changes with mass effect on surrounding structures (36%).
- In AVM, symptomatic cases represented 73% of the total. Palpable thrill (44%), pain (27%), bleeding (20%), increase in local temperature (7%) and mass effect (2%) were the most important.

3.3 | Complementary exams

3.3.1 | Imaging exams

Figure 4 details the imaging main exams performed for each VM subtype.

FIGURE 3 Color of vascular malformations (VM) according to the different subtypes

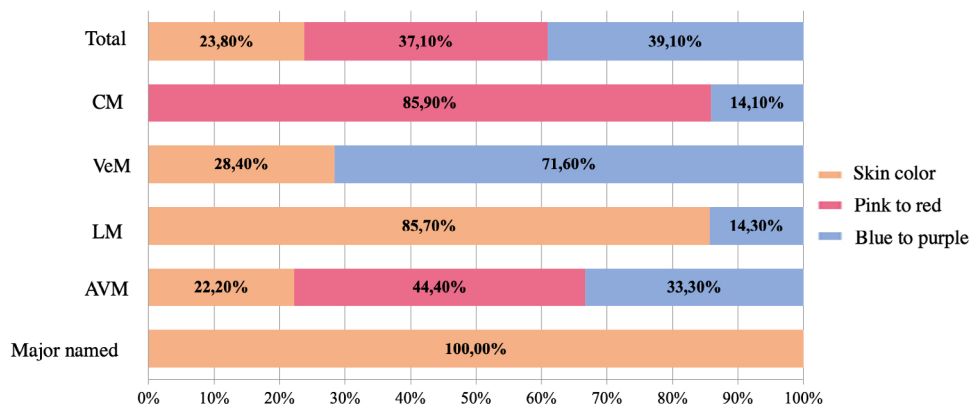
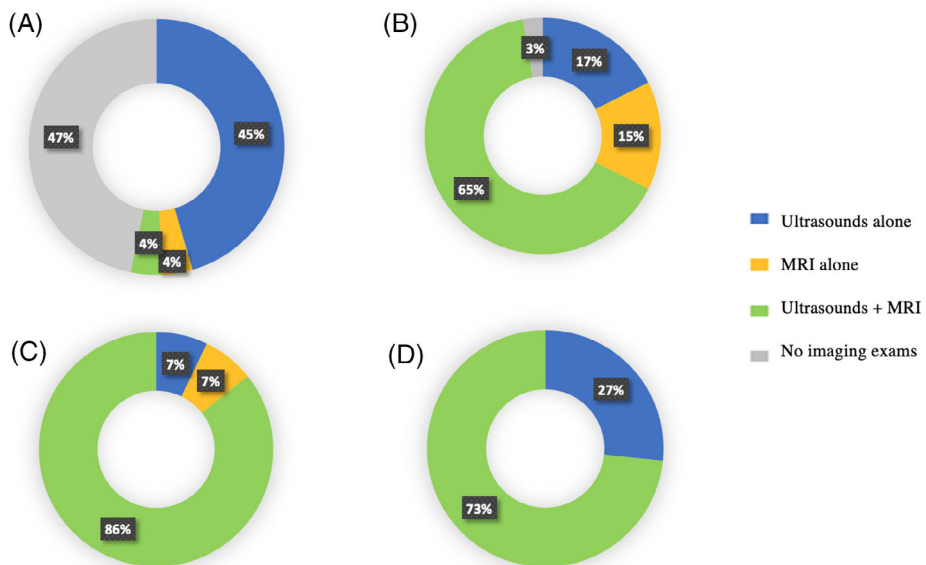


FIGURE 4 Imaging exams performed in vascular malformations (VM) subtypes (A) Capillary malformations, (B) Venous malformations, (C) Lymphatic malformations, (D) Arteriovenous malformations



3.3.2 | Clinico-radiological correlation

Ultrasound

Overall, we found a fairly strong positive relationship between clinical and ultrasound diagnosis ($\kappa = 0.812$, $p < 0.0001$) with differences between clinico-radiological correlation of ultrasounds and VM subtype ($p < 0.0001$). Ultrasound diagnosis was 97% correct for CM, 87% for VeM, 54% for LM and 87% for AVM.

MRI

Overall, we found a strong positive relationship between clinical and MRI diagnosis ($\kappa = 0.670$, $p < 0.0001$) with differences between clinico-radiological correlation of MRI and the VM subtype ($p < 0.0001$). MRI diagnosis was 83% correct for CM, 92% for VeM, 62% for LM and 58% for AVM.

The correlation found between ultrasound and MRI diagnosis was based on 101 patients in whom we performed both exams. We found a strong positive relationship between ultrasound and MRI diagnosis ($\kappa = 0.726$, $p < 0.0001$) with overall agreement in diagnosis in 81% of cases (75% for CM, 88% for VeM, 100% for LM and 63% for AVM). The correlation between ultrasounds and MRI on VM size was strongly positive ($\kappa = 0.912$, $p < 0.0001$).

3.4 | Treatment

Overall, 88 patients were managed conservatively, six with mTOR inhibitors, 19 with sclerotherapy, nine with embolization, 42 with surgery and 49 with laser therapy. Some patients received more than one treatment.

We found no relationship between decision-making on active treatment and VM subtype ($p = 0.491$), patient age ($p = 0.055$) or location of VM ($p > 0.05$ for all categories). However, treatment decision-making was influenced by VM size, as those < 5 cm² were more frequently managed conservatively ($p = 0.024$).

The management of each subtype is detailed as follows:

- CM: 64% of CM were treated with laser therapy (93% PDL and 7% PDL-NdYAG). The mean number of sessions was 6.57 for treatments without sedation and 4.12 for treatments under sedation. The number of laser therapy sessions was higher for CM ≥ 5 cm² ($p = 0.015$). However, we found a nonstatistically significant difference between number of laser therapy sessions and age of treatment onset ($p = 0.024$, $p = 0.882$) or location of CM ($p > 0.05$ for all categories). We found a trend towards a greater number of sessions in CM located in the lower limbs ($p = 0.099$).
- VeM: 46% of patients were managed conservatively. Sclerotherapy was the most frequent treatment (26%), followed by surgery (15%), laser therapy (9%) and mTOR inhibitors (3%). Bleomycin was the most often used sclerosing agent (63%). The mean number of sclerotherapy sessions was 2.71.
- LM: 36% of cases underwent surgery and 29% received mTOR inhibitors. All LM treated with oral Sirolimus were large,

complicated malformations leading to functional limitation or with laryngopharyngeal involvement.

- AMV: 47% of cases were treated with surgery (33% with preoperative embolization), 4% with embolization alone and 2% with laser therapy. Almost half the patients (47%) were managed conservatively.

3.5 | Multivariate analysis

Multivariate analysis revealed clinical symptoms, trunk location and age of onset as the best predictors of VM type, dwarfing all other factors studied. With these three categories correct diagnosis of CM and VeM reaches over 85%, of LM around 65% and 53% for AVM.

4 | DISCUSSION

The distribution of VM subtypes in our study is similar to those reported in the literature, where VeM are the most frequent ones.⁷ It may seem surprising that CM are not the most frequent VM, but this could be explained by the inclusion of patient referrals to eight different medical and surgical specialties, as well as both children and adults (0–78 years old). Considering only pediatric patients (under the age of 16) the distribution of VM changes and CM are the main group (50%). Small CM located in nonvisible areas rarely prompt pediatrician referral to tertiary hospitals. However, in our study, AVM were more frequent than in other studies.^{6,7} This could be due to several factors: we included all stages (about 70% were stage I–II) and all AVM were studied with ultrasound. As previously mentioned, correlation between different imaging exams was much weaker for AVM than for the other subtypes, which could lead to overdiagnosis.

Regarding location, over 50% of CM, VeM and AVM are located in the head and neck. Compared with previous reports (40%) our study found an even higher proportion of VeM located in head and neck (67.6%), frequently involving the oral mucosa.^{8–10} LM can be located anywhere in the body but tend to affect areas with most lymphatic drainage, such as the neck or axilla⁹ (Figure 1).

Although VM are congenital lesions, age of onset varies between subtypes. As previously reported, in our study we observed that CM tend to be evident at birth, LM at the age of 2,¹¹ VeM at puberty¹² and up to 40% of AVM not until adulthood.⁶ There are also fast-flow malformations related to trauma, infections or hormonal changes (such as digital AVM). While obstetrical history (preterm delivery, obstetrical complications and previous miscarriage) is related to development of infantile hemangiomas,^{13,14} we found no statistically-significant relationship with VM.

In line with conventional understanding and definitions in the literature, CM tend to be reddish, VeM bluish and LM keep the patients' skin tone. AVM are not characterized by a particular color as they may equally present as pink to red, blue to purple or skin color.

Analyzing size, we found that MC and ML tend to be larger than VeM and AVM. This smaller size might be explained by the high rate of symptomatic cases, resulting in earlier specialist referral.

CM are very often asymptomatic. However, progressive hypertrophy of soft tissues leading to bleeding or pain in nontreated CM is frequent.¹⁵ Ocular complications are described in about 15% of periorcular CM^{2,16}; we found a slightly higher proportion (22%), including glaucoma, exotropia and buphthalmos. Incidence of Sturge-Weber syndrome (SWS) in CM involving the area defined as high-risk¹⁷ ranges from 8 to 15%,¹⁷ similar to ours (12%). Although CM with secondary ocular complications should be considered as type I SWS, we only make reference to type II SWS with the typical triad. Symptomatic VeM, LM and AVM made up more than 70% of total cases, making a conservative approach less frequent.

Diagnosis of VM is mainly clinical. There is no need for complementary exams to diagnose CM, although in some cases ultrasound may help in the differential diagnosis with early infantile hemangiomas. For the other subtypes, Doppler ultrasound is the first line and main complementary exam to be done, while MRI helps determine extent and depth. Both imaging exams are especially useful for the diagnosis of VM when they present as a subcutaneous tumor in newborns. Dermatologists should suspect VM in the differential diagnosis, and in case of doubt request an imaging test. Diagnosis is not always easy and management requires a multidisciplinary perspective, making it vital for these patient cases to be discussed in the appropriate committees.

Although correlation between clinical and radiological diagnosis is good (especially for CM and VeM), most cases must be approached from multiple viewpoints. Treatment options for VM range from watchful waiting to aggressive surgeries, and management requires not only surgeons but also interventional radiologists and dermatologists specialized in laser therapy, as reported in our study.

Laser therapy (pulse dyed laser, PDL) is the most useful option to fade CM and halt its natural course.¹⁵ Previous publications recommend early treatment initiation (before the age of 10,¹⁸ 6,¹⁹ or 1²⁰); however, we found no supporting evidence for this. Recent studies report that CM located in the face and neck²¹ or proximally in extremities²² tend to have better outcomes, with fewer sessions needed. We also observed that CM located distally in extremities, especially if >5 cm², typically receive more sessions with worse results. While sclerotherapy or surgery seem the most effective treatment for symptomatic VeM, the use of oral mTOR inhibitors to treat common VeM is being evaluated²³ and has already been reported in BRB²⁴ and verrucous VeM.²⁵ We treated two VeM with oral sirolimus: a combined capillary-VeM and an extensive symptomatic common VeM.

Although surgery with preoperative embolization is considered the standard treatment for AVM, it is a complex procedure requiring a trained team. Oral MEK inhibitors (EudraCT 2019-003573-26) and thalidomide²⁶ have been proposed to treat inoperable AVM.

Limitations of our study include that the population may not be representative as we are a tertiary hospital where patients are referred for specialist opinion. As it is a retrospective study some data

may not have been available; however, detailed medical records of all patients discussed in the committee were at our disposal.

5 | CONCLUSION

VM is a frequent reason for consultation in dermatology; however, diagnosis and treatment require multidisciplinary management. Our report on the epidemiological, clinical, radiological and therapeutic characteristics of more than 200 VM evaluated in our hospital should contribute to the literature and provide practical data for clinicians and researchers. Genetics will probably play a major role in the future classification, diagnosis and targeted treatment of VM.

AUTHORS CONTRIBUTION

All authors are involved in the multidisciplinary committee according to their medical specialty. Dr Martín Hernández suggested and conceived the study. Dr Martín Hernández, Dr Puche-Torres and Dr Sanchis directed the project. Dr Estébanez carried out the study and wrote the article. All authors discussed the results and contributed to the final version.

DATA AVAILABILITY STATEMENT

The data that support the findings of this study are available on request from the corresponding author. The data are not publicly available due to privacy or ethical restrictions.

ORCID

Andrea Estébanez  <https://orcid.org/0000-0002-5700-6281>

REFERENCES

1. ISSVA classification for vascular anomalies. 2018. Disponible en: <https://www.issva.org/classification>
2. Rozas-Muñoz E, Frieden IJ, Roé E, Puig L, Baselga E. Vascular stains: proposal for a clinical classification to improve diagnosis and management. *Pediatr Dermatol Noviembre de*. 2016;33(6):570-584.
3. Valdivielso-Ramos M, Martín-Santiago A, Azaña JM, et al. Capillary malformation-arteriovenous malformation syndrome. A multicenter study. *Clin Exp Dermatol*. 2020;25:ced.14428.
4. Alegre-Sánchez A, Bernárdez C, Fonda-Pascual P, et al. Videodermoscopy and doppler-ultrasound in spider naevi: towards a new classification? *J Eur Acad Dermatol Venereol Enero de*. 2018;32(1):156-159.
5. McRae MY, Adams S, Pereira J, Parsi K, Wargon O. Venous malformations: clinical course and management of vascular birthmark clinic cases. *Australas J Dermatol*. 2013;54(1):22-30.
6. De Miguel R, López-Gutierrez JC, Boixeda P. Malformaciones arteriovenosas: un reto diagnóstico y terapéutico. *Actas Dermosifiliogr*. 2014;105(4):347-358.
7. Lopez-Gutierrez JC. Epidemiology of vascular anomalies. In: Mariella C, ed. *VAS European Book on Angiology and Vascular Medicine*. 1st ed. Aracne; 2018:949-954.
8. Greene AK, Alomari AI. Management of venous malformations. *Clin Plast Surg*. 2011;38(1):83-93.
9. Flors L, Leiva-Salinas C, Maged IM, et al. MR imaging of soft-tissue vascular malformations: diagnosis, classification, and therapy follow-up. *Radiographics*. 2011;31(5):1321-1340.

10. Fayad LM, Hazirolan T, Bluemke D, Mitchell S. Vascular malformations in the extremities: emphasis on MR imaging features that guide treatment options. *Skelet Radiol*. 2006;35(3):127-137.
11. Kiersten Ricci, Lymphatic Malformations. Cincinnati Children's Hospital Medical Center, <https://www.cincinnatichildrens.org/health//lymphatic>, 2020
12. Garzon MC, Huang JT, Enjolras O, Frieden IJ. Vascular malformations: part I. *J Am Acad Dermatol*. 2007;56(3):353-370.
13. Hemangioma Investigator G, Haggstrom AN, Drolet BA, et al. Prospective study of infantile hemangiomas: demographic, prenatal, and perinatal characteristics. *J Pediatr*. 2007;150(3):291-294.
14. Munden A, Butschek R, Tom WL, et al. Prospective study of infantile haemangiomas: incidence, clinical characteristics and association with placental anomalies. *Br J Dermatol*. 2014;170(4):907-913.
15. Sanchez-Carpintero I, Mihm MC, Mizeracki A, Waner M, North PE. Epithelial and mesenchymal hamartomatous changes in a mature port-wine stain: morphologic evidence for a multiple germ layer field defect. *J Am Acad Dermatol*. 2004;50(4):608-612.
16. Bayoumi NHL, Elsayed EN. Glaucoma in children with facial port wine stain. *Eur J Ophthalmol*. 2020;30(1):168-174.
17. Waelchli R, Aylett SE, Robinson K, Chong WK, Martinez AE, Kinsler VA. New vascular classification of port-wine stains: improving prediction of Sturge-weber risk. *Br J Dermatol*. 2014;171(4):861-867.
18. Namba Y, Mae O, Ao M. The treatment of port wine stains with a dye laser: a study of 644 patients. *Scand J Plast Reconstr Surg Hand Surg*. 2001;35(2):197-202.
19. Anolik R, Newlove T, Weiss ET, et al. Investigation into optimal treatment intervals of facial port-wine stains using the pulsed dye laser. *J Am Acad Dermatol*. 2012;67(5):985-990.
20. Morelli JG, Weston WL, Huff JC, Yohn JJ. Initial lesion size as a predictive factor in determining the response of port-wine stains in children treated with the pulsed dye laser. *Arch Pediatr Adolesc Med*. 1995;149(10):1142-1144.
21. Sabeti S, Ball KL, Burkhart C, et al. Consensus statement for the management and treatment of port-wine birthmarks in Sturge-weber syndrome. *JAMA Dermatol*. 2021;157(1):98-104. <https://jamanetwork.com/journals/jamadermatology/fullarticle/2772814>
22. Yu W, Zhu J, Han Y, Chang SJ, Shang Y, Ma G, et al. Assessment of outcomes with pulsed dye laser treatment of port-wine stains located proximally vs distally on extremities. <https://www.ncbi.nlm.nih.gov/pubmed/32347897>
23. Boscolo E, Limaye N, Huang L, et al. Rapamycin improves TIE2-mutated venous malformation in murine model and human subjects. *J Clin Invest*. 2015;125(9):3491-3504.
24. Wong XL, Phan K, Rodriguez Bandera AI, Sebaratnam DF. Sirolimus in blue rubber bleb naevus syndrome: a systematic review. *J Paediatr Child Health*. 2019;55(2):152-155.
25. Zhang G, Chen H, Zhen Z, et al. Sirolimus for treatment of verrucous venous malformation: a retrospective cohort study. *J Am Acad Dermatol*. 2019;80(2):556-558.
26. Boon LM, Marot L, Hammer F, Jeanjean A, Dekeuleneer V, Tadler M, et al. Thalidomide is an efficient treatment for symptomatic and/or life threatening arteriovenous malformations 2020.

How to cite this article: Estébanez A, Puche-Torres M, Sanchis García JM, et al. Characteristics of mucocutaneous vascular malformations drawn from a decade of a multidisciplinary committee experience. *Dermatologic Therapy*. 2021;e15074. <https://doi.org/10.1111/dth.15074>