

Title	Adjunct Antimicrobial Therapy and Periodontal Surgery to Treat Generalized Aggressive Periodontitis: A Case Report
Author(s)	Irokawa, D; Makino-Oi, A; Fujita, T; Yamamoto, S; Tomita, S; Saito, A
Journal	Bulletin of Tokyo Dental College, 57(2): 105-114
URL	<a href="http://hdl.handle.net/10130/5704">http://hdl.handle.net/10130/5704</a>
Right	
Description	

## Adjunct Antimicrobial Therapy and Periodontal Surgery to Treat Generalized Aggressive Periodontitis: A Case Report

Daisuke Irokawa<sup>1)</sup>, Asako Makino-Oi<sup>1)</sup>, Takahisa Fujita<sup>1,2)</sup>,  
Shigeki Yamamoto<sup>1,3)</sup>, Sachiyo Tomita<sup>1)</sup> and Atsushi Saito<sup>1)</sup>

<sup>1)</sup> Department of Periodontology, Tokyo Dental College,  
2-9-18 Misaki-cho, Chiyoda-ku, Tokyo 101-0061, Japan

<sup>2)</sup> Sumitomo Mitsui Banking Corporation, Tokyo Dental Clinic,  
1-3-2 Marunouchi, Chiyoda-ku, Tokyo 100-0005, Japan

<sup>3)</sup> Yamamoto Dental Clinic,  
1-3-3 Kandasudacho, Chiyoda-ku, Tokyo 101-0041, Japan

Received 14 December, 2015/Accepted for publication 13 January, 2016

### Abstract

Here we report a case of generalized aggressive periodontitis treated with periodontal therapy including adjunct antimicrobial therapy and periodontal surgery. The patient was a 22-year-old woman who presented with the chief complaint of gingival recession. Baseline examination revealed generalized plaque deposition and gingival inflammation. Thirty-nine percent of the sites had a probing depth (PD) of 4–6 mm and 2% a PD of  $\geq 7$  mm; 63% exhibited bleeding on probing (BOP). Radiographic examination revealed vertical bone loss in the molars and horizontal bone loss in other teeth. Microbiological examination of subgingival plaque revealed the presence of *Aggregatibacter actinomycetemcomitans* and *Tannerella forsythia*. Oral health-related quality of life was assessed as a measure of patient-reported outcome. Based on a clinical diagnosis of generalized aggressive periodontitis, initial periodontal therapy and adjunct antimicrobial therapy were implemented. After reducing inflammation and subgingival bacteria, open flap debridement was performed for teeth with a PD of  $\geq 4$  mm. Reevaluation showed no sites with a PD of  $\geq 5$  mm, a minimal level of BOP, and a marked reduction in the level of the targeted periodontal pathogens. The patient's oral health-related quality of life was slightly worsened during supportive periodontal therapy (SPT). Implementation of adjunct antimicrobial therapy targeting periodontal pathogens and subsequent periodontal surgery resulted in improvement in periodontal and microbiological parameters. This improvement has been adequately maintained over a 2-year period. However, additional care is necessary to further improve the patient's oral health-related quality of life during SPT.

Key words: Generalized aggressive periodontitis — Antimicrobial therapy —  
Local Drug Delivery System (LDDS) — Supportive periodontal therapy —  
Oral health-related quality of life

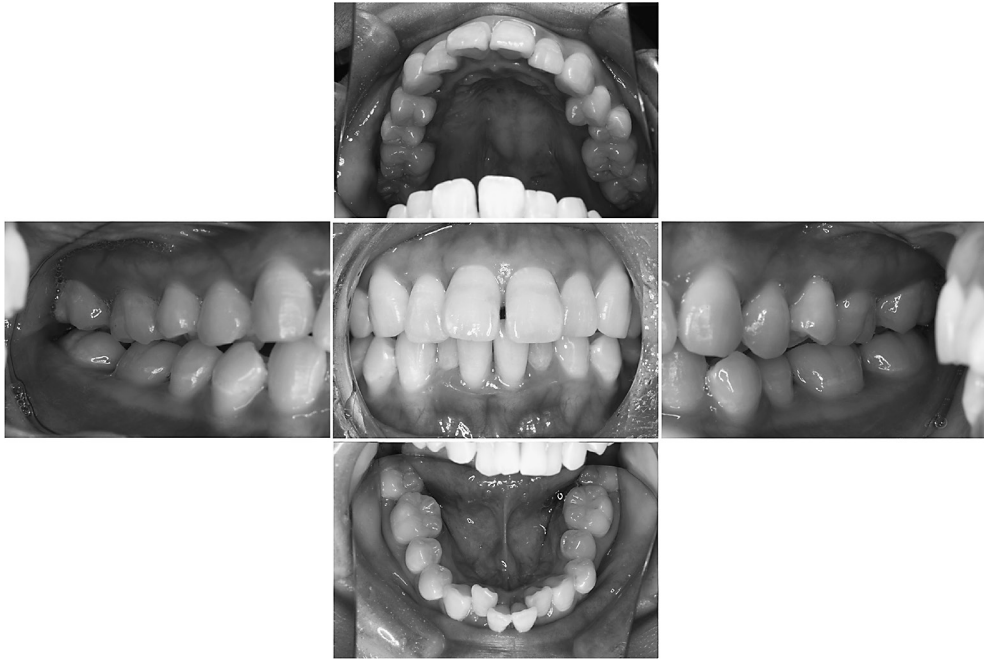


Fig. 1 Oral view at baseline

### Introduction

Periodontitis, a dysbiotic inflammatory disease, has an adverse impact on systemic health<sup>6</sup>. Although it can be classified into several different categories, there are two main types: aggressive periodontitis (AgP) and chronic periodontitis<sup>2</sup>, the former of which is distinguished by characteristic clinical and laboratory findings<sup>10</sup>. Both localized and generalized AgP share certain features in common: firstly, patients with this disease are otherwise clinically healthy; secondly, rapid loss of attachment and destruction of bone; and thirdly, familial aggregation<sup>10</sup>. The reported prevalence of AgP in Asia is relatively low, at between 0.13 and 1.8%<sup>20</sup>. However, given the early onset and rapid progression so characteristic of this disease, early intervention is important. If left untreated, further resorption of alveolar bone and tooth loss or extraction follow in sequence, and extensive periodontal prosthetic procedures will become necessary<sup>21</sup>.

Patient perception of periodontal disease and its treatment have increasingly come to be recognized as an important measurement of outcome<sup>16</sup>, and our research team has been investigating the effect of periodontitis and its treatment on oral health-related quality of life (QoL)<sup>13,16,18</sup>. Currently, information is still limited on the effect of periodontal treatment on patient perception of AgP.

In the present report, we describe a case of AgP involving adjunct antimicrobial therapy and periodontal surgery to control periodontal pockets and infection by periodontal pathogens. In addition to periodontal examination, assessment of oral health-related QoL was also performed as a patient-reported outcome measurement.

### Case Report

Written informed consent was obtained from the patient for inclusion in this report.

B P	5 3 3	6 3 3	3 2 4	4 2 4	4 2 6	5 2 4	4 2 5	3 2 5	5 2 5	5 2 4	4 2 3	3 2 6	4 3 5	5 2 3		
	5 2 6	7 3 6	4 3 6	5 3 6	6 3 6	5 3 4	4 3 3	4 3 5	6 3 6	6 5 3	4 5 3	2 2 3	5 3 6	4 3 3		
	8	7	6	5	4	3	2	1	1	2	3	4	5	6	7	8
	8	7	6	5	4	3	2	1	1	2	3	4	5	6	7	8
L B	4 3 4	3 5 7	3 3 6	3 4 4	3 2 4	3 2 2	3 2 4	3 3 3	3 2 2	2 2 3	2 2 3	3 3 3	7 3 4	4 3 4		
	3 6 3	4 3 6	3 2 3	3 2 3	3 2 3	4 2 3	3 2 3	3 4 4	4 3 4	4 3 3	3 2 2	2 2 3	3 3 3	4 3 4		

PCR 60%

Fig. 2 Periodontal examination at baseline

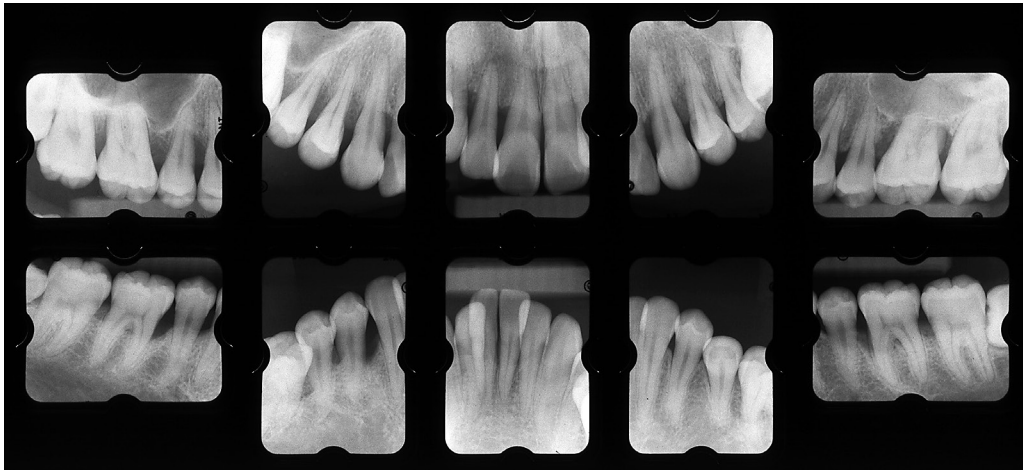


Fig. 3 Radiographic view at baseline

**1. Baseline examination**

In April 2012, a 22-year-old woman was referred to the Clinic of Conservative Dentistry at Tokyo Dental College Chiba Hospital with the chief complaint of gingival recession. The patient was systemically healthy. Although she had been receiving regular dental check-ups, she had noticed the appearance of gingival recession and spaces between the anterior teeth. Her 49-year-old mother had a history of severe periodontitis and wore a partial removable prosthesis.

A visual examination revealed general gingival inflammation and recession in the canines and lower molars (Fig. 1). Diastema was present between tooth #11 and 21. Tooth #25 showed buccal inclination. Crowding was observed in teeth #32–42. The guiding teeth were #14–16 and #44–46 for right lateral

movement, and 24, 26, 27 and 35–37 for left lateral movement. No premature contact or balancing-contact interference was observed.

Figure 2 shows the results of the baseline periodontal examination. Mean full-mouth probing depth (PD) was 3.6 mm. Thirty-nine percent of sites showed a PD of 4–6 mm and 2% a PD of ≥7 mm; 63% exhibited bleeding on probing (BOP). Thirteen teeth had a PD of ≥6 mm. Degree I furcation involvement<sup>14)</sup> was found in #16. The level of plaque control as assessed according to the O’Leary Plaque Control Record (PCR)<sup>15)</sup> was 60%. Radiographic examination (Fig. 3) revealed vertical bone defects in #11, 13–16, 23, 24, 26, 36, 37, and 44–46. Bone resorption exceeding 2/3 of the root length was found in #16 and 17.

Microbiological examination was performed according to a method described previously<sup>22)</sup>.

Table 1 Treatment process

April 2012	Initial periodontal therapy <ul style="list-style-type: none"> <li>• Plaque control</li> <li>• Quadrant SRP</li> <li>• Extraction (#28 and 38)</li> </ul>
July 2012	(Reevaluation) <ul style="list-style-type: none"> <li>• Antimicrobial therapy (LDDS) (#11–17, 23–27, 31, 32, 35–37, 41, 43, 44, 46, 47)</li> </ul>
September 2012	(Reevaluation) Surgical periodontal therapy <ul style="list-style-type: none"> <li>• Open flap debridement (#16, 17, 26, 27, 36, 37, 46, 47)</li> </ul>
August 2013 to present	(Reevaluation) Supportive periodontal therapy <ul style="list-style-type: none"> <li>• Plaque control</li> <li>• Professional tooth cleaning</li> <li>• Extraction (#18 and 48)</li> <li>• Hypersensitivity treatment (#13–17, 23–27, 31, 34–37, 41, 44–47)</li> </ul>

SRP, scaling and root planing; LDDS, local drug delivery system

Briefly, a sample of subgingival plaque obtained from the deepest pocket (in tooth #36) with sterile paper points and transferred into a sampling tube supplied in a commercial kit (Saliva-Check Lab, GC, Tokyo, Japan) was sent to a microbiological testing laboratory (GC Oral Check Center, Tokyo) for quantitative analysis of *Aggregatibacter actinomycetemcomitans*, *Porphyromonas gingivalis*, and *Tannerella forsythia* using real-time PCR. Total bacterial count at baseline was  $2.7 \times 10^7$  copies. The values for *A. actinomycetemcomitans* and *T. forsythia* were  $1.3 \times 10^6$  (comprising 4.8% of the total bacterial count) and  $1.0 \times 10^4$  (0.037%), respectively. No *P. gingivalis* was detected.

The patient's oral health-related QoL was assessed using an oral health-related QoL (OHRQL) instrument<sup>16)</sup> as a measurement of patient-reported outcome. The total OHRQL score was 17. The clinical diagnosis was generalized AgP<sup>2)</sup>.

## 2. Treatment plan

### 1) Initial periodontal therapy

This comprised: (1) instruction on maintenance of oral hygiene and an explanation of the etiology of AgP; (2) quadrant scaling and root planing (SRP); and (3) extraction

of #18, 28, 38, and 48.

### 2) Reevaluation

### 3) Antimicrobial therapy

This consisted of administration of the antimicrobial agent minocycline-HCl (PERIOFEEL DENTAL Oint., Showa Yakuhin Kako, Tokyo)<sup>17)</sup> in pockets with a PD of  $\geq 4$  mm using a local drug delivery system (LDDS).

### 4) Reevaluation

### 5) Surgical periodontal therapy (for sites with a PD of $\geq 4$ mm)

This comprised: (1) regenerative therapy with enamel matrix derivative (EMD) for #11, 13–16, 23, 24, 26, 36, 37, and 44–46; (2) open flap debridement for the remaining sites with residual pockets; and (3) periodontal plastic surgery to improve gingival recession.

### 6) Reevaluation

### 7) Treatment for recovery of oral function

This comprised orthodontic treatment.

### 8) Supportive periodontal therapy (SPT)

## 3. Treatment process

An outline of the treatment process is shown in Table 1.

### 1) Initial periodontal therapy

The periodontal conditions were explained to the patient by showing periodontal charts,

Table 2 Change in subgingival count (copies) of total bacteria *A. actinomycetemcomitans* (*Aa*), *T. forsythia* (*Tf*), and *P. gingivalis* (*Pg*), as assessed by real-time PCR

	Baseline	Post-IP/AT	Post-Surgery	SPT: start	SPT: 6M	SPT: 26M
Total bacteria	27,000,000	8,700,000	38,000	350	1,700	2,100
<i>Aa</i>	1,300,000	5,400	60	0	0	0
<i>Tf</i>	10,000	0	0	0	0	0
<i>Pg</i>	0	0	0	0	0	0

IP, initial periodontal therapy; AT, antimicrobial therapy; SPT, supportive periodontal therapy

radiographs, and the results of microbiological assessment with the aim of increasing her knowledge of the disease and motivation to undergo treatment. Initial periodontal therapy consisting mainly of instruction on tooth brushing (the Bass method); quadrant SRP was also implemented.

Two of the third molars (#28 and 38) were extracted for prophylactic reasons.

#### 2) Antimicrobial therapy

Reevaluation following initial periodontal therapy showed sites with a PD of  $\geq 4$  mm, so LDDS using 2% minocycline-HCl was administered once a week for 4 weeks.

The total OHRQL score at this stage was 16.

#### 3) Periodontal surgery

At reevaluation, closed pockets<sup>24)</sup> were observed in 71% of the teeth and BOP in 19%; the plaque score was 26%. These results were judged to be “insufficient” according to the criteria for the success of non-surgical periodontal therapy<sup>9)</sup>. Microbiological assessment revealed a decrease in *A. actinomycetemcomitans* ( $5.4 \times 10^3$ , 0.06% of the total bacterial count) (Table 2). Neither *T. forsythia* nor *P. gingivalis* were found in the pockets examined.

The need and options for periodontal surgery based on these findings were explained to the patient. After consultation, she chose not to receive EMD therapy. Subsequently, open flap debridement was performed for #16 and 17 (Fig. 4a), with essentially the same procedure being performed for #26, 27, 36, 37, 46, and 47 also (Fig. 4b). The remaining sites with a PD of  $\geq 4$  mm received re-SRP.

The patient did not consent to periodontal plastic surgery, which was suggested for

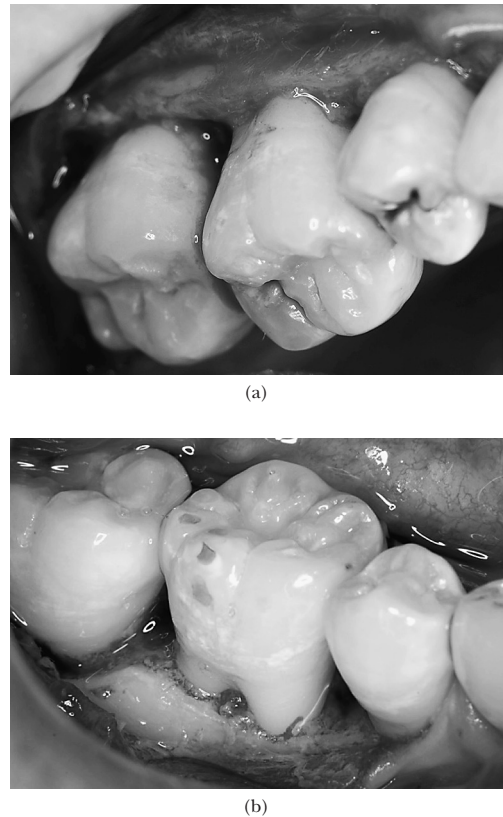


Fig. 4 During open flap debridement for (a) #16 and 17, (b) #46

improvement of gingival recession.

#### 4) Supportive periodontal therapy

At reevaluation, sites with a PD of 4 mm were found in #16 and 26. However, the values for BOP and PCR were 4 and 17%, respectively, indicating an improvement. The targeted periodontal pathogens were found

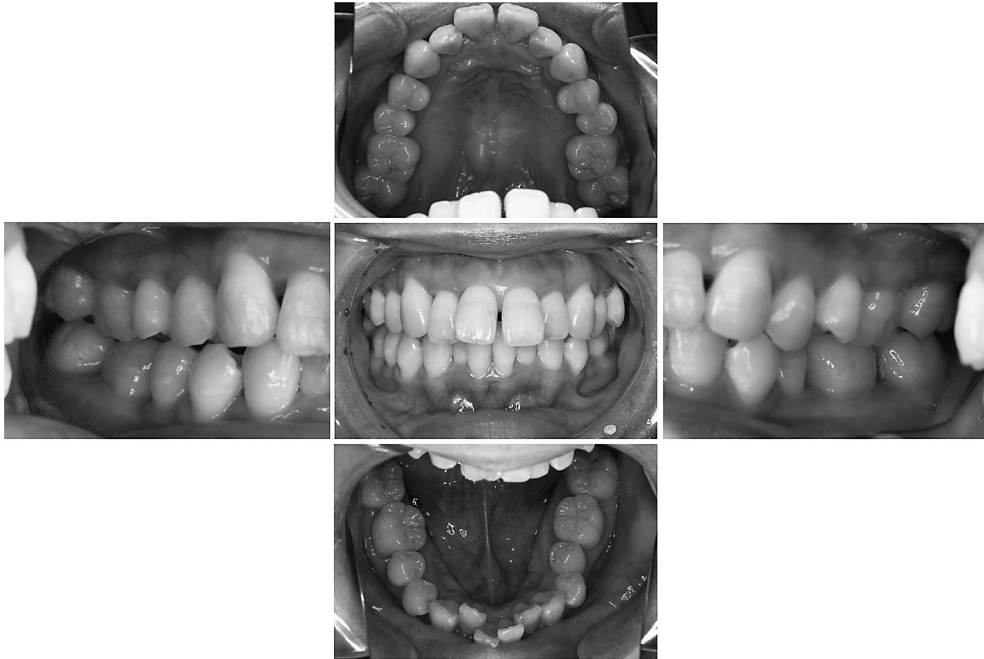


Fig. 5 Oral view at 6 months during supportive periodontal therapy (SPT)

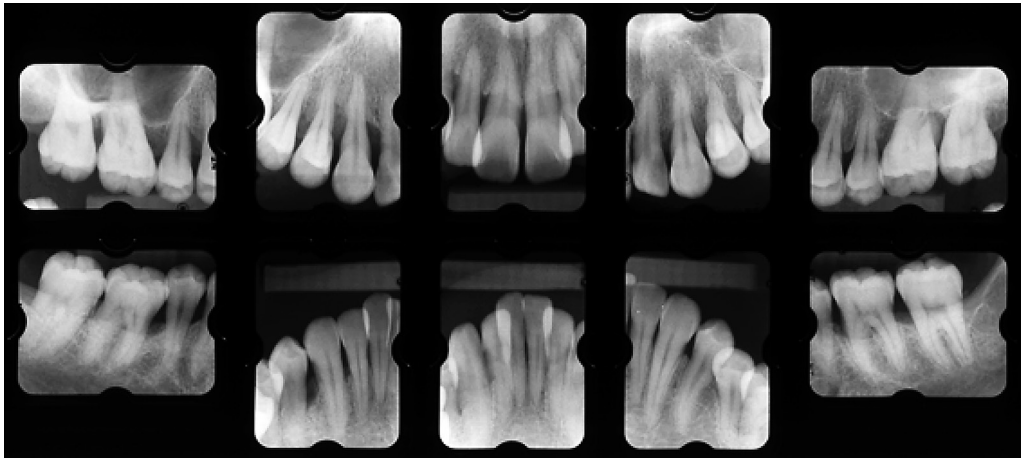


Fig. 6 Radiographic view at 6 months during SPT

to be suppressed even further: the count for *A. actinomycetemcomitans* was  $6.0 \times 10^1$  (0.16%) (Table 2). Neither *T. forsythia* nor *P. gingivalis* was detected. Therefore, periodontal status was judged to be stable and the patient was placed in a recall system for SPT. According

to Periodontal Risk Assessment<sup>11)</sup>, the risk at SPT was judged to be moderate. Because the patient refused the proposed orthodontic treatment, problems regarding malalignment remained. Therefore, the patient was frequently recalled (2 to 3 times per month) to

B P		3 2 3	3 2 3	2 2 2	2 2 2	2 2 2	2 2 2	2 2 2	2 1 2	2 2 2	2 2 2	2 2 2	3 2 2	2 2 2	2 2 2	2 2 3	3 2 3	
		3 3 3	3 2 3	2 2 2	2 2 2	3 2 2	2 2 2	2 2 2	2 2 2	2 2 2	2 2 2	2 2 2	2 2 3	3 2 2	2 2 2	2 2 3	2 3 3	
	<b>8</b>	<b>7</b>	<b>6</b>	<b>5</b>	<b>4</b>	<b>3</b>	<b>2</b>	<b>1</b>	<b>1</b>	<b>1</b>	<b>2</b>	<b>3</b>	<b>4</b>	<b>5</b>	<b>6</b>	<b>7</b>	<b>8</b>	
	<b>8</b>	<b>7</b>	<b>6</b>	<b>5</b>	<b>4</b>	<b>3</b>	<b>2</b>	<b>1</b>	<b>1</b>	<b>2</b>	<b>3</b>	<b>4</b>	<b>5</b>	<b>6</b>	<b>7</b>	<b>8</b>		
L B		2 2 2	2 2 2	2 2 2	2 2 2	2 2 2	2 2 2	2 2 2	2 2 2	2 2 2	2 2 2	2 2 2	2 2 2	2 2 2	2 2 2	2 2 2	2 2 2	
		3 2 2	2 2 2	2 2 2	2 2 2	2 2 2	2 2 2	2 2 2	2 2 2	2 2 2	2 2 2	2 2 2	2 2 2	2 2 2	2 2 2	2 2 2	3 2 3	

PCR 11%

Fig. 7 Periodontal examination at 6 months during SPT

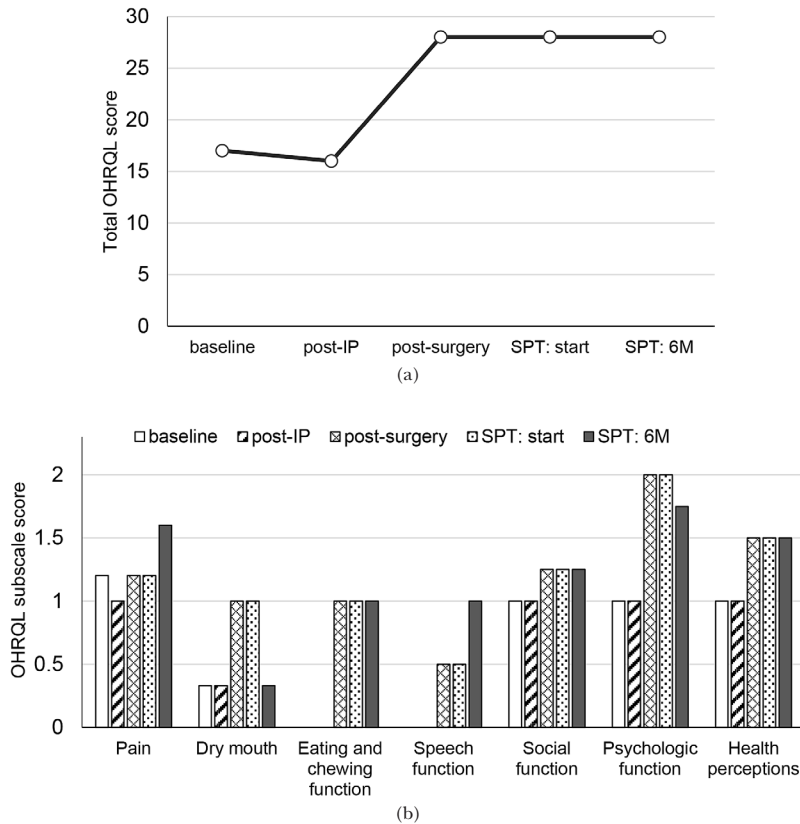


Fig. 8 Change in OHRQL scores: (a) total score, (b) subscale score

IP, initial periodontal therapy; SPT, supportive periodontal therapy. Lower score denotes better QoL.

assess her ability to control plaque during the early phase of SPT. The remaining third molars (#18 and 48) were subsequently extracted for prophylactic reasons. An oral view, radiographic view, and the patient’s periodontal chart at 6 months after start of SPT are shown in Figs. 5–7. The total OHRQL score at the

start of SPT was 28, showing slight worsening in oral health-related QoL compared to at baseline (Fig. 8). A fluoro-alumino-calcium silicate-based desensitizer (Nanoseal, Nihon Shika Yakuhin, Shimonoseki, Japan) was used to treat any teeth that were hypersensitive.

Over the last 26 months, the periodontal



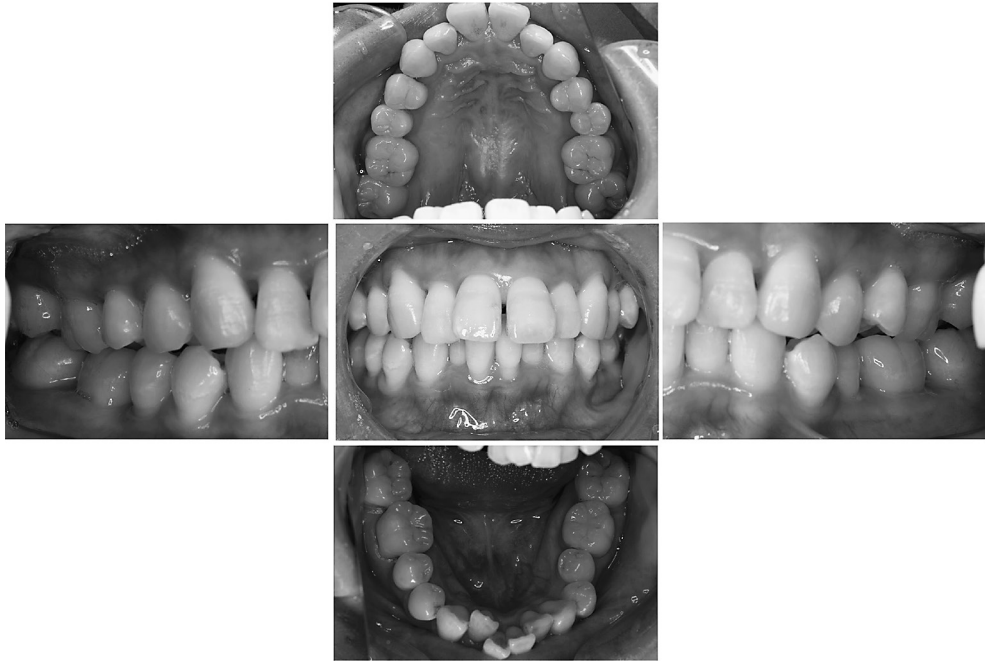


Fig. 9 Oral view at 26 months during SPT

condition has remained stable in most of the teeth (Fig. 9). The status of oral hygiene is good, with a PCR score of 11%. The targeted periodontal pathogens were no longer detected (Table 2). The total OHRQL score was still 28, unchanged from that at the start of SPT (Fig. 8a). The patient is currently being followed-up once a month.

### Discussion

Despite ample evidence showing AgP as a distinct disease category which is different from chronic periodontitis, clear case definitions of these two disease types are still lacking<sup>1)</sup>. The patient in the present report was otherwise generally healthy. We believe that the onset of AgP here may have occurred at around puberty, followed by rapid progression of periodontal destruction. Familial aggregation was also suspected. All these factors are consistent with a diagnosis of AgP<sup>2)</sup>.

The involvement of *A. actinomycetemcomitans*

and/or *P. gingivalis* has been implicated in the pathogenesis and progression of AgP<sup>19)</sup>. Again, at baseline, the present patient was harboring *A. actinomycetemcomitans* and *T. forsythia*. Therefore, early intervention was directed at reducing the depth of the periodontal pockets and levels of these periodontal pathogens. According to the guidelines of the Japanese Society of Periodontology, the principles of antimicrobial therapy are: 1) controlled use based on a treatment plan; 2) a clear objective; 3) assessment of adverse effects; and 4) the need for microbiological testing<sup>8)</sup>. Therefore, in line with the first of these recommendations, meticulous plaque control and subsequent SRP were implemented first to reduce the level of plaque biofilm as much as possible. In line with the second and fourth recommendations, microbiological assessment was performed and the primary goal established as reducing the level of periodontal pathogens. In line with the third recommendation, an antimicrobial agent was administered using an LDDS and the patient's condition both

during and after antimicrobial treatment carefully monitored. The clinical and microbiological efficacies of locally delivered antimicrobial agents have been reported in several studies<sup>4,5,7,12,17,23</sup>. In the present case, initial periodontal therapy and administration of 2% minocycline-HCl by an LDDS markedly improved periodontal parameters and reduced levels of *A. actinomycetemcomitans* and *T. forsythia*. However, these treatment modalities failed to completely eliminate periodontal pockets with a PD of  $\geq 4$  mm and the subgingival presence of those pathogens. Therefore, periodontal surgery was implemented to address these problems.

Following surgical treatment, periodontal and microbiological parameters showed a marked improvement. It is, however, important to note that the patient's OHRQL actually worsened, although she verbally expressed gratitude and general satisfaction with the treatment she had received. One reason for this may be that we were unable to improve gingival recession, which had been the patient's chief complaint on presenting at our hospital. After discussing various treatment options, she decided not to receive periodontal plastic surgery such as having a connective tissue graft with an coronally repositioned flap. The patient did, however, agree to periodontal surgery to reduce the depth of the periodontal pockets. Again, though, some discomfort resulted from this, including hypersensitivity and food impaction. It is also possible that the patient became more aware of her oral and general health during the treatment period. Some improvement in hypersensitivity was achieved, but a complete resolution was not possible. These factors may have contributed to the higher total OHRQL scores and some of the subscale scores (Fig. 8). This experience reminded us of the importance of patient-centered outcome measurement. Currently, we are focusing on improving the OHRQL subscale score by interventions, including treatment for hypersensitivity.

In a case series, Buchmann *et al.*<sup>3</sup> reported that while 95% of AgP lesions can be successfully arrested by comprehensive mechanical/

surgical intervention together with antimicrobial therapy, some 2 to 5% of patients will still experience discrete or recurrent episodes of disease progression. Furthermore, it has recently been reported that adjunctive antimicrobial therapy may be more beneficial in patients with generalized AgP harboring *A. actinomycetemcomitans* than in those who do not<sup>3</sup>. However, evidence regarding when periodontal pathogens are likely to recur is still insufficient. Therefore, in the present patient, we will continue to monitor the targeted pathogens every 6 to 12 months during SPT.

## References

- 1) Albandar JM (2014) Aggressive and acute periodontal diseases. *Periodontol* 2000 65:7–12.
- 2) Armitage GC (1999) Development of a classification system for periodontal diseases and conditions. *Ann Periodontol* 4:1–6.
- 3) Buchmann R, Nunn ME, Van Dyke TE, Lange DE (2002) Aggressive periodontitis: 5-year follow-up of treatment. *J Periodontol* 73:675–683.
- 4) Greenstein G (2006) Local drug delivery in the treatment of periodontal diseases: assessing the clinical significance of the results. *J Periodontol* 77:565–578.
- 5) Guerrero A, Nibali L, Lambertenghi R, Ready D, Suvan J, Griffiths GS, Wilson M, Tonetti MS (2014) Impact of baseline microbiological status on clinical outcomes in generalized aggressive periodontitis patients treated with or without adjunctive amoxicillin and metronidazole: an exploratory analysis from a randomized controlled clinical trial. *J Clin Periodontol* 41:1080–1089.
- 6) Hajishengallis G (2015) Periodontitis: from microbial immune subversion to systemic inflammation. *Nat Rev Immunol* 15:30–44.
- 7) Hanes PJ, Purvis JP (2003) Local anti-infective therapy: pharmacological agents. A systematic review. *Ann Periodontol* 8:79–98.
- 8) Japanese Society of Periodontology (2011) Guideline for antimicrobial treatment in patients with periodontal disease 2010, p.10, Japanese Society of Periodontology, Tokyo. (in Japanese)
- 9) Jönsson B, Öhrn K (2010) Evaluation of an individually tailored oral health educational programme on periodontal health. *J Clin*

- Periodontol 37:912–919.
- 10) Lang N, Bartold PM, Cullinan M, Jeffcoat M, Mombelli A, Murakami S, Page R, Papapanou P, Tonetti P, Van Dyke T (1999) Consensus report: aggressive periodontitis. *Ann Periodontol* 4:53.
  - 11) Lang NP, Tonetti MS (2003) Periodontal risk assessment (PRA) for patients in supportive periodontal therapy (SPT). *Oral Health Prev Dent* 1:7–16.
  - 12) Lu HK, Chei CJ (2005) Efficacy of subgingivally applied minocycline in the treatment of chronic periodontitis. *J Periodontol Res* 40: 20–27.
  - 13) Makino-Oi A, Ishii Y, Hoshino T, Okubo N, Sugito H, Hosaka Y, Fukaya C, Nakagawa T, Saito A (2016) Effect of periodontal surgery on oral health-related quality of life in patients who have completed initial periodontal therapy. *J Periodontol Res* 51:212–220.
  - 14) Nymann S, Lindhe J (1989) Examination of patients with periodontal disease, *Textbook of Clinical Periodontology*, 2nd ed., pp.316–317, Munksgaard, Copenhagen.
  - 15) O’Leary TJ, Drake RB, Naylor JE (1972) The plaque control record. *J Periodontol* 43:38.
  - 16) Saito A, Hosaka Y, Kikuchi M, Akamatsu M, Fukaya C, Matsumoto S, Ueshima F, Hayakawa H, Fujinami K, Nakagawa T (2010) Effect of initial periodontal therapy on oral health-related quality of life in patients with periodontitis in Japan. *J Periodontol* 81:1001–1009.
  - 17) Saito A, Hosaka Y, Nakagawa T, Seida K, Yamada S, Okuda K (1994) Locally delivered minocycline and guided tissue regeneration to treat post-juvenile periodontitis. A case report. *J Periodontol* 65:835–839.
  - 18) Saito A, Ota K, Hosaka Y, Akamatsu M, Hayakawa H, Fukaya C, Ida A, Fujinami K, Sugito H, Nakagawa T (2011) Potential impact of surgical periodontal therapy on oral health-related quality of life in patients with periodontitis: a pilot study. *J Clin Periodontol* 38:1115–1121.
  - 19) Socransky SS, Haffajee AD (1992) The bacterial etiology of destructive periodontal disease: current concepts. *J Periodontol* 63:322–331.
  - 20) Susin C, Haas AN, Albandar JM (2014) Epidemiology and demographics of aggressive periodontitis. *Periodontol* 2000 65:27–45.
  - 21) Takanashi T, Fujinami K, Matsuzaki M, Sekine H, Saito A (2012) Treatment of generalized aggressive periodontitis with enamel matrix derivative and implant prosthesis: A case report. *Clinic Adv Periodontics* 2:187–194.
  - 22) Tomita S, Komiya-Ito A, Imamura K, Kita D, Ota K, Takayama S, Makino-Oi A, Kinumatsu T, Ota M, Saito A (2013) Prevalence of *Aggregatibacter actinomycetemcomitans*, *Porphyromonas gingivalis* and *Tannerella forsythia* in Japanese patients with generalized chronic and aggressive periodontitis. *Microb Pathog* 61–62:11–15.
  - 23) van Steenberghe D, Rosling B, Söder PÖ, Landry RG, van der Velden U, Timmerman MFT, McCarthy EF, Vandenhoven G, Wouters C, Wilson M, Matthews J, Newman HN (1999) A 15-month evaluation of the effects of repeated subgingival minocycline in chronic adult periodontitis. *J Periodontol* 70:657–667.
  - 24) Wennström JL, Tomasi C (2005) Full-mouth ultrasonic debridement versus quadrant scaling and root planing as an initial approach in the treatment of chronic periodontitis. *J Clin Periodontol* 32:851–859.

*Correspondence:*

Dr. Atsushi Saito  
 Department of Periodontology,  
 Tokyo Dental College,  
 2-9-18 Misaki-cho, Chiyoda-ku,  
 Tokyo 101-0061, Japan  
 E-mail: atsaito@tdc.ac.jp