

<https://helda.helsinki.fi>

Effect of cataract surgery on wet age-related macular degeneration activity

Karesvuo, Petteri

2022-02

Karesvuo , P , Elbaz , U , Achiron , A , Hecht , I , Kaarniranta , K & Tuuminen , R 2022 , ' Effect of cataract surgery on wet age-related macular degeneration activity ' , Acta Ophthalmologica , vol. 100 , no. 1 , pp. e262-e269 . <https://doi.org/10.1111/aos.14864>

<http://hdl.handle.net/10138/339526>

<https://doi.org/10.1111/aos.14864>

cc_by

publishedVersion

Downloaded from Helda, University of Helsinki institutional repository.

This is an electronic reprint of the original article.

This reprint may differ from the original in pagination and typographic detail.

Please cite the original version.

Effect of cataract surgery on wet age-related macular degeneration activity

Petteri Karesvuo,^{1,2†} Uri Elbaz,^{3,4†} Asaf Achiron,^{3,5,6} Idan Hecht,^{1,3,7} Kai Kaarniranta^{8,9} and Raimo Tuuminen^{1,10}

¹Helsinki Retina Research Group, University of Helsinki, Helsinki, Finland

²Department of Ophthalmology, Helsinki University Hospital, Helsinki, Finland

³Sackler School of Medicine, Tel Aviv University, Tel Aviv, Israel

⁴Department of Ophthalmology, Rabin Medical Center, Petach-Tikva, Tel Aviv, Israel

⁵Department of Ophthalmology, Wolfson Medical Center, Holon, Israel

⁶Bristol Eye Hospital, Bristol, UK

⁷Department of Ophthalmology, Shamir Medical Center, Tel Aviv, Israel

⁸Department of Ophthalmology, University of Eastern Finland, Kuopio, Finland

⁹Department of Ophthalmology, Kuopio University Hospital, Kuopio, Finland

¹⁰Department of Ophthalmology, Kymenlaakso Central Hospital, Kotka, Finland

ABSTRACT.

Background: Wet age-related macular degeneration (AMD) and age-related cataract are often coexisting causes of visual impairment. Yet, the timing of cataract surgery in wet AMD patients is controversial.

Methods: One hundred and eleven eyes of 111 patients with wet AMD underwent cataract surgery at Helsinki University Hospital in Finland during 2014–2018. Best-corrected visual acuity and central subfield macular thickness (CSMT) were analysed at the time of wet AMD diagnosis, at the last recording prior to cataract surgery and at the first recording and at 1 year after surgery. The cumulative number of anti-vascular endothelial growth factor (anti-VEGF) injections at surgery, systemic and topical medication and postoperative anti-VEGF burden were recorded.

Results: Mean age was 78.9 ± 5.6 years at the time of surgery. Central subfield macular thickness (CSMT) significantly decreased (280.1 ± 75.0 μm preoperatively to 268.6 ± 67.6 μm at the first postoperative recording, $p = 0.001$, and to 265.9 ± 67.9 μm at 1 year, $p = 0.003$), visual acuity improved (0.70 ± 0.46 logMAR units preoperatively to 0.39 ± 0.40 at the first postoperative recording, and to 0.33 ± 0.34 at 1 year, $p < 0.001$ for both) and anti-VEGF treatment intervals lengthened despite the surgery (6.53 ± 2.08 weeks prior to surgery to 7.03 ± 2.23 weeks at 1 year, $p = 0.246$, and to 7.05 ± 2.57 weeks at the last documented visit, $p = 0.035$). A CSMT increase of over 30% from the preoperative values was seen in only one case (1 out of 111 eyes, 0.9%). Macular status at surgery, wet AMD subtype, comorbidity of type II diabetes, systemic drugs and topical anti-inflammatory medication were not associated with macular changes nor with treatment intervals after surgery. The cumulative number of anti-VEGF injections correlated neither with CSMT change postoperatively ($r = -0.051$, $p = 0.619$) nor with CSMT change at 1 year ($r = 0.091$, $p = 0.426$).

Conclusion: Satisfactory visual outcomes and controlled disease activity were seen in patients with wet AMD undergoing cataract surgery. We found no evidence to support delaying surgery in patients who require it.

Key words: age-related cataract – anti-vascular endothelial growth factor – cataract surgery – wet age-related macular degeneration

Acta Ophthalmol. 2022; 100: e262–e269

© 2021 The Authors. Acta Ophthalmologica published by John Wiley & Sons Ltd on behalf of Acta Ophthalmologica Scandinavica Foundation

This is an open access article under the terms of the Creative Commons Attribution License, which permits use, distribution and reproduction in any medium, provided the original work is properly cited.

doi: 10.1111/aos.14864

Introduction

Age-related macular degeneration (AMD) is the leading cause of visual

impairment in western countries with increasing global incidence (Wong et al. 2014; Mitchell et al. 2018). Age-

related cataracts often coexist with AMD (Ho et al. 2008), with reported comorbidity in 74% of visually

impaired patients over 65 years of age (Kessel et al. 2015; Flaxman et al. 2017). Wet AMD can cause vision to deteriorate rapidly if left untreated. In recent years, antivascular endothelial growth factor (anti-VEGF) injections have revolutionized the prognosis of wet AMD.

The timing of cataract surgery among wet AMD patients is a matter of debate (Kessel et al. 2015). Apparently, it might be reasonable to postpone cataract surgery when there is concern about wet AMD exacerbation, as cataract surgery might induce an inflammatory response. It is postulated that surgery may disrupt or further stimulate delicate leaking neovessels characteristic of wet AMD. Consequently, surgery might stimulate progression of geographic atrophy, development of choroidal neovascularization (CNV) or lead to a weaker anti-VEGF treatment response (Saraf et al. 2015). On the other hand, cataract reduces retinal visibility and hinders treatment, in addition to reducing patients' vision. It is, therefore, not completely clear whether wet AMD should be treated with the normal anti-VEGF protocol despite cataract surgery, and whether it is justified to postpone cataract surgery depending on disease activity.

Comorbidities, especially diabetes, and patients' systemic medication such as vasoactive drugs were suggested to have a bearing on the incidence of pseudophakic cystoid macular oedema (PCME) after routine cataract surgery (Ylinen et al. 2018; Danni et al. 2019). Antihypertensive drugs and statins have not been found to be significantly associated with the progression of AMD (Al-Holou et al. 2015; Heesterbeek et al. 2020), while anticoagulation and antiplatelet drugs have been considered to carry at least a theoretical risk of exacerbating wet AMD (Small et al. 2017).

Several studies have evaluated the influence of cataract extraction on AMD progression (Cugati et al. 2006; Chew et al. 2009). Nevertheless, there is a lack of consensus regarding the protocol treatment of wet AMD patients undergoing cataract surgery (Othenin-Girard et al. 1994; Chew et al. 2009; Kessel et al. 2014; Ylinen et al. 2018). A better understanding of the variables associated with macular anatomical and functional

response to treatment with anti-VEGF in wet AMD patients and to cataract surgery could improve preoperative planning and reduce the treatment burden. Here, we aim to investigate whether cataract surgery in wet AMD patients affects its course and the relationship to how it influences clinical outcomes.

Methods

Study design

This study was a registry-based retrospective cohort study of consecutive cataract surgeries performed on wet AMD patients at Helsinki University Hospital, Helsinki, Finland. The study was approved by the Helsinki and Uusimaa Hospital District (Research permission §42/2019; HUS/466/2019) and complied with the tenets of the Declaration of Helsinki.

The primary outcome of the study was to evaluate the change in CSMT after surgery and at 1 year. Secondary outcomes were the changes in visual acuity, anti-VEGF treatment interval, macular status between the preoperative phase and postoperatively and the correlation between the CSMT change and the cumulative number of anti-VEGF injections before surgery.

Data acquisition

The study included patients who underwent uncomplicated cataract surgery between January 2014 and December 2018 at Helsinki University Hospital. Data were collected from the operating room management system (BCB Medical, cataract database, Turku, Finland). 25,818 consecutive cases of uncomplicated cataract surgery were reviewed for registry. For inclusion, all patients were required to have documentation on the type of postoperative medical treatment received, systemic medication and anti-VEGF treatment for wet AMD prior to laterality matched uncomplicated cataract surgery.

Anti-VEGF treatment protocol

Helsinki University Hospital uses the fixed-treat-and-extend regimen (fixed-TER) anti-VEGF protocol for the treatment of wet AMD. Either bevacizumab 1.25mg (Avastin[®], Genentech,

Inc., South San Francisco, CA) or aflibercept 2mg (Eylea[®], 40mg/ml, Bayer Pharma AG, Leverkusen, Germany) was used as anti-VEGF drug according to the national current care guidelines for wet AMD (Tuuminen et al. 2017).

Patients received three monthly anti-VEGF injections at baseline, and the treatment interval was lengthened accordingly: three consecutive injections at 6-week interval, two consecutive injections at 8-week interval, one injection at 10-week interval and finally reaching the maximum 12-week interval. If the disease showed activation, the treatment intervals were shortened.

Cataract surgery

According to the Finnish national guidelines for cataract operations, the best-corrected visual acuity (BCVA) for cataract surgery is recommended to be 0.5/0.3 in the better/worse eye, respectively, or less by Snellen equivalents, except under some specific circumstances (Cataracts Current Care Guideline 2019). The surgical technique used in this study was phacoemulsification (Infinity[®]/Centurion[®] Vision System, Alcon Laboratories, Inc., Fort Worth, TX) with a 2.4–2.75 mm clear corneal incision. A single-piece acrylic monofocal IOL (Tecnis[®], Johnson & Johnson Surgical Vision Inc., Santa Ana, CA or AcrySof IQ[®], Alcon Laboratories, Inc.) was implanted into the capsular bag. During the study period, the single-piece monofocal Tecnis[®] was the IOL type used most (96.1%) (Hecht et al. 2020). None of the wet AMD patients underwent complicated cataract surgery.

Postoperative care

The choice of postoperative anti-inflammatory medication was at the discretion of the treating physician. Treatment was either with steroids (N = 22, 19.8%; Pred Forte[®], prednisolone acetate 10 mg/ml, Allergan, Inc. Irvine, CA, or Oftan Dexam[®], dexamethasone 1 mg/ml, Santen Oy, Tampere, Finland), NSAIDs (N = 80, 72.1%; Nevanac[®], nepafenac 1mg/ml or 3mg/ml, Novartis, Basel, Switzerland) or a combination of both (N = 9, 8.1%). The duration of the anti-inflammatory treatment was three weeks in all cases except for two in which the

surgeries were planned with four-week anti-inflammatory treatment. No subconjunctival or intracameral anti-inflammatory adjunct treatment was used.

Clinical evaluation

All patients underwent a comprehensive ophthalmic examination and optical coherence tomography (OCT) analysis. Foveal thickness, central subfield macular thickness (CSMT) defined as mean thickness in the central 1000 μm diameter area and maximum thickness in the central 1000 μm diameter area were recorded by spectral-domain OCT (SD-OCT, Heidelberg Eye Explorer Version 1.10.4.0 and HRA / SPECTRALIS® Viewing Module Version 6.13.3.0, Heidelberg Engineering GmbH, Heidelberg, Germany). Follow-up 30-frame SD-OCT scans were performed with AutoRescan™ software. The subtyping of wet AMD was done at the time of diagnosis with fluorescein angiography (FA) and/or indocyanine green angiography. Macular status on OCT scans of all cases was evaluated masked by a medical retina specialist (P.K.).

Visual acuity was examined using a standard Snellen chart with the best-corrected refraction and using decimal numbers. Best-corrected visual acuity (BCVA) decimal values were converted to logarithms of the minimum angle of resolution (logMAR) for statistical purposes. BCVA and OCT parameters were obtained at different time points, including: at the time of wet AMD diagnosis, and within 18 weeks before and after surgery depending on the timing of out-patient clinic visits according to our fixed-TER protocol and patients’ treatment intervals, that is anti-VEGF injections may have been given in between the surgery and the latest OCT scans.

Sample size calculation

For sample size calculations, the standard deviation of CSMT was set at 70 μm (according to previous studies ranging from 61 to 80 μm) (Berg et al. 2015; Achiron et al. 2021) with a minimal clinically significant difference of 10 μm in CSMT. Using a paired model, we found that a sample size of 98 patients was required to detect a significant difference between

measurements with a significance level of 0.05 and a power of 80%.

Statistics

Unless otherwise specified, data are presented as mean ± standard deviation (SD). Visual acuity decimal numbers were converted to logMAR units using the -log10 conversion method. In visual acuity testing, when the largest optotype could not be recognized correctly, the classification was very low VA on a semi-quantitative scale and was graded as counting fingers (CF) and hand motion (HM). Very low VA measurements were converted as follows: CF to 1.9 and HM to 2.3 logMAR units (Dong et al. 2003; Schulze-Bonsel et al. 2006). Statistical analysis was performed using IBM SPSS Statistics 25 (SPSS Inc., Chicago, IL). For two-group comparison, the chi-squared test was used for categorical variables, Student’s *t*-test was used for parametric variables and the Mann–Whitney *U*-test for non-parametric variables. The paired *t*-test was used to compare BCVA, CSMT and anti-VEGF treatment interval at different timepoints. For multiple group comparisons, the Fisher–Freeman–Halton test was used for qualitative data, the one-way ANOVA test using Bonferroni’s correction was used for continuous variables, and the Kruskal–Wallis test with Dunn’s correction for non-parametric variables. A multiple linear regression model was used to estimate the relationships between the preoperative CSMT, cumulative number of anti-VEGF injections, anti-VEGF treatment interval, macular status (presence of subretinal and intraretinal fluid) at cataract surgery and the CSMT change postoperatively. *p* < 0.05 was considered statistically significant.

Results

One hundred and eleven eyes of 111 patients (38 males and 73 females) with a mean age of 78.9 ± 5.6 years were included in the study (Table 1). On average, patients received 24.8 ± 17.3 intravitreal anti-VEGF injections before cataract surgery (Table 1). The time from last anti-VEGF injection to cataract surgery was 29.9 ± 27.6 days. The time from the last medical retina specialist visit to cataract surgery was

Table 1. Baseline variables at time cataract surgery timepoint.

	All (N = 111)
Gender (M:F)	38:73
Age (years)	78.9 ± 5.6
Laterality R:L	52:59
Diabetes	24
Medication (oral: insulin:combination)	18:3:3
PFX (N=)	17
Poor mydriasis	15
Glaucoma	4
No. anti-VEGF injections before surgery	24.8 ± 17.3
Wet AMD subtype	
Classic	16
Minimally classic	2
Occult	21
Polypoidal	7
RAP	7
Missing	58
Topical anti-inflammatory medication	
Steroid	22
NSAID	80
Steroid + NSAID	9
Systemic medication	
ACE/AT2	61
Beta-blockers	61
CCBs	37
Statins	59
Anti-thrombotic	28
Anti-coagulation	23
Nitrates	17

Data are given as mean ± SD or absolute numbers.

ACE = angiotensin-converting enzyme inhibitors, AT2 = angiotensin II receptor blockers, BCVA = best-corrected visual acuity, CCBs = calcium channel blockers, PFX = pseudoexfoliation syndrome.

56.8 ± 38.0 days, while the mean time from cataract surgery to the first postoperative medical retina specialist visit was 66.9 ± 44.2 days.

Baseline variables regarding relevant systemic and ocular comorbidities, wet AMD subtype, macular status at the time of cataract surgery and topical anti-inflammatory and systemic medications are presented in Table 1.

Macular status and visual acuity after cataract surgery in eyes with wet AMD

Cataract surgery did not significantly influence the incidence of haemorrhages, pigment epithelial detachment, intraretinal fluid or subretinal fluid when comparing macular status at surgery to that at first postoperative visit and at 1 year (Table 2). At the

Table 2. Macular status in wet AMD eyes.

	All (N = 111)			
	Baseline	At cataract surgery	Postoperatively	At 1-year
Haemorrhages	41 (37%)	2 (2%)	2 (2%)	1 (1%)
IRF	52 (47%)	33 (30%)	39 (35%)	29 (26%)
SRF	81 (73%)	32 (29%)	36 (32%)	28 (25%)
PED	57 (51%)	25 (23%)	26 (23%)	23 (21%)

Data are given as absolute numbers.

IRF = intraretinal fluid, PED = pigment epithelial detachment, SRF = subretinal fluid.

Table 3. Macular thickness and visual acuity in wet AMD eyes.

	All (N = 111)
BCVA (logMAR)	
at wAMD diagnosis	0.45 ± 0.34
at cataract surgery	0.70 ± 0.46
postoperatively	0.39 ± 0.40
at 1-year	0.33 ± 0.34
at last documented visit	0.44 ± 0.39
CSMT (µm)	
at wAMD diagnosis	356.3 ± 114.5
at cataract surgery	280.1 ± 75.0
postoperatively	268.6 ± 67.6
at 1-year	265.9 ± 67.9
at last documented visit	263.7 ± 64.0
Foveal thickness (µm)	
at wAMD diagnosis	323.2 ± 126.9
at cataract surgery	259.8 ± 103.5
postoperatively	228.6 ± 80.1
at 1-year	233.7 ± 79.8
at last documented visit	237.7 ± 78.3
Max thickness at 1-mm diameter area (µm)	
at wAMD diagnosis	448.6 ± 132.3
at cataract surgery	361.0 ± 88.7
postoperatively	347.5 ± 88.9
at 1-year	353.1 ± 97.6
at last documented visit	337.7 ± 74.3
Macular oedema relapse after cataract surgery	
Foveal thickness ≥30% postoperatively	3
CSMT ≥30% postoperatively	1
Max thickness ≥30% postoperatively	1
Anti-VEGF treatment intervals (weeks)	
at cataract surgery	6.53 ± 2.08
at 1-year	7.03 ± 2.23
at last documented visit	7.05 ± 2.57

Data are given as mean ± SD or absolute numbers.

CSMT = central subfield macular thickness, logMAR = logarithm of the minimum angle of resolution.

time of cataract surgery, CSMT was 280.1 ± 75.0 µm, with a postoperative CSMT of 268.6 ± 67.6 µm (p = 0.001, Table 3) and a 1-year CSMT of 265.9 ± 67.9 µm (p = 0.003, Table 3). The BCVA in logMAR units was 0.70 ± 0.46 (Snellen equivalent median and IQR; 0.30, 0.125–0.40) prior to cataract surgery, and improved to 0.39 ± 0.40 (Snellen equivalent median and IQR; 0.50, 0.32–0.80) postoperatively (p < 0.001, Table 3), and to 0.33 ± 0.34 (Snellen equivalent median

and IQR; 0.50, 0.32–0.80) at 1 year (p < 0.001, Table 3).

After cataract surgery, foveal thickness increased >30% (from preoperative values) in only three out of the 111 eyes (2.7%), a CSMT increase of >30% was found in one case (total incidence 0.9%) and a maximal macular thickness increase >30% in one case (total incidence 0.9%) (Table 3). Postoperatively, none of the patients lost BCVA of 0.2 Snellen decimals or more compared to preoperative values (data

not shown). At 1 year, two patients lost BCVA of 0.2 Snellen decimals or more compared to their preoperative values (data not shown). The anti-VEGF treatment interval was 6.53 ± 2.08 weeks prior to surgery, 7.03 ± 2.23 weeks at 1 year (p = 0.246, Table 3) and 7.05 ± 2.57 weeks at the last documented visit (p = 0.035, Table 3).

The CSMT change postoperatively inversely correlated with the CSMT level prior to surgery (i.e. the higher the macular thickness preoperatively the higher the CSMT resolution postoperatively, r = -0.483, p < 0.001, Fig. 1), but not with the cumulative number of anti-VEGF injections before surgery (r = -0.051, p = 0.691, Fig. 2). The CSMT change postoperatively or at 1 year did not correlate with patient age at surgery, nor with the preoperative BCVA (Table 4).

In a multiple regression analysis, significant baseline variables such as preoperative CSMT, cumulative number of anti-VEGF injections, anti-VEGF treatment interval and macular status (presence of subretinal and intraretinal fluid) at cataract surgery were analysed for CSMT change postoperatively. Central subfield macular thickness (CSMT) level prior to surgery significantly correlated with CSMT change postoperatively (B -0.311, 95% CI -0.431 to -0.190, p < 0.001), whereas the cumulative number of anti-VEGF injections (B -0.235, 95% CI -0.738 to 0.269, p = 0.356), anti-VEGF treatment interval (B -2.088, 95% CI -6.658 to 2.483, p = 0.366) and presence of subretinal (B -2.963, 95% CI -24.958 to 19.032, p = 0.789) and intraretinal fluid (B -4.041, 95% CI -21.836 to 13.754, p = 0.652) at cataract surgery did not.

Clinical outcomes after cataract surgery regarding different wet AMD subtypes and the presence of intraretinal or subretinal fluid during surgery are presented in Tables S1 and 5, respectively.

Effect of systemic drugs and topical anti-inflammatory medication on cataract surgery outcomes in eyes with wet AMD

To assess the influence of baseline factors such as existence and type of diabetes, anti-inflammatory drugs, use of anti-coagulants, calcium-channel blockers and statins on the study

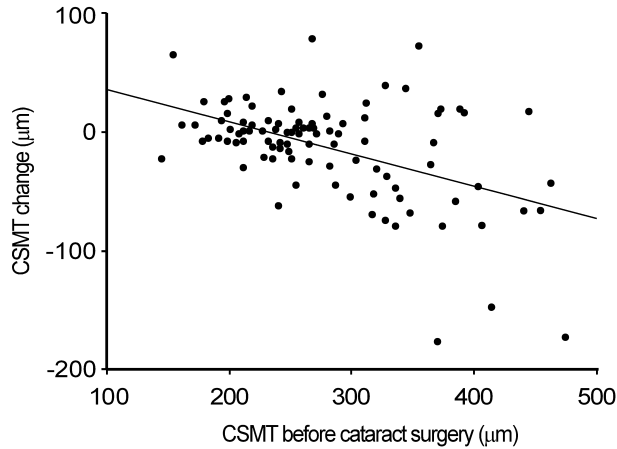


Fig. 1. Correlation between CSMT level prior to surgery and CSMT change postoperatively. $r = -0.483$, $p < 0.001$.

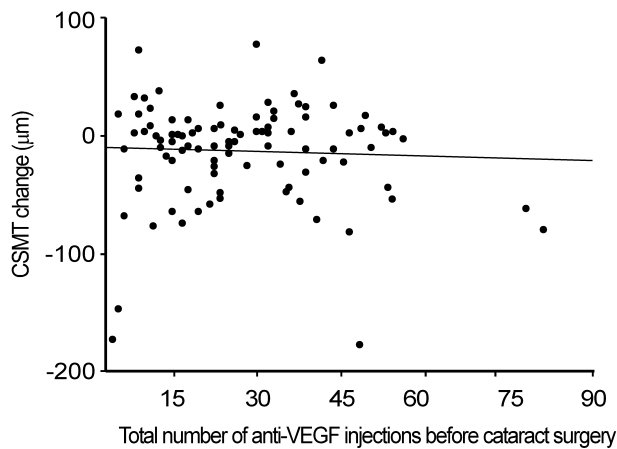


Fig. 2. Correlation between the cumulative number of anti-VEGF injections before the surgery and CSMT change postoperatively. $r = -0.051$, $p = 0.691$.

Table 4. Correlation between baseline variables and CSMT change.

	Postoperative CSMT change (µm)		At 1-year CSMT change (µm)	
	$r =$	$p =$	$r =$	$p =$
At cataract surgery				
Age (years)	0.002	0.983	-0.093	0.416
Cumulative no. of anti-VEGF injections	-0.051	0.619	0.091	0.426
BCVA (logMAR)	-0.060	0.564	-0.122	0.286
CSMT (µm)	-0.483	<0.001	-0.589	<0.001

BCVA = best-corrected visual acuity, CSMT = central subfield macular thickness, logMAR = logarithm of the minimum angle of resolution.

outcome, we repeated the multiple regression analysis while controlling for these baseline factors. Results remained consistent as only CSMT prior to surgery was significantly correlated with CSMT change postoperatively (B -0.109, 95% CI -0.203 to -0.014, $p = 0.025$), while number of

anti-VEGF injections (B 0.488, 95% CI -0.370 to 1.346, $p = 0.259$), anti-VEGF treatment interval (B 3.59, 95% CI -0.96 to 8.16, $p = 0.120$) and presence of subretinal (B 9.61, 95% CI -12.52 to 31.75, $p = 0.388$) or intraretinal fluid (B 7.54, 95% CI -10.12 to -27.10, $p = 0.418$) were not.

The effect of baseline factors was also examined independently for an association with clinical outcomes using a multiple regression analysis. Baseline factors included existence and type of diabetes, systemic drugs (anti-coagulants, calcium-channel blockers and statins) and topical anti-inflammatory medication along with age and gender, and were examined for association with CSMT change postoperatively or at 1 year and the anti-VEGF treatment burden after surgery. None of the baseline factors were associated with any clinical outcomes related to wet AMD first or 1-year postoperative visits, except for thinner CSMT at first postoperative visit in those taking statins (B -23.17, 95% CI -41.1 to -5.24, $p = 0.012$).

Discussion

In this retrospective registry-based study, we show that cataract surgery does not cause progression or worsening of wet AMD. Among the 111 eyes investigated only one eye showed an increase of over 30% in CSMT and in maximal macular thickness. The mean treatment interval of anti-VEGF injections did not change after surgery compared to the preoperative period. In addition, BCVA improved significantly up to 1 year after surgery.

Cataract and wet AMD often coexist, and both diminish visual function. Following cataract surgery, wet AMD can theoretically progress through one of two possible mechanisms: blue-light toxicity and surgically induced inflammation. Blue light has been shown in laboratory studies to affect retinal pigment cells (Noell et al. 1966; Ham et al. 1976; Grimm et al. 2001; Algvere et al. 2006) and is thought to have an *in vivo* negative effect on macular health (Sparrow et al. 2002). This led to the invention of blue-light filtering intraocular lenses (IOLs). In the present study, only non-blue-light filtering IOLs were implanted; nevertheless, we still could not show wet AMD progression after cataract surgery. Indeed, in a recent study by our group, non-blue-light filtering IOLs were ruled out as a possible explanation for wet AMD progression, as they were found equal to blue-light filtering IOLs in terms of the development and progression of wet AMD (Achiron et al. 2021).

Table 5. Subgroup analysis regarding macular status at cataract surgery.

	IRF – (N = 78)	IRF + (N = 33)	p-value
BCVA (logMAR)			
at wAMD diagnosis	0.43 ± 0.38	0.48 ± 0.26	0.078
before cataract surgery	0.72 ± 0.51	0.66 ± 0.32	0.834
postoperatively	0.38 ± 0.41	0.42 ± 0.38	0.339
at 1-year	0.32 ± 0.35	0.36 ± 0.31	0.399
at last documented visit	0.43 ± 0.40	0.49 ± 0.38	0.296
CSMT (µm)			
at wAMD diagnosis	359.0 ± 118.8	350.7 ± 106.9	0.739
before cataract surgery	273.1 ± 74.1	294.9 ± 76.0	0.191
postoperatively	260.1 ± 65.3	287.7 ± 69.8	0.067
at 1-year	258.2 ± 67.4	283.3 ± 67.1	0.127
at last documented visit	261.8 ± 63.4	268.4 ± 66.6	0.667
Anti-VEGF treatment interval (weeks)			
before cataract surgery	6.8 ± 2.2	6.0 ± 1.8	0.073
at 1-year	7.2 ± 2.4	6.5 ± 1.6	0.161
at last documented visit	7.4 ± 2.7	6.2 ± 1.9	0.043
	SRF – (N = 79)	SRF + (N = 32)	p-value
BCVA (logMAR)			
at wAMD diagnosis	0.43 ± 0.30	0.49 ± 0.43	0.759
before cataract surgery	0.75 ± 0.51	0.58 ± 0.27	0.222
postoperatively	0.39 ± 0.41	0.39 ± 0.39	0.889
at 1-year	0.36 ± 0.36	0.25 ± 0.24	0.226
at last documented visit	0.47 ± 0.40	0.39 ± 0.39	0.269
CSMT (µm)			
at wAMD diagnosis	353.6 ± 113.3	362.9 ± 119.3	0.732
before cataract surgery	266.3 ± 66.7	312.3 ± 84.3	0.012
postoperatively	260.6 ± 64.6	288.4 ± 71.8	0.076
at 1-year	269.5 ± 74.2	257.0 ± 49.9	0.379
at last documented visit	260.7 ± 60.7	271.2 ± 72.5	0.518
Anti-VEGF treatment interval (weeks)			
before cataract surgery	6.8 ± 2.0	5.7 ± 2.3	0.012
at 1-year	7.5 ± 2.1	6.0 ± 2.2	0.010
at last documented visit	7.5 ± 2.5	6.0 ± 2.4	0.010

Data are given as mean ± SD or absolute numbers. Data were analysed with the Student's *t*-test for continuous variables and with Mann–Whitney U-test for non-parametric variables. '+' sign represents the presence and '-' sign represents the absence of a factor in question. BCVA = best-corrected visual acuity, CSMT = central subfield macular thickness, IRF = intraretinal fluid, logMAR = logarithm of the minimum angle of resolution, SRF = subretinal fluid.

Regarding surgically induced inflammation, the stress to the eye with modern phacoemulsification technology is much less than with older methods such as intracapsular and extracapsular cataract extraction. Consequently, PCME and other intra- and postoperative complications are fewer with phacoemulsification surgery (de Silva et al. 2014). This has been partially attributed to the use of anti-inflammatory medications in the immediate postoperative period (Kessel et al. 2014; Hecht et al. 2020). For most patients in the present study, the postoperative anti-inflammatory treatment period after cataract surgery was three weeks. Neither topical anti-inflammatory medication administered during the postoperative period nor

the use of systemic medication was associated with macular status. The only significant measure found was that the thicker the CSMT at the time of surgery and the greater the extent of CSMT resolution postoperatively, the better was the BCVA gain. In the vast majority of patients, anti-inflammatory treatment was given three weeks after cataract surgery. Since events of wet AMD activation and clinically significant relapses were rare, we speculate that three weeks of anti-inflammatory medication is sufficient, regardless of the presence of wet AMD. Of note, the anti-inflammatory treatment and the incidences between NSAID, corticosteroids and their combination in wet AMD patients reflect the real-life of clinical practice,

recently studied by us in another article (Hecht et al. 2020).

We also evaluated the effect of type II diabetes mellitus on wet AMD progression and found no effect on BCVA, CSMT or the number of anti-VEGF injections after cataract operation. Moreover, in parallel with the age-related eye disease (AREDS) report (Al-Holou et al. 2015), statins were not associated with wet AMD progression in our study. Similarly, anticoagulation and other systemic medication such as CCB and beta-blockers were not associated with wet AMD progression either. Saraf et al. (2015) have evaluated the effect of cataract surgery on wet AMD progression in a case-control study. As in our study, they demonstrated no change in the number of anti-VEGF injections before and after cataract surgery. Interestingly, they reported an increase in the mean central thickness and worsening of foveal cysts during the 3 months after cataract surgery. They postulated that these OCT changes may be related to PCME occurrence in the early postoperative period. However, the OCT features were not followed beyond the 3-month postoperative period. Our data did not indicate worsening of OCT findings within the postoperative time points. Furthermore, OCT findings remained stable even after a longer period of follow-up of up to 1 year.

When considering clinically relevant parameters and the best proxy for wet AMD activity the clinical variables CSMT, visual acuity, macular status and anti-VEGF injection interval could be considered as candidates. Visual acuity and its gain during the postoperative phase is largely dependent on the baseline status of the macula and other comorbidities, rather than on wet AMD activity alone. Macular status (presence or absence of fluid) is a dichotomic variable that does not reflect the severity of the exudation. Anti-VEGF treatment interval is gradually changing towards a shorter or a longer time, and thus better reflects the long-term rather than the current activity of the disease. On the other hand, of the clinically relevant variables, CSMT change was considered to best correlate with the current wet AMD activity. Thus, CSMT change was selected as a primary outcome. Furthermore, we investigated which baseline variables

correlate with CSMT change postoperatively and at 1 year. We found a significant inverse correlation with baseline CSMT. These results can be interpreted to mean that the higher the CSMT at baseline, the greater the extent of CSMT resolution at the postoperative timepoints. Further, evidenced by the resolution of exudation regardless of cataract surgery, these results can be interpreted to indicate that the wet AMD activity and the large extent of exudation in wet AMD patients prior to cataract surgery do not indicate the need to postpone the surgery.

According to a recent survey, 12% of ophthalmic surgeons in the UK did not consider cataract surgery for wet AMD patients due to fear of disease activation (Malick et al. 2020). Other recent studies suggested postponing cataract surgery for up to 6 months from wet AMD diagnosis because of ongoing disease activity (Kessel et al. 2015; Kessel et al. 2016; Daien et al. 2018). On the other hand, some studies concluded that cataract surgery does not cause or worsen the course of wet AMD and that surgery may be performed at any time despite the presence of macular fluid detected by OCT (Wang et al. 2016; Ehmann & Ho 2017; Rim et al. 2017; Starr et al. 2018). A recent review concluded that even if cataract surgery does affect AMD, this hazard is of insignificant magnitude relative to the established role of ageing as an AMD risk factor (Ehmann & Ho 2017). This small risk would be far outweighed by the benefits of improved visual function and a better quality of life after surgery. Similarly, our study supports performing cataract surgery regardless of wet AMD activity when a potential improvement in visual acuity can be expected. Neither the macular status prior to surgery nor the cumulative number of anti-VEGF injections was associated with clinical outcomes postoperatively. Helsinki University Hospital has had no protocol to administer anti-VEGF just before or at the end of cataract surgery. Only two surgeries out of 111 were performed with concomitant anti-VEGF administration. In the light of our findings, it may be unnecessary to time anti-VEGF injection just before or at the same time as cataract surgery, but this is beyond the scope of this study

and deserves to be studied in a separate prospective trial.

A relatively small cohort size (N = 111) and the short follow-up time are the primary limitations of this study. Although 1 year of follow-up is relatively short, it is reasonably long enough to assess CSMT, visual acuity gain and anti-VEGF burden. Our study was also designed to address the question of whether postoperative management of cataract surgery should be standardized or tailored individually in wet AMD. We found that the incidence of a clinically significant CSMT increase (0.9%) as defined by a 30% CSMT increase was comparable to that previously reported among cataract surgery patients without known risk factors for PCME (1.17%) (Chu et al. 2016). Furthermore, a postoperative trend towards a CSMT decrease was achieved in wet AMD patients, even after cataract surgery regardless of disease activity. The anatomical and functional outcomes of surgery were not dependent on anti-VEGF treatment status or activity of wet AMD. Neither topical anti-inflammatory drug selection nor systemic medication was associated with positive the long-term outcome of cataract surgery. In addition, previous studies have shown that wet AMD patients' motor function and vision-related quality of life both improve after cataract surgery (Taipale et al. 2020). On the other hand, postponing cataract surgery due to coexisting wet AMD may adversely affect health-related quality of life (Porela-Tiihonen et al. 2016) and can be an obstacle to treatment due to poor retinal visibility (Loriaut et al. 2014). Another limitation of this study is that the time between pre- and postoperative out-patient visits and cataract surgery was not standardized because of the retrospective setting, which means that the macular oedema may fluctuate depending on the cataract surgery and treatment intervals. On the other hand, use of just a single standardized timepoint, such as a postoperative visit four weeks after surgery, would lack the information on macular status just before the next anti-VEGF administration. In TER protocol all out-patient visits were predetermined based on the disease activity and the current treatment interval. Thus, we find that the macular

status at the predetermined out-patient visit is of clinical interest.

We conclude that timing of cataract surgery in wet AMD patients should be adjusted according to patients' needs. We found no justification to support delaying surgery until dry macula has been achieved. Surgery should, therefore, not be postponed for these considerations in patients who require it.

References

- Achiron A, Elbaz U, Hecht I, Spierer O, Einan-Lifshitz A, Karesvuo P, Laine I & Tuuminen R. (2021): The effect of blue-light filtering intraocular lenses on the development and progression of neovascular age-related macular degeneration. *Ophthalmology* **128**: 410–416.
- Algvere PV, Marshall J & Seregard S (2006): Age-related maculopathy and the impact of blue light hazard. *Acta Ophthalmol Scand* **84**: 4–15.
- Al-Holou SN, Tucker WR, Agrón E, Clemons TE, Cukras C, Ferris FL 3rd & Chew EY (2015): The association of statin use with age-related macular degeneration progression: the age-related eye disease study 2 report number 9. *Ophthalmology* **122**: 2490–2496.
- Berg K, Pedersen TR, Sandvik L & Bragadóttir R (2015): Comparison of ranibizumab and bevacizumab for neovascular age-related macular degeneration according to LUCAS treat-and-extend protocol. *Ophthalmology* **122**: 146–152.
- Cataracts Current Care Guideline: the Finnish Medical Society Duodecim 2019 www.kaypa.hoitto.fi/web/kh/suosituksset/suositus?id=hoi50035#s9 [In Finnish].
- Chew EY, Sperduto RD, Milton RC et al. (2009): Risk of advanced age-related macular degeneration after cataract surgery in the Age-Related Eye Disease Study: AREDS report 25. *Ophthalmology* **116**: 297–303.
- Chu CJ, Johnston RL, Buscombe C, Sallam AB, Mohamed Q, Yang YC & United Kingdom Pseudophakic Macular Edema Study Group (2016): Risk Factors and Incidence of Macular Edema after Cataract Surgery: A Database Study of 81984 Eyes. *Ophthalmology* **123**: 316–323.
- Cugati S, Mitchell P, Rochtchina E, Tan AG, Smith W & Wang JJ (2006): Cataract surgery and the 10-year incidence of age-related maculopathy: the Blue Mountains Eye Study. *Ophthalmology* **113**: 2020–2025.
- Daien V, Nguyen V, Morlet N et al. (2018): Outcomes and predictive factors after cataract surgery in patients with neovascular age-related macular degeneration. The fight retinal blindness! Project. *Am J Ophthalmol* **190**: 50–57.
- Danni R, Taipale C, Holmström EJ, Ilveskoski L & Tuuminen R (2019): Systemic use

- of calcium channel blockers associated with less increase in central retinal thickness after uncomplicated cataract surgery. *Acta Ophthalmol* **97**: 178–184.
- de Silva SR, Riaz Y & Evans JR. (2014): Phacoemulsification with posterior chamber intraocular lens versus extracapsular cataract extraction (ECCE) with posterior chamber intraocular lens for age-related cataract. *Cochrane Database Syst Rev* **29**: CD008812.
- Dong LM, Marsh MJ & Hawkins BS (2003): Measurement and analysis of visual acuity in multicenter randomized clinical trials in the United States: findings from a survey. *Ophthalm Epidemiol* **10**: 149–165.
- Ehmann DS & Ho AC (2017): Cataract surgery and age-related macular degeneration. *Curr Opin Ophthalmol* **28**: 58–62.
- Flaxman SR, Bourne RRA, Resnikoff S et al. (2017): Global causes of blindness and distance vision impairment 1990–2020: a systematic review and meta-analysis. *Lancet Global Health* **5**: e1221–e1234.
- Grimm C, Wenzel A, Williams T, Rol P, Hafezi F & Remé C (2001): Rhodopsin-mediated blue-light damage to the rat retina: effect of photoreversal of bleaching. *Invest Ophthalmol Vis Sci* **42**: 497–505.
- Ham WT Jr, Mueller HA & Sliney DH (1976): Retinal sensitivity to damage from short wavelength light. *Nature* **260**: 153–155.
- Hecht I, Karesvuo P, Achiron A, Elbaz U, Laine I & Tuuminen R (2020): Anti-inflammatory Medication After Cataract Surgery and Posterior Capsular Opacification. *Am J Ophthalmol* **215**: 104–111.
- Heesterbeek TJ, Lorés-Motta L, Hoyng CB, Lechanteur YTE & den Hollander AI (2020): Risk factors for progression of age-related macular degeneration. *Ophthalm Physiol Optics* **40**: 140–170.
- Ho L, Boekhoorn SS, van Liana CM, Duijn AGU, Hofman A, de Jong PT, Stijnen T & Vingerling JR (2008): Cataract surgery and the risk of aging macula disorder: the rotterdam study. *Invest Ophthalmol Vis Sci* **49**: 4795–4800.
- Kessel L, Erngaard D, Flesner P, Andresen J, Tendal B & Hjortdal J (2015): Cataract surgery and age-related macular degeneration. An evidence-based update. *Acta Ophthalmol* **93**: 593–600.
- Kessel L, Koefoed Theil P, Lykke Sørensen T & Munch IC (2016): Cataract surgery in patients with neovascular age-related macular degeneration. *Acta Ophthalmol* **94**: 755–760.
- Kessel L, Tendal B, Jorgensen KJ, Erngaard D, Flesner P, Andresen JL & Hjortdal J (2014): Post-cataract prevention of inflammation and macular edema by steroid and nonsteroidal anti-inflammatory eye drops: a systematic review. *Ophthalmology* **121**: 1915–1924.
- Loriaut P, Loriaut P, Boyer P, Massin P & Cochereau I (2014): Visual impairment and hip fractures: a case-control study in elderly patients. *Ophthalm Res* **52**: 212–216.
- Malick H, Din N, Rajput R & Mushtaq B (2020): Cataract surgery in patients with neovascular age related macular degeneration—examination of current practice among UK ophthalmic surgeons. *Eye* **35**: 685–686.
- Mitchell P, Liew G, Gopinath B & Wong TY (2018): Age-related macular degeneration. *Lancet (London, England)* **392**: 1147–1159.
- Noell WK, Walker VS, Kang BS & Berman S (1966): Retinal damage by light in rats. *Invest Ophthalmol* **5**: 450–473.
- Othenin-Girard P, Tritten JJ, Pittet N & Herbort CP (1994): Dexamethasone versus diclofenac sodium eyedrops to treat inflammation after cataract surgery. *J Cataract Refract Surg* **20**: 9–12.
- Porela-Tiihonen S, Roine RP, Sintonen H, Kaarniranta K, Kokki M & Kokki H (2016): Health-related quality of life after cataract surgery with the phacoemulsification technique and intraocular lens implantation. *Acta Ophthalmol* **94**: 21–25.
- Rim TH, Lee CS, Lee SC, Kim S & Kim SS (2017): Association between previous cataract surgery and age-related macular degeneration. *Semin Ophthalmol* **32**: 466–473.
- Saraf SS, Ryu CL & Ober MD (2015): The effects of cataract surgery on patients with wet macular degeneration. *Am J Ophthalmol* **160**: 487–492.e481.
- Schulze-Bonsel K, Feltgen N, Burau H, Hansen L & Bach M (2006): Visual acuities "hand motion" and "counting fingers" can be quantified with the Freiburg visual acuity test. *Invest Ophthalmol Vis Sci* **47**: 1236–1240.
- Small KW, Garabetian CA & Shaya FS (2017): Macular degeneration and aspirin use. *Retina* **37**: 1630–1635.
- Sparrow JR, Zhou J, Ben-Shabat S, Vollmer H, Itagaki Y & Nakanishi K (2002): Involvement of oxidative mechanisms in blue-light-induced damage to A2E-laden RPE. *Invest Ophthalmol Vis Sci* **43**: 1222–1227.
- Starr MR, Mahr MA, Barkmeier AJ, Iezzi R, Smith WM & Bakri SJ (2018): Outcomes of cataract surgery in patients with exudative age-related macular degeneration and macular fluid. *Am J Ophthalmol* **192**: 91–97.
- Taipale C, Grzybowski A & Tuuminen R (2020): Effect of cataract surgery on quality of life for patients with severe vision impairment due to age-related macular degeneration. *Ann Transl Med* **8**: 1543.
- Tuuminen R, Tuulonen A & Kaarniranta K (2017): The Finnish national guideline for diagnosis, treatment and follow-up of patients with wet age-related macular degeneration. *Acta Ophthalmol* **95**: 649–650.
- Wang JJ, Fong CS, Burlutsky G et al. (2016): Risk of age-related macular degeneration 4 to 5 years after cataract surgery. *Ophthalmology* **123**: 1829–1830.e1821.
- Wong WL, Su X, Li X, Cheung CM, Klein R, Cheng CY & Wong TY (2014): Global prevalence of age-related macular degeneration and disease burden projection for 2020 and 2040: a systematic review and meta-analysis. *Lancet Global Health* **2**: e106–116.
- Ylinen P, Holmström E, Laine I, Lindholm JM & Tuuminen R (2018): Anti-inflammatory medication following cataract surgery: a randomized trial between preservative-free dexamethasone, diclofenac and their combination. *Acta Ophthalmol* **96**: 486–493.

Received on September 23rd, 2020.

Accepted on March 16th, 2021.

Correspondence:

Raimo Tuuminen MD, PhD, FEBO
Kymenlaakso Central Hospital
Department of Ophthalmology
Kotkantie 41
FI-48210 Kotka
Finland
Phone: +358 50 411 3870
Fax: +358 9 2411 227
Email: raimo.tuuminen@helsinki.fi

†Equal contribution.

The authors have neither proprietary nor commercial interests in any medications or materials discussed in this study.

This study was supported by grants from the Finnish Eye Foundation, the Finnish Ophthalmological Society, the Nissi Foundation, Orion Research Foundation, the Mary and Georg C. Ehrnrooth foundation, Sokeain Ystävät ry, the Paulo Foundation, the Waldemar von Frenckell Foundation and HUS Specific Catchment Area (ERVA) Clinical Research Grants.

Supporting Information

Additional Supporting Information may be found in the online version of this article:

Table S1. Subgroup analysis regarding wet AMD subtype.