




## BRIEF REPORT

# Genome-wide analysis of acute leukemia and clonally related histiocytic sarcoma in a series of three pediatric patients

Matthias Bleeke<sup>1</sup>  | Pascal Johann<sup>2,3,4</sup> | Susanne Gröbner<sup>2,3</sup> | Julia Alten<sup>5</sup> |  
 Gunnar Cario<sup>5</sup>  | Hansjörg Schäfer<sup>6</sup> | Wolfram Klapper<sup>7</sup> | Joseph Houry<sup>8</sup> |  
 Stefan Pfister<sup>2,3,4</sup> | Ingo Müller<sup>1</sup> 

<sup>1</sup>Division of Pediatric Stem Cell Transplant and Immunology, University Medical Center Hamburg-Eppendorf, Hamburg, Germany

<sup>2</sup>Hopp Children's Cancer Center at the NCT Heidelberg (KiTZ), Heidelberg, Germany

<sup>3</sup>Division of Pediatric Neurooncology, German Cancer Consortium (DKTK) and German Cancer Research Center (DKFZ), Heidelberg, Germany

<sup>4</sup>Department of Pediatric Hematology and Oncology, Heidelberg University Hospital, Heidelberg, Germany

<sup>5</sup>Department of Pediatrics, University Medical Center Schleswig-Holstein, Campus Kiel, Germany

<sup>6</sup>Institute of Pathology, University Medical Center Hamburg-Eppendorf, Hamburg, Germany

<sup>7</sup>Institute of Pathology, University Medical Center Schleswig-Holstein, Campus Kiel, Germany

<sup>8</sup>Department of Hematopathology, MD Anderson Cancer Center, Houston, Texas

## Correspondence

Matthias Bleeke, Division of Pediatric Stem Cell Transplant and Immunology, University Medical Center Hamburg-Eppendorf, Martinistrasse 52, 20245 Hamburg, Germany  
 Email: m.bleeke@uke.de

Matthias Bleeke and Pascal Johann contributed equally to this work.

## Abstract

Pediatric histiocytic sarcoma (HS) clonally related to antecedent leukemia is a rare malignancy with poor outcome. We performed a molecular characterization of HS and the corresponding leukemia by methylation arrays and whole-exome sequencing and found a variety of aberrations in both entities with deletions of *CDKN2A/B* as a recurrent finding. Furthermore, data from genome-wide mutation analysis from one patient allowed the reconstruction of a sequence of tumorigenesis of leukemia and HS lesions including the acquisition of a putatively activating *KRAS* frameshift deletion (p.A66fs). Our results provide an insight into the genetic landscape of pediatric HS clonally related to antecedent leukemia.

## KEYWORDS

histiocytic sarcoma, leukemia, pediatric oncology

## 1 | INTRODUCTION

Histiocytic sarcoma (HS) is a rare malignancy in adult and pediatric patients characterized by aggressive growth and poor response to conventional chemotherapy. HS tumors display morphological and immunohistochemical characteristics of histiocytic differentiation, including expression of CD68, CD163, or lysozyme. Several case reports describe HS arising as a secondary neoplasm after leukemia or lymphoma with proof of clonal relationship between both malignancies by detection of specific T-cell receptor (TCR) or immunoglobulin heavy

chain (IgH) rearrangements.<sup>1-3</sup> Clonal IgH rearrangements were also found in a significant subset of sporadic HS tumors suggesting a lymphoid progenitor,<sup>4</sup> but knowledge about genetic alterations in HS related to lymphoid neoplasms beyond IgH or TCR rearrangements is scarce. Recent studies have identified several oncogenic aberrations in HS from mostly adult patients including *BRAFp.V600E*,<sup>5</sup> *KMT2D/MLL2* mutations,<sup>6</sup> and cyclin-dependent kinase inhibitor 2A (*CDKN2A*) deletions,<sup>2</sup> indicating that a comprehensive genetic evaluation of HS might help identifying pathophysiologically relevant mutations and druggable targets. Furthermore, a comparative analysis of leukemias

Abbreviations: HS, histiocytic sarcoma; IgH, immunoglobulin heavy chain; MRD, Minimal residual disease; TCR, T-cell receptor; WES, whole-exome sequencing.

This is an open access article under the terms of the Creative Commons Attribution-NonCommercial License, which permits use, distribution and reproduction in any medium, provided the original work is properly cited and is not used for commercial purposes.

© 2019 The Authors. *Pediatric Blood & Cancer* Published by Wiley Periodicals, Inc.

**TABLE 1** Locations of copy number aberrations in leukemia and respective HS as determined by copy number data derived from 850K arrays

Leukemia	Histiocytic sarcoma
Patient 1 Unique to one entity	
Loss Chr 7q: 104 958 385-153 199 381	Gain Chr 7p,q: 1-58 072 668
Loss Chr 9q: 77 415 221-126 234 720	Gain Chr 7q: 61 923 421-119 895 361
Loss Chr 15q: 23 472 366-67 048 206	Gain Chr 9q: 13 395 102-141 156 693
Gain Chr 21q: 22 314 227-27 226 053	Gain Chr 12p,q: 1-5 521 390
	Loss 21q: 11 912 696-47 717 353
Shared	
Loss Chr 9p: 20 586 271-23 849 732	Loss Chr 9p: 20 586 271-23 849 732
Loss Chr 14q: 106 371 892-106 937 395	Loss Chr 14q: 106 371 892-106 937 395
Loss Chr 12p: 11 670 214-14 179 936	Loss Chr 12p: 11 670 214-14 179 936
Gain Chr X: Whole chromosome	Gain Chr X: Whole chromosome
Patient 2 Unique to one entity	
Loss 14q: 22 352 674-23 185 588	Loss Chr 8q: 136 419 111-139 842 983
	Loss Chr 16q: 86 054 836-88 571 860
Shared	
Loss Chr 9p: 21 992 296-23 793 711	Loss Chr 9p: 21 992 296-23 793 711
Patient 3 Shared	
Loss Chr 9p: 21 372 878-32 359 000	Loss Chr 9p: 21 372 878-32 359 000
Loss Chr 14q: 22 275 031-23 003 474	Loss Chr 14q: 22 275 031-23 003 474

Gains and losses were scored visually using a threshold of  $\pm 0.2$  as cut-off values. While some aberrations were found in leukemia as well as HS in one patient (shared), there were distinct aberrations exclusively found in either leukemia or HS.

and HS with proof of clonal relation would help to understand the mode of relationship between these two diseases.

## 2 | RESULTS

### 2.1 | Patient histories

Patient 1 presented with biphenotypic/bilineal acute leukemia at the age of 11 years with two distinct blast populations each coexpressing immunophenotypic markers of myeloid and B-cell lineages. Five months after diagnosis of leukemia HS infiltrating the spleen, and in the further course also the liver, was diagnosed (Figure S1). Both, leukemic and histiocytic cells, showed a homozygous deletion of *CDKN2A* indicating a clonal relationship between the two diseases. Patients 2 and 3 have previously been reported.<sup>2</sup> Briefly, both developed HS 12 and 15 months after the diagnosis of T lymphoblastic leukemia. Clonal rela-

tionship of leukemia and HS was confirmed by specific TCR rearrangements as well as deletions in *CDKN2A*. All three patients died due to progressive HS.

### 2.2 | Methylation analysis and whole-exome sequencing

Experimental procedures are described in Supporting Information.

As expected, the methylation profiles showed a high degree of similarity between antecedent leukemia and histiocytic sarcoma with several overlapping gains and losses. However, in patients 1 and 2 some aberrations were only detected in either leukemia or HS (Table 1).

In addition to methylation arrays, we performed whole-exome sequencing (WES) and low coverage whole genome sequencing of leukemic cells and HS lesions from patient 1 (Table S1). The identified mutations provide information on the degree of similarity between leukemia and HS (Table S2). As expected, leukemia, hepatic, and splenic HS metastases share a proportion of insertion/deletions (INDELs) and single nucleotide variants (SNVs) but also display unique aberrations allowing us to model the sequence of tumorigenesis in this patient (Figure 1).

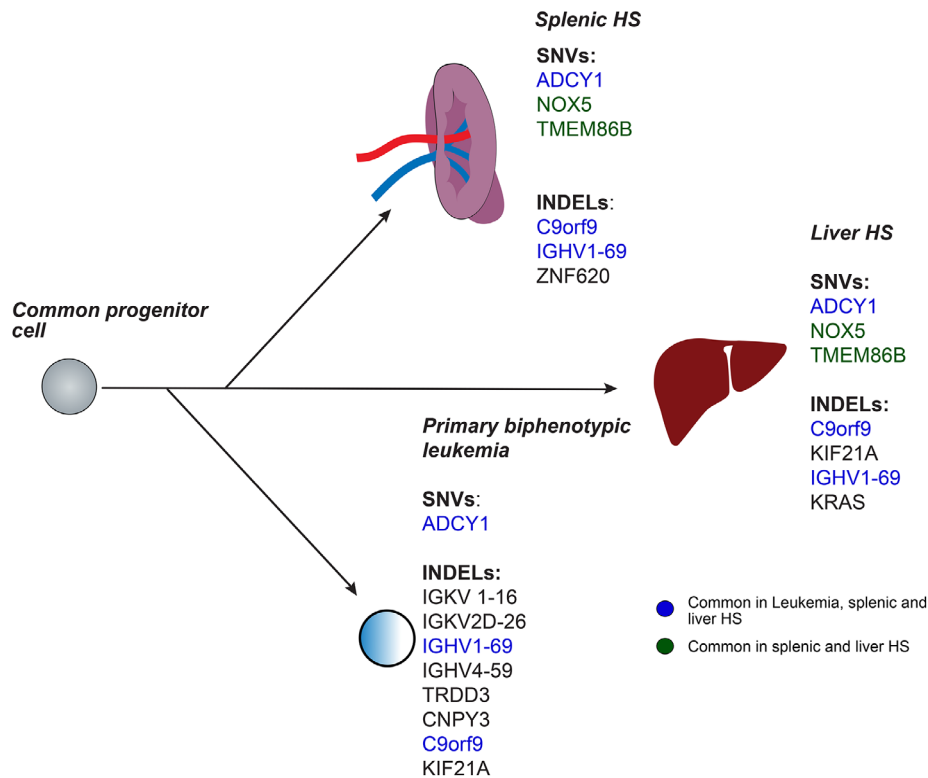
Adding to the notion that HS acquire genetic alterations in a site-specific way, we found a *KRAS* frameshift insertion (p.A66fs) affecting exon 3 of the gene and thus the RAS-domain only in the hepatic HS lesion. The same aberration was not present in the initial leukemia or the splenic HS and represents the only mutation of a bona fide oncogene found in all three samples.

## 3 | DISCUSSION

While a relationship between HS and leukemia has been widely suggested in the literature, the precise degree as to which the genomic profiles of these malignancies overlap remains largely elusive.

Different types of relationship have been hypothesized: (1) direct trans-differentiation, for example by genetic or epigenetic events, leading to a change in the phenotype of the affected cell, (2) de-differentiation of a lymphoid lineage committed cell to the level of a pluripotent hematopoietic stem cell and subsequent re-differentiation into histiocytic lineage, and (3) separate development of both malignant cell clones from a common progenitor. Interestingly, the sequence of lymphoid neoplasm and subsequent HS seems to be defined, given that there is no report about HS antecedent a clonally related lymphoid neoplasm.

Copy number profiles of leukemia and the respective HS analyzed in this small cohort showed a high degree of concordance. However, in two of three patients we found aberrations in the leukemic cells that were not present in the respective HS (Table 1). Supposing that genomic aberrations would be conserved through a process of trans-differentiation, these findings indicate that leukemia and HS derive from a common progenitor. This is in line with a previously reported observation in an adult patient with multiple relapses of follicular lymphoma and eventually clonally related HS. Each relapse showed



**FIGURE 1** Relationship of biphenotypic leukemia and two distinct HS metastases from patient 1 by SNV and INDELs from whole-exome sequencing. Derived from a hypothetical common progenitor leukemia and HS lesions develop independently showing a specific set of genetic aberrations. Common clonal origin is proved by aberrations found in all three sites (printed blue) and only in HS (printed green)

a specific pattern of genomic aberrations while none of these were detectable in the HS.<sup>3</sup>

The only recurrent high-level alterations detected by methylation array profiling were *CDKN2A* deletions. *CDKN2A* plays an important role in cell cycle control by inhibition of cyclin-dependent kinases 4 and 6 (CDK4/6). Alterations of *CDKN2A* can be found in multiple malignant diseases probably contributing to genetic instability. In pediatric acute lymphoblastic leukemia deletions of *CDKN2A* are found in up to 30% of cases and are associated with inferior response to treatment and increased risk of relapse.<sup>7</sup> In a recently published analysis of 28 patients—mainly adult—cases of HS *CDKN2A* was the most frequently affected single gene with alterations identified in 46% of all cases.<sup>8</sup> The same study reported MAPK pathway alterations in 59% of cases. We also detected a frameshift insertion affecting the switch 2 domain of *KRAS* (p.A66fs) in the hepatic HS lesion from patient 1. Previously reported frameshift mutations affecting the same site were proven to be oncogenic by conferring resistance to hydrolytic inhibition of *KRAS*. In vitro insertion mutations of *KRAS* at position A66 thus resulted in elevated MAPK signaling and abnormal cell growth, but with sensitivity to MEK inhibition.<sup>9</sup>

Given the aggressive course of HS in the majority of patients with resistance to conventional chemotherapy, the addition of molecular targeted therapies seems to be a promising approach for patient treatment. Several case reports describe responses to treatment with MEK inhibitors trametinib and cobimetinib in patients with HS harboring MAPK pathway alterations.<sup>10,11</sup> Another molecular tar-

geted approach could be the application of CDK4/6 inhibitors, since *CDKN2A* alterations seem to be the most frequent genetic alteration in HS.

It is however noteworthy that we found a potentially oncogenic *KRAS* mutation only in the hepatic and not in the splenic infiltrates of HS or the initial leukemia in the reported patient 1. Thus, genetic heterogeneity of different HS lesions in one patient has to be taken into account and biopsying multiple sites in one patient should be considered when molecular targeted therapies are planned.

In summary, HS clonally related to an antecedent leukemia is a very rare condition in pediatric oncology. The finding of genetic alterations unique to HS or antecedent leukemia rather indicates development of HS from a common progenitor than by a process of true trans-differentiation. Given the rareness of HS in pediatric patients, further collaborative efforts are needed to expand our view on the genetic landscape of this disease as a basis for improved therapies for this highly malignant cancer.

## CONFLICT OF INTEREST

The authors declare that there is no conflict of interest.

## ORCID

Matthias Bleeke  <https://orcid.org/0000-0003-0455-8338>

Gunnar Cario  <https://orcid.org/0000-0001-8396-0127>

Ingo Müller  <https://orcid.org/0000-0002-7477-6632>

## REFERENCES

1. Feldman AL, Minniti C, Santi M, et al. Histiocytic sarcoma after acute lymphoblastic leukaemia: a common clonal origin. *Lancet Oncol*. 2004;5(4):248-250.
2. Alten J, Klapper W, Leuschner I, et al. Secondary histiocytic sarcoma may cause apparent persistence or recurrence of minimal residual disease in childhood acute lymphoblastic leukemia. *Pediatr Blood Cancer*. 2015;62(9):1656-1660.
3. Brunner P, Ruffe A, Dirnhofer S, et al. Follicular lymphoma transformation into histiocytic sarcoma: indications for a common neoplastic progenitor. *Leukemia*. 2014;28(9):1937-1940.
4. Chen W, Lau SK, Fong D, et al. High frequency of clonal immunoglobulin receptor gene rearrangements in sporadic histiocytic/dendritic cell sarcomas. *Am J Surg Pathol*. 2009;33(6):863-873.
5. Michonneau D, Kaltenbach S, Derrieux C, et al. BRAF(V600E) mutation in a histiocytic sarcoma arising from hairy cell leukemia. *J Clin Oncol*. 2014;32(35):e117-21.
6. Hung YP, Lovitch SB, Qian X. Histiocytic sarcoma: new insights into FNA cytology and molecular characteristics. *Cancer Cytopathol*. 2017;125(8):604-614.
7. Braun M, Pastoczak A, Fendler W, et al. Biallelic loss of CDKN2A is associated with poor response to treatment in pediatric acute lymphoblastic leukemia. *Leuk Lymphoma*. 2017;58(5):1162-1171.
8. Shanmugam V, Griffin GK, Jacobsen ED, et al. Identification of diverse activating mutations of the RAS-MAPK pathway in histiocytic sarcoma. *Mod Pathol*. 2019;32:830-843.
9. White Y, Bagchi A, Van Ziffle J, et al. KRAS insertion mutations are oncogenic and exhibit distinct functional properties. *Nat Commun*. 2016;7:10647.
10. Kumamoto T, Aoki Y, Sonoda T, et al. A case of recurrent histiocytic sarcoma with MAP2K1 pathogenic variant treated with the MEK inhibitor trametinib. *Int J Hematol*. 2019;109(2):228-232.
11. Gounder MM, Solit DB, Tap WD. Trametinib in histiocytic sarcoma with an activating MAP2K1 (MEK1) mutation. *N Engl J Med*. 2018;378(20):1945-1947.

## SUPPORTING INFORMATION

Additional supporting information may be found online in the Supporting Information section at the end of the article.

**How to cite this article:** Bleeke M, Johann P, Gröbner S, et al. Genome wide analysis of acute leukemia and clonally related histiocytic sarcoma in a series of three pediatric patients. *Pediatr Blood Cancer*. 2020;67:e28074. <https://doi.org/10.1002/pbc.28074>