

# Multimodal imaging comparison of perifoveal exudative vascular anomalous complex and resembling lesions

Lisette M. Smid,<sup>1</sup> Jennifer S. N. Verhoekx,<sup>2</sup> José P. Martinez Ciriano,<sup>2</sup> Koenraad A. Vermeer<sup>1</sup> and Suzanne Yzer<sup>2</sup>

<sup>1</sup>Rotterdam Ophthalmic Institute, Rotterdam, The Netherlands

<sup>2</sup>Medical Retina Service, Rotterdam Eye Hospital, Rotterdam, The Netherlands

## ABSTRACT.

**Purpose:** Perifoveal exudative vascular anomalous complex (PEVAC) was initially described as an isolated aneurysmal lesion in healthy eyes. Similar aneurysmal abnormalities may occur in association with retinal vascular diseases such as diabetic retinopathy or retinal vein occlusions (PEVAC-resembling). The aim of this study was to compare several imaging characteristics of PEVAC and PEVAC-resembling lesions.

**Methods:** Ten eyes with a PEVAC and 27 eyes with a PEVAC-resembling lesion were included in this cross-sectional study. They were all imaged with optical coherence tomography (OCT), OCT angiography (OCT-A) and colour fundus photography (CFP). Several clinical, morphological and vascular characteristics were assessed and compared between both PEVAC types.

**Results:** All PEVAC lesions were unilateral, while PEVAC-resembling lesions appeared bilateral in 23% of patients ( $p > 0.05$ ). Unilateral multifocal PEVAC-resembling lesions were more frequently observed (56%) than unilateral multifocal PEVAC lesions (10%,  $p < 0.01$ ). Furthermore, 90% of the PEVAC lesions were located within 500  $\mu\text{m}$  from the centre of the fovea, while this was only true for 56% of the PEVAC-resembling lesions ( $p > 0.05$ ). No notable differences were observed in other studied characteristics.

**Conclusions:** The clinical, morphological and vascular features of PEVAC and PEVAC-resembling lesions are similar based on multimodal imaging. Given the bilaterality and multifocality seen in PEVAC-resembling lesions, an underlying retinal vascular disease may stimulate the quantity of aneurysmal abnormalities. Due to the similarities with PEVAC-resembling lesions, PEVAC may also be considered a microangiopathy but with an unknown origin.

**Key words:** aneurysm – clinical – imaging – morphological – perifoveal exudative vascular anomalous complex – PEVAC-resembling – retinal – vascular

Acta Ophthalmol. 2021; 99: 553–558

© 2020 The Authors. Acta Ophthalmologica published by John Wiley & Sons Ltd on behalf of Acta Ophthalmologica Scandinavica Foundation

This is an open access article under the terms of the Creative Commons Attribution-NonCommercial-NoDerivs License, which permits use and distribution in any medium, provided the original work is properly cited, the use is non-commercial and no modifications or adaptations are made.

doi: 10.1111/aos.14650

## Introduction

Perifoveal exudative vascular anomalous complex (PEVAC) is recently described as a large isolated perifoveal unilateral aneurysmal abnormality in subjects without underlying retinal vascular or ocular inflammatory pathologies (Querques et al. 2011; Sacconi et al. 2017; Mrejen-Uretsky et al. 2018; Kim et al. 2019). However, Fernandez-Vigo et al. (2020) described an atypical case that presented with multiple PEVAC lesions, both bilateral and multifocal. PEVAC is often associated with intraretinal cystoid spaces, haemorrhages and/or hard exudates, and appears on optical coherence tomography (OCT) as a round or oval lesion with hyperreflective surroundings (Mrejen-Uretsky et al. 2018; Kim et al. 2019; Venkatesh et al. 2019). A focal hyperreflective lumen is present on OCT angiography (OCT-A) in either the superficial vascular complex (SVC), the deep vascular complex (DVC) or both (Sacconi et al. 2017; Mrejen-Uretsky et al. 2018). As illustrated by our recent paper that described 21 PEVAC cases from a single centre (Verhoekx et al. 2020), this perifoveal abnormality may be more prevalent than previously assumed.

Aneurysmal abnormalities are commonly present in retinal vascular diseases, such as diabetic retinopathy (DR) or retinal veno-occlusive diseases,

and may be accompanied by cystoid macular oedema and intraretinal exudation, occasionally having a PEVAC-resembling appearance (Bourhis et al. 2010; Wiley & Ferris 2013; Spaide & Barquet 2018). Although these patients were excluded in the first papers on PEVAC (Querques et al. 2011; Sacconi et al. 2017; Mrejen-Uretsky et al. 2018; Kim et al. 2019), PEVAC and PEVAC-resembling lesions have a similar appearance on OCT. It is not clear whether the imaging characteristics of these aneurysmal abnormalities differ from the originally described PEVAC lesions, and if so, to what extent. Venkatesh et al. (2019) reported a case showing all features of a PEVAC lesion, but the patient was also diagnosed with diabetic retinopathy. The authors suggested that PEVAC may be seen in healthy eyes and may also occur in those with retinal vascular abnormalities.

PEVAC is a newly identified vascular abnormality, first described by Querques et al. (2011), and both pathophysiology and pathogenesis are not fully understood. It is also unclear whether PEVAC-resembling lesions are similar to the originally described PEVAC lesions. The aim of this study was to describe and compare clinical, morphological and vascular characteristics of PEVAC and PEVAC-resembling lesions using multimodal imaging.

## Methods

### Study design

This cross-sectional observational study was approved by the local internal review board of the Rotterdam Eye Hospital (Rotterdam, the Netherlands). This study adhered to the tenets of the Declaration of Helsinki. Written informed consent was obtained from all participants.

### Study population

We prospectively recruited consecutive patients between January 2019 and October 2019, who were identified with a PEVAC(-resembling) lesion on OCT. Identification of PEVAC lesions was based on the structural appearance on OCT, that is a round or oval lesion with hyperreflective surrounding had to be present. Lesions with similar

structure and size on OCT, but in patients with a history of a retinal vascular disease, were identified as PEVAC-resembling lesions. We divided the patients into two groups: subjects without vascular retinopathy (PEVAC group) and subjects with a vascular retinopathy, such as diabetic retinopathy or retinal vein occlusions (PEVAC-resembling group). This was decided based on medical history, slit-lamp examination, OCT, OCT-A, fluorescein angiography (FA) and/or indocyanine green angiography (ICGA).

The exclusion criterium for the PEVAC group was the presence of any other retinal or choroidal vascular abnormalities, previous treatment, presence of diabetes mellitus and presence of uncontrolled hypertension. In addition, subjects that were imaged during earlier visits with the Heidelberg Spectralis SD-OCT (Heidelberg Engineering, Heidelberg, Germany) and colour fundus photography (CFP) were retrospectively included in the study.

### Image acquisition

OCT and OCT-A imaging was performed on a Spectralis SD-OCT system (Heidelberg Engineering, Heidelberg, Germany), which has a wavelength of 840 nm and operates at 40 kHz A-scan rate. OCT scans were acquired using a scan pattern (width × height) of 30° × 15° (±8.7 mm × 4.3 mm). The distance between consecutive B-scans was 30 µm; 145 B-scans were obtained per OCT scan. For the OCT-A scans, the distance between B-scans was 6 µm and the pattern size was 10° × 10° (±2.9 mm × 2.9 mm), resulting in 512 B-scans per OCT-A image. Scanning was performed by a single operator.

Acquisition of colour fundus photographs was performed on a Zeiss FF450<sup>plus</sup> Fundus Camera (Carl Zeiss Meditec AG, Jena, Germany).

### Measurement variables

Every B-scan of the OCT volume scan of both eyes was assessed. This assessment enables the detection of several characteristics of the lesion, such as its laterality (unilateral or bilateral) and focality (unifocal or multifocal). When multiple PEVAC(-resembling) lesions in one eye were present, we selected the

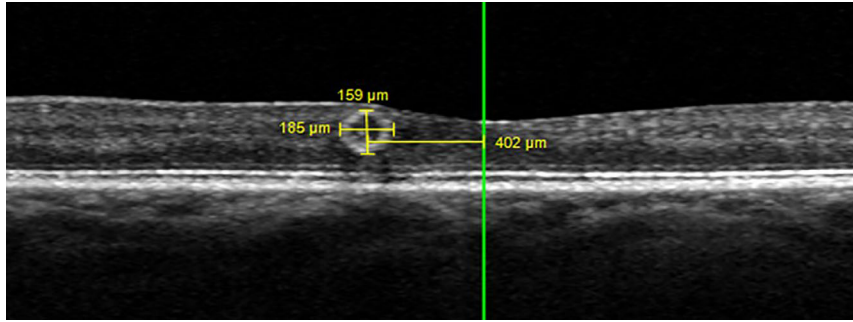
largest lesion for analysis. The B-scan containing the largest section of the lesion was used for further analysis. Based on this B-scan, we assessed the retinal location of the lesion, that is in which retinal layer, the centre of the lesion, was located. Furthermore, we measured on this B-scan the horizontal and vertical diameter of the lesion and the horizontal distance of the lesion to the fovea (Fig. 1). These measurements were performed using the built-in 'measure distance' tool of the Heidelberg Spectralis software. The cross-sectional surface area of the lesion was estimated using the equation for ellipse surface. Moreover, following Horii et al. (2010) we classified the capsular structure of the aneurysmal lesions as complete ring sign, incomplete ring sign or absent ring sign.

We evaluated, based on OCT-A, whether the PEVAC(-resembling) lesions were perfused. OCT-A *en face* images in combination with scanning laser ophthalmoscopy (SLO) or CFP were used to trace the PEVAC(-resembling) lesion back proximally and distally to analyse whether the lesion originates from an arterial or venous branch (Ishibazawa et al. 2019). It was also analysed whether they were located in the capillary network or a higher-order branch. In some patients, the quality of SLO and CFP was not sufficient. For those patients, we consulted prior FA images to analyse the inflow and outflow, which provides information on whether vessels are arterial or venous. An example is shown in Fig. 2. Qualitative analysis of the presence or absence of a perilesional microvascular rarefaction, that is capillary dropout around the flow corresponding to the lesion, was performed by two of the authors (J.V. and L.S.).

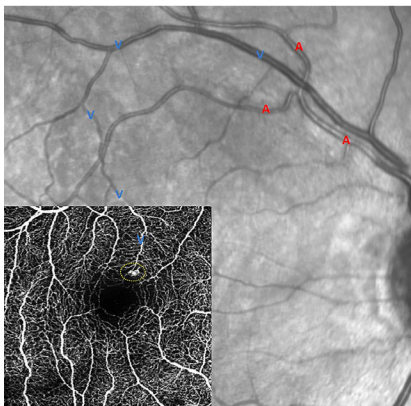
The presence or absence of haemorrhages and exudates was recorded, based on funduscopy and on evaluation of the CFP images that were acquired on the same date as the OCT and OCT-A scans.

### Statistical analysis

Statistical analysis was performed using SPSS Statistics Version 24 (IBM, Armonk, NY, USA). Categorical variables were expressed as counts (*n*) and percentages (%), and continuous data as mean ± standard



**Fig. 1.** The horizontal diameter and vertical diameter were assessed on the selected B-scan; in this example, the horizontal diameter was 185 μm and the vertical diameter 159 μm. The horizontal distance to the centre of the fovea was measured between the green reference line (located on the centre of the fovea) and the vertical diameter measurement line. In this example, the horizontal distance to the fovea was 402 μm. [Colour figure can be viewed at wileyonlinelibrary.com]



**Fig. 2.** The perifoveal exudative vascular anomalous complex is located within the yellow, dotted ellipse. The red letters of A refer to an arterial vessel, and the blue letters of V refer to a venous vessel. This figure shows that this particular PEVAC lesion is connected to a venous vessel. Furthermore, the lesion is located on the level of retinal capillaries.

**Table 1.** Demographics and baseline characteristics.

	PEVAC	PEVAC-resembling
Number of patients	10	22
Male	8	11
Female	2	11
Number of eyes	10	27
Age	76.6 ± 9.7	72.3 ± 7.6
General health (per eye)		
Hypertension	7	11
DM	0	21
Ischaemic attack or stroke	4	4
Coinciding retinal vascular diseases (per eye)		
Dry ARMD	2	1
DRP	0	21
BRVO	0	4
CRVO	0	1
Myopic maculopathy with staphyloma	0	2
Ischaemic maculopathy	0	1

ARMD = age-related macular degeneration, BRVO = branch retinal vein occlusion, CRVO = central retinal vein occlusion, DM = diabetes mellitus, DRP = diabetic retinopathy.

**Table 2.** Detailed information on the age and history of cardiovascular problems in patients with perifoveal exudative vascular anomalous complex (PEVAC).

Patient	Age (years)	History of cardiovascular problems
1	76	Myocardial infarction, transient ischaemic attack
2	56	Hypertension
3	92	Hypertension
4	75	Hypertension, myocardial infarction
5	73	None
6	86	Hypertension, transient ischaemic attack
7	76	Hypertension, cerebrovascular accident
8	70	Hypertension
9	83	Hypertension
10	71	None

deviation (SD). A p-value smaller than 0.05 was considered statistically significant. The chi-square test of independence was used to analyse whether categorical variables differed statistically significantly between the PEVAC and PEVAC-resembling groups. For continuous variables, a Mann-Whitney U-test was used to analyse statistically significant differences between PEVAC and PEVAC-resembling lesions.

## Results

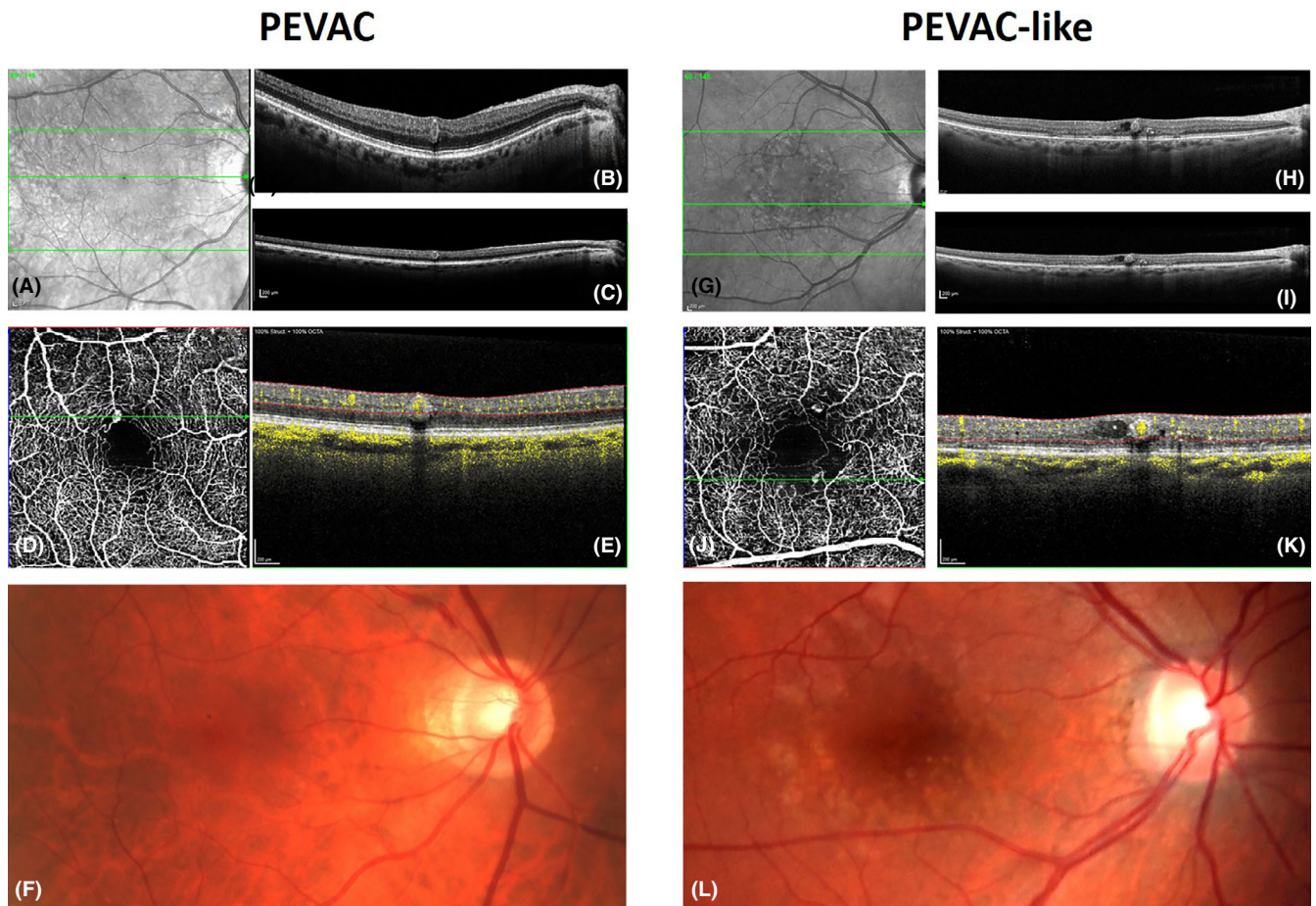
Ten eyes of 10 patients with a PEVAC and 27 eyes of 22 patients with a PEVAC-resembling lesion were included in this study. Demographics and baseline characteristics are presented in Tables 1 and 2. Figure 3 shows examples of the OCT, OCT-A

and fundus images of a PEVAC and a PEVAC-resembling lesion.

OCT observations are shown in Table 3. In the PEVAC group, all the lesions were unilateral (100%) and almost all appeared unifocally (90%). In contrast, PEVAC-resembling lesions appeared in 23% of cases bilateral ( $p > 0.05$ ) and 56% of the PEVAC-

resembling cases had multifocal lesions ( $p < 0.05$ ). In 90% of the eyes, PEVAC lesions were located within 500 μm from the centre of the fovea, while this was true for only 56% of the PEVAC-resembling lesions ( $p > 0.05$ ).

Table 4 shows the vascular observations of PEVAC and PEVAC-resembling lesions. Lumens of almost all



**Fig. 3.** Optical coherence tomography (OCT), OCT-A and CFP images of an eye with a PEVAC (left) and an eye with a PEVAC-resembling (right) lesion. Images A and G are the scanning laser ophthalmoscopy (SLO) images. The green line corresponds with the location of the B-scans B and C and H and I. Images B and H are the B-scans with an oval PEVAC(-resembling) lesion. Images C and I represent the true structure of the PEVAC(-resembling) lesions, that is a more circular structure. Optical coherence tomography (OCT) images are normally scaled to enhance vertical resolution (B and H), while in C and I the vertical scale is adjusted to the horizontal scale, that is these images show true proportions. D and J represent the OCT-A *en face* images, showing hyperreflective dots on the location of the PEVAC(-resembling) lesions. The green line goes through the lesion and corresponds with the location of the cross-sectional B-scan. In J, another PEVAC-resembling lesion is visible more superior. E and K show the cross-sectional B-scan with flow overlay, showing perfusion of both lesions. F and L are the CFP images of both lesions. Small haemorrhages are present in the CFP image of the PEVAC-resembling patient. [Colour figure can be viewed at [wileyonlinelibrary.com](http://wileyonlinelibrary.com)]

PEVAC and PEVAC-resembling lesions were perfused (100% vs. 96%,  $p > 0.05$ ). There was one PEVAC-resembling lesion without perfusion that could therefore not be used for further vascular analysis. PEVAC and PEVAC-resembling lesions were venous in 50% and 62% of the cases ( $p > 0.05$ ), and most of them were connected to capillaries (80% and 85%,  $p > 0.05$ ). Perilesional microvascular rarefaction was observed around 90% of the PEVAC lesions, but also around 89% of the PEVAC-resembling lesions ( $p > 0.05$ ).

Statistical significantly fewer haemorrhages were observed on fundus photographs in the eyes with a PEVAC (10%) than in eyes with a PEVAC-resembling lesion (82%,  $p < 0.001$ ).

Furthermore, no statistically significant difference was found in observed exudates between both groups (PEVAC 30% and PEVAC-resembling 22%,  $p > 0.05$ ).

### Discussion

In this prospective cross-sectional study, we explored several features of PEVAC based on multimodal imaging and compared those with PEVAC-resembling lesions. These lesions were previously excluded from studies because these aneurysmal microangiopathies are related to an underlying retinal vascular pathology. Clinical, morphological and vascular features were predominantly similar in PEVAC and PEVAC-resembling lesions.

There were, however, some observed differences. First of all, PEVAC-resembling lesions were significantly more often accompanied by haemorrhages, which are related to the underlying retinal vascular pathology. We furthermore observed differences in quantity of PEVAC and PEVAC-resembling lesions. PEVAC lesions appeared unifocal, or in isolation, in almost all cases. On the other hand, PEVAC-resembling lesions appeared statistically significant more frequently multifocal within the same eye. Interestingly, multifocality of PEVAC has never been described to exceed three lesions (Fernandez-Vigo et al. 2020), while we have observed up to five PEVAC-resembling lesions within a single eye. Furthermore,

**Table 3.** Optical coherence tomography observations of patients with perifoveal exudative vascular anomalous complex (PEVAC) and patients with a PEVAC-resembling lesion.

	PEVAC	PEVAC-resembling	p-Value
Laterality			
Unilateral	10 (100%)	17 (77%)	0.10
Bilateral	0 (0%)	5 (23%)	
Focality			0.009*
Unifocal	9 (90%)	12 (44%)	
Multifocal	1 (10%)	15 (56%)	
Location centre PEVAC			0.73
GCL	0 (0%)	1 (4%)	
IPL	1 (10%)	3 (11%)	
INL	7 (70%)	17 (63%)	
OPL	2 (20%)	2 (7%)	
ONL	0 (0%)	4 (15%)	
Intraretinal cystoid space			0.25
Present	5 (50%)	19 (70%)	
Absent	5 (50%)	8 (30%)	
Capsular structure			0.21
Complete ring sign	3 (30%)	8 (30%)	
Incomplete ring sign	3 (30%)	15 (56%)	
Absent ring sign	4 (40%)	4 (15%)	
PEVAC dimensions			
Horizontal diameter (µm)	156 ± 35	161 ± 32	0.72
Vertical diameter (µm)	145 ± 39	157 ± 32	0.13
Surface area (µm <sup>2</sup> )	18 × 10 <sup>3</sup> ± 9 × 10 <sup>3</sup>	20 × 10 <sup>3</sup> ± 7 × 10 <sup>3</sup>	0.32
Horizontal distance to fovea (µm)	373 ± 145	445 ± 258	0.58
Within or outside central fovea			0.051
<500 µm	9 (90%)	15 (56%)	
>500 µm	1 (10%)	12 (44%)	

GCL = ganglion cell layer; IPL = inner plexiform layer; INL = inner nuclear layer; ONL = outer nuclear layer; OPL = outer plexiform layer.

\* Statistically significant difference between PEVAC and PEVAC-resembling groups.

**Table 4.** Vascular observations of patients with perifoveal exudative vascular anomalous complex (PEVAC) and patients with a PEVAC-resembling lesion

	PEVAC	PEVAC-resembling	p-Value
Flow in PEVAC			0.54
Present	10 (100%)	26 (96%)	
Absent	0 (0%)	1 (4%)	
Branching			0.53
Arterial or venous			
Arterial	5 (50%)	10 (38%)	
Venous	5 (50%)	16 (62%)	
Capillaries or arteriole/venule			0.74
Capillaries	8 (80%)	22 (85%)	
Arteriole/venule	2 (20%)	4 (15%)	
Microvascular rarefaction			0.92
Present	9 (90%)	24 (89%)	
Absent	1 (10%)	3 (11%)	

although not statistically significantly different, PEVAC-resembling lesions occurred bilateral in 23%, independent of the underlying vascular pathology, while none of the PEVAC lesions were bilateral. Even though it is very infrequent, a case study has recently described the appearance of a bilateral PEVAC lesion (Fernandez-Vigo et al. 2020). Moreover, OCT showed that 90% of the PEVAC lesions were located within 500 µm

from the centre of the fovea, while this was only true for 56% of the PEVAC-resembling lesions. Given the frequently occurring multifocality and bilaterality of PEVAC-resembling lesions, it is reasonable to assume that an underlying vascular pathology stimulates the formation of one or more perifoveal aneurysmal abnormalities. This observation is supported by the more diffusely appearance of the PEVAC-resembling lesions.

Querques et al. (2011) were the first to describe PEVAC and stated that this peculiar clinical entity does not clinically fit any known retinal disease. PEVAC is therefore considered a stand-alone retinal vascular disease in otherwise healthy eyes. In contrast, PEVAC-resembling lesions are considered retinal microangiopathies related to a known underlying retinal vascular disease. Given the multi-modal-based imaging similarities between PEVAC and PEVAC-resembling lesions, we may consider both PEVAC and PEVAC-resembling as local microangiopathies regardless of their origin. Microangiopathies are known to change and may disappear over time without intervention (Wiley & Ferris 2013). As Verhoekx et al. (2020) showed that PEVAC lesions may regress spontaneously and even disappear over time, this supports the suggestion that PEVAC lesions may indeed be considered a microangiopathy. However, as the appearance of PEVAC has no relation to any underlying retinal vascular disease, we speculate that a possible cause of the development of this isolated microangiopathy might be related to a past or ongoing general cardiovascular problem as in our study, 40% of the PEVAC patients have suffered from an ischaemic attack or stroke and 70% of cases have controlled hypertension (Tables 1 and 2).

The pathogenesis of aneurysmal microangiopathies is still largely unknown (Beltramo & Porta 2013). Pericytes play a prominent role in the development of microaneurysms related to diabetes. They are specialized contractile cells that regulate vascular tone and perfusion pressure in the retinal capillaries (Stitt et al. 1995; Armulik et al. 2005; Beltramo & Porta 2013). Apoptosis and dropout of pericytes may contribute to the initiation of endothelium to proliferate into microaneurysms (Stitt et al. 1995; Kern & Huang 2010). The hypothesis of microaneurysm genesis could also apply to PEVAC and PEVAC-resembling lesion development. However, this does not explain why PEVAC(-resembling) grows into such large lesions in comparison with microaneurysms. A possible explanation could be a theory postulated by Spaide & Barquet (2018) that these kind of lesions are actually an aneurysmal expansion, possibly due to a decrease in the lesion wall strength and an increased wall tension.

In the perilesional area, microvascular rarefaction was observed in 90% of the patients with a PEVAC lesion. Microvascular rarefaction is described as the result of an impaired angiogenesis, leading to microvascular regression (Goligorsky 2010). Factors that may contribute to microvascular rarefaction are removal of angiogenic stimuli, discontinuation of blood flow, disruption of endothelial pericyte association, angiogenesis inhibitors, endothelial dysfunction, or endothelial or stem cell reprogramming (Goligorsky 2010). Both genesis of aneurysmal abnormalities and perilesional microvascular regression seem to be related to the process of pericyte loss (Stitt et al. 1995; Armulik et al. 2005; Goligorsky 2010; Beltramo & Porta 2013). Furthermore, an association has been suggested between microvascular rarefaction and ageing in the retinal vasculature (Azemin et al. 2012). The PEVAC patients in our study were  $76.6 \pm 9.7$  years old, and microvascular rarefaction was found in both patients with and without past or ongoing cardiovascular problems. Therefore, we hypothesize that ageing might possibly be a critical factor in the development of an aneurysmal abnormality. These aneurysmal changes could either appear as a small microaneurysm (Ashton 1951), or expand into a prominently visible PEVAC lesion.

There are some limitations to this study. The statistical power of this study was limited due to the small sample size, even though we included a relatively large group of patients compared with other published studies on PEVAC. Furthermore, as this was a cross-sectional study, only single-visit imaging data were available. Verhoekx et al. (2020) showed that PEVAC lesions change and may completely disappear over time. It remains unclear how PEVAC(-resembling) develops, why they change and what the sequence of events is that result in PEVAC regression or disappearance. We are therefore not sure in what phase we captured the PEVAC lesions that were included here. Different phases may result in different features of the PEVAC or PEVAC-resembling lesion. However, this study provides a first overview of several clinical, morphological and vascular characteristics of both PEVAC and PEVAC-resembling lesions, and further research should include the PEVAC and

PEVAC-resembling lesions when they are in the most active phase to draw further conclusions. Furthermore, the presence of microvascular rarefaction on OCT-A *en face* was subjectively scored by two of the authors, but a quantitative measure would be preferable. Vessel density analysis for such a focal lesion and its surroundings is not suitable because of the differences in size of the area of interest between patients.

In conclusion, PEVAC and PEVAC-resembling lesions are both retinal microangiopathies with predominantly similar clinical, morphological and vascular features on multimodal imaging but different causes. We observed evident differences in quantity of PEVAC compared with PEVAC-resembling lesions, which suggests that an underlying retinal vascular pathology stimulates the formation of perifoveal aneurysmal abnormalities. We hypothesize that either general cardiovascular issues or local age-related deterioration of the retinal vasculature or both are related to the development of a focal PEVAC lesion.

## References

- Armulik A, Abramsson A & Betsholtz C (2005): Endothelial/pericyte interactions. *Circ Res* **97**: 512–523.
- Ashton N (1951): Retinal micro-aneurysms in the non-diabetic subject. *Br J Ophthalmol* **35**: 189–212.
- Azemin MZ, Kumar DK, Wong TY, Wang JJ, Mitchell P, Kawasaki R & Wu H (2012): Age-related rarefaction in the fractal dimension of retinal vessel. *Neurobiol Aging* **33**: 194.e1–194.e4.
- Beltramo E & Porta M (2013): Pericyte loss in diabetic retinopathy: mechanisms and consequences. *Curr Med Chem* **20**: 3218–3225.
- Bourhis A, Girmens JF, Boni S, Pecha F, Favard C, Sahel JA & Paques M (2010): Imaging of macroaneurysms occurring during retinal vein occlusion and diabetic retinopathy by indocyanine green angiography and high resolution optical coherence tomography. *Graefes Arch Clin Exp Ophthalmol* **248**: 161–166.
- Fernandez-Vigo JI, Burgos-Blasco B, Dolz-Marco R, Jimenez-Santos M, Lopez-Guardado L & Donate-Lopez J (2020): Atypical perifoveal exudative vascular anomalous complex (PEVAC) with multifocal and bilateral presentation. *Am J Ophthalmol Case Rep* **18**: 100717.
- Goligorsky MS (2010): Microvascular rarefaction: the decline and fall of blood vessels. *Organogenesis* **6**: 1–10.

- Horii T, Murakami T, Nishijima K, Sakamoto A, Ota M & Yoshimura N (2010): Optical coherence tomographic characteristics of microaneurysms in diabetic retinopathy. *Am J Ophthalmol* **150**: 840–848.
- Ishibazawa A, Mehta N, Sorour O et al. (2019): Accuracy and reliability in differentiating retinal arteries and veins using Wide-field *en face* OCT angiography. *Transl Vis Sci Technol* **8**: 60.
- Kern TS & Huang S (2010): Ocular disease: mechanisms and management. 506–513.
- Kim JH, Kim JW, Kim CG & Lee DW (2019): Characteristics of perifoveal exudative vascular anomalous complex in Korean patients. *Semin Ophthalmol* **34**: 353–358.
- Mrejen-Uretsky S, Le HM, Nghiem-Buffer S, Tabary S, Quentel G & Cohen SY (2018): Insights into perifoveal exudative vascular anomalous complex. *Retina* **40**: 80–86.
- Querques G, Kuhn D, Massamba N, Leveziel N, Querques L & Souied EH (2011): Perifoveal exudative vascular anomalous complex. *J Fr Ophthalmol* **34**: 559.e1–559.e4.
- Sacconi R, Freund KB, Yannuzzi LA et al. (2017): The expanded spectrum of perifoveal exudative vascular anomalous complex. *Am J Ophthalmol* **184**: 137–146.
- Spaide RF & Barquet LA (2018): Retinal capillary macroaneurysms. *Retina* **39**: 1889–1895.
- Stitt A, Gardiner T & Archer D (1995): Histological and ultrastructural investigation of retinal microaneurysm development in diabetic patients. *Br J Ophthalmol* **79**: 362–367.
- Venkatesh R, Yadav NK, Bavaharan B, Prabhu V & Sinha S (2019): Multimodal imaging in perifoveal exudative vascular anomalous complex with co-existent diabetic retinopathy. *Clin Exp Optom* **102**: 528–532.
- Verhoekx JSN, Smid LM, Vermeer KA, Martinez Ciriano JP & Yzer S (2020): Anatomical changes on sequential multimodal imaging in perifoveal exudative vascular anomalous complex. *Retina*. Online ahead of print.
- Wiley HE & Ferris FL (2013): Nonproliferative diabetic retinopathy and diabetic macular edema. 940–968.

Received on June 5th, 2020.

Accepted on September 23rd, 2020.

### Correspondence:

Lisette M. Smid  
Rotterdam Ophthalmic Institute  
Schiedamse Vest 160d  
3011BH Rotterdam  
The Netherlands  
Tel: +31 10 402 34 49  
Email: roi@oogziekenhuis.nl

Funding: This work was supported by Rotterdamse Stichting Blindenbelangen (RSB, B20180055), Rotterdam, the Netherlands, and Stichting Wetenschappelijk Onderzoek Oogziekenhuis (SWOO, 2018S04), Rotterdam, the Netherlands.