

# Leiomyosarcoma Metastatic to the Skull and Spine: a Case Report

## *Metástase de Leiomiossarcoma para o Crânio e Coluna: Relato de Caso*

### Metástasis de Leiomiossarcoma en el Cráneo y la Columna Vertebral: Informe de un Caso

Francisco Otávio Camargo Pereira<sup>1</sup>, Daniel Callegari Pereira<sup>1</sup>, Rafael de Castro Aguiar<sup>1</sup>, Ismael Augusto Silva Lombardi<sup>1</sup>, Marco Antonio Zanini<sup>2</sup>

#### **Abstract**

**Background:** Uterine leiomyosarcomas account for approximately 30% of uterine sarcomas. The peak incidence age is around the mid-thirties reaching a plateau in the mid-fifties. It rarely metastasizes to the skull and the bone. **Case Presentation:** In this report, we describe an unusual case of uterine leiomyosarcoma metastasizing to both the spine and the skull. This patient had a known diagnosis of uterine leiomyosarcoma following a total hysterectomy five years before. She underwent resection of the skull mass and radiotherapy for the spinal lesions. **Conclusion:** Leiomyosarcoma is usually accompanied by widespread metastases and a poor chance of survival. Skull metastases are usually seen in the advanced stage of the disease. Surgery cannot change the course of the underlying disease, but can relieve local discomfort. Treatment options for spinal metastases are varied, and definitive statements regarding efficacy cannot be made. To our knowledge, this is the first case of simultaneous metastatic deposits in both spine and skull.

**Key words:** Leiomyosarcoma; Spine; Skull Neoplasms; Case Studies

---

<sup>1</sup>M.D. Neurology and Neurosurgery Department, UNESP, Botucatu, Brazil.

<sup>2</sup>M.D., PhD. Neurology and Neurosurgery Department, UNESP, Botucatu, Brazil.

*Mailing address:* Neurosurgery Department, UNESP, Botucatu (SP), Brazil. CEP: 18618-970. *E-mail:* franotavio@hotmail.com.

## INTRODUCTION

Leiomyosarcoma is a rare malignant smooth muscle tumor that occurs most commonly either in the uterus, digestive tract or retroperitoneum<sup>1</sup>. Uterine leiomyosarcoma accounts for 25-36% of uterine sarcomas and 1% of all malignancies. It has a poor prognosis due to its high metastatic recurrence rate<sup>2</sup>. The commonly reported sites of metastatic disease are the lung, the peritoneal cavity and the liver<sup>3</sup>. Metastatic bone lesions are rare, particularly as the first site of recurrence, and the spine is the most common site of osseous metastatic spread. In this paper, we report a case of a patient with uterine leiomyosarcoma who developed simultaneous metastatic disease in both the spine and skull, as the first sites of recurrent disease.

## CASE PRESENTATION

A 55-year-old woman presented with a fast growing mass over her right parieto-occipital region, 5 years after undergoing a total hysterectomy for uterine leiomyosarcoma. At the same time, she complained of back pain and noted a bulging mass in her thoracic column. Neurological examination on admission was normal.

A magnetic resonance imaging (MRI) of the brain (Figure 1) showed a gadolinium enhancing large extradural mass compressing the brain parenchyma with involvement of the skull and the adjacent scalp. MRI and computed tomography (CT) of the thoracic spine showed a mass in the right paravertebral muscles (Figure 2). MRI of the lumbar spine showed a metastatic deposit in the L3 vertebral body.

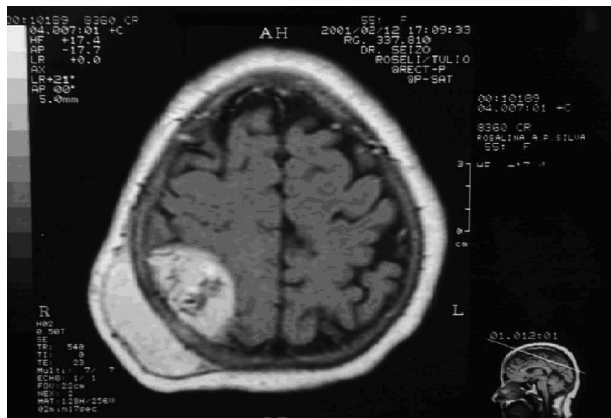


Figure 1. MRI showing the extradural cranial lesion

A craniotomy was performed covering the limits of the tumor, which was removed, including the skull plate, the dura and the scalp (Figure 3). The tumor invaded the underlying dura, but not the brain parenchyma. The post-operative period was uneventful. Figure 4 shows both pre and post-operative surgical result.

Histopathologic examination confirmed the diagnosis of uterine metastatic leiomyosarcoma (Figure 5) and immunohistochemistry was positive for desmin and muscle actin.

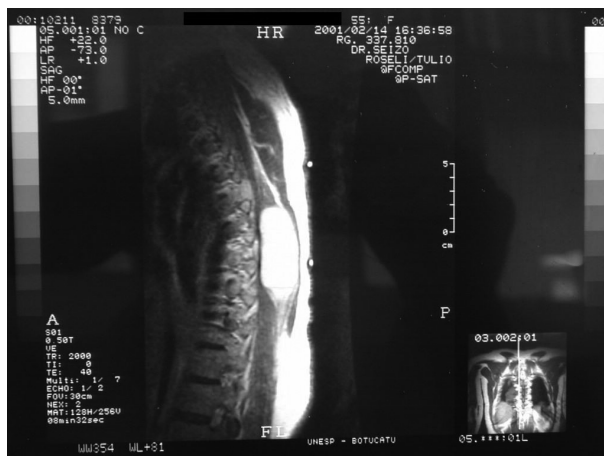

Figure 2. MRI showing the thoracic lesion (paravertebral muscles involvement)

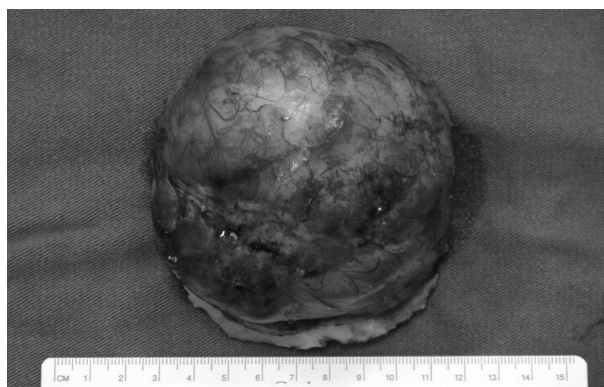


Figure 3. Surgical specimen showing a large (10 cm) resected tumor

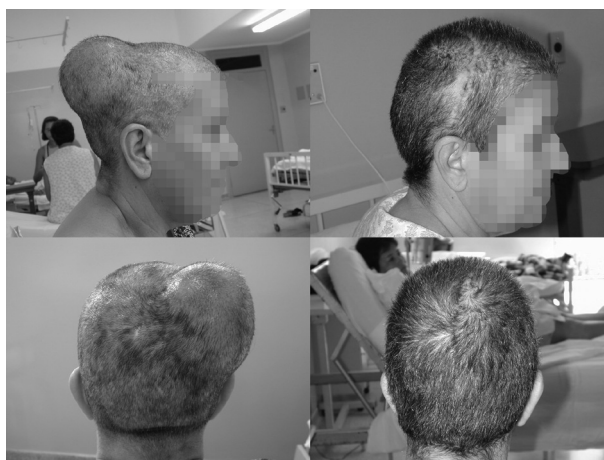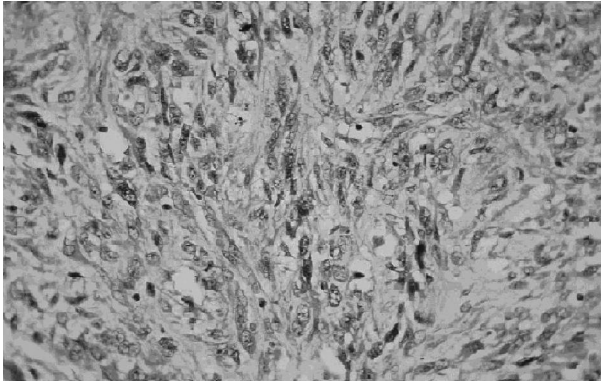


Figure 4. Pre and post-operative images of the patient

A follow-up MRI of the lumbar column four months after the first study showed the tumor invading the spinal canal and adjacent areas, including the pelvic bones. She developed intractable pain and eventually expired from the disease 4 weeks after that.

## DISCUSSION

Leiomyosarcoma is an aggressive tumor that often metastasizes to the lung, liver and peritoneal cavity. The



**Figure 5.** Metastatic leiomyosarcoma showing nuclear pleomorphism and increased number of mitosis

prognosis is poor with a 5-year survival ranging from 0 to 68% in different series<sup>4</sup>. Bone metastases are rare, the spine being the most common site. Metastatic disease to the skull is quite rare and, to our knowledge, this is the first case of simultaneous presentation of disease involving the spine and skull. Surgery to the skull metastasis is usually recommended particularly when there is significant neurologic deficit; a massive destruction of bone and/or dura infiltration; uncontrollable painful symptoms or a solitary metastasis<sup>5</sup>. Moreover, surgical intervention will confirm the diagnosis. In this case, surgical intervention was mostly to improve esthetics of the patient as she had evidence of metastatic disease elsewhere.

The spine is the most common site of osseous metastasis and it tends to symptomatically involve one or more spinal levels at the time of diagnosis<sup>6</sup>. However, the patient's general condition, status of the disease, neurological deficit and the stability of the spine must be evaluated.

In this case, despite persistent back pain, the patient had a normal neurological exam and underwent radiotherapy for palliative care. There was a metastatic lesion in the L3 vertebral body and also a metastatic thoracic mass with radiological findings suggestive of involvement of the thoracic spine. These findings explained the patient's painful symptoms.

## CONCLUSION

The treatment of each disease, from the beginning, should be appropriate to the patient's clinical condition,

considering the prognosis<sup>7</sup>. Patients diagnosed with metastatic leiomyosarcoma who are in good general condition should be assessed carefully in order to determine the best surgical or conservative treatment to be taken. Improvement in quality of life is an important endpoint at the time the metastatic disease is diagnosed.

## CONSENT

The approval of the Research Ethics Committee was established and is registered under number 454/2010. A copy of this consent is available for review by the Editor-in-Chief of this journal.

**Conflict of Interest: The Authors Declare that they Have no Conflict of Interest.**

## REFERENCES

1. Elhammady MS, Manzano GR, Lebwohl N, Levi AD. Leiomyosarcoma metastases to the spine. *J Neurosurg* 2007; 6: 178-83
2. Barbetakis N, Paliouras D, Asteriou C, Samanidis G, Kleontas A, Anestakis D, et al. Cutaneous skull metastasis from uterine leiomyosarcoma: a case report. *World J Surg Oncol* 2009; 7: 45.
3. Ferreira A, Garcia V, Costa MV, Braga FM. Leiomiossarcoma cerebral. *Jornal brasileiro de neurocirurgia* 1996; 7(1):50-2
4. Prussia PR, Clarke HA, Mansoor G, Garriques S, Maheswaran B. Uterine leiomyosarcoma with intracerebral metastasis: a case report. *J Natl Med Assoc* 1992; 84 (4):368-70.
5. Yip C, Yang K, Lo Y, Liao W, Chen J, Hsu S. skull metastasis from uterine leiomyosarcoma: a case report. *Acta Neurol Taiwan* 2006;15 (2):109-13.
6. Meltzer CC, Fishman EK, Scott WW Jr. Computed tomography appearance of bone metastases of leiomyosarcoma. *Skeletal Radiol* 1992; 21 (7):445-7.
7. Silva CHD, Reis TC, Pinto CS, Schramm FR. Quando o tratamento oncológico pode ser fútil? *Revista brasileira de cancerologia* 2008; 54 (4): 385-6.

## Resumo

**Introdução:** O leiomiossarcoma uterino corresponde a, aproximadamente, 30% dos sarcomas uterinos. A idade de maior incidência é por volta dos trinta e cinco anos, alcançando seu crescimento máximo aos cinquenta e cinco anos. Raramente envia metástases para o crânio e para os ossos. **Apresentação do caso:** Neste relato, descreve-se um caso raro de leiomiossarcoma uterino com metástase para o crânio e coluna. A paciente tinha um diagnóstico prévio de leiomiossarcoma uterino após histerectomia total ocorrida há cinco anos. A lesão craniana foi ressecada e as lesões da coluna foram abordadas com radioterapia. **Conclusão:** O leiomiossarcoma é normalmente acompanhado por metástases disseminadas e um prognóstico reservado. Metástases do crânio são geralmente vistas em um estágio avançado da doença. A cirurgia não pode alterar o curso da doença subjacente, mas pode aliviar o desconforto local. As opções de tratamento para as metástases espinais são variadas, e as indicações definitivas sobre eficácia não podem ser feitas. Ao nosso conhecimento, é o primeiro caso relatado com ambas as metástases apresentando-se simultaneamente.

**Palavras-chave:** Leiomiossarcoma; Coluna Vertebral; Neoplasias Cranianas; Estudos de Casos

## Resumen

**Introducción:** El leiomiossarcoma uterino representa, aproximadamente, el 30% de los sarcomas uterinos. La edad de mayor incidencia es a mediados de los treinta, estabilizándose a mediados de los cincuenta. En raras ocasiones envía metástasis al cráneo y los huesos. **Presentación del caso:** Divulgamos aquí un caso raro de leiomiossarcoma uterino con metástasis para el cráneo y columna. La paciente tenía un diagnóstico previo de leiomiossarcoma uterino tras histerectomía total, sucedida cinco años antes. La lesión craneal se resecó y las lesiones de la columna fueran tratadas con radioterapia. **Conclusión:** El leiomiossarcoma suele acompañarse de metástasis diseminadas y pronóstico reservado. Metástasis del cráneo ocurren en la etapa avanzada de la enfermedad. La cirugía no altera el curso de la enfermedad subyacente, pero alivia el malestar local. Las opciones de tratamiento para las metástasis vertebrales son variadas, y uno no puede hacer declaraciones definitivas sobre sus eficacias. A nuestro entender, es el primer caso reportado que presenta ambas las metástasis de modo simultáneo.

**Palabras clave:** Leiomiossarcoma; Columna Vertebral; Neoplasias Craneales; Estudios de Casos