



CASE REPORT

# Case Report: severe paediatric COVID-19 pneumonitis treated with remdesivir and nitazoxanide [version 1; peer review: 1 approved with reservations]

Nuria Sanchez Clemente<sup>1,2\*</sup>, Juanita Pang <sup>3,4\*</sup>, Charlene Rodrigues <sup>1,5</sup>, Paul Aurora<sup>6</sup>, Judith Breuer<sup>4</sup>

<sup>1</sup>Immunology and Infectious Diseases Department, Great Ormond Street Hospital for Children, London, UK

<sup>2</sup>Department of Infectious Disease Epidemiology, London School of Hygiene & Tropical Medicine, London, UK

<sup>3</sup>Division of Infection and Immunity, University College London, London, UK

<sup>4</sup>Department of Infection, Immunity, and Inflammation, UCL Great Ormond Street Institute of Child Health, London, UK

<sup>5</sup>Department of Zoology, University of Oxford, Oxford, UK

<sup>6</sup>Department of Respiratory Paediatrics, Great Ormond Street Hospital for Children, London, UK

\* Equal contributors

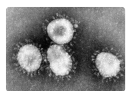
**v1** First published: 03 Dec 2021, 6:329  
<https://doi.org/10.12688/wellcomeopenres.17377.1>  
Latest published: 03 Dec 2021, 6:329  
<https://doi.org/10.12688/wellcomeopenres.17377.1>

## Abstract

Paediatric severe acute respiratory syndrome coronavirus 2 (SARS-CoV-2) infection rarely results in a critical respiratory presentation. It is not yet known which children are at particular risk of adverse outcomes. We describe a paediatric case of critical SARS-CoV-2 infection requiring Extra Corporeal Membrane Oxygenation (ECMO), who made a full recovery after receiving a dual antiviral therapy of remdesivir and nitazoxanide.

## Keywords

SARS-CoV-2, COVID-19, remdesivir, nitazoxanide, combination therapy, whole genome sequencing



This article is included in the [Coronavirus \(COVID-19\)](#) collection.

## Open Peer Review

### Reviewer Status ?


Invited Reviewers

1

### version 1

03 Dec 2021

?  
report

1. [Jonathan Cohen](#) , Evelina London  
Children's Hospital, London, UK

Any reports and responses or comments on the article can be found at the end of the article.

**Corresponding author:** Judith Breuer ([j.breuer@ucl.ac.uk](mailto:j.breuer@ucl.ac.uk))

**Author roles:** **Sanchez Clemente N:** Conceptualization, Data Curation, Formal Analysis, Investigation, Methodology, Visualization, Writing – Original Draft Preparation; **Pang J:** Data Curation, Formal Analysis, Investigation, Methodology, Project Administration, Software, Validation, Visualization, Writing – Original Draft Preparation; **Rodrigues C:** Conceptualization, Investigation, Project Administration, Writing – Review & Editing; **Aurora P:** Conceptualization, Investigation, Resources, Writing – Review & Editing; **Breuer J:** Conceptualization, Funding Acquisition, Investigation, Methodology, Project Administration, Supervision, Writing – Review & Editing

**Competing interests:** No competing interests were disclosed.

**Grant information:** This work was supported by Wellcome (203268); the NIHR UCL/UCLH BRC (to JB) and the Rosetrees fellowship (A2288 to JP).

*The funders had no role in study design, data collection and analysis, decision to publish, or preparation of the manuscript.*

**Copyright:** © 2021 Sanchez Clemente N *et al.* This is an open access article distributed under the terms of the [Creative Commons Attribution License](#), which permits unrestricted use, distribution, and reproduction in any medium, provided the original work is properly cited.

**How to cite this article:** Sanchez Clemente N, Pang J, Rodrigues C *et al.* **Case Report: severe paediatric COVID-19 pneumonitis treated with remdesivir and nitazoxanide [version 1; peer review: 1 approved with reservations]** Wellcome Open Research 2021, **6**:329 <https://doi.org/10.12688/wellcomeopenres.17377.1>

**First published:** 03 Dec 2021, **6**:329 <https://doi.org/10.12688/wellcomeopenres.17377.1>

## Case Report

We describe the case of a five-year-old girl who developed severe pneumonitis secondary to SARS-CoV-2 infection in December 2020 in the United Kingdom (UK), requiring maximal intensive care, who was treated with a dual antiviral therapy of remdesivir and nitazoxanide and made a full recovery.

## Background

The girl was born at term in the UK to consanguineous parents (first cousins), with no requirement for neonatal care. She first became unwell at the age of five months with influenza A bronchiolitis and atypical haemolytic uraemic syndrome. She was ventilated and haemofiltered for 22 days, including a period of time on high frequency oscillatory ventilation (HFOV). She recovered from this illness but at eight months of age had parainfluenza bronchiolitis requiring ventilation for seven days. She continued to have recurrent severe respiratory illnesses with viral infections which resulted in several admissions to hospital as well as six admissions to the paediatric intensive care unit (PICU).

She was extensively investigated for underlying conditions by respiratory and immunology specialists at our centre. There was no family history of predisposition to severe infections. Immunologically, she was initially found to have absent NK cells, low B-cells, low CD8 cells and was panhypoglobulinaemic. She was commenced on three-weekly intravenous immunoglobulin (IVIg) replacement as well as prophylactic co-trimoxazole and fluconazole at the age of 10 months. Her immunology subsequently normalised and no underlying cause was identified for the repeated infections on whole exome (R15) sequencing. Her IVIg replacement and antibiotic/antifungal prophylaxis were therefore stopped at the age of 18 months. At the age of two and a half years, following another severe respiratory infection requiring intubation a chest computed tomography (CT) was performed which showed evidence of bronchiectasis and bronchiolitis obliterans and after multi-disciplinary discussions, she was re-started on IVIg replacement and azithromycin prophylaxis. She had a lung biopsy at the age of three years following a further life-threatening infection, which confirmed chronic peribronchial inflammation and scattered bronchiolitis obliterans. She received monthly pulsed methylprednisolone for six months at that time, followed by a mild improvement in her clinical condition, which also coincided with her moving out of a mould infested house.

## COVID pneumonitis

The episode we describe here occurred in December 2020 when she was five years old, where she presented with cough, wheeze, increased work of breathing and a positive SARS-CoV-2 polymerase chain reaction (PCR) test in respiratory secretions. She initially stabilised with bronchodilators and steroids but developed progressive respiratory failure over three days, leading to intubation and transfer to our PICU. She was difficult to ventilate (conventionally and with HFOV), and rapidly reached thresholds for Extra Corporeal Membrane Oxygenation (ECMO) with a pH of 6.8 and unrecordably high

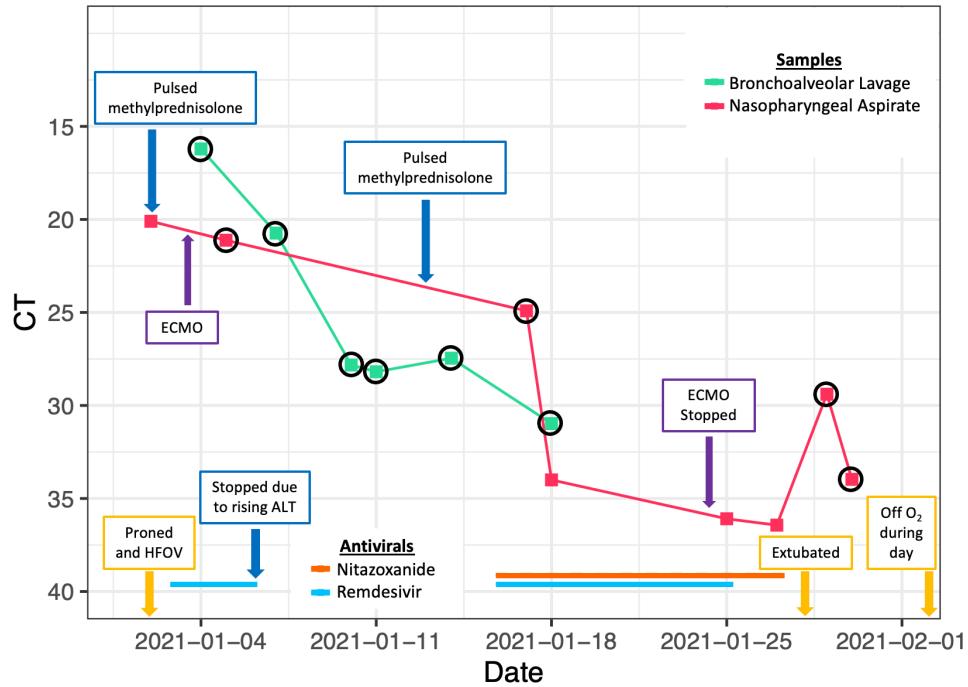
PCO<sub>2</sub>. On commencement of ECMO, she was started on a course of compassionate use remdesivir (130mg loading dose followed by 65mg once daily) and was pulsed with methylprednisolone. At this time, the cycle threshold (Ct) value for SARS CoV-2 was 20, but this reached a peak of 16 on day two. There was no obvious response of viral load to remdesivir and it was discontinued after four doses, on day four of admission, due to increasingly deranged liver function tests. SARS CoV-2 Ct values improved to 28 on day 9 but on day 15, while still on ECMO, they worsened to 25; a decision was then made to commence a second course of remdesivir (with the same dosing regimen) together with adjunctive nitazoxanide (500mg twice daily), which has been shown to have an antiviral activity against SARS-CoV-2<sup>1</sup>. Dual therapy was continued for ten days with evidence of viral load suppression from Ct 25 to Ct 36 occurring within 36 hours (Figure 1). She also received a second pulse of methylprednisolone on day 13. Her chest x-ray aspect gradually appeared to improve, as well as her SARS CoV-2 viral load (Figure 2). She received at total of 20 days of veno-venous ECMO and was ventilated for a further four days following decannulation. She was stepped down to the ward on day 30 and was off daytime oxygen by day 45. She required significant physiotherapy input in her rehabilitation both from a respiratory and neurological point of view after stepping down from PICU, and was finally discharged almost three months after her initial admission. SARS-CoV-2 has subsequently been intermittently detectable in her respiratory secretions for six months following the start of this episode.

## Whole genome sequence analysis

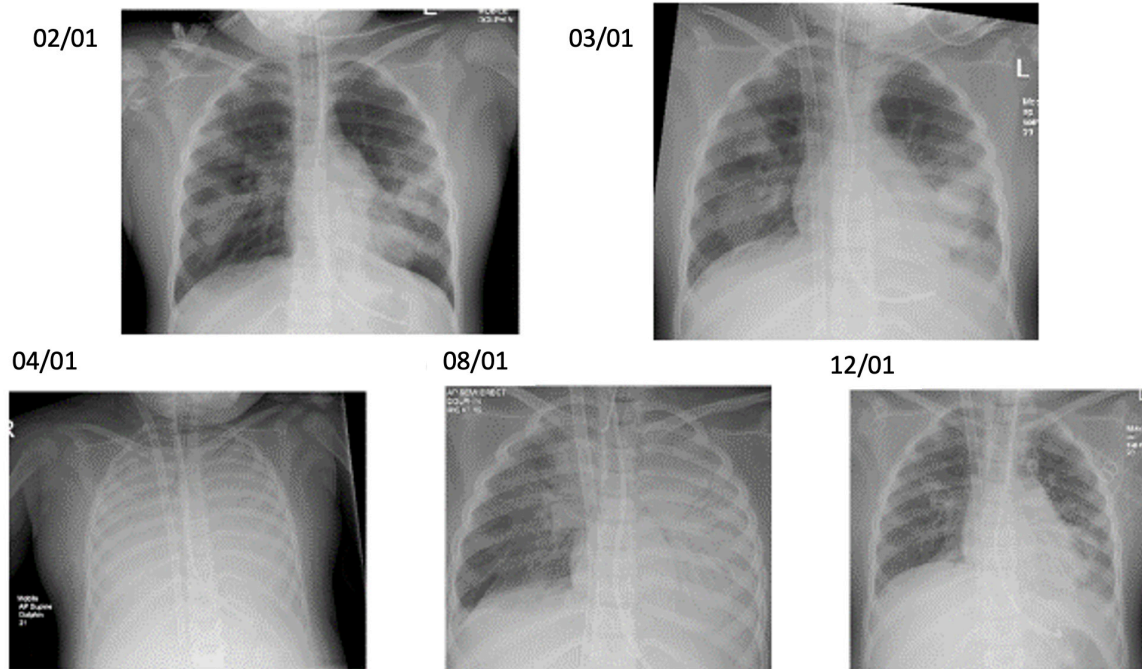
To investigate the response to treatment, we obtained full length SARS-CoV-2 genome sequences from six positive bronchoalveolar lavage samples and four nasopharyngeal aspirate samples (dates of sampling shown in Figure 1) using SureSelect target enrichment and Illumina sequencing. A unique patient reference sequence was generated by mapping the reads of the first sample to the SARS-CoV-2 reference genome (NC\_045512) from GenBank using bwa-mem<sup>2</sup>. Reads from the subsequent samples were mapped to this patient reference. Consensus sequences were aligned using MAFFT<sup>3</sup>. Minority allele variants with a frequency of above 2% were identified using VarScan<sup>4</sup>.

All samples were identified as lineage B.1.1.7 using Local Lineage and Monophyly Assessment (LLAMA)<sup>5</sup>. In a phylogenetic tree with other global and local SARS-CoV-2 samples, all ten consensus sequences from this patient clustered together, indicating no evidence of multiple haplotypes or mixed infection. No resistance mutations were identified.

We have previously reported heterogeneous responses in three patients who received remdesivir monotherapy treatment, with viral suppression occurring in only one<sup>6</sup>. Longitudinally sampled viruses sequenced from these patients suggested the presence of lung compartmentalisation, wherein viral replication occurs in physically separated niches within the lung<sup>6</sup>. A similar phenomenon has been observed for other



**Figure 1.** Cycle threshold value trajectories with indications of treatments received. Orange bar = nitazoxanide treatment received; blue bar = remdesivir treatment received.



**Figure 2.** Chest x-ray appearances on admission (02/01), and on ECMO (03/01, 04/01, 08/01, 12/01) showing gradual improvement.

persistent inflammatory lung infections, including tuberculosis and influenza, with combination chemotherapy recommended to achieve adequate pathogen clearance<sup>7,8</sup>. Based on previous

experience and the extreme severity of her condition, we added nitazoxanide. The rapid suppression of viral load and clinical improvement raises the possibility that combining

remdesivir with a second antiviral agent may improve outcomes in SARS-CoV-2 pneumonitis.

### Consent

The parents/guardians provided informed consent for the publication of this case report.

### Ethics Approval

This work was approved for publication by the Great Ormond Street Hospital (Clinical Audit Number #2857) and PHE Research Ethics and Governance Group (REGG) (R&D NR0195).

### Data availability

All data underlying the results are available as part of the article and no additional source data are required.

### Acknowledgments

The authors would like to thank members of the infectious diseases, immunology, intensive care, respiratory, rheumatology and pharmacy teams who were involved in the management of this patient

### References

1. Rocco PRM, Silva PL, Cruz FF, *et al.*: **Early use of nitazoxanide in mild COVID-19 disease: randomised, placebo-controlled trial.** *Eur Respir J.* 2021; **58**(1): 2003725.  
[PubMed Abstract](#) | [Publisher Full Text](#) | [Free Full Text](#)
2. Li H, Durbin R: **Fast and accurate short read alignment with Burrows-Wheeler transform.** *Bioinformatics.* 2009; **25**(14): 1754–1760.  
[PubMed Abstract](#) | [Publisher Full Text](#) | [Free Full Text](#)
3. Katoh K, Standley DM: **MAFFT multiple sequence alignment software version 7: improvements in performance and usability.** *Mol Biol Evol.* 2013; **30**(4): 772–780.  
[PubMed Abstract](#) | [Publisher Full Text](#) | [Free Full Text](#)
4. Koboldt DC, Zhang Q, Larson DE, *et al.*: **VarScan 2: Somatic mutation and copy number alteration discovery in cancer by exome sequencing.** *Genome Res.* 2012; **22**(3): 568–576.  
[PubMed Abstract](#) | [Publisher Full Text](#) | [Free Full Text](#)
5. O'Toole A: **Local Lineage and Monophyly Assessment.** 2021.  
[Reference Source](#)
6. Boshier FAT, Pang J, Penner J, *et al.*: **Remdesivir induced viral RNA and subgenomic RNA suppression, and evolution of viral variants in SARS-CoV-2 infected patients.** *Infectious Diseases (except HIV/AIDS).* 2020; Accessed 26 November 2020.  
[Publisher Full Text](#)
7. Lumby CK, Zhao L, Oporto M, *et al.*: **Favipiravir and Zanamivir Cleared Infection with Influenza B in a Severely Immunocompromised Child.** *Clin Infect Dis.* 2020; **71**(7): e191–e194.  
[PubMed Abstract](#) | [Publisher Full Text](#)
8. Strydom N, Gupta SV, Fox WS, *et al.*: **Tuberculosis drugs' distribution and emergence of resistance in patient's lung lesions: A mechanistic model and tool for regimen and dose optimization.** *PLoS Med.* 2019; **16**(4): e1002773.  
[PubMed Abstract](#) | [Publisher Full Text](#) | [Free Full Text](#)

# Open Peer Review

Current Peer Review Status: ?

---

## Version 1

Reviewer Report 07 January 2022

<https://doi.org/10.21956/wellcomeopenres.19213.r47484>

© 2022 Cohen J. This is an open access peer review report distributed under the terms of the [Creative Commons Attribution License](#), which permits unrestricted use, distribution, and reproduction in any medium, provided the original work is properly cited.

? Jonathan Cohen 

Paediatric Infectious Diseases and Immunology, Evelina London Children's Hospital, London, UK

This is a case of a child with a possible but undiagnosed immunodeficiency, bronchiectasis and bronchiolitis obliterans who develops severe COVID-19 pneumonitis. She required supportive care with extra-corporeal membrane oxygenation. Due to lack of improvement she received dual anti-viral therapy with nitazoxanide in addition to remdesivir, leading to recovery.

There is in vitro evidence of nitazoxanide having an antiviral effect against COVID-19. It is already used for giardiasis in children, and thus considered a potential drug for repurposing for COVID-19. Randomised controlled trials are yet to report on its efficacy in this context. There are no prior reports published to my knowledge of its use in this context in children.

An WGS analysis of several samples of the virus over time proves an additional level of interest highlighting the possibility of compartmentalisation within the lung with the potential (although not here) for the evolution of resistance when exposed to monotherapy.

### Minor points:

1. Was the primary immunodeficiency screening panel repeated, as several years had passed since the original analysis and annotations to the significance of variants may have changed?
2. You state "immunology had normalised" by 18 months - did this include function responses to vaccination?
3. Was she still receiving monthly pulsed steroid therapy at the time of this COVID-19 infection?
4. What dose of which corticosteroids were used in the early phase of treatment prior to requiring PICU?
5. Please provide the dose of remdesivir per kg.
6. Perhaps you can expand a bit further on the significance of compartmentalisation to clinical

practice. Which patients would benefit from dual therapy? Those with immunodeficiency who are at greater risk of delayed viral clearance?

**Is the background of the case's history and progression described in sufficient detail?**

Yes

**Are enough details provided of any physical examination and diagnostic tests, treatment given and outcomes?**

Yes

**Is sufficient discussion included of the importance of the findings and their relevance to future understanding of disease processes, diagnosis or treatment?**

Yes

**Is the case presented with sufficient detail to be useful for other practitioners?**

Yes

**Competing Interests:** No competing interests were disclosed.

**Reviewer Expertise:** Paediatric infection

**I confirm that I have read this submission and believe that I have an appropriate level of expertise to confirm that it is of an acceptable scientific standard, however I have significant reservations, as outlined above.**

---