

## Multiple Clinical Findings on The Tongue: Variants of Normal or Pathologic Condition? (A Case Report)

### Temuan Klinis Multipel pada Lidah: Variasi Normal atau Kondisi Patologis? (Sebuah Laporan Kasus)

Yurina Alhayu, Febrina Rahmayanti, Ambar Kusuma Astuti

Department of Oral Medicine,  
Faculty of Dentistry, Universitas Indonesia,  
Jl Salemba Raya no. 4, Jakarta 10430, Indonesia  
Corresponding email: febrina\_r@ui.ac.id

#### Abstract

A variety of normal and pathologic findings are occasionally found on the tongue and might confuse some patients and clinicians due to its atypical presentation. Therefore, this study aims to present a case of multiple oral findings related to variants of normal and pathological on the tongue including geographic and fissured tongue, as well as central papillary atrophy. A 53-year-old male patient came to Universitas Indonesia Dental Hospital for a dental check-up. The tongue examination showed depapillated areas surrounded by keratinized lining in the ventral and lateral left and right part of the tongue, multiple fissures over the dorsum, and an ovoid redness area in the middle of 2/3 posterior dorsum. All these findings were asymptomatic and were diagnosed as geographic and fissured tongue, as well as central papillary atrophy. Consequently, oral health professionals need to understand and recognize the normal anatomy, along with variants of normal and pathological lesions. Patients are then informed and educated about normal variations in the oral mucosa and related clinical findings to avoid unnecessary anxiety.

**Keywords:** central papillary atrophy, fissured tongue, geographic tongue, normal variations

#### Abstrak

Berbagai variasi normal maupun lesi patologis dapat ditemukan di lidah, namun sebagian besar pasien dan klinisi mengalami kebingungan karena adanya gambaran klinis yang tidak khas. Laporan kasus ini bertujuan untuk memaparkan beberapa tampilan di lidah yang berhubungan dengan variasi normal dan patologis, yakni *geographic tongue*, *fissured tongue* dan *central papillary atrophy*. Seorang laki-laki berusia 53 tahun datang ke RSKGM FKG UI untuk memeriksakan giginya. Pada pemeriksaan objektif ditemukan area depapilasi dikelilingi batas berkeratin pada ventral dan lateral lidah kiri dan kanan, fisur multipel di seluruh dorsum lidah, dan area merah oval pada 2/3 posterior dorsum lidah. Seluruh tampilan tersebut tidak bergejala. Diagnosis tampilan tersebut adalah *geographic tongue*, *fissured tongue* dan *central papillary atrophy*. Penting bagi profesional kesehatan gigi dan mulut untuk memahami dan mengenali anatomi normal, variasi normal dan keadaan patologis dari suatu tampilan klinis. Pasien harus diberikan informasi dan edukasi terkait variasi normal rongga mulut serta tampilan klinis terkait untuk menghindari kecemasan yang tidak diharapkan.

**Kata Kunci:** *central papillary atrophy*, *fissured tongue*, *geographic tongue*, variasi normal

## INTRODUCTION

Normal variations of oral healthy tissues are commonly found on the hard and soft palates, tongue, labial, as well as buccal mucosa. Although the locations are predictable for dentists, most people are not familiar with normal variations. In the oral cavity, the tongue is a visible organ that indicates certain systemic conditions, hence, a variety of normal and

pathologic lesions might incidentally be found on the tongue.<sup>1-3</sup>

There are numerous normal variations of the tongue, such as geographic (GT), fissured (FT), and hairy tongue, pigmented fungiform papillae, lateral lingual tonsil, oral varicosities, as well as the crenated and accessory tongue.<sup>1,2</sup> These lesions might be symptomatic, but most are often asymptomatic.<sup>1,3</sup> An

increase in oral cancer might also raise concern towards normal variations in some patients. Furthermore, people and clinicians sometimes misinterpret normal variations or abnormal lesions on the tongue because it might mimic oral cancer. Therefore, the identification of normal anatomy and information about patients' conditions are very important.<sup>4</sup>

Tongue investigation is an essential part of clinical examination, hence, clinicians need to identify certain disorders affecting the tongue.<sup>4</sup> The benign lesion needs to be well-identified because oral cancer is often found in the tongue,<sup>5</sup> hence, the diagnosis and treatment are required to be accurate. This study aims to present a case of a patient with multiple oral findings on the tongue including GT, FT, and central papillary atrophy (CPA) which are variants of normal and pathologic lesions.

## CASE

A 53-year-old male patient serving as a general aide in the government office came to Universitas Indonesia Dental Hospital for a dental check-up. The patient once consumed an alcoholic drink 20 years ago and has been smoking two packs of cigarettes per day for over ten years, but has gradually reduced the numbers. Recently, the patient realized that smoking potentially causes oral cancer and therefore wanted to check the mouth for any abnormalities. There was no complaint of pain in the mouth and the diet consists of regular consumption of vegetables, but infrequent fruits intake. Additionally, the hydration was poor with only four glasses of water per day and there was a history of systemic diseases and routine medications, while food or drugs allergies were denied.

In the extraoral examination, there was a palpable but not painful right submandibular lymph node, as well as brownish-black hyperpigmentation and dryness on the lip. Meanwhile, in the intraoral examination, there were depapillated areas surrounded by raised, white well-defined borders in the ventrolateral left and the right area of the tongue (Figure 1) with multiple fissures spreading over the dorsum and on the lateral left and right side, as well as an ovoid redness area on the middle 2/3 of the posterior dorsum (Figure 2). Furthermore, the saliva was bubbly and sticky, suspected as a sign of hyposalivation. All these findings were asymptomatic and diagnosed as geographic and fissured tongue, as well as central papillary atrophy, while the fear of having cancer was diagnosed as cancer phobia.

## CASE MANAGEMENT

The patient was informed about the mouth condition and then instructed to stop smoking imme-

diately. The effects of smoking such as dry mouth, fungal infection, cervical caries, as well as pigmentation on the mucosa and gingiva as a risk factor for malignancy were explained. Furthermore, Dental Health Education (DHE) was given including brushing the teeth and tongue with a soft brush without pressure at least two times a day in the morning and night before going to bed with a non-detergent toothpaste. DHE not only improves oral hygiene but also prevents plaque and debris stuck in tongue fissures which might cause halitosis. The patient was also instructed to increase the intake of water to at least 2L/day and eat at least 1 serving of fruit a day, to improve saliva quantity.

The tongue lesions, especially central papillary atrophy was treated by applying a sterile gauze wetted with 0.2% chlorhexidine gluconate 10 ml which has an antimicrobial and antifungal ability for 2-3 minutes 2 times a day for seven days. This antifungal was used to treat the asymptomatic CPA in addition to improving OH. Considering that GT and FT are variants of normal and asymptomatic findings, specific treatment was not needed. The patient was also instructed to frequently check complete blood count for screening any systemic condition such as anemia, allergies, and scheduled for the follow-up visit next week. Finally, the patient was assured that everything found in the oral cavity is not an indicator of malignancy, but a regular dental check-up every six months is needed. Unfortunately, the patient was unable to show up for the follow-up visit as there was a need to go out of town for an indefinite period in the office, hence, a referral for another dentist in the new town was made.

## DISCUSSION

The tongue is a multifunctional organ that facilitates the sensation of touch and taste as well as for chewing, speaking, swallowing, and self-cleansing.<sup>6,7</sup> It is accessible and easy to move, hence, clinicians are able to detect any oral lesion or variants of normal immediately. Meanwhile, the common presentation of benign oral pathology might mimic malignancy, and become a major concern for some patients.<sup>8</sup>

In this case report, the patient was concerned about all three benign lesions on the tongue and was informed about oral cancer through social media and the peer group. This is in line with Wimardhani *et al.* which reported that all smokers in Jakarta recognize that tobacco might increase oral cancer risk.<sup>9</sup> A survey conducted in Jakarta also showed that dentists' knowledge about oral cancer risk factors and diagnostic measures was very low.<sup>10</sup> Meanwhile, delayed diagnosis of cancer on the tongue potentially leads to

more advanced stages, extensive treatments, poorer survival, and greater psychological morbidity.<sup>11</sup>

A dentist needs to proficiently distinguish between variants of normal condition and disease in the oral cavity. Coleman *et al.* described the features of variants of normal conditions in the oral cavity.<sup>12</sup> They are located in bilateral symmetry with a wide range of unusual features and also have a predictable location, for example, a prominent ductus Stenson in the buccal mucosa. Majority of the normal tissue variations are asymptomatic,<sup>12</sup> while other features include independent findings, no altered tissue consistency, remain static, more prominent with increasing age. There are no empiric treatments for these types of lesions.<sup>13</sup>

Geographic tongue has numerous synonyms, including benign migratory glossitis, erythema, annulus, and glossitis areata migrans, as well as wandering rash of the tongue.<sup>1,4,13-16</sup> It is a chronic inflammatory condition illustrated by the loss of filiform papillae in the dorsal tongue that displays as red patches,<sup>17,18</sup> surrounded by raised, well-defined white borders.<sup>15,19</sup> Differential diagnoses of GT include candidiasis, leukoplakia, psoriasis, and drug reaction.<sup>16</sup> Since the patient admitted to not being allergic to drugs nor lesion on the skin, drug reaction and psoriasis were rule out.

The geographic tongue is usually located on the anterior two-thirds and rarely occurs on the ventrolateral surface.<sup>1</sup> The etiology is less understood, but several factors contribute to the pathogenesis. Some investigators do not fully regard GT as an anomaly of the tongue or hereditary in origin with a higher level of HLA-B15.<sup>16,20</sup> Previous studies showed that GT is connected with various systemic and psychological conditions such as anemia, Reiter's syndrome, emotional stress, diabetes, Down syndrome, allergies, and hormonal disturbances, while others reported the diseases as an oral manifestation of psoriasis.<sup>4,14,1,16,20</sup>

GT is common in young people and non-smokers because cigarette smoking plays a role in cytological alterations in the oral mucosa, including keratinization and cellular proliferation. Moreover, nicotine diminishes the intensity of anti-inflammatory mediators such as TNF- $\alpha$ , interleukin (IL)-1, and IL-6, which might lessen the progress of GT.<sup>15</sup> In this case, the patient was a middle-aged and active smoker. The predisposition of this condition is attributed to poor OH and decreased salivary flow,<sup>17</sup> which are bad effects from tobacco. Also, a complete blood count and blood glucose levels are needed to screen the possibility of GT symptoms such as anemia, diabetes, and allergies.

Most of the GT cases are asymptomatic, therefore, the treatment is reassurance, for example, when pa-

tients are disturbed by seasoned food, such food is recommended to be avoided. Meanwhile, when the patient feels discomfort, anti-fungal, topical corticosteroids, or analgesics might be prescribed to relieve the pain.<sup>14</sup> Furthermore, patients need to be informed of the benign character of GT. Patients is then recommended brushing the tongue with toothpaste and a soft toothbrush for 5-10 strokes after meals and before sleeping need to be instructed to avoid debris and bacteria accumulation in the fissures that potentially cause halitosis.<sup>1,14</sup>

Fissure tongue is characterized by grooves or fissures in the lateral and dorsal surfaces, and there is a strong correlation between GT and FT.<sup>1,15</sup> Majority of these conditions occurred at the same time.<sup>1</sup> FT is the most frequent tongue developmental defect, with 5-11,4% prevalence,<sup>4</sup> and occurs everywhere in the dorsal tongue, including the lateral margins.<sup>4,14</sup> It becomes normal as the person ages,<sup>4,1</sup> and certain associated conditions include Down syndrome, Sjogren's syndrome, acromegaly, psoriasis, GT, and Melkersson-Rosenthal syndrome.<sup>1,4,14</sup>

Central papillary atrophy (CPA) is a round-shaped, raised area with a smooth surface in the mid-dorsal tongue in front of the circumvallate papillae.<sup>2,4,21</sup> It usually feels normal or firm on palpation and mostly occurs three times in men compared to women.<sup>4,17,22</sup> Central papillary atrophy was formerly known as a developmental disorder of tongue formation. It is a persisting tuberculum impar that did not fuse completely with lateral lingual swelling during the tongue development, leading to a smooth, erythematous, and less papilla surface. Nowadays, CPA is considered a variant of candidiasis,<sup>22</sup> and a study reported that 90% of patients tend to have candida infection.<sup>4,23</sup> Therefore, chlorhexidine gluconate which has anti-fungal ability was used.<sup>24</sup>

Aside from the dorsal part of the tongue, a similar-appearing red lesion might also occur on the adjacent hard palate, termed "kissing lesion".<sup>23</sup> When such associated palatal inflammation occurs, immunosuppressive conditions are to be expected. It is a benign lesion that has no specific systemic association,<sup>4</sup> with male predilection three times more frequent than women<sup>4,22</sup> and a prevalence of 0.01%–1.0% of the population.<sup>22</sup>

The geographic tongue might be mildly painful, especially when consuming spiced foods, but most cases are asymptomatic,<sup>4</sup> while some clinicians or patients often confuse the condition for oral cancer. Furthermore, when there is a significant anxiety in a suspicious lesion, a biopsy might be indicated.<sup>14</sup> In this case, the patient had been informed about the benign nature of GT, FT, CPA and was encouraged to stop smoking as well as improve personal oral hygiene.

Since FT, GT, and CPA often look unfamiliar, patients and clinicians often become overly concerned about the “unusual” appearance. Therefore, oral health professionals need to understand and proficiently detect normal and variants of pathologic conditions in the tongue. The related conditions need to also be identified and managed, hence, oral health professionals are recommended to inform and edu-

cate patients about oral normal variations to avoid irrelevant anxiety.

#### ACKNOWLEDGEMENT

The authors are grateful to the Universitas Indonesia Dental Hospital (RSKGM FKG UI) for supporting the case management.

#### FIGURES

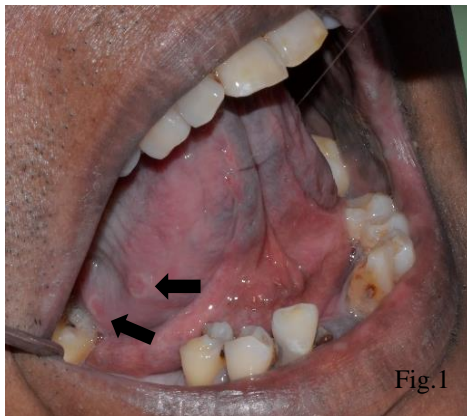


Figure 1. Geographic tongue on the ventrolateral border

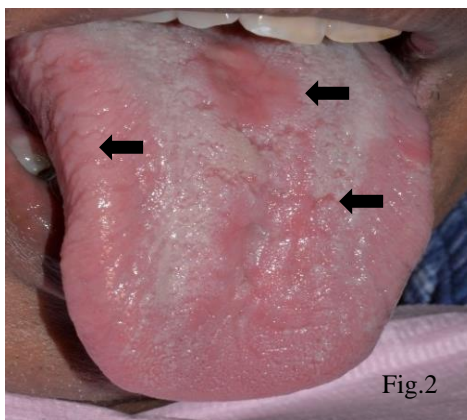


Figure 2. Multiple fissure tongue at the dorsum and lateral of the tongue; Central Papillary Atrophy.

#### REFERENCES

1. Madani FM, Kuperstein A. Normal variations of oral anatomy and common oral soft tissue lesions evaluation and management. *Med Clin NA*. 2019; 98(6): 1281-98.
2. Naik SM, S Ravishankara, Appaji M, MK G, Devi NP, Naik S. Congenital accessory tongue: a rare case of non syndromic tongue anomaly. *J Otolaryngology*. 2015; 5(1): 1-11.
3. Mangold AR, Torgerson RR, Iii RSR. Diseases of the tongue. 2019; 2016: 458-69.
4. Byrd JA, Bruce AJ, Rogers RS. Glossitis and other tongue disorders. *Dermatol Clin*. 2003; 21(1): 123-34.
5. Elimairi I, Sami A, Yousef B. Oral cancer and potentially malignant disorders. In: Srivastava S. *Histopathology*. London: Intech Open, 2016: 991-1339
6. Tagliabue M, Gandini S, Maffini F, et al. The role of the T-N tract in advanced stage tongue cancer. *Head Neck*. 2019; 41(8): 2756-67.
7. Shetty SS, Kudpaje A, Jayaraj R, Rao V, Shah PK. Tongue cancer: A discrete oral cavity subsite. *Oral Oncol*. 2019; 99: 1-2.
8. Azimi S, Ghorbani Z, Ghasemi E, Tennant M, Kruger E. Disparities in oral cancer awareness: a population survey in Tehran, Iran. *J Cancer Educ*. 2019; 34(3): 535-41.

9. Wimardhani YS, Warnakulasuriya S, Subita GP, Soegyanto AI, Pradono SA, Patoni N. Public awareness of oral cancer among adults in Jakarta, Indonesia. *J Invest Clin Dent*. 2018; 10(1): 1-8.
10. Wimardhani YS, Warnakulasuriya S, Wardhany II, Syahzaman S, Agustina Y, Maharani DA. Knowledge and practice regarding oral cancer: A Study Among Dentists in Jakarta, Indonesia. *Int. Dent. J.* 2021; 71(4): 309-15
11. Rakhmania H, Sufiawati I. Impact of delay on diagnosis and treatment of oral squamous cell carcinoma: Three cases report. *J Int Dent Med Res*. 2017; 10(3): 1017-20.
12. Coleman GC, Nelson JF. Principles of oral diagnosis. 1st ed., St Louis: CV Mosby Co, 1993: 271-3.
13. Aghel S, Esfehiani M, Zarabadipour Met al. The frequency of normal variations of oral mucosa in patients referred to Qazvin School of Dentistry, Spring, 2015. *Internat. J. of Ayurv. Med.* 2018; 9(1): 34-8.
14. Rogers RS, Bruce AJ. The tongue in clinical diagnosis. *J Eur Acad Dermatology Venereol*. 2004; 18(3): 254-59.
15. Dafar A, Robledo-sierra J, Mattsson ULF, Jontell M. Factors associated with geographic tongue and fissured tongue. 2016;(May 2015):210-6.
16. Kumar D, Das A, Gharami RC. Benign Migratory Glossitis. *Indian Pediatric*. 2013; 50: 1178.
17. Scariot R, Beltrami T, Batista D, et al. Host and clinical aspects in patients with benign migratory glossitis. *Arch Oral Biol*. 2017; 73: 259-68.
18. Dafar A, Bankvall M, Çevik-Aras H, Jontell M, Sjöberg F. Lingual microbiota profiles of patients with geographic tongue. *J Oral Microbiol*. 2017; 9(1): 1355206.
19. Singh Bakshi S, Bhattacharjee S, Pondicherry B. Image in allergy geographic tongue. *J Allergy Clin Immunol Pract*. 2017; 5(1): 176.
20. Mirza D, Qureshi NR, Naqvi K. Benign migratory glossitis an unusual enigmatic lesion 2. 2013;3 3(3): 470-3.
21. Jahanbani J, Morse DE, Alinejad H. Prevalence of oral lesions and normal variants of the oral mucosa in 12 to 15-year-old students in Tehran, Iran. *Arch. Iran Med*. 2012; 15(3): 142-6.
22. Surboyo MD, Ernawati DS, Parmadiati AE. Glossitis mimicking median rhomboid glossitis induced by throat lozenges and refreshment candies. *J Int Oral Health* 2019; 11: 323-8.
23. Yarom N, Cantony U, Gorsky M. Prevalence of fissured tongue, geographic tongue and median rhomboid glossitis among Israeli adults of different ethnic origins. *Dermatology* 2004; 209: 88-94.
24. Fathilah AR, Himratul-Aznita WH, Fatheen ARN, Suriani KR. The antifungal properties of chlorhexidine digluconate and cetylpyridinium chloride on oral *Candida*. *J Dent*. 2012; 40(7) :609-15.