

Bezold-Jarisch Reflex Induced by Dopamine during Isoflurane Anesthesia in Small Dogs

Sang Yub Oh^{ORCID}, Soonpil Hwang^{ORCID}, Hyuk Soo Seo^{ORCID}, Seungju Lee^{ORCID} & Hwi-Yool Kim^{ORCID}

ABSTRACT

Background: Unlike other major reflexes contributing to hemodynamic homeostasis, the Bezold-Jarisch reflex (BJR) paradoxically decreases heart rate (HR) and mean arterial pressure (MAP) despite hypotension. In the veterinary field, there are few reported cases of BJR induced by dopamine, which is often used to manage hypotension. Herein, 2 cases involving small dogs exhibiting BJR due to dopamine infusion during general anesthesia are described.

Cases: *Case 1:* A 7-year-old, 7 kg, mongrel was referred for external skeletal fixator removal. The patient was premedicated with 0.3 mg/kg midazolam and 0.2 mg/kg butorphanol intravenously (IV). General anesthesia was induced with 6 mg/kg propofol and maintained with 1.6% isoflurane in oxygen. The patient was given 5 mL/kg/h of Hartmann's solution IV. The respiratory rate (RR) was set to 9 breaths/min with a ventilator. The HR and MAP values were initially 120 bpm and 76 mmHg and gradually decreased to 70 bpm and 40 mmHg, respectively. The end-tidal CO₂ partial pressure (ETCO₂) was 39 mmHg, and the patient was administered 2.5 µg/kg glycopyrrolate IV. Then, 5 µg/kg/min dopamine was administered IV since the MAP did not improve. The HR, MAP, and ETCO₂ increased to 113 bpm, 72 mmHg, and 47 mmHg, respectively. Subsequently, HR and MAP dramatically decreased to 50 bpm and 43 mmHg, respectively. A second-degree atrioventricular block was detected, prompting dopamine infusion discontinuation, and 2.5 µg/kg glycopyrrolate was again administered IV. Within 5 min, HR and MAP values normalized, and postoperative patient recovery was typical. *Case 2:* A 2-year-old, 8.6 kg, mongrel underwent surgery to correct a medial luxating patella of the right leg. The patient was premedicated with 0.3 mg/kg midazolam and 0.2 mg/kg butorphanol IV. Anesthesia was induced with 4 mg/kg propofol IV and maintained with 3% isoflurane in oxygen; 10 mL/kg/h of Hartmann's solution was administered IV. Within 15 min, the patient's HR and MAP values decreased from 120 to 107 bpm and 73 to 50 mmHg, respectively. The ETCO₂ remained approximately 39 mmHg, and RR decreased from 20 to 17 breaths/min. Dopamine was infused at a rate of 5 µg/kg/min. After 10 min, the MAP slightly increased from 50 to 57 mmHg, but the HR dramatically decreased from 107 to 62 bpm and the RR also dropped to 12 breaths/min. Further, a second-degree atrioventricular block was observed. Dopamine infusion was immediately discontinued, and 2.5 µg/kg glycopyrrolate was injected IV. As the HR returned to 94 bpm, the atrioventricular block disappeared, and the RR increased to 15 breaths/min. After general anesthesia was terminated, the patient recovered well.

Discussion: Among drugs used for anesthesia, propofol and isoflurane may lower the MAP and HR. Therefore, HR or MAP decreases at the beginning of anesthesia are likely due to the drugs. Considering half-life, it is unlikely that propofol provoked sudden HR or MAP decreases at about 25 min post-induction. Isoflurane may also be ruled out since the hemodynamic disorder depended on dopamine injection. Sudden decreases in the HR, MAP, or RR after dopamine injection are not generally expected dopaminergic or adrenergic responses, which likely occur due to the vagal cardiopulmonary reflex suggesting the BJR resulting from activation of cardiac mechano- or chemoreceptors. To the best of our knowledge, there have been no reports of dopamine-mediated BJR in young or middle-aged, small dogs. The BJR has been observed in older, larger dogs and humans. In the patients described, body condition score may be considered when estimating the cause of the BJR. Since they scored 8/9, it is possible that obesity increased the risk of the BJR. This report described the clinical features and treatment outcomes in young or middle-aged, obese, small-sized dogs, whose hypotension or bradycardia was exacerbated by dopamine.

Keywords: Bezold-Jarisch reflex, dopamine, hypotension, bradycardia, canine.

DOI: 10.22456/1679-9216.117344

Received: 17 September 2021

Accepted: 10 December 2021

Published: 25 January 2022

Department of Veterinary Surgery, College of Veterinary Medicine and Veterinary Teaching Hospital, Konkuk University, Seoul, Republic of South Korea. CORRESPONDENCE: H.Y. Kim [hykim@konkuk.ac.kr]. Department of Veterinary Surgery, College of Veterinary Medicine and Veterinary Teaching Hospital - Konkuk University, 120 Neungdong-ro, Gwangjin-gu, Seoul, Republic of South Korea.

INTRODUCTION

The major reflexes that control the cardiovascular system include the baroreflex, Bainbridge reflex, and Bezold-Jarisch reflex (BJR) [2,5]. Unlike other reflexes contributing to hemodynamic homeostasis, the BJR paradoxically decreases heart rate (HR) and blood pressure (BP) despite hypotension [2,5]. Type C vagal fibers, which are responsive to mechanical or chemical stimuli to ventricle, are known to cause the BJR [2,5]. In the veterinary field, there are reports of the BJR being provoked via the stimuli in dogs [3,6,7,10,17]. However, there have been few reported cases of the BJR induced by dopamine administration [3,17], which is commonly used to manage hypotension. This is a report of 2 cases involving small dogs who experienced a dopamine-induced BJR during general anesthesia.

CASES

Case 1. A 7-year-old, 7.0 kg, spayed female mongrel was referred to the Konkuk Veterinary Medical Teaching Hospital, Seoul, South Korea for the removal of the external skeletal fixator due to delayed union after external skeletal fixation of a right femoral fracture (Figure 1A). Physical examination revealed a body condition score (BCS) of 8/9 and American Society of Anesthesiologists (ASA) class II. Preanesthetic assessments, including physical and blood examinations [complete blood cell count (CBC), serum chemistry, and electrolytes], were performed. With the exception of the existence of thrombocytosis [710,000/ μ L; reference range: 148,000-484,000/ μ L], all parameters assessed were within the normal range. After preoperative hydration with Hartmann's solution, the patient was premedicated with midazolam¹ [Midazolam[®] - 0.3 mg/kg IV] and butorphanol² [Butophan[®] - 0.2 mg/kg IV]. A total dose of 6 mg/kg propofol³ (Anepol[®]) was administered IV to induce anesthesia, which was then maintained with 1.6% isoflurane in 1.7 L/min oxygen. A lumbosacral epidural block was not performed due to the patient's obesity. After induction of anesthesia, the dog received cefazolin⁴ [Cefozol[®] - 20 mg/kg] and 5 mL/kg/h of Hartmann's solution IV. A multi-parameter veterinary monitor⁵ (V10[®]) revealed a HR of 120 beats/min and non-invasive systolic, diastolic, and mean arterial pressures (SAP, DAP, and MAP, respectively) of 105, 62, and 76 mmHg, respectively (Figure 2A). The patient's respiratory rate (RR) was set to 9 breaths/min using a ventilator. After that, for

20 min, the HR gradually decreased to 70 beats/min and the SAP, DAP, and MAP values decreased to 69, 26, and 40 mmHg, respectively. Therefore, the patient was medicated with glycopyrrolate² [Mobinul[®] - 2.5 μ g/kg IV] in order to improve the HR and BP. Due to the patient's lack of BP improvement, dopamine⁶ [Dopamine[®] - 5 μ g/kg/min IV] was added. Ten min after glycopyrrolate² injection, the HR and MAP values increased to 113 beats/min and 72 mmHg, respectively, while peripheral capillary oxygen saturation (SpO₂) was stable, at 99%, and the end-tidal CO₂ partial pressure (ETCO₂) rose from 39 to 47 mmHg. However, the HR and MAP values subsequently decreased to 50 beats/min and 43 mmHg, respectively. The ETCO₂ also fell to 40 mmHg. A second-degree atrioventricular block with a prolonged PR interval (Mobitz type I) was detected on electrocardiogram (ECG). As a result, dopamine⁶ infusion was discontinued immediately, and glycopyrrolate² [Mobinul[®] - 2.5 μ g/kg IV] was again administered IV to manage bradycardia. After 5 min, the HR and MAP values returned to 90 beats/min and 69 mmHg, respectively. The surgery was completed without complications, and the patient showed a normal postoperative recovery.

Case 2. A 2-year-old, 8.6 kg, castrated male mongrel underwent surgical correction of grade 2 medial patellar luxation of the right leg (Figure 1B). Physical examination revealed a BCS of 8/9 and ASA class I. Physical and hematological examinations (CBC, serum chemistry, and electrolytes) revealed normal findings, except for mild neutrophilia (14,770/ μ L; reference range: 2,950-11,640/ μ L) and leukocytosis (17,990 cells/ μ L; reference range: 5,050-16,760/ μ L). After preoperative hydration with Hartmann's solution, the patient was premedicated with midazolam¹ [Midazolam[®] - 0.3 mg/kg IV]. Ten min later, butorphanol² [Butophan[®] - 0.2 mg/kg IV] was administered. Anesthesia was induced with propofol³ [Anepol[®] - 4 mg/kg IV] and maintained with 3% isoflurane in 1.5 L/min oxygen. An epidural block was not performed due to the patient's obesity. A prophylactic antibiotic⁴ [cefazolin - 20 mg/kg] and Hartmann's solution were administered IV at a rate of 10 mg/kg/h. Vital signs, including the HR, ETCO₂, and MAP, were monitored using a multi-parameter veterinary monitor⁵. Fifteen min post-induction of anesthesia, the HR declined from 120 to 107 beats/min, and the SAP, MAP, and DAP declined from 97, 73, and 61 to 72, 50, and 39

mmHg, respectively (Figure 2B). While the ETCO_2 remained 39 mmHg, the patient's spontaneous RR decreased from 20 to 17 breaths/min. In consideration of sufficient fluid supply maintenance, dopamine⁶ was infused at a rate of 5 $\mu\text{g}/\text{kg}/\text{min}$ to raise the BP. After 10 min, the MAP slightly increased from 50 to 57 mmHg. However, the HR dramatically decreased from 107 to 62 beats/min, and the patient's RR fell from 17 to 12 breaths/min. Furthermore, ECG revealed a second-degree atrioventricular block with a prolonged PR interval (Mobitz type I) [Figure3]. Resultingly, the dopamine⁶ infusion was immediately discontinued, and glycopyrrolate² [Mobinul[®] - 2.5 $\mu\text{g}/\text{kg}$ IV] was injected with Hartmann's solution at a rate of 12 mL/kg/h. As the patient's HR returned to 94 beats/min, the atrioventricular block disappeared, the waveform on ECG normalized, and the RR increased to 15 breaths/min. Because MAP values remained at around 60 mmHg, intravenous fluid/isoflurane settings were changed to 13 mL/kg/h and 2%, respectively, which increased the MAP up to 81 mmHg. SpO_2 remained > 98% throughout the anesthesia. To augment MAP, dopamine⁶

infusion was tried again 40 min after it was initially attempted. After 10 min, the HR dropped from 100 to 75 beats/min and a second-degree atrioventricular block was noted. Discontinuation of the infusion without glycopyrrolate injection was sufficient to normalize the vital signs. General anesthesia was terminated, and the patient was admitted to the intensive care unit for postoperative recovery.

DISCUSSION

Both the BJR and the reverse-Bainbridge reflex may reduce the HR and BP, but they are difficult to distinguish in clinical situations [5]. However, since the BJR is more likely to occur due to β -adrenergic stimulation via chemoreceptors [2,5,18], the mechanism underlying HR or BP reductions in both cases described was assumed to be the BJR. The BJR is believed to alleviate ischemic cardiac damage from excessive myocardial contractions versus ventricular filling, such as severe hemorrhage [2]. In both cases, hypovolemia was excluded because the patients underwent preoperative hydration and less-bleeding




Figure 1. Pictures of the patients. A- A 7-year-old, 7.2 kg, spayed female mongrel (Case 1). B- A 2-year-old, 8.6 kg, castrated male mongrel (Case 2).

surgery. Among drugs used for anesthesia, propofol and isoflurane have the potential to significantly reduce the BP or HR [8]. Therefore, decreases in the HR or MAP at the beginning of anesthesia are thought to be due to use of the drugs. However, considering the half-life of propofol, it is unlikely that it caused the sudden decrease in the HR or MAP that was observed at about 25 min post-induction [8]. Isoflurane was also ruled out because the hemodynamic disorder observed depended on dopamine administration. Measurement of end-tidal isoflurane levels would have allowed for a more detailed evaluation of each patient.

Dopamine is an endogenous catecholamine that is commonly used as a positive inotrope and vasopressor in veterinary practice. Dopamine activates dopaminergic, α 1-adrenergic, and β -adrenergic receptors in a dose dependent manner [13,16]. In isoflurane-anesthetized healthy dogs, $> 10 \mu\text{g/kg/min}$ dopamine increases the MAP and HR values by activating α 1- and β -adrenergic receptors, respectively [13,16]. However, since plasma dopamine levels within individuals administered the same dosage are inconsistent [1], the patients were administered $5 \mu\text{g/kg/min}$ rather than $10 \mu\text{g/kg/min}$ dopamine. A sudden decrease in the HR or MAP was observed after dopamine injection, which was not a generally expected dopaminergic or adrenergic response. As a result, $10 \mu\text{g/kg/min}$ dopamine was not attempted. The activation of dopaminergic receptors is known to induce local vasodilation, but does not significantly affect the systemic MAP [16]. A cardiac mechanoreceptor or chemoreceptor seemed to be activated, which resulted in the BJR. A comparison of the second patient, who experienced a dopamine-mediated HR change exclusively, to the first showed independent modulation of the BP and HR by the BJR [2]. In the second case, the BJR was confirmed when isoflurane levels were reduced and dopamine infusion was attempted again. Hence, it was assumed that the BJR was caused by dopamine. No direct relationship between the BJR and the thrombocytosis observed in *Case 1* or neutrophilia observed in *Case 2* was identified.

Vagal C-fiber stimulation induces the BJR, which down-regulates the HR, BP, and RR [5]. In the patient who underwent surgery with spontaneous breathing, the RR changed in accordance with dopamine administration, which was thought to be due to the vagal cardiopulmonary reflex. The ETCO_2 values remained relatively stable despite the reduced HR and BP values due to the reduction of ventilation per minute. In the first patient (*Case 1*), RR maintenance with a ventilator caused the ETCO_2 fluctuations in accordance with cardiovascular changes.

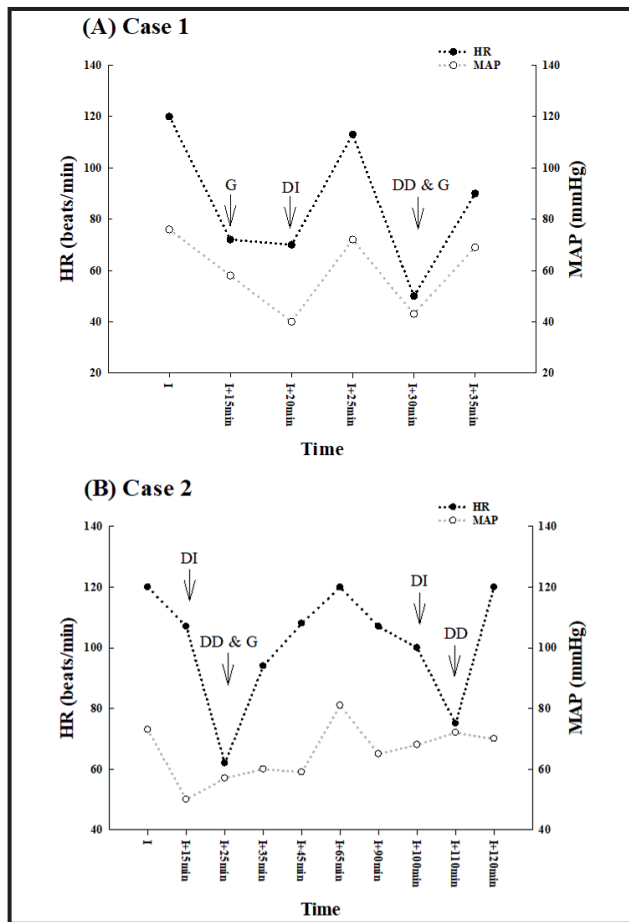


Figure 2. HR and MAP of patients during anesthesia. A- In the first patient, glycopyrrrolate and dopamine were administered to improve HR and MAP. B- In the second patient, glycopyrrrolate and dopamine were given to raise HR and MAP. Dopamine was used again before the surgery was finished. Abbreviations: I: induction; G: glycopyrrrolate injection; DI: dopamine infusion; DD: dopamine discontinuation.

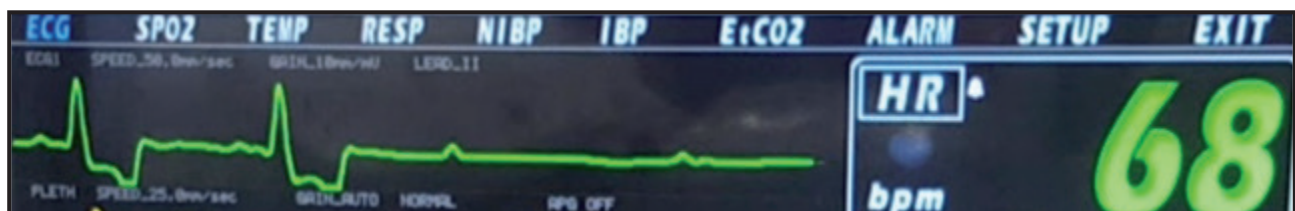


Figure 3. Mobitz type I atrioventricular block in the second patient.

Anticholinergics or inotropes such as dopamine can be used to treat bradycardia or hypotension [8]. Furthermore, anticholinergics are useful for improving hemodynamic disorders caused by the BJR [2,5,17]. In the patient (*Case 1*) who received glycopyrrolate and dopamine injections almost simultaneously, a dopamine-induced BJR was observed despite the inhibitory effect of low-dose glycopyrrolate on vagal action [12]. Therefore, it can be concluded that low-dose glycopyrrolate administration is insufficient for blocking vagal action caused by the BJR [15]. Based on the first case, dopamine infusion was halted in the second patient (*Case 2* - aged 2-year-old) who showed bradycardia, and glycopyrrolate was subsequently administered to stabilize vital values. Glycopyrrolate was used preferentially because it is less arrhythmogenic and has lesser effects on the central nervous system than atropine [8,15].

To the best of our knowledge, there have been no reports of dopamine-mediated BJR in young or middle-aged, small-sized dogs. Two cases of dopamine-induced BJR has been previously described in middle-aged and older dogs, which were medium- to large-sized [3,17]. In human medicine, a retrospective study on intradialytic hypotension due to the BJR showed that the mean age of patients was 50.1 years [14]. As described above, the BJR is commonly reported in middle-aged to elderly people or dogs possibly due to ventricular filling reductions that occur with aging [4]. In fact, one month after surgery, echocardiography of the first patient (*Case 1* - aged 7-year-old) revealed indicators of mild relaxation dysfunction associated with reduced ventricular filling. In the veterinary field, large-sized dogs are more predisposed to ventricular filling disorders such as dilated cardiomyopathy than

small dogs [9]. This is likely one of the reasons there have been few reports of the BJR in small dogs. The BCS of each patient described herein likely contributed to the BJR, because both had a BCS of 8/9, which possibly indicates that obesity increased the BJR risk. Obesity causes volume and pressure overload, which interferes with ventricular filling [11]. However, the clinical significance of the correlation between obesity and BJR development remains to be studied further. This report has limitations in that end-tidal isoflurane level was not measured and the effect of obesity on the development of BJR was not experimentally confirmed.

In summary, this report describes the clinical features and treatment outcomes in young or middle-aged, obese, small dogs, whose hypotension or bradycardia was exacerbated by dopamine administration. While dopamine-induced BJR has rarely been documented in dogs, especially those that are small sized, this phenomenon should be considered when dopamine is administered to patients under general anesthesia.

MANUFACTURERS

¹Bukwang Pharmaceutical Co. Ltd. Seoul, Republic of South Korea.

²Myungmoon Pharm. Co. Ltd. Seoul, Republic of South Korea.

³Hana Pharm Co. Ltd. Seoul, Republic of South Korea.

⁴Hankook Korus Pharm Co. Ltd. Seoul, Republic of South Korea.

⁵Votem Co. Ltd. Chuncheon, Gangwon, Republic of South Korea.

⁶Huons Co. Ltd. Seongnam, Gyeonggi, Republic of South Korea.

Acknowledgments. We thank Bong Han Kim (Maris Animal Medical Center) for providing resource of this case report. And the report was supported by the Cooperative Research Program of the Center for Companion Animal Research (Project No. PJ013951), Rural Development Administration, Republic of South Korea.

Declaration of interest. The authors report no conflicts of interest. The authors alone are responsible for the content and writing of the paper.

REFERENCES

- 1 Barter L.S. & Pypendop B.H. 2020. Plasma dopamine concentrations following dopamine infusion to isoflurane-anesthetized New Zealand White rabbits. *Veterinary Anaesthesia and Analgesia*. 47(2): 219-223.
- 2 Campagna J.A. & Carter C. 2003. Clinical relevance of the Bezold-Jarisch reflex. *Anesthesiology*. 98(5): 1250-1260.
- 3 Carvalho E.R., Garafalo N.A., Giroto C.H. & Teixeira Neto F.J. 2018. Hypotension aggravated by dopamine in a dog under isoflurane anesthesia. *Acta Scientiae Veterinariae*. 46(Suppl 1): 246. 6p.
- 4 Chiao Y.A. & Rabinovitch P.S. 2015. The Aging Heart. *Cold Spring Harbor Perspectives in Medicine*. 5(9): a025148.
- 5 Crystal G.J. & Salem M.R. 2012. The Bainbridge and the “reverse” Bainbridge reflexes: history, physiology, and clinical relevance. *Anesthesia & Analgesia*. 114(3): 520-532.
- 6 Davis J., Rasis A.L., Haitjema H., Drynan E.A. & Hosgood G.L. 2017. Paradoxical bradycardia during surgical caudal vena cava occlusion in an anesthetized dog. *Journal of Veterinary Emergency and Critical Care*. 27(2): 243-249.

- 7 Hofmeister E.H., Keenan K. & Egger C.M. 2005. Dobutamine-induced bradycardia in a dog. *Veterinary Anaesthesia and Analgesia*. 32(2): 107-111.
- 8 Ko J.C. 2018. Preanesthetic medication., Intravenous injection techniques and intravenous anesthetic agents., Anesthesia monitoring and management. In: Ko J.C. (Ed). *Small Animal Anesthesia and Pain Management*. 2nd edn. Boca Raton: CRC Press, pp.63-133.
- 9 Mansilla W.D., Marinangeli C.P.F., Ekenstedt K.J., Larsen J.A., Aldrich G., Columbus D.A., Weber L., Abood S.K. & Shoveller A.K. 2019. Special topic: The association between pulse ingredients and canine dilated cardiomyopathy: addressing the knowledge gaps before establishing causation. *Journal of Animal Science*. 97(3): 983-997.
- 10 McMillan M.W., Aprea F. & Leece E.A. 2012. Potential Bezold-Jarisch reflex secondary to a 180° postural change in an anaesthetized dog. *Veterinary Anaesthesia and Analgesia*. 39(5): 561-562.
- 11 Ortega-Loubon C., Fernández-Molina M., Singh G. & Correa R. 2019. Obesity and its cardiovascular effects. *Diabetes/Metabolism Research and Reviews*. 35(4): e3135.
- 12 Ramsey I. 2011. Glycopyrronium. In: Ramsey I. (Ed). *BSAVA Small Animal Formulary*. 7th edn. Gloucester: BSAVA, p.161.
- 13 Rosati M., Dyson D.H., Sinclair M.D. & Sears W.C. 2007. Response of hypotensive dogs to dopamine hydrochloride and dobutamine hydrochloride during deep isoflurane anesthesia. *American Journal of Veterinary Research*. 68(5): 483-494.
- 14 Schroeder K.L., Sallustio J.E. & Ross E.A. 2004. Continuous haematocrit monitoring during intradialytic hypotension: precipitous decline in plasma refill rates. *Nephrology Dialysis Transplantation*. 19(3): 652-656.
- 15 Singh S., McDonnell W., Young S. & Dyson D. 1997. The effect of glycopyrrolate on heart rate and intestinal motility in conscious horses. *Veterinary Anaesthesia and Analgesia*. 24(1): 14-19.
- 16 Tobata D., Takao K., Mochizuki M., Nishimura R. & Sasaki N. 2004. Effects of dopamine, dobutamine, amrinone and milrinone on regional blood flow in isoflurane anesthetized dogs. *Journal of Veterinary Medical Science*. 66(9): 1097-1105.
- 17 Tsompanidou P.P., Kazakos G.M. & Anagnostou T.L. 2013. Dopamine-induced bradycardia in two dogs under isoflurane anaesthesia. *Journal of Small Animal Practice*. 54(12): 672-674.
- 18 Waxman M.B., Asta J.A. & Cameron D.A. 1994. Vasodepressor reaction induced by inferior vena cava occlusion and isoproterenol in the rat. Role of β_1 - and β_2 -adrenergic receptors. *Circulation*. 89(5): 2401-2411.