

THE STUDY OF FREE RADICALS TO EVALUATE THE HEALING EFFECTS OF *PUNICA GRANATUM* PEEL ON ACETIC ACID-INDUCED COLITIS IN RATS

ARPIT VERMA¹, MANI GOEL², SATYENDRA PRAJAPATI³, ANAND BHADKARIYA^{4*}

¹Department of Pharmacology, Government Medical College, Datia, Madhya Pradesh, India. ²Department of Pharmacology, Maharani Laxmi Bai Medical College, Jhansi, Uttar Pradesh, India. ³Department of Physiology, Government Medical College, Datia, Madhya Pradesh, India. ⁴Department of Pathology, Government Medical College, Datia, Madhya Pradesh, India. Email: anandbhadkaria@gmail.com

Received: 04 November 2021, Revised and Accepted: 14 December 2021

ABSTRACT

Objective: The objective of the study was to analyze the effect of 50% ethanolic extract of the dried *Punica granatum* peel (PGE) on the healing of acetic acid-induced colitis in rats.

Methods: Colitis was induced in rats using 50% acetic acid and then PGE extract was administered by oral route daily for 14 days to those rats. Optimal healing was observed by the administration of a 100 mg/kg dose of PGE extract. Effectiveness of the above-mentioned dosage of PGE on biochemical parameters, basically free radicals – nitric oxide and lipid peroxidation was studied on 18 hours fasting rats on the 15th day of the experiment.

Results: The results were suggestive of the healing properties of PGE extract by reduction of the inflammation and mucosal damage in the colon of those rats. The healing effects were established by the estimation and study of free radicals taken from the mucosal samples of the rat's colon. The safety of extract was established by the effective administration of 10 times the therapeutic dose, that is, 1000 mg/kg dosage of the PGE extract with no noticeable adverse effects or side effects related to ANS or central nervous system.

Conclusion: PGE extract was found to be effective in healing mucosal damage due to colitis by controlling the infection and reducing the inflammation.

Keywords: Ulcerative Colitis, *Punica granatum* peel extract, Acetic acid, Sulfasalazine, free radicals.

© 2022 The Authors. Published by Innovare Academic Sciences Pvt Ltd. This is an open access article under the CC BY license (<http://creativecommons.org/licenses/by/4.0/>) DOI: <http://dx.doi.org/10.22159/ajpcr.2022v15i1.43894>. Journal homepage: <https://innovareacademics.in/journals/index.php/ajpcr>

INTRODUCTION

Ulcerative colitis (UC) is a chronic, inflammatory disease of the colon which affects the innermost lining of the intestines. The condition leads to inflammation, sores or ulcers, and bleeding in the gastric mucosal lining. Symptoms include a liberal loosening of the stool, abdominal cramps, rectal bleeding, and loss of appetite that result in nutrient deficiencies, weight loss, and anemia [1]. A combination of genetic, microbial, and environmental factors that influence the normal intestinal microbiota is considered responsible to trigger a pathological immune response resulting in mucosal damage. Genetic and environmental factors are also thought to play some role, the exact cause is still not clear. The pathological findings associated with UC are an increase in certain inflammatory mediators, signs of oxidative stress, a deranged colonic milieu, abnormal glycosaminoglycan (GAG) content of the mucosa, decreased oxidation of the short chain fatty acids (SCFAs), increased intestinal permeability, increased sulphide production and decreased methylation [2,3]. Chronic inflammation, infection, or immune imbalance increase the production of ROS and impair antioxidant defenses, resulting in intestinal oxidative injury in UC patients [4].

Punica granatum plant commonly known as the pomegranate is a striking shrub or small tree growing 6–10 m high with multiple spiny divisions. The edible fruit is a berry and is 5–12 cm in diameter with a rounded shape and thick reddish casing (peel). In the Indian subcontinent's ancient Ayurveda system of medicine, the pomegranate has extensively been used as a source of traditional remedies and is considered as a pharmacy in itself. It is used as an antiparasitic go-between, hemostatic, antibacterial, antifungal, antiviral, and as a remedy for cut wounds, a blood tonic, an eye drop, and to heal ulcers. The peel of the fruit is used to treat diarrhea, dysentery, and intestinal parasites. The astringent makings of the flower juice, peel, and tree bark are considered valuable for a variety of purposes, such as toning skin, firming up sagging breasts,

and treating hemorrhoids. In South Anatolia, Turkey, some people employ the ruins of the fruit peel as protective against skin contagion. The plant extract has been exposed to possess anti-inflammatory activity, anti-cancer activity [5], and anti-spermatogenic effect. It is extremely valued for its neuroprotective property in stress-induced neurodegeneration like Alzheimer's disease [5]. It has an anti-atherogenic effect and demonstrates hypoglycemic activity in diabetic rats.

The present study was undertaken to evaluate the healing effects of 50% ethanol extract of *Punica granatum* peel (PGE) in acetic acid-induced colitis in rats.

METHODS

Animals

Inbred Charles-Foster albino rats (160–180 g) and mice (25–30 g) of either sex were obtained with permission from the central animal house of the Institute of Medical Sciences, Banaras Hindu University, Varanasi. They were kept in the departmental animal house at 26 ± 2°C and relative humidity 44–56%, light and dark cycles of 10 and 14 h, respectively, for 1 week before and during the duration of experiments. Animals were provided with a standard rodent pellet diet (Pashu Aahar, Ramnagar, and Varanasi) and water *ad libitum*. Principles of laboratory animal care (NIH publication no. 82–23, revised 1985) guidelines were followed. Approval from the Institutional Animal Ethical Committee was taken before the initiation of experimental work (Notification no.: Dean/12-13/CAEC/10 dated January 11, 2013).

Plant material and preparation of extract

The whole plant of *Punica granatum* was collected in the months of September–November from the Ayurvedic Gardens of Banaras Hindu University. The peel was dried in shade and blended to form a fine powder and used. About 50% ethanolic extract of PG (PGE) was

prepared by adding 200 g of dried fine powder of PG peel in 1000 ml of ethanol (500 ml) and distilled water (500 ml) mixture. The mixture was shaken at regular intervals and the extract so obtained was filtered after a gap of 2 days. PGE so obtained each time was mixed and later dried at 40°C in the incubator. The yield was about 20% (w/w). PGE was stored at -20°C until further use.

Drug and chemicals

Sulfasalazine (TAB. SALAZAR 500 mg by Zydus Cadila), acetic acid, and all the other chemicals and reagents that were used were of analytical grade.

Chemicals

Estimation of protein

- Alkaline preparation – 50 ml alkaline reagent+0.5 ml of 4% sod. Pot. Tartrate+0.5 ml of 2% copper sulfate.
- Alkaline reagent – 2 g of sodium bicarbonate+100 ml of 0.1 N NaOH.
- Phenol reagent – 5 ml of phenol+5 ml of distilled water.

Estimation of free radical

Lipid peroxidation (LPO)

- 8.1% Sodium dodecyl sulfate (SDS) (Sigma) – 8.1% solution was prepared by dissolving 810 mg of SDS in 10 ml distilled water.
- 20% Acetic acid (E. Merck) – a 20% solution was made by adding 20 ml of acetic acid to 80 ml of distilled water. The pH of the solution was adjusted to 3.5 by adding NaOH. This was prepared fresh before use.
- 0.8% Thiobarbituric acid (Sigma) – 0.8% TBA was prepared by dissolving 800 mg thiobarbituric acid in 100 ml of distilled water.
- Butanol and pyridine mixture (15:1) (E. Merck) – 15 ml of n-butanol was mixed with 1 ml of pyridine.
- 1, 1, 3, 3-tetramethoxy propane (Sigma) was used as a standard for LPO estimation.

Nitric oxide (NO):

- Griess reagent (Sigma, catalog # G4410)
- Vanadium chloride (VCl₃, E. Merck) saturated solution of VCl₃ by dissolving 400 mg in 506 ml of 1M HCl.
- Sodium nitrite (E. Merck) was used to prepare a standard curve for the estimation of NO.

Induction of colitis and treatment protocol

Experimental colitis was produced by intracolonic administration of acetic acid (10%, 0.20 ml/100 g rat) given per rectally [6]. A dose-response study was first undertaken with 50% ethanol extract of PGE (50, 100, and 200 mg/kg) when given orally for a period of 14 days after the induction of UC with acetic acid, and on the 15th day of the experiment, the healing effect was studied by the estimation of free radicals – NO and LPO on the 15th day of the experiment in 18 h fasting rats. The animals were sacrificed on the 15th day after intracolonic administration of either normal saline (negative control) or acetic acid (control) and after treatments with PGE extract (test extract, 100 mg/kg) and sulfasalazine (positive control, 100 mg/kg) [7] in acetic acid-induced colitis rats. PGE and standard UC protective drug, sulfasalazine suspension was prepared in 0.5% carboxymethyl cellulose and administered orally, once daily in the volume of 1 ml/100 g rat for 14 days after the induction of colitis. The results of the acetic acid group were compared with a normal saline group while the treatment groups were compared with the acetic acid group.

Biochemical estimations

Estimation of protein

To estimate the protein content in the colonic mucosal homogenate, 95% ethanol was added to 0.1 ml of colonic mucosal homogenate (100 mg/ml) and was then centrifuged at 3000 rpm for exactly 5 min. The precipitate so obtained was dissolved in 1 ml of 0.1 N NaOH. 0.4 ml of the above sample was taken in another test tube. Four milliliters of alkaline reagent were then added to this test tube and kept for 10 min. Then, 0.4 ml of the phenol reagent was added and again 10 min were allowed for color development. The absorbency was measured at

610 nm spectrophotometrically against blank prepared using distilled water. The protein content was estimated from the standard curve prepared with bovine albumin and has expressed as mg/g wet tissue.

Estimation of free radicals

Measurement of LPO

The levels of LPO were estimated in terms of malondialdehyde (MDA). Add 0.2 ml of 8.1% SDS, 1.5 ml of 20% acetic acid solution to 0.4 ml of the colonic tissue homogenate and adjust the pH to 3.5 with NaOH, and 1.5 ml of 0.8% aqueous solution of TBA. The mixture was made up to 4.0 ml with distilled water and then heated in an oil bath at 95°C for 60 min. After cooling with tap water, 1.0 ml of distilled water and 5 ml of a mixture of n-butanol and pyridine (15:1, v/v) were added and shaken vigorously. After centrifugation at 4000 rpm for 10 min, the organic layer was taken and its absorbance at 532 nm was measured against a blank containing 0.4 ml of distilled water in place of the sample. 1,1,3,3-tetramethoxy propane was used as an external standard and the level of LPO was expressed as nmol MDA/g wet tissue.

Estimation of NO

As nitrite and nitrate were formed as end products of the reactive nitrogen intermediates, the measurement of nitrite using the Griess reagent is generally employed as a marker for the formation of NO. Briefly, the rat gastric mucosal homogenates were mixed with an equal volume of vanadium (III) chloride and Griess reagent and incubated at 37° C for 30 min. The absorbency was measured at 540 nm spectrophotometrically against blank prepared using distilled water. Nitrite content was determined from a standard curve prepared using sodium nitrite.

Statistical analysis

Statistical comparison was performed using either unpaired “t”-test or one-way analysis of variance (ANOVA) and for multiple comparisons versus control group was done by Dunnett’s test. All statistical analyses were performed using SPSS statistical version 16.0 software package (SPSS® Inc., USA). p<0.05 was considered statistically significant.

RESULTS

The effects of PGE extract (test extract, 100 mg/kg) and sulfasalazine (positive control, 100 mg/kg) on free radicals related to the inflammatory process and healing were estimated in mucosal incubates following induction of colitis by acetic acid. Free radicals – LPO and NO, which are important parameters for tissue damage, were estimated and indicated a positive effect of healing of colonic mucosa in the present study.

Effects on free radicals – LPO and NO

AA did not cause any change in protein content of the colonic mucosa expressed as mg/g wet tissue while it enhanced both LPO and NO expressed either as nmol/g wet tissue or nmol/mg protein compared to NS rats. PGE (100 mg/kg) and SS (100 mg/kg) showed reversal of levels of both LPO and NO near to the NS rats. The effect on free radicals by PGE was comparable with SS (Table 1 and Fig. 1).

The results of the present study with the PGE extract (test extract, 100 mg/kg) and sulfasalazine (positive control, 100 mg/kg) on the level of free radicals that indicate the reversal of colonic damage and inflammation induced by AA do indicate the effective healing effects of PGE.

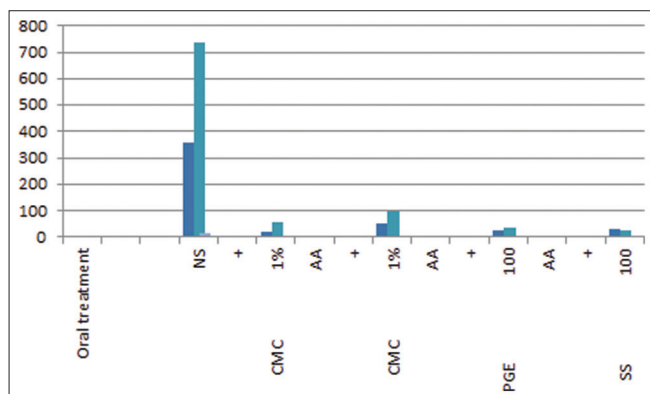
DISCUSSION

Acetic acid-induced colitis has been reported to resemble human inflammatory bowel disease in terms of prolonged colonic inflammation and serves as a useful model to investigate the role of free radicals and antioxidants in the pathophysiology of colitis [8,9]. Our results with intracolonic administration of acetic acid showed an increase in inflammation and ulceration in the mucosa of rat’s colon. Our studies on the LPO and NO status revealed that PGE possessed significant therapeutic properties and reduced free radicals stress, which would help to prevent oxidative damage and promote the healing process and its effect was comparable with the sulfasalazine-treated group. The above

Table 1: Effects of PGE and SS treatment on AA-induced changes in free radicals (lipid peroxidation, LPO and nitric oxide, NO) in AA-induced ulcerative colitis in rat's colon

Oral treatment (mg/kg, OD×14 days)	Protein mg/g wet tissue	Free radicals			
		LPO		NO	
		nmol/g wet tissue	nmol/mg protein	nmol/g wet tissue	nmol/mg protein
NS+CMC 1%	57.2±3.62	356.9±21.9	6.4±0.39	736.9±58.1	13.1±1.13
AA+CMC 1%	51.1±2.98	795.6***±51.57	15.9***±1.23	1223.9***±99.42	24.4***±2.37
AA+PGE 100	66.8c±2.01	327.1c±26.8	4.8c±0.38	531.6c±34.15	8.0c±0.71
AA+SS 100	65.5b±1.83	425.7c±32.78	6.7c±0.58	542.8c±24.46	8.4c±0.28

Results are mean±SEM of six rats in each group. **<0.01, ***<0.001 compared to respective NS group (unpaired "t"-test), ^b<0.01, ^c<0.001, compared to respective AA group (statistical analysis was done by one-way analysis of variance followed by Dunnett's test for multiple comparisons)

**Fig. 1: The effects of PGE and SS treatment on AA-induced changes in free radicals (lipid peroxidation [LPO] and nitric oxide [NO]) in rat's colonic mucosa**

effects may be attributed to the anti-inflammatory, antinociceptive, and antiulcer properties of PGE. The presence of anti-inflammatory activity in PGE may be attributed to other pharmacologically active constituents such as ellagic acid, ellagitannins, punicic acid, flavonoids, anthocyanidins, anthocyanins, and estrogenic flavonols and flavones isolated earlier [10,11]. Flavonoids are most commonly known for their antioxidant activity. Thus, PGE could have a potential role in the therapy of various inflammatory conditions including UC.

CONCLUSION

The results of the present study revealed that 50% ethanolic extracts of PGE have significant healing activity in AA-induced colitis rats. Free radicals and colonic microorganisms play an important role in tissue injury and healing which were affected in AA-induced colitis, and their reversal by PGE, do suggest a possible role of *Punica granatum* in the treatment of colitis, could be due to their promotion effect on decreasing free radical generation. Further, PGE seemed to be safe and did not produce any lethal effect.

ACKNOWLEDGMENT

All the authors express their sincere thanks to the Department of Pharmacology, Faculty of Medicine, Institute of Medical Sciences, Banaras Hindu University, Varanasi, India, for providing the best facilities and funding for the research work.

CONFLICTS OF INTEREST

We declare that we have no conflicts of interest.

SOURCE OF FUNDING

None.

AUTHORS' CONTRIBUTIONS

Concept, design, and data collection were done by Dr. Arpit Verma. Data analysis and interpretation were done by Dr. Mani Goel. Drafting was done by Dr. Satyendra Prajapati and Dr. Anand Bhadkariya. Critical revision and final approval of the version to be published were done by Dr. Anand Bhadkariya and Dr. Arpit Verma.

REFERENCES

- Kathleen A, Jurenka JS. Inflammatory bowel disease Part 1: Ulcerative colitis pathophysiology and conventional and alternative treatment options. *Altern Med Rev* 2003;8:247-83.
- Benson JM, Shepherd DM. Aryl hydrocarbon receptor activation by TCDD reduces inflammation associated with crohn's disease. *Toxicol Sci* 2010;120:68-78.
- Molodecky NA, Kaplan GG. Environmental risk factors for inflammatory bowel disease. *Gastroenterol Hepatol* 2010;6:339-46.
- Khor B, Gardet A, Xavier RJ. Genetics and pathogenesis of inflammatory bowel disease. *Nature* 2011;474:307-17.
- Akhlaghi M, Band B. Mechanisms of flavonoid protection against myocardial ischemia-reperfusion injury. *J Mol Cell Cardiol* 2009;46:309-17.
- Gautam MK, Goel S, Ghatule RR, Singh A, Nath G, Goel RK, et al. Curative effect of Terminalia chebula extract on acetic acid-induced experimental colitis: Role of antioxidants, free radicals and acute inflammatory marker. *Inflammopharmacol* 2013;21:377-83.
- Wiegand I, Hilpert K, Hancock RE. Agar and broth dilution methods to determine the minimal inhibitory concentration (MIC) of antimicrobial substances. *Nat Protoc* 2008;3:163-75.
- Tahan G, Aytac E, Aytakin H, Gunduz F, Dogusoy G, Aydin S, et al. Vitamin E has a dual effect of anti-inflammatory and ulcerative colitis in rats. *Can J Surg* 2011;54:333-8.
- Keshavarzian A, Banan A, Farhadi A. Increases in free radicals and cytoskeletal protein oxidation and nitration in the colon of patients with inflammatory bowel disease. *Gut* 2003;52:720-8.
- Lansky EP, Newman RA. *Punica granatum* (pomegranate) and its potential for prevention and treatment of inflammation and cancer. *J Ethnopharmacol* 2007;109:177-206.
- Pirbalouti AG, Koohpayeh A, Karimi I. The wound healing activity of flower extracts of *Punica granatum* and *Achillea kallelensis* in wistar rats. *Acta Pol Pharm* 2010;67:107-10.