

Loma Linda University

TheScholarsRepository@LLU: Digital Archive of Research, Scholarship & Creative Works

Loma Linda University Electronic Theses, Dissertations & Projects

6-1991

Cephalometric Analysis of Soft Tissue Profile Change Associated with Orthodontics and Orthognathic Surgery : A Long-Term Study

Douglas M. Brown

Follow this and additional works at: <https://scholarsrepository.llu.edu/etd>



Part of the [Orthodontics and Orthodontology Commons](#)

Recommended Citation

Brown, Douglas M., "Cephalometric Analysis of Soft Tissue Profile Change Associated with Orthodontics and Orthognathic Surgery : A Long-Term Study" (1991). *Loma Linda University Electronic Theses, Dissertations & Projects*. 1234.

<https://scholarsrepository.llu.edu/etd/1234>

This Thesis is brought to you for free and open access by TheScholarsRepository@LLU: Digital Archive of Research, Scholarship & Creative Works. It has been accepted for inclusion in Loma Linda University Electronic Theses, Dissertations & Projects by an authorized administrator of TheScholarsRepository@LLU: Digital Archive of Research, Scholarship & Creative Works. For more information, please contact scholarsrepository@llu.edu.

ABSTRACT

CEPHALOMETRIC ANALYSIS OF SOFT TISSUE PROFILE CHANGE ASSOCIATED WITH ORTHODONTICS AND ORTHOGNATHIC SURGERY: A LONG-TERM STUDY

by

Douglas M. Brown, DDS

The purpose of this study was to determine the effect of combined orthodontic and orthognathic surgical treatment upon the soft tissue profile, and to determine the correlation between soft tissue response and the following variables: type of surgery, genioplasty, lip thickness, method of surgical site closure, interlabial distance and eversion of the lower lip. Preoperative and long-term postoperative lateral cephalograms were traced for 327 patients (231 females, 96 males) who had been treated with orthognathic surgery (108 Le Fort I, 109 mandibular sagittal split, 110 combined Le Fort I and mandibular sagittal split surgery). The results indicated that strong correlations existed between the hard tissue and soft tissue landmarks in a horizontal direction, poor correlations existed between the hard tissue and soft tissue landmarks in a vertical direction, horizontal movement of the soft tissue chin was greater than previously reported, there was significant uprighting of an everted lower lip following surgery. It was also found that individuals exhibited large variations in response to similar procedures.

UNIVERSITY LIBRARY
LOMA LINDA, CALIFORNIA

LOMA LINDA UNIVERSITY

Graduate School

CEPHALOMETRIC ANALYSIS OF SOFT TISSUE PROFILE
CHANGE ASSOCIATED WITH ORTHODONTICS
AND ORTHOGNATHIC SURGERY:
A LONG-TERM STUDY

by

Douglas M. Brown, DDS

A Thesis in Partial Fulfillment
of the Requirements for the Degree Master of Science
in Orthodontics

June 1991

ACKNOWLEDGEMENTS

I would like to express my gratitude and appreciation to the following persons:

Dr. G. William Arnett for making his office, computer system and patient records available, without which this project would not have been possible.

Gene Scroggins of Prescription Data, Inc. for the creation of the data collection and measurement program.

Jonathan Foster of Channel Computer Consulting for the creation of the measurement comparison program and for his on-site assistance.

Each person whose signature appears below certifies that this thesis, in his opinion, is adequate in scope and quality as a thesis for the degree Master of Science.

Toufic Jeiroudi

,Chairman

M. Toufic Jeiroudi, Associate Professor of Orthodontics

Norman S. Carter

Norman S. Carter, Chairman, Department of Orthodontics

Joseph M. Caruso

Joseph M. Caruso, Graduate Program Director, Department of Orthodontics

William J. Emmerson

William J. Emmerson, Assistant Professor of Orthodontics

Timothy B. Welch

Timothy B. Welch, Coordinator of Residency Training, Department of Oral Surgery

TABLE OF CONTENTS

Introduction.....	1
Literature Review.....	2
Methods and Materials.....	10
Results.....	18
Discussion.....	29
Summary.....	37
References.....	39

INTRODUCTION

During the last decade there has been an increasing interest in health and beauty. Orthodontists and oral surgeons have noticed an increase in the number of adult patients they are treating. The expectation of these patients is to not only restore their dentition to a healthy, functioning state, but more importantly to improve their facial aesthetics. There have been a multitude of advances in treatment techniques which have allowed the surgeon and orthodontist to dramatically alter a patient's appearance while improving function. In order to optimize the final result of the treatment an in depth analysis, accurate diagnosis, and careful treatment planning prior to treatment are essential. Numerous articles providing information concerning soft tissue changes following orthognathic surgery have been published. The majority of these studies, however, have examined small numbers of post-surgical patients. It has been noted that great variation exists among the response of individuals to surgical procedures and surgical technique. Studies with limited sample sizes may lead to erroneous conclusions if a large variation of response exists within the sample. A study which examines a large number of patients who have undergone similar surgical procedures performed by the same surgeons may provide a more accurate description of the results. The objective of this study is to provide the clinician with relevant data with respect to soft tissue changes following the orthodontic-orthognathic surgical treatment, as reported in this study, to assist in treatment planning.

REVIEW OF THE LITERATURE

One of the major goals of the orthodontist or orthognathic surgeon is to improve facial aesthetics. To reach that goal a number of steps must be undertaken, the first of which is an in depth analysis.

The development of the cephalometer, by Broadbent, gave the clinician the ability to examine the skeletal and dental structure of a patient. Since that time many clinicians have developed a number of cephalometric analyses to aid in identification of skeletal or dental deficiencies.^{1,2} Cephalometric analysis can provide valuable information prior to initiating treatment, and provide the practitioner with some insight into how a patient might respond to various methods of treatment. Values have been determined for those measurements which best represented the "normal" individual. These "norms" give the clinician a target for which to aim his treatment. Their use, however, is only one of the steps which leads to the achievment of the goal of improved facial aesthetics. To reach that goal the clinician must also have an understanding of the relationship between the soft tissue and the underlying bony structure.

The importance of analyzing the soft tissue in conjunction with orthodontic treatment was clearly stated by Burstone.³ He developed a system of soft tissue analysis for patients requiring orthodontic treatment. Peck and Peck⁴ reiterated this concern and urged orthodontists not to rely solely on skeletal measurements when treating patients. In 1980, Legan and Burstone⁵ carried this a step

further by outlining a method of analysis of the tissue prior to orthognathic surgery.

Questions began to arise about what actually constituted a normal, or even an ideal skeletal and facial relationship. McNamara⁶ presented information gleaned from studying one hundred and twenty-five adult individuals with ideal facial and occlusal relationships. He presented this data to demonstrate that there are infinite combinations of dentoskeletal relationships which provide an aesthetically pleasing soft tissue profile, and emphasized the importance of using cephalometric norms merely as targets for individual treatment.

Many patients were treated for skeletal deformities by orthodontics alone. This resulted in less than pleasing facial aesthetics even though harmony of the dental occlusion was achieved. The additional use of orthognathic surgery to correct the skeletal deformity often resulted in improved aesthetics. On occasion, however, the result fell short of the expectation of both the patient and the clinician due to improper diagnosis or treatment planning. Researchers began to examine the effects of surgical procedures on the soft tissue profile to determine whether the result could be predicted.

MANDIBULAR SURGERY

Articles appeared in the literature⁷⁻⁸ during the late 1960's and early 1970's which described surgical methods to correct mandibular prognathism. Robinson, et al, in several articles⁹⁻¹⁰

described the changes in the soft tissue profile associated with mandibular set-back surgery. His articles were followed in rapid succession by the studies of Fromm¹¹, Bell and Dann¹², Lines¹³, and Hershey¹⁴. These researchers generally found a horizontal soft tissue to hard tissue response of 1:1 in the chin area, and of 3:4 for changes in the lower lip with respect to the lower incisor, in either advancement or retraction of the mandible. Great variation, however, was noted in the response of some individuals to the surgical procedures.

MAXILLARY SURGERY

During the 1970's there was an increasing interest in surgical procedures to correct maxillary and midface skeletal deformities. Lines and Steinhauser¹³ studied 35 patients who had undergone various types of maxillary and mandibular surgical correction. These included total maxillary advancements and maxillary alveolar set-backs. Several of their sample groups, however, were quite small. The three patients who had undergone maxillary advancement demonstrated a soft tissue change to hard tissue movement ratio of 2:3 in a horizontal direction. The seven patients treated with maxillary alveolar set-backs averaged a 1:2 soft to hard tissue response. Dann, Fonseca, and Bell¹⁵ studied eight patients who were treated with maxillary advancements. They also found that the upper lip followed a 1:2 ratio of change. In addition they noted a vertical shortening of the lip as the maxilla was moved forward horizontally. Schendel and associates,¹⁶ in a study of thirty

patients after maxillary impaction, found that the vertical change in the upper lip when compared to the vertical repositioning of the upper incisor followed a ratio of 0.38:1. It was also noted that with maxillary impaction the mandible auto-rotated, which resulted in a 0.60:1 horizontal and a 1:1 vertical movement of the lower lip to the lower incisor.

COMBINATION SURGERY

Skeletal imbalance frequently involved more than just the maxilla or mandible. Treatments often called for surgical correction of both jaws. New methods of surgery came to light in numerous publications in the late 1970's and early 1980's.¹⁷⁻²⁶ The development of grafting techniques and implant materials provided another important tool to the surgeon. The use of one type of alloplastic material (Proplast) for chin augmentation was addressed in an article by Dann and Epker.²⁷

The addition of these techniques, however, brought on new problems. Correction of dental and skeletal imbalance in adults soon became a complex series of orthodontic and surgical treatments. Diagnosis and selection of the most appropriate treatment became more of a challenge due to the interplay of many variables each exerting an effect upon the overlaying soft tissues.

EFFECTS OF VARIABLES

Studies of surgical effects on the soft tissue often encountered wide variations in response. Investigators attempted to explain this variation. Mansour,²⁸ in a study of twenty-one individuals,

investigated the relationships between upper lip area, interlabial gap, alterations in the occlusal plane, and variations in surgical technique and the soft tissue response. Quast²⁹ attempted to determine whether the long term soft tissue change was different from that seen in the six months immediately following the surgical procedure. Phillips and his associates³⁰ examined the full-face effects of maxillary impaction and the variations associated with surgical techniques. Stella³¹ studied twenty-one individuals to determine if initial lip thickness played a role in variable tissue response.

These researchers found that it was increasingly difficult to predict the final soft tissue result and that comparisons of single variables were unlikely to result in accurate predictions. Engle²¹ and Radney,²³ in their earlier articles, developed formulas utilizing multiple regression equations to calculate the expected soft tissue response in an attempt to more accurately predict the movement of several soft tissue landmarks. It was often difficult for the clinician to determine which of these variables would affect the soft tissue, and to what degree. Careful treatment planning prior to treatment was essential.

VISUAL TREATMENT OBJECTIVES

Ricketts'¹ study, in 1957, of cephalometric and growth patterns led him to develop a system useful in treatment planning orthodontic cases termed the Visual Treatment Objective. He found that it was beneficial to have a visual objective prior to initiating

treatment to help achieve his aesthetic goal. In 1974 Lines and Steinhauser³² recognized the importance for preparation prior to orthognathic surgery, just as Ricketts had stressed treatment planning prior to orthodontic correction. They proposed a system, useful to the surgeon, for diagnosis and treatment planning prior to orthognathic surgery. Two years later Worms, Isaacson, and Speidel³³ released their article which included a profile analysis to be utilized prior to mandibular surgery.

A revolution to surgical treatment planning occurred in 1980 with the publication of an article by Fish and Epker.³⁴ This was the first time a method for creating a surgical-orthodontic cephalometric prediction tracing was addressed in the literature. Their method was based upon techniques from Ricketts' work, and that of Bench, Gugino and Hilgers.³⁵⁻³⁶ They outlined steps to position the bone structures, as one would in surgery, and then presented some very basic ratios for movement of the lips and chin, which were based upon their experience with surgical patients. Much was left, however, to the artistry of the clinician. In 1985 Wolford, Hilliard, and Dugan³⁷ published a systematic approach to the prediction tracing. In their book, Surgical Treatment Objective (STO), they provided tables of ratios of change for various types of surgical movement, which allowed the surgeon to select procedures that could conceivably create the desired soft tissue aesthetic result. These ratios were based upon several of the studies previously mentioned, which attempted to analyze the soft tissue profile results

of surgical treatment. Epker and Fish refined their own work in a two volume publication released in 1986.²⁶ A more recent work, containing a method for creating a surgical treatment objective prediction tracing, was compiled by Proffit and White³⁸ in 1991. In that work the listing of soft tissue change effects was derived from a research study which has yet to be published.³⁹

More recently available to the practitioner are a number of computerized diagnostic and treatment prediction programs.⁴⁰ One disadvantage of their use is that the clinician may create a profile which is impossible to achieve within the limitations of the actual surgery. In addition, the clinician may not be aware that the automatic soft tissue adjustments are based on data derived from studies with limited sample sizes.³⁸ There may be a danger in presenting such an image to the patient in as much as they might be led to expect a guaranteed result.

PROBLEM

Clinicians utilizing these prediction techniques have occasionally found that the aesthetic result of the surgery does not match the predicted profile. This could be due to errors introduced into previous studies through large variations among small sample sizes. Previous studies have been based upon sample sizes under thirty-five, and several of the sample groups have been as small as three. This becomes increasingly important when it has been shown that a multitude of variables may affect the amount of soft tissue response. Some, but not all of the variables, may be represented in a

small sample. A larger sample size would increase the probability of examining individuals with a greater number of variables, and aid the orthodontist or oral surgeon in identification of the variables most likely to affect the response of the soft tissue.

OBJECTIVE

This study was initiated to provide orthodontists and oral surgeons with comprehensive data which will aid in the prediction of soft-tissue changes following orthodontic treatment combined with orthognathic surgery. The first objective of this study was to examine a large number of post-orthodontic and orthognathic surgical patients to determine the soft tissue response, and to categorize these patients according to their variables. The second objective was to create a large data base for in-depth analysis, to determine whether there are correlations among variables which will aid the clinician in diagnosis and treatment planning.

METHODS AND MATERIALS

This study investigated the long term profile changes following orthognathic surgery and the orthodontic treatment that followed. A comparison of the soft tissue changes corresponding to skeletal changes was made through the use of preoperative and postoperative lateral head films. The desire was to examine a large number of individuals, therefore, selection according to surgical procedure was not part of the criteria. Control of surgical technique, however, was essential. The sample was selected from the files at the Center for Corrective Jaw Surgery, Santa Barbara, CA. All surgical procedures were performed by either Dr. William Arnett or Dr. James Tamborello. This insured consistency in methods of incision, osseous manipulation, fixation and surgical closure. The earliest surgeries were performed in 1983, and the most recent in 1990.

During this period several methods of surgical site closure and tissue management were employed. Impaction of the maxilla often results in widening of the alar base of the nose and a thinning of the upper lip. To limit the amount of nasal base flaring a suture is passed through the lateral aspects of the alar bases and cinched tight as needed. To control thinning of the upper lip a VY closure method was employed. This method involves the closure of a vertical incision in the area of the maxillary labial frenum prior to the closure of the horizontal vestibular incision. Excessive tightening of the alar base suture or a long Y stem in the VY closure may result in excessive thickening of the upper lip. The method of closure has been recorded and is part of the data base.

In addition information concerning the method of bony chin augmentation was collected. Some individuals were treated with a sliding bony genioplasty while others received an alloplastic implant (Proplast) to augment the chin.

A total of 327 individuals were selected for examination. There were 231 female and 96 male patients. The age range was 12 years 2 months to 63 years 4 months. There were seven patients between the ages of 12 to 13 years. There were 141 patients between the ages of 14 and 19 years, and 179 that were 20 years of age or older. Of the 327 patients, 108 underwent maxillary Le Fort I surgery, 109 were treated with bilateral sagittal split osteotomies, and 110 patients received both Le Fort I and sagittal split osteotomies.

All radiographs were taken in-office, on the same cephalometer. As a result, there was uniform image magnification on all cephalograms eliminating the need to correct measurements prior to comparison. All films were taken with the patient in relaxed closure and with the lips in repose. This avoided the possibility for artificial influence on the soft tissue profile by reducing the chance for lip strain.⁴¹ For each individual the preoperative (T1) film was taken within one month of surgery. The postoperative (T3) film was taken no sooner than six months following surgery. This post-op time requirement was necessary to allow for the reduction of swelling and the restoration of soft tissue stability.^{17, 28} The maximum time between the surgery and the post-op radiographic examination was 72 months. It was not possible to assess the degree of orthodontic

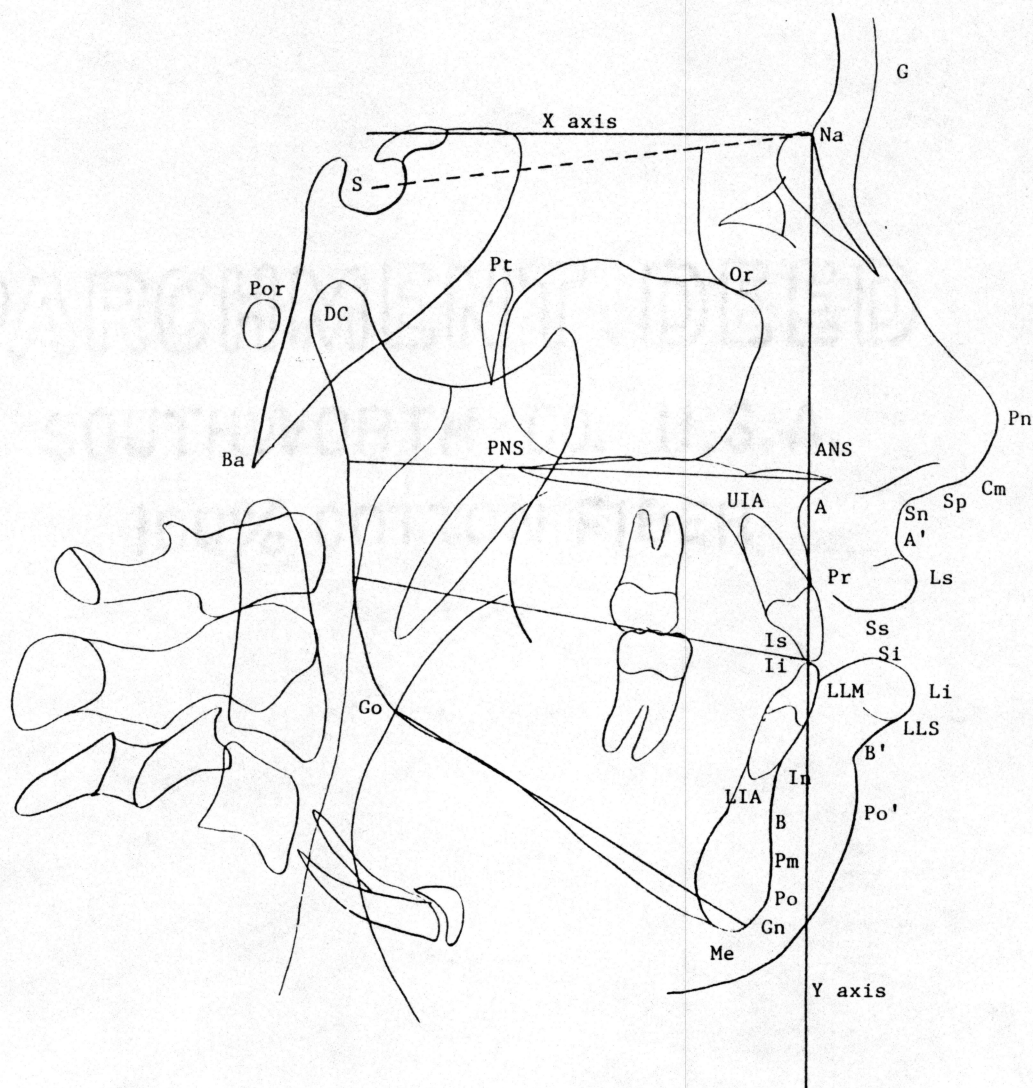


Fig. 1. Cephalometric landmarks and reference planes. (Refer to Table I)

Table I. Listing of measured cephalometric landmarks. (Refer to Fig.1)

ANS - Anterior nasal spine.

Columella (Cm) - The most anterior point on the columella of the nose.

Gnathion (Gn) - The most anterior inferior point on the chin.

Incision inferius (Ii) - The incisal edge of the crown of the most anterior mandibular central incisor.

Incision superius (Is) - The incisal edge of the crown of the most anterior maxillary central incisor.

Infradentale (In) - The point where the mandibular dental alveolus contacts the labial surface of the mandibular central incisor in the midsagittal plane.

Labrale inferius (Li) - The most anterior point on the lower lip.

Labrale superius (Ls) - The most anterior point on the upper lip.

Lower lip mucosa (LM) - Point on the lower lip mucosa directly opposite the vermillion border.

Lower lip vermillion (LV) - The lower most point on the vermillion border of the lower lip.

Menton (Me) - The most inferior point on the bony chin.

PNS - Posterior nasal spine.

Pogonion (Po) - The most anterior point on the bony chin.

Pronasale (Pn) - The most anterior point on the nose.

Prosthion (Pr) - The point where the maxillary dental alveolus contacts the labial surface of the maxillary central incisor in the midsagittal plane.

S point (Sp) - The point at which the curvature of the nasal septum in the midsagittal plane reverses direction.

Soft tissue A (A') - The point of greatest concavity on the anterior border of the upper lip between subnasale and labrale superius.

Soft tissue B (B') - The point of greatest concavity on the anterior border of the lower lip between labrale inferius and soft pogonion.

Soft tissue pogonion (Po') - The most anterior point of the soft tissue chin.

Stomion inferius (Si) - Most superior point of the lower lip.

Stomion superius (Ss) - The most inferior point on the vermillion border of the upper lip.

Subnasale (Sn) - The point at which the nasal septum merges with the upper cutaneous lip in the midsagittal plane.

Subspinale (A) - The point of greatest concavity on anterior border of the premaxilla between ANS and Pr in the midsagittal plane.

Supramentale (B) - The deepest point in the midsagittal plane between infradentale and pogonion.

Supra pogonion (Pm) - The point at which the curvature of the bony chin in the midsagittal plane, between subspinale and pogonion, reverses direction.

correction following surgery, however, it is expected that such movement would be minimal since the gross corrections were achieved surgically leaving only minor orthodontic movement.

A preoperative and a postoperative cephalogram was traced for each individual by one investigator. This was done through the use of an IBM compatible computer, a pen-stylus type digitizer, and a specialized cephalometric analytical program created for this study by Prescription Data, Inc. This program allowed the digitization of selected cephalometric landmarks which were then related to computer generated reference lines. A study by Bamrind and Frantz⁴² evaluated the reliability of identification of numerous cephalometric landmarks. In this study both sella and nasion were rated extremely high. Hence, only these two landmarks were required to construct the two reference lines, thus ensuring a high degree of reliability and reproduction.

The T1 cephalogram was placed on the digitizer screen. A sheet of acetate was placed on top and a fine tip marking pen was used to pinpoint sella, nasion, cranial base structures and a template of the palate. The cephalometric landmarks, shown in Fig. 1, were then digitized. Next, the acetate and T1 film were removed and the T3 film was placed upon the digitizer. The acetate overlay was aligned along the cranial base⁴³ structures and the cephalometric landmarks were again digitized. The acetate template of the palate was utilized to aid in locating the approximate position of the anterior nasal spine (ANS) and subspinale (A), which often were

Table II. Listing of additional measurements and angles.

- Interincisal angle* - The angle between the long axes of the upper and lower incisor.
- Interlabial gap* - The distance between stomion superius and stomion inferius.
- Mandibular incisor to mandibular plane angle* - The angle between the long axis of the lower incisor and the mandibular plane.
- Mandibular plane angle* - The angle between S-Na and Go-Gn.
- Mandibular sulcus angle* - The angle of the lower lip between Li-B'-Po'.
- Maxillary incisor to S-Na angle* - The angle between the long axis of the upper incisor and S-Na.
- Maxillary incisor to palatal plane angle* - The angle between the long axis of the upper incisor and the palatal plane.
- Maxillary sulcus angle* - The angle of the upper lip between Sn-A'-Ls.
- Nasal length* - The distance between columella and subnasale.
- Nasolabial angle* - The angle between the base of the nose and the upper lip as measured from Cm-Sn-Ls.
- Occlusal plane angle* - The angle of the occlusal plane to S-Na.
- Overbite* - The distance between incision superius and incision inferius in a vertical direction.
- Overjet* - The distance between incision superius and incision inferius in a horizontal direction.
- Palatal plane angle* - The angle of the palatal plane to S-Na.
- Profile angle* - The angle measured between G-Sn-Po'. Angles <math><180^\circ</math> are positive.
- Upper lip to Sn-Po'* - The distance between labrale superius and a line from Sn to Po'.
- Lower lip to Sn-Po'* - The distance between labrale inferius and a line from Sn to Po'.
- Upper lip thickness* - The distance between prosthion and labrale superius.
- Lower lip thickness* - The distance between lower lip mucosa and lower lip vermillion.
-

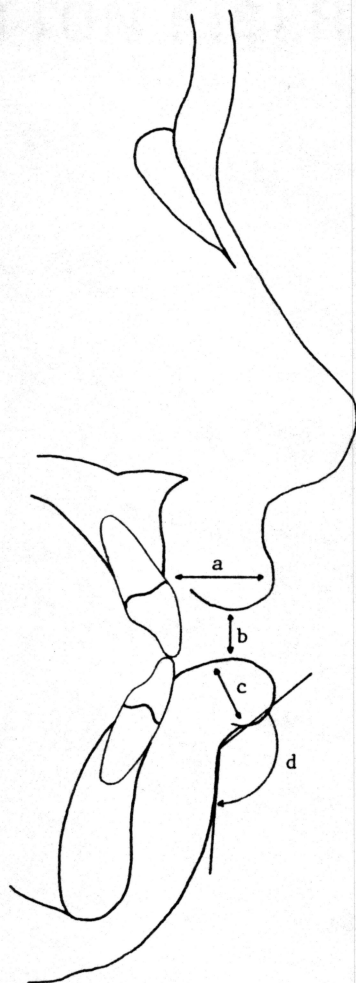


Fig. 2. Measured variables a) Distance measured for upper lip thickness.
b) Interlabial distance. c) Distance measured for lower lip thickness.
d) Mandibular sulcus angle.

indistinguishable following the Le Fort 1 procedure. The computer program created a horizontal reference line (X axis) at an angle 7° to sella-nasion and passing through nasion.²⁸ A perpendicular (Y axis) was then constructed to the horizontal line at nasion. Linear measurements were made between these two reference lines and selected soft and hard tissue landmarks (Table I) for each tracing. Points which were located anterior to the Y axis were given a positive (+) value, and those posteriorly located were assigned a negative (-) value. All points fell below the X axis and received a positive (+) value. In addition, a number of other linear measurements and angles (Table II, Fig. 2) were calculated.

A computerized data base was created to contain the measurements from each tracing. A second data base was created, through the use of another specialized program, which calculated the differences between the T1 and T3 measurement values. Both of these data base files were automatically transferred by computer directly to the ABSurv™ statistical analysis program. This avoided the risk of introducing additional error through data base entry.

Ratios of soft tissue change to hard tissue change were determined and correlation coefficients were then calculated, with the patients grouped according to differences in variables such as type of surgery, genioplasty, chin augmentation and surgical closure technique. No profile tracings were generated, only numerical data were compared.

RESULTS

This study involved the creation of a large data base containing information about the soft and hard tissue changes following orthognathic surgery and orthodontic treatment. In addition to the numerical data, a number of variables suspected of affecting the soft tissue response were tabulated. It is expected that a number of articles for publication will be derived from this data.

MAXILLARY SURGERY

The ratios of soft tissue to hard tissue change for patients treated with maxillary Le Fort I surgery are presented in Table III. Correlation of the soft tissue to hard tissue movement in a horizontal direction is presented first. The average advancement or retraction of the maxilla was 2.80 mm with a maximum advancement of 9.36 mm.

This study found that the ratio of soft tissue lip (Ls) movement was 0.72:1 of the bone movement at prosthion (Pr) for both the advancement and retraction groups with a correlation coefficient of $r=0.82$. Soft tissue A (A') was also closely correlated ($r=0.83$) to the horizontal movement of prosthion with a ratio of 0.71:1. The upper lip (Ls) followed the movement of the upper incisor (Is) by a ratio of 0.43:1. Correlation of landmarks of the nose, pronasale (Pn) and subnasale (Sn), in a horizontal direction to subspinale (A) were $r=0.35$ and $r=0.61$ respectively, with variable ratios of movement.

One hundred seven of the patients received maxillary impactions with the average impaction of 1.66 mm at ANS (max. 6.11 mm) and 2.51 mm at PNS (max. 7.73 mm). The correlation

Table III.

Soft tissue : Hard tissue ratios
Maxillary surgery n=108

Ratios Mean change value	Mean	Standard Error	Correlation Coefficient	Significance
LsH / PrH*	0.72	0.25	0.82	<0.01
LsH / IsH	0.43	0.28	0.77	<0.01
A'H / PrH	0.71	0.32	0.83	<0.01
SnH / AH	0.57	0.31	0.61	N.S.
PnH / AH	0.81	0.27	0.35	N.S.
PnV / AV†	0.91	0.29	0.49	N.S.
LiH / IiH	0.69	0.20	0.81	<0.01
LiV / IiV	1.24	0.42	0.69	N.S.

*H=horizontal movement
†V=vertical movement

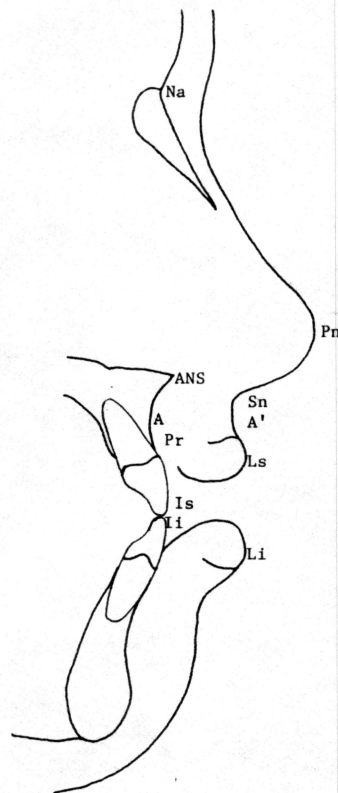


Fig. 3. Maxillary surgery soft tissue and hard tissue landmarks.
(Refer to Table III)

coefficient for the vertical movement of pronasale to subspinale was $r=0.49$. In this group the mandible rotated counter-clockwise an average of 3.75 mm. Correlation between the vertical movement of the lower lip (Li) and the lower incisor (Ii) was $r=0.69$ with a ratio of change of 1.24:1. The horizontal movement of the lower lip to the lower incisor was more closely related ($r=0.81$) with the lip moving by a ratio of 0.69:1 of the incisor movement.

MANDIBULAR SURGERY

Values of the ratios, along with correlation coefficients, for those patients treated by mandibular advancement or retraction are presented in Table IV. For movements in a horizontal direction the following correlations were found between soft and hard tissue. The correlation coefficient for the change in horizontal position of the lower lip (Li) and the lower incisor (Ii) was $r=0.87$, with a mean change ratio of 0.58:1. Correlation coefficients of $r=0.93$ were found between both soft tissue B (B') and hard tissue B, as well as between soft tissue pogonion and hard tissue pogonion (Po) in a horizontal direction. Soft tissue B movement exceeded hard tissue B movement (1.20:1). Similarly soft tissue pogonion exceeded hard tissue pogonion movement (1.17:1).

COMBINATION SURGERY

Patients who underwent surgery of both the maxilla and mandible to correct skeletal deficiencies are represented in the listing of ratios presented in Table V. Movements in a horizontal direction are as follows. The mean upper lip (Ls) movement exceeded

Table IV.

Soft tissue : Hard tissue ratios
Mandibular surgery n=109

Ratios Mean change value	Mean	Standard Error	Correleation Coefficient	Significance
Li H / liH*	0.58	0.08	0.87	<0.01
LiH / InH	0.57	0.09	0.84	<0.01
B' H / InH	1.02	0.24	0.91	<0.01
B' H / B H	1.20	0.07	0.93	<0.01
Po'H / PoH	1.17	0.14	0.93	<0.01

*H=horizontal movement

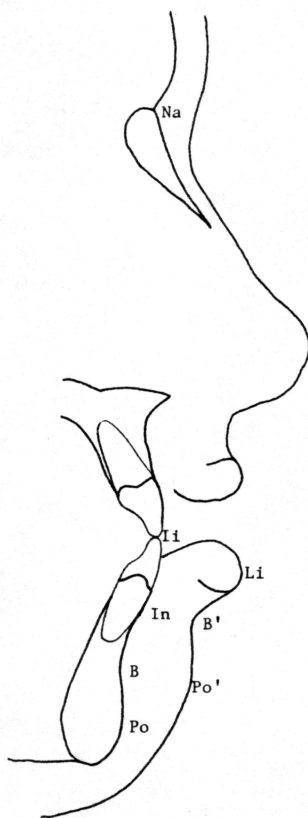


Fig. 4. Mandibular surgery soft tissue and hard tissue landmarks.
(Refer to Table IV)

Table V.

Soft tissue : Hard tissue ratios
 Combination surgery n=110

Ratios Mean change value	Mean	Standard Error	Correlation Coefficient	Significance
LsH / PrH*	1.34	0.38	0.81	<0.01
LsH / Is H	0.45	0.41	0.77	<0.01
A' H / PrH	1.44	0.59	0.80	<0.01
SnH / AH	0.62	0.30	0.63	N.S.
PnH / A H	0.67	0.20	0.55	N.S.
PnV / AV†	1.56	0.35	0.35	N.S.
Li H / li H	0.74	0.81	0.90	<0.01
Li V / li V	0.99	0.25	0.76	<0.01
B' H / In H	1.23	0.32	0.93	<0.01
B' H / BH	0.82	0.19	0.95	<0.01
Po' H / PoH	0.93	0.26	0.94	<0.01

*H=horizontal movement
 †V=vertical movement

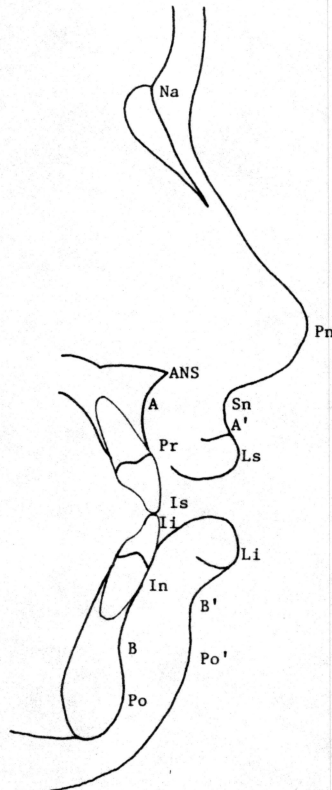


Fig. 5. Combination surgery soft tissue and hard tissue landmarks.
 (Refer to Table V)

the movement of prosthion (Pr) by a ratio of 1.34:1 ($r=0.81$). The upper lip followed the upper incisor horizontal movement by a ratio of 0.45:1 ($r=0.77$). Soft tissue A (A') exceeded the alveolar bone (Pr) movement by a ratio of 1.44:1.

Subnasale (Sn) to subspinale (A) had a correlation coefficient of $r=0.63$, with a ratio of movement of 0.62:1 in a horizontal direction. Pronasale (Pn) to subspinale (A) had a correlation coefficient of $r=0.55$ with a ratio of movement of 0.67:1 in a horizontal direction. In a vertical direction the correlation coefficient of pronasale to subspinale was $r=0.35$ with a ratio of movement of 1.56:1.

The lower lip followed the horizontal movement of the lower incisor by a ratio of 0.74:1 with a correlation coefficient of $r=0.93$. Soft tissue B followed hard tissue B by 0.82:1 ($r=0.95$), while soft pogonion followed hard tissue pogonion by a ratio of 0.93:1 ($r=0.94$).

GENIOPLASTY

The effects of sliding bone genioplasty or alloplastic chin augmentation on the soft tissue chin are presented in Table VI. The horizontal movement of the lower lip (Li) was 0.45:1 with respect to the underlying bone (In) for the genioplasty group ($r=0.83$), 0.43:1 for the augmentation group ($r=0.87$), and 0.46:1 for the non-genioplasty group ($r=0.87$).

The relationship of horizontal movement of soft tissue B (B') to supramentale (B) was 1.14:1 for the genioplasty group ($r=0.92$), 1.17:1 for the augmentation group ($r=0.91$) and 1.15:1 for the non-genioplasty group ($r=0.95$).

Table VI.

Soft tissue : Hard tissue ratios
Comparison of the chin

Ratios		Mean	Standard Error	Correlation Coefficient	Significance
Mean change value					
Genioplasty n=141	Li H / In H*	0.45	0.28	0.83	<0.01
	B' H / B H	1.14	0.18	0.92	<0.01
	Po'H/ PoH	0.92	0.12	0.92	<0.01
	P0'V/ MeV†	0.77	0.35	0.69	N.S.
Augmentation n=41	Li H / In H	0.43	0.43	0.87	<0.01
	B' H / B H	1.17	0.41	0.91	<0.01
	Po'H/ PoH	1.31	0.54	0.83	<0.01
	P0'V/ MeV	1.00	0.70	0.54	N.S.
No Genioplasty n=145	Li H / In H	0.46	0.26	0.87	<0.01
	B' H / B H	1.15	0.16	0.95	<0.01
	Po'H/ PoH	0.97	0.12	0.93	<0.01
	P0'V/ MeV	0.24	0.40	0.55	N.S.

*H=horizontal movement
†V=vertical movement

The soft tissue pogonion (Po') response to horizontal movement of hard tissue pogonion (Po) was 0.92:1 for those in the genioplasty group ($r=0.92$), 1.31:1 for the augmentation group ($r=0.83$), and 0.97:1 for those individuals not receiving a genioplasty ($r=0.93$).

In relationship to the vertical movement of menton (Me), we found that in the genioplasty group soft tissue pogonion (Po') moved upwards by a ratio of 0.77:1 of the vertical movement of menton ($r=0.69$). Patients treated by augmenting the chin with an implant (proplast) followed a 1:1 ratio of vertical movement ($r=0.54$). Those patients not receiving a genioplasty show a 0.24:1 ratio of vertical movement ($r=0.55$).

OTHER VARIABLES

An examination of upper lip thickness and the effects played upon it by maxillary advancement or retraction, and soft tissue closure technique was also done. The average preoperative upper lip thickness of this sample was 16.32 mm (range 11.14-24.19 mm). Of the patients who exhibited maxillary advancement the mean net change in upper lip thickness was less than 1 mm. Those in the maxillary retraction group demonstrated no change in lip thickness.

Data was recorded as to the patients in which the maxillary surgical site was closed utilizing a VY closure technique. The horizontal mean change ratio of labrale superius (Ls) to prosthion (Pr) for the VY closure group was 1.03:1. The ratio for the standard closure technique was 1.04:1.

Lower lip thickness, interlabial distance and an everted lower lip were also studied. When subgrouped according to the type of surgery, it was found that for those subjects in the mandibular or combination surgical groups the mean lower lip thickness prior to treatment was 13.82 mm. Following surgery it was 13.63 mm, a mean net change of less than 1 mm.

In conjunction with maxillary impaction there is a corresponding autorotation of the mandible. This results in a vertical movement of the mandibular jaw coupled with a closure of the interlabial gap. The mean value of closure for the sample group treated was 2.48 mm. There was a large amount of variation in this group. Many individuals demonstrated a closure of less than 1 mm, and one individual was found with a closure of 12.90 mm. Patients treated with mandibular advancement demonstrated the lowest amount of closure (mean=1.38 mm). Individuals who underwent a combination of surgeries had a mean closure of 2.66 mm. The group of patients who received a maxillary impaction had a mean closure of 3.60 mm (Fig. 6).

Individuals in the sample were classified as having either a normal appearing lip or having an everted lower lip on the T1 film, prior to surgery. For those individuals having a normal appearing lip the mean mandibular sulcus angle was 126° prior to surgery. Following surgical correction the normal lip group mean was 128° . This was a mean net change of two degrees. The mean pre-treatment mandibular sulcus angle for patients classified as having an everted

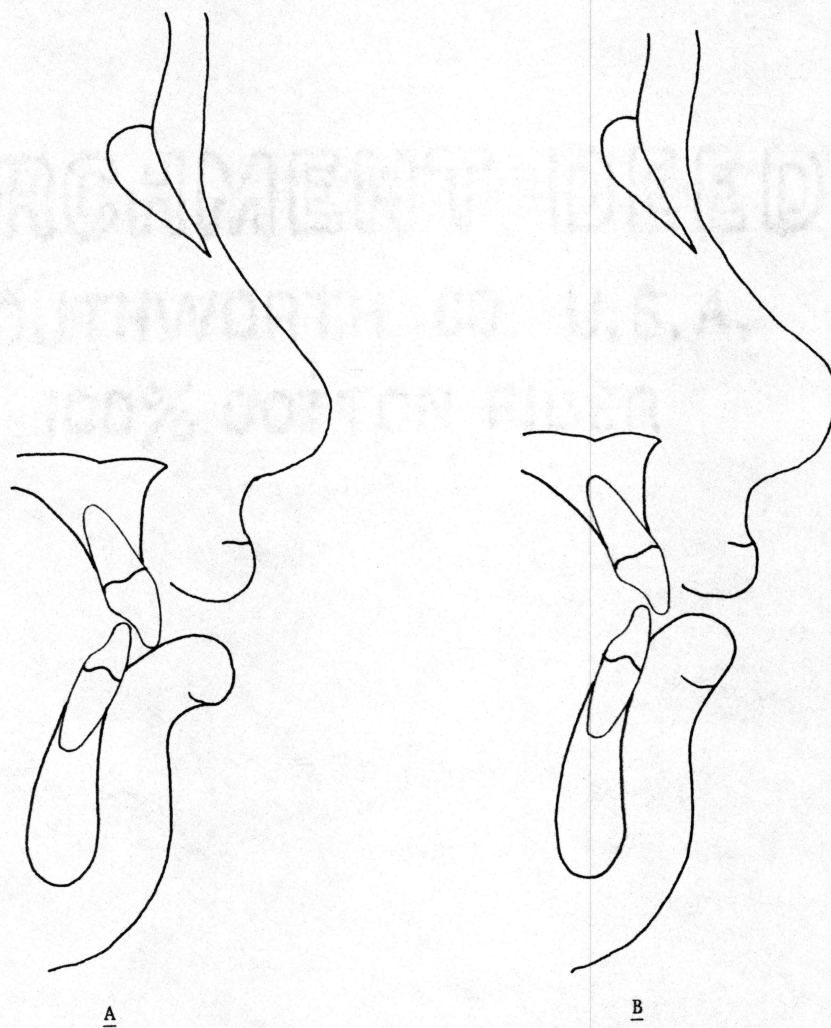


Fig. 6. Effects of maxillary impaction on mandibular sulcus angle and interlabial gap. A) Excessive interlabial distance and an everted lower lip prior to surgery. B) Post-surgical lower lip uprighting and reduction of interlabial distance.

lower lip was 114° , with the lowest value being 48° . Following surgical correction of the skeletal deformities, the mean mandibular sulcus angle was 124° . This was an uprighting of 10° of the lower lip (Fig. 6). The lowest value for the mandibular sulcus angle after surgery was 94° . Of the patients classified as having an everted lower lip 25% were treated with a Le Fort I, 44% underwent mandibular surgery, and 31% required surgical correction of both jaws.

DISCUSSION

It should be noted that in previous studies the sample was normally taken from a very selected group of individuals receiving similar surgical treatments. In this study a broad spectrum of individuals and treatments are represented. Patients who were examined in this study underwent a range of orthodontic and surgical treatment from segmental maxillary impactions to mandibular sagittal osteotomies, and many various combinations. Many also received a genioplasty or chin augmentation graft.

MAXILLARY SURGERY

Comparison of the results for the maxillary surgery group with previous studies indicate a similar amount of horizontal movement of the upper lip to the horizontal movement of the supporting hard tissue. This study found a reasonably strong correlation between the movement of these structures ($r=0.82$). Lines and Steinhauser¹³ found a 0.66:1 ratio of movement of the lip to the supporting bone. The ratio found in this study, 0.72:1 upper lip to prosthion, is relatively close to that value. Wolford, in his book Surgical Treatment Objective,³⁷ presented a value of 0.50:1, which he notes may increase to 0.90:1 when an alar base suture and VY closure is used. There was also a strong correlation ($r=.083$) between the horizontal movement of soft tissue A to prosthion with a 2:3 ratio.

The upper lip to upper incisor movement found in this study (0.43:1) was less than the ratio of 0.60:1 reported by Mansour.²⁸ A difference in the method of data collection exists between that study and this one. Mansour used the labial surface of the upper incisor as

the hard tissue reference point. In this study it was found that the pre-surgical radiographs were taken with orthodontic brackets upon the teeth, while the T3 radiographs were taken after orthodontic movement had been completed and the brackets removed. Therefore, it was difficult to establish a consistently identifiable position on the labial surface of the incisor on both pre- and post-op films. In this study correlation was therefore made between the horizontal movement of the upper lip (Ls) and the incisal edge (Is) of the upper central incisor, which was more easily identified. A moderate correlation was found ($r=0.77$), with the lip movement slightly less than a 1:2 ratio.

The movement of the soft tissue landmarks of the nose exhibited great variability. The correlation of the movement of those landmarks to the underlying bone were mediocre. In a horizontal direction the correlation of subnasale (Sn) to subspinale (A) was $r=0.61$, with a 1:2 ratio of movement, while pronasale (Pn) to subspinale (A) exhibited an even weaker correlation ($r=0.35$). In the vertical dimension the closest correlation ($r=0.49$) was found between the vertical movement of subspinale (A) and pronasale (Pn). This study found that the tip of the nose elevated 90% of the elevation of subspinale. Proffit³⁸ indicated that his studies have shown the vertical movement of the nose to be only temporary. This study found that these changes remained even after the reduction of swelling. This could be due, however, to the method of landmark identification. The large variation in vertical movement of the nose

may be due to the method of selection of pronasale. There is no specific criteria for its selection other than the most anterior point on the tip of the nose. Difficulty was noted in selecting the same soft tissue point with respect to the vertical position, on both the pre- and post-op films. Tracing error could account for the large ratio of movement.

Auto-rotation of the lower jaw followed impaction of the maxilla. Our study found a close correlation between the movement of the lower incisor (Ii) and the lower lip (Li) in a horizontal direction (2:3). In the vertical dimension, the lower lip elevated 24% more than the lower incisal edge. A portion of this may be due to the manner with which the lower jaw rotates. The lower lip, being located at a greater distance from the center of condylar rotation than the lower incisor, will rotate along a slightly longer arc. The greater movement may also be a result of the uprighting of an everted lower lip which will be discussed later.

MANDIBULAR SURGERY

Strong correlations were found between all soft to hard tissue during horizontal movements accompanying mandibular advancement or retraction. It was found that the lower lip moved by a ratio of 0.58:1 of the horizontal movement of the lower incisor. This is less than what has previously been reported in the literature. Wolford³⁷ reported a ratio of 0.67-0.85:1, while Proffit³⁸ recommended a ratio of 0.60-0.70:1 lower lip to lower incisor movement.

The movement of the soft tissue overlying the chin (Po') was 1.17:1 mm. This is nearly 20% greater movement than the general ratio of 1:1 which has been previously reported in the literature.^{11-14,37,38} Similarly soft tissue B (B') exceeded the movement of supramentale (B) by 20%. The movement of these two landmarks to their corresponding hard tissue landmark was strongly correlated ($r=0.93$).

COMBINATION SURGERY

The patients who were treated with multiple jaw surgery exhibited a greater variability in the ratio of movement than was found in the previous two groups. Those patients who were treated through multiple surgeries may have exhibited greater skeletal deformities than those in the other groups thus requiring greater amounts of bony movement to achieve an aesthetic result. The combination of types of surgery, with alteration of a greater number of landmarks and movements being made to the limits of the tissue, undoubtedly has affected the outcome of the results on some individuals. This study found that the upper lip advanced by a ratio of 4:3 to subspinale (A), while the ratio of movement of the upper lip related to the upper incisor was only 1:2. It was noted in review of the postoperative records that many of these patients were treated by segmentally repositioning the maxilla. Clockwise or counter-clockwise rotation of the anterior segment around a center close to prosthion could account for the seemingly greater movement of the upper lip compared to the alveolar bone.

Movement of the nasal landmarks was highly variable and difficult to predict. Correlation coefficients for the movement of the landmarks of the nose to the hard tissue landmarks were low ($r=0.35-0.63$). Horizontal movement of subnasale and pronasale to subspinale were slightly greater than 0.60:1. The vertical movement of the tip of the nose (Pn) to impaction at subspinale (A) was greater than a 1:1 ratio. This, again, may be due to the difficulty in selecting the pronasale landmark in a vertical direction.

The results of this study of the effects of combined surgery of the soft tissue of the lower face are similar to the study reported by Proffit.³⁸ The lower lip followed the horizontal movement of the lower incisor by a ratio of 3:4 and the ratio of vertical movement for the same points due to auto-rotation was 1:1. Response of the soft tissue in the chin area was slightly less than a 1:1 ratio.

GENIOPLASTY

The patients were subgrouped according to the use of sliding bone genioplasty or alloplastic implant chin augmentation to discern whether there was a difference in response of the overlying soft tissue. It was found that in all cases the lower lip followed infradentale (B) movement by an approximate ratio of 0.45:1, which is less than the ratio of 0.67-0.85:1 reported in the literature.^{12,13} Similarly, soft tissue B (B') followed hard tissue B by a ratio of 1.14-1.17:1, which is greater than the 1:1 ratio found in previous studies.^{12,29}

The response in soft tissue pogonion was somewhat variable among the groups. Patients who did not receive a genioplasty exhibited a ratio of horizontal movement of soft tissue pogonion to hard tissue pogonion of 0.97:1. Patients in the genioplasty group had a ratio of 0.92:1 Po' to Po compared to the 0.60-0.70:1 reported by Proffit.³⁸ Those who received implants for chin augmentation responded with a ratio of 1.31:1 soft tissue to hard tissue movement, which is considerably greater than the ratio of 0.85:1 found in previous studies.^{27,37} The results of this area of study are that the soft tissue pogonion responds with a greater ratio of movement than has previously been reported when an implant is utilized to augment the chin. In digitizing the bony landmarks, care was taken to discern the outline of the implant when selecting the appropriate "hard tissue" pogonion to avoid influencing the results through tracing error.

There was a poor correlation ($r < 0.70$) between the vertical movements of the hard and soft tissue chin landmarks, such that the resultant movement cannot be predicted. This again may be due to the difficulty in selecting a consistent vertical location of Po'.

OTHER VARIABLES

Contrary to the findings of Stella³¹, who reported a reduction in lip thickness of 2 mm following maxillary advancement, this study did not find any thinning of the upper or lower lip. In fact, the mean lip thickness was quite stable regardless of the closure technique. This study found an average decrease in the upper lip thickness of

less than 1 mm following maxillary advancement. Retraction of the maxilla did not have any affect upon the upper lip thickness. There was, however, a difference in the method of measurement of lip thickness compared to previous studies. This study measured the distance between prosthion and labrale superius when determining upper lip thickness, while Stella measured the thickness of the upper lip between subspinale and the most posterior point along the upper lip sulcus.

Numerous studies have addressed the effects of maxillary impaction upon the width of the alar base and indicate that with maxillary impaction the base of the nose tends to widen and the upper lip thins out. It has been suggested that the surgeon may be able to control those effects on the soft tissue through the selective use of alar base suture and VY closure techniques. This study found, however, that the method of closure may have more of an effect upon the frontal appearance of the patient than upon the profile, as very little difference was noted between the VY and normal closure subgroups. When grouped according to closure techniques, the mean change ratio for labrale superius (Ls) to prosthion (Pr) was nearly identical for both the VY closure (0.1.04:1) and the normal closure group (1.03:1). Coupled with the previously mentioned information concerning change in upper lip thickness it could be assumed that influence of the method of closure with respect to the profile is minimal.

As with the results concerning upper lip thickness, it was found that the lower lip thickness was quite stable. This study found an average decrease in lower lip thickness of less than 1 mm following the surgery.

Many of the patients, at rest, exhibited a large interlabial distance prior to surgery. This study found an average reduction of the interlabial gap of 2.48 mm for the entire sample group. The maximum amount of closure was 12.90 mm. Patients who were treated by impacting the maxilla demonstrated a mean closure of 3.60 mm due to the auto-rotation of the mandible. The other methods of surgery resulted in lesser amounts of closure.

One area of interest derived from this study was the effect of the surgery on the angle of the lower lip. Data was collected with respect to patients who had an everted lower lip prior to surgery. Measurements of the mandibular sulcus angle revealed that the mean angular value was 12° less for this group (mean= 114°) than more normal appearing individuals (mean= 126°). Following the surgical procedure the mean angular measurement for individuals having a pre-surgical eversion of the lower lip was 124° , a change of 10° (Fig. 6). This contrasts with the mean change value of only 2° (post-op mean= 128°) for the normal appearing individuals. This change could have a dramatic affect upon the post-surgical aesthetics of the individual and should be considered by the clinician when making a presurgical diagnosis and treatment plan.

SUMMARY

This study examined 327 individuals to determine the effects of orthognathic surgery and post-op orthodontics on the soft tissue profile. Patients were subgrouped according to the type of surgery utilized in treatment as well as a number of variables. The conclusions reached were as follows:

- 1) Strong correlations were found between the horizontal movement of certain soft tissue landmarks and corresponding hard tissue landmarks for patients treated with maxillary surgery.
- 2) Poor correlations existed between the movement of the landmarks of the nose and the corresponding hard tissue landmarks.
- 3) Selection of many of the soft tissue landmarks commonly used today was difficult to reproduce accurately in both the horizontal and vertical dimension, as they are not based upon precise anatomical structures.
- 4) Strong correlations were found between the horizontal movement of certain soft tissue landmarks corresponding to hard tissue landmarks for patients treated with mandibular surgery. The ratio of movement in the chin region was greater than has been reported in the literature.
- 5) Patients treated through a combination of surgical techniques demonstrated a greater ratio of movement in the upper lip region than has been previously reported.
- 6) Horizontal movement of the soft tissue chin, when a genioplasty or implant was utilized, was found to be greater than has been previously reported.

- 7) The interlabial distance was reduced a significant amount following maxillary impaction.
- 8) An everted lower lip demonstrated a significant uprighting following correction of the skeletal imbalance.
- 9) There was a large variation in the response of individuals to a given treatment procedure.
- 10) A multitude of variables influenced the final aesthetic result. When these variables are identified by the practitioner they should be recognized as factors which affect the soft tissue response, and should be considered when selecting the appropriate treatment modality.

REFERENCES

1. Ricketts, R.M.: Planning treatment on the basis of the facial pattern and an estimate of its growth, part 1. *Angle Orthod* 1957;27:14.
2. Wylie, G.A., Fish, L.C., Epker, B.N.: Cephalometrics: a comparison of five analyses currently used in diagnosis of dentofacial deformities. *Internat J Adult Ortho* 1987;2:15.
3. Burstone, C.J.: Integumental profile, *Am J Orthod* 1959;44:1-25.
4. Peck, H., Peck, S.: A concept of facial esthetics. *Angle Orthod* 1970;40:284.
5. Legan, H.L., Burstone, C.J.: Soft tissue cephalometric analysis for orthognathic surgery, *J Oral Surgery* 1980;38:744-751.
6. McNamara, J.A., Ellis, E.: Cephalometric analysis of untreated adults with ideal facial and occlusal relationships. *Internat J of Adult Orthod* 1988;3:221.
7. Aaronson, S.A.: A cephalometric investigation of the surgical correction of mandibular prognathism, *Angle Orthod* 1967;37:251.
8. Bjork, N., Eliasson, S., Victorin, L.: Changes in facial profile after surgical treatment of mandibular protrusion. *Scand J Plast Reconstr Surg* 1971;5:41.
9. Robinson, W.W., Speidel, T.M., Isaacson, R.J., Worms, T.W.: Soft tissue profile change produced by reduction of mandibular prognathism. *Angle Orthod* 1971;41:227.
10. Robinson, W.W., et al: Soft tissue profile change produced by reduction of mandibular prognathism. *Angle Orthod* 1972;42:227.
11. Fromm, B., Lundberg, M.: The soft tissue facial profile before and after surgical correction of mandibular protrusion. *Acta Orthod Scand* 1972; 28:157.

12. Bell, W.H., Dann, J.J.: Correction of dentofacial deformities by surgery in the anterior part of the jaws: a study of stability and soft-tissue changes. *Am J Orthod* 1973;64:162.
13. Lines, P.A., Steinhauser, E.W.: Soft tissue changes in relationship to movement of hard structures in orthognathic surgery: a preliminary report. *J Oral Surgery* 1974;32:891.
14. Hershey, H.G., Smith, J.H.: Soft tissue profile change associated with surgical correction of the prognathic mandible. *Am J Orthod* 1974;65:483.
15. Dann, J.J., Fonseca, R.J., Bell W.H.: Soft tissue changes associated with total maxillary advancement: a preliminary study. *J Oral Surgery* 1976;34:19.
16. Schendel, S. A., Eisenfeld, J.H., Bell, W.H., Epker, B.N.: Superior repositioning of the maxilla: stability and soft tissue osseous relations. *Am J Orthod* 1976;70:663.
17. Freihofer, H.P.M.: The lip profile after correction of retromaxillism in cleft and non-cleft patients. *J Maxillofac Surg* 1976;4:136.
18. Epker, B.N., Fish, L.C.: The surgical-orthodontic correction of Class III skeletal open-bite. *Am J Orthod* 1978;73:601.
19. Epker, B.N., Fish, L.C.: Surgical-orthodontic correction of vertical maxillary excess. *Am J Orthod* 1978;73:241.
20. Bell, W.H., Jacobs, J.D.: Combined orthodontic-surgical correction of moderate mandibular deficiency. *Am J Orthod* 1979;75:481.
21. Engle, G.S., Quan, R.E., Chaconas, S.J.: Soft-tissue change as a result of maxillary surgery: A preliminary report. *Am J Orthod* 1979;75:291.

22. Bell, W.H., Proffit, W.R., and White, R.P.; Surgical correction of dentofacial deformities. Philadelphia, 1980, W.B. Saunders Co.
23. Radney, L.J., Jacobs, J.D.: Soft-tissue changes associated with surgical total maxillary intrusion. Am J Ortho 1981;80:191.
24. Bell, W.H., Dann, J.D.: Tridimensional planning for surgical/orthodontic treatment of mandibular excess. Am J Orthod 1981;80:263.
25. Bell, W., Jacobs, J., Quejada, J.: Simultaneous repositioning of the maxilla, mandible, and chin. Treatment planning and analysis of soft tissues. Am J Orthod 1986;89:28.
26. Epker, B.N., Fish, L.C.: Dentofacial Deformities: Integrated Orthodontic and Surgical Correction, Philadelphia, 1986, The C.V. Mosby Co.
27. Dann, J.J., Epker, B.N.; Proplast genioplasty: a retrospective study with treatment recommendations. Angle Orthod 1977;47:173.
28. Mansour, S., Burstone, C., Legan, H.: An evaluation of soft-tissue changes resulting from Le Fort I maxillary surgery. Am J Orthod 1983;84:37.
29. Quast, D.C., Biggerstaff, R.H., Haley, J.V.: The short-term and long-term soft tissue profile changes accompanying maxillary advancement surgery. Am J Orthod 1983;84:29.
30. Phillips, C., Devereux, J., Tulloch, J.: Tucker, M., Full-face soft tissue response to surgical maxillary intrusion. Internat J Adult Orthod 1988;1:299.
31. Stella, J.P., Streater, M.R., Epker, B.N.: Predictability of Upper Lip Soft Tissue Changes With Maxillary Advancement. J Oral Maxillofac Surg 1989;47:697.

32. Lines, P.A., Steinhauser, E.W.: Diagnosis and treatment planning in surgical orthodontic therapy. *Am J Orthod* 1974;66:378.
33. Worms, F., Isaacson, R., Speidel, M.: Surgical Orthodontic Treatment Planning: Profile Analysis and Mandibular Surgery. *Angle Orthod* 1976;46:1.
34. Fish, L.C., Epker, B.N.: Surgical-Orthodontic cephalometric prediction tracing. *J Clinical Orthod* 1980;14:36.
35. Bench, R.W., Gugino, C.F., Hilgers, J.J.: Bioprogressive Therapy: Part 2-Principles of the Bioprogressive Therapy. *J Clinical Orthod* 1977;11:661.
36. Bench, R. W., Gugino, C. F., Hilgers, J.J.: Bioprogressive Therapy: Part 3-Visual Treatment Objective. *J Clinical Orthod* 1977;11:744.
37. Wolford, L.M., Hilliard, F.W., Dugan, D.J.: Surgical Treatment Objective, Philadelphia, 1985, The C.V. Mosby Co.
38. Proffit, W.R., White, R.P.: Surgical-Orthodontic Treatment, St. Louis, 1991, Mosby Year Book, Inc.
39. Jensen, A.C., Sinclair, P.M., Wolford, L.M.: Soft tissue changes associated with double jaw surgery. *Am J Orthod Dentofac Orthop* [in press].
40. Sarver, D.M., Johnston, M.K., Matukas V.J.: Video imagining in planning and counseling in orthognathic surgery. *J Oral Maxillofac Surg* 1988;46:939.
41. Burstone, C.J.: Lip posture and its significance in treatment planning. *Am J Orthod* 1967;53:262.
42. Bamrind, S., Franz, R.C.: The reliability of headfilm measurements, 1. Landmark identification. *Am J Orthod* 1971;60:111.

43. Steuer, I.: The cranial base for superimposition of lateral cephalometric radiographs. Am J Orthod 1972;61:493.

PARCHMENT DEED

SOUTHWORTH CO. U.S.A.

100% COTTON FIBER