



Bulletin of the International Association for Paleodontology

Volume 15, Issue 2, 2021

Established: 2007

CONTENT

Denise Rabelo Maciel, Daniel Fidalgo, Cláudio Costa, Verônica Wesolowski, Edgard Michel Crosato, Maria Gabriela Haye Biazevic / Estimation of age at death based on the analysis of third molar mineralization in individuals from Brazilian archaeological populations	58
Anastasiia V. Sleptsova / Non-metric dental trait variation among Western Siberian forest-steppe populations in the Great Migration period	66
Beshlina Fitri W.R. Prakoeswa, Arofi Kurniawan, Aspalilah Alias, An'nisa Chusida, Maria Istiqomah Marini, Beta Novia Rizky / Palatal rugoscopy as an aid for sex determination in Tengger population, Indonesia	77
Anahit Yu. Khudaverdyan / Bronze and Iron Ages warriors from the Qarashamb burial ground: anthropological and paleopathological perspective	83
Resham AV, Vivek Pakhmode / Occurrence of three-rooted permanent mandibular molar and its possible link with archaic human - an overview	98
Tin Crnić, Andrej Janeš, Željka Bedić / Paleopathological and traumatic changes on the mandible of the skeleton found at the Bijela - St. Margaret site	102

Reviewers of this issue:

Olga Botanina, Nikita Efthymia, Katie Faillace, Tams Hajdu, Senad Muhasilović, Emilio Nuzzolese, Ashwin Prayudi, Svend Richter, Vineeta Saini, Aida Selmanagic, Nataša Šarkić and Ksenija Zelić.

We thank all the reviewers for their effort and time invested to improve the papers published in this issue.

Paleopathological and traumatic changes on the mandible of the skeleton found at the Bijela - St. Margaret site*

• Tin Crnić (1), Andrej Janeš (2), Željka Bedić (3) •

1 – Independent researcher, Mainz, Germany

2 – Division for Archaeological Heritage, Croatian Conservation Institute, Zagreb, Croatia

3 – Anthropological Centre, Croatian Academy of Sciences and Arts, Zagreb, Croatia

Address for correspondence:

Željka Bedić

Anthropological Centre,

Croatian Academy of Sciences and Arts, Zagreb, Croatia

E- mail: zeljka.bedic@gmail.com

Bull Int Assoc Paleodont. 2021;15(2):102-109.

Abstract

The Anthropological Center of the Croatian Academy of Sciences and Arts received human bone remains from the Late Medieval and Early Modern Period site of Bijela - St. Margaret derived from research conducted in 2019. The human remains found in grave number 22 caught the attention due to the atypical position of a male aged between 40 and 50 years at the time of death and trauma visible on the anterior region of the mandibular bone. In the same region pathological changes were also visible microscopically and on the X-Ray scan. In this case report the description of the changes on the mandibular bone and the possible etiology is presented.

Keywords: burial; incision; mandible; paleopathology; trauma

** Bulletin of the International Association for Paleontology is a journal powered by enthusiasm of individuals. We do not charge readers, we do not charge authors for publications, and there are no fees of any kind. We support the idea of free science for everyone. Support the journal by submitting your papers. Authors are responsible for language correctness and content.*



Introduction

Discovering the human remains provides a possibility to retrospectively diagnose the cause of death. Paleopathological cases have shown a great importance of the interdisciplinary odontological studies in the investigation of historical figures (1).

Lesions on the mandibular bone can be closely examined and be used to find out the cause of death or the nature of the lesion (2).

Apart from the infectious diseases, injuries can also be the reason for bone damage. Due to its prominent position, the maxillofacial skeleton is often fractured (3). The injuries in the facial region are of a significant importance as they provide the anterior protection of the cranium and are responsible for the appearance. The injuries in the facial region can be fatal as they can lead to serious complications or can be associated with skull, brain, and cervical injuries (4). If there is evidence of trauma or damage on skeletons or single bones, it raises the question whether these were made in an antemortem, perimortem, or postmortem time frame. Perimortem trauma (trauma that occurred around the time of death), is of great forensic interest as it can indicate clues about the manner and cause of death. Antemortem injuries are those which were made before the death, but they are not directly connected with the cause of death, however they can still be useful for the identification purposes. The damages on the skeleton can also occur during the retrieval of remains and are called postmortem damages. The closer in time the damages have been inflicted to the time of the death event, the harder it is to determine whether the damages on the bones were made in antemortem, perimortem or postmortem time frame. Postmortem changes on the bones can occur due to the exposure of the bones to the surrounding deposition conditions in addition to already existing postmortem changes or antemortem inflections which may greatly complicate the problem.

During the anthropological analysis of the osteological material excavated in 2019 in Bijela - St Margaret site, a paleopathological case of cut inflicted with the sharp edged instrument and periapical process on the mandible was recorded. In this study, a description of observed changes in the mandible as well as possible etiology of the case is discussed.

Material and methods

The remains of the Benedictine Monastery of St. Margaret complex are situated 1 km to the south of the village Bijela and 6 km to the southeast of Daruvar in Croatia.

Although historical sources are missing it can be presumed that the establishment of the Benedictine monastic community happened sometimes during the 13th century. In the 14th century it was mentioned as a locus ecclesiasticus, a priory, a monastery and, finally, as an abbey (5). During the 15th century it was fortified, the Bishop of Zagreb mended its structures and it was used as a military facility before it was given to the monks in 1513. The presumption was that it was abandoned around 1543 and left to decay through time, however the graves interred in the church during the 16th and 17th centuries suggest otherwise (5). So far nine systematic archaeological excavation campaigns (2012-2019) were concentrated on the area of the monastic church. Numerous architectural elements, some small finds, and 36 graves dating from 13/14th to 17th centuries were uncovered (6). Sex of the individual from grave 22 was estimated on the basis of cranial and os coxae morphology following standards set by Buikstra and Ubelaker (7). Age-at-death was estimated using morphological changes in the pubic symphysis (8, 9), the auricular surface of the ilium (10), and dental attrition criteria established by Brothwell (11) and Smith (12). A detailed inventory of all present bones and teeth was done. The tooth inventory was performed using a form in which each tooth is coded as: present, antemortem loss, postmortem loss, none, or partially erupted. The presence of caries and alveolar abscesses has been conducted. The X-Ray scan also helped in determining the demineralized changes of the teeth. Radiograph was scanned in the Department of Diagnostic and Interventional Radiology, University Hospital Centre "Zagreb".

Results

The burial was found in the northern part of the monastery church, in an atypical position for the burial customs and practices of the time. The skeleton was buried in the pit in the position that deviates from the classic burial on the back with outstretched legs and arms placed next to the body / chest / abdomen / pelvis (Figure 1).

The skeleton gives the impression that it was disposed of into the burial. It was lying on its back

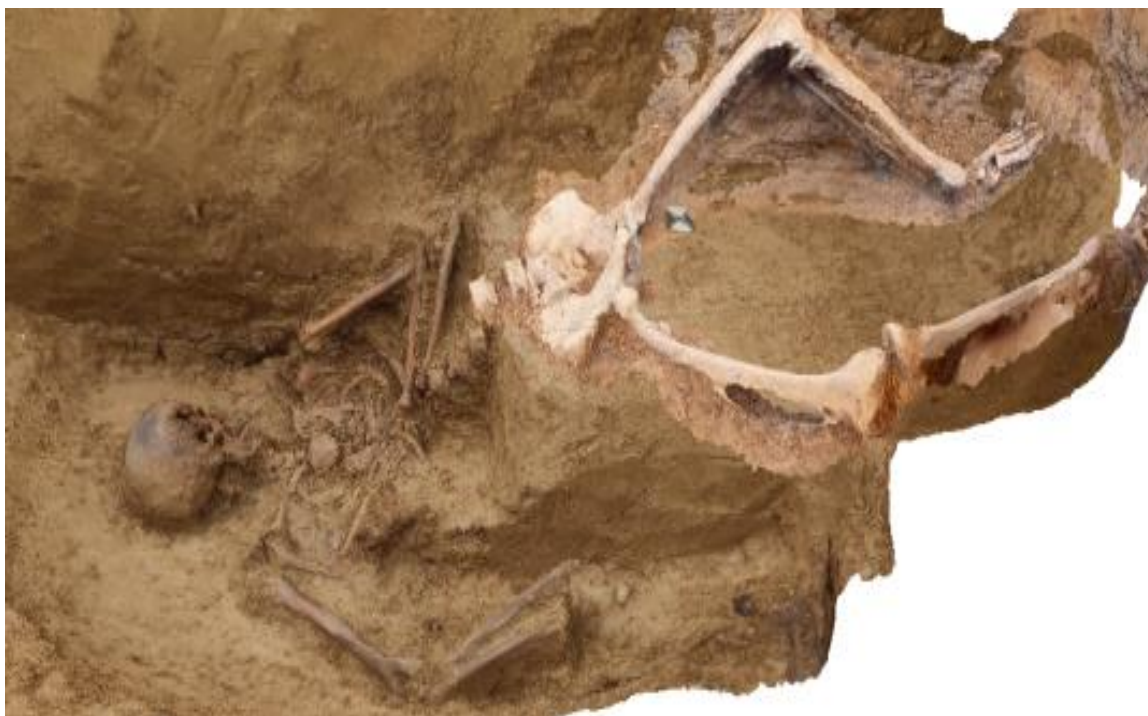

Figure 1. Atypical position of the individual from the grave 22 (author Gligora V.).

while the upper part of the skeleton (head and torso) was located deeper than the lower part of the body (pelvis and legs). The legs were spread at the knees, and the feet were resting on the walls of the burial. Since labile articulations were preserved, and in anatomical position it can be assumed that this was a primary burial, i.e. that burial occurred rapidly after death (13). No burial goods were found in the grave.

The skeleton was dated by radiocarbon method to AD 1489 to 1603 (2 sigma range 95.4% probability), i.e. AD 1521 to 1591 (1 sigma range 68.3% probability).

According to this result, this man was thrown into a pit inside the church (or buried very strangely, outside the customs of the time) during the second half of the 16th century. From the point of view of archaeologists, this is interesting because it happens at a time when the monastery is almost certainly not functioning.

Using standard anthropological criteria it was estimated that an individual from grave 22 was male aged between 40 and 50 years at the time of death. The degree of preservation of the skeleton in this report is shown graphically, and the preserved bones are marked in orange (Figure 2). The presence or absence of teeth of the analyzed teeth is also shown in this report graphically. Orange means that the tooth is present in the preserved sample, yellow means

that the tooth fell out antemortem, and green means that the tooth fell out postmortem. Black mark on the tooth crown scheme represents caries, and the dashed mark on the root of the tooth indicates the presence of alveolar abscess (Figure 3).

On the mandibular bone, at the site of the left second incisor, on the posterior part of the alveolar bone, a small antemortal incision 7 mm long and 0.35 mm wide at the inferior end is present. The superior part of the incision is damaged postmortem which unabled the measurement. The wound seems to be an injury from a sharp instrument (Figure 4a, b). The alveolus of the tooth is completely remodelled and inferiorly a lesion of dimension 10 × 7 mm is present.

The lateral portion of the alveoli of the first left incisor was also remodeled, and the tooth fell out antemortal. Thickening is present on the inferior part of the mandibula, with one larger (5 × 4 mm) and two smaller (2 × 1 and 1 × 1 mm) openings (Figure 5). The openings are communicating through the canal that is visible on the X-Ray scan (Figure 6).

Furthermore, horizontal bone resorption is present in the lower jaw, which indicates an antemortal chronic periodontal disease (Figure 7).

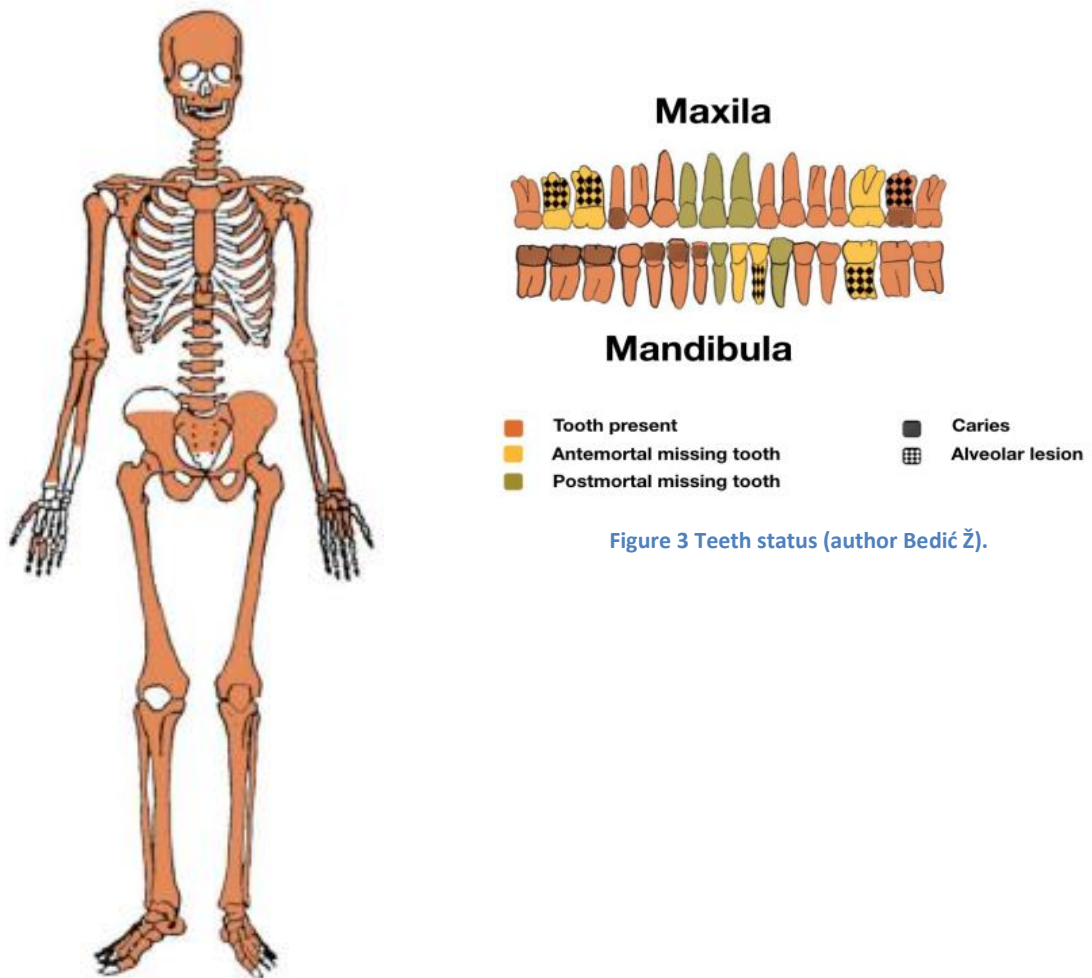


Figure 3 Teeth status (author Bedić Ž).

Figure 2 Schematic representation of the preserved bones of the skeleton (author Bedić Ž.)

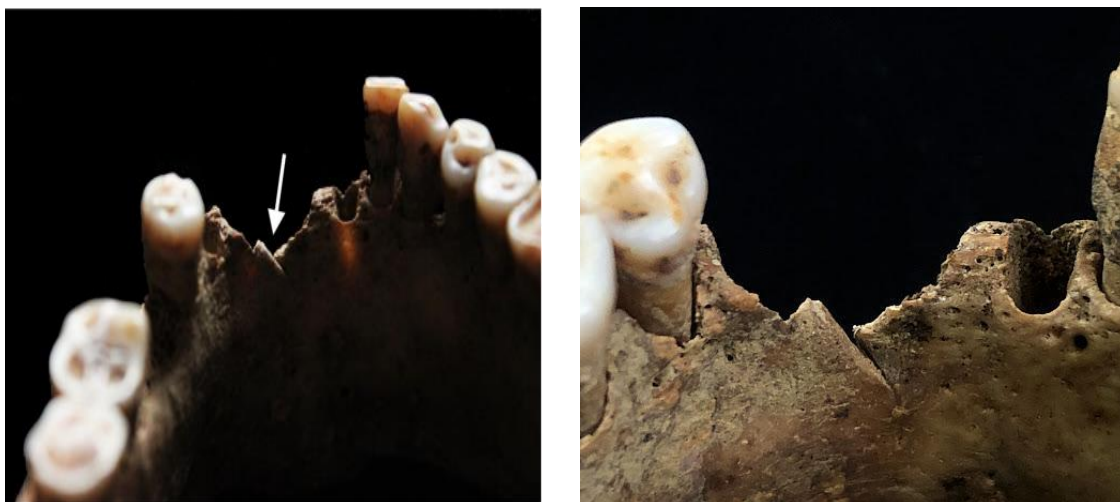

Figure 4 Left: 7 mm long antemortal incision on the mandible. Right: A detail of the antemortal incision (author Vyroubal V.)



Figure 5. On the inferior part of the lower jaw there is a thickening of the bone with one larger and two smaller openings (author Vyroubal V.).

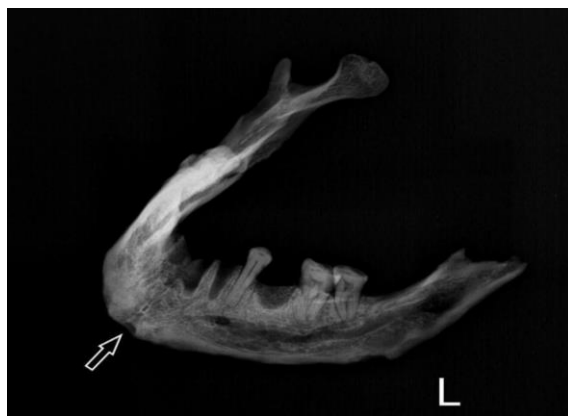

Figure 6. X-Ray scan of the mandible. Visible canal (white arrow) on anterior part of the mandible in the incisor region.

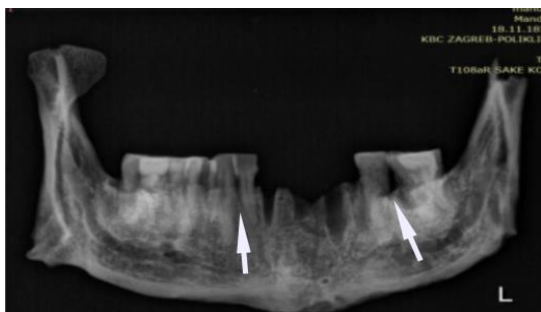

Figure 7. X-Ray scan. Horizontal bone loss.

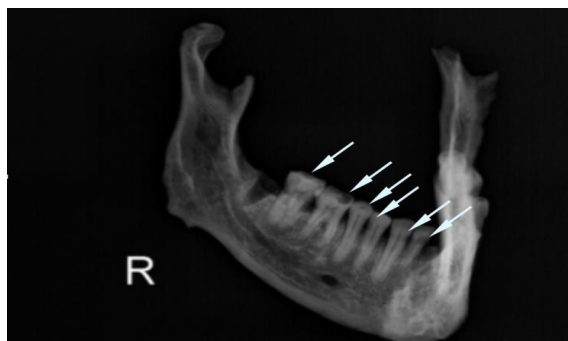

Figure 8. X-Ray scan. Visible demineralized changes on the teeth.



Figure 9. Razor blade found at the site Bijela - St Margaret (author Škudar J.).

The teeth have lost their occlusal morphology antemortally due to the dental abrasion. What is more, X-Ray scan showed the existence of demineralized sites which were made either by erosion or by caries antemortal. The demineralized sites can be visible on the first and second mandibular right molar on the occlusal surface, on the second mandibular right premolar on the occlusal surface, on the first mandibular right premolar on the distal surface, on the mandibular left canine on the mesial site and on the second right mandibular incisor on the mesial site (Figure 8).

Discussion

The discovery of the skeleton in the grave 22 showed an atypical position for the burial customs and practices, giving an impression that the individual was carelessly thrown or buried into the pit.

The mandibular bone caught the attention with the small antemortal incision 7 mm long at the site of the left second incisor which could have been caused by the sharp instrument. There is a wide classification of weapons that can be done by examining the kerf floor of the bone injury, where a narrow V shaped floor indicates a bladed instrument that is thin, whereas a thicker or heavier blade (e.g. axe or machete) create a wider or squared kerf (14). The blade of the weapon will determine if the cut will be deep and narrow or deep and wide where the blades that are not so sharp will produce a kerf with a squared floor (14). If the wound looks like an incision, the bone markings will follow that contour, however if there is a stabbing wound, it will show punctures or gouges in the bone (14). When documenting sharp force trauma, variables for documenting sharp force trauma can be used (14).

Therefore, we could say that the visible trauma on the mandibular bone of the skeleton in the grave 22 was initially a cut caused by a thin instrument. In context of possible interpersonal violence it has to be noted that in the cemetery of Bijela a total of 56 traumas were recorded on 17 adults, 21 of which were antemortem, while 35 were perimortem. Four males and two females exhibited perimortem traumas, all of which were inflicted with sharp-edged weapons such as swords, sabres and knives indicating that members of this community were subjected to high levels of intentional violence (6). Therefore it is possible that an individual from grave 22 was

also a victim of violence although the location on the mandibular bone, at the site of the left second incisor seems atypical.

The visible trauma did not kill, however it might have been the consequence that followed the emergence of the periapical lesion that created three openings on the mandibular bone inferior to the trauma and the canal that is connecting them (visible on the X-Ray scan). As the X-Ray scan and the macroscopic analysis of the mandibular bone show a horizontal bone resorption, due to the periodontal disease (15) and some demineralization of the teeth (caries), it could be possible that the person underwent the tooth extraction due to the pain. In the period between 14th-18th centuries, people had very poor oral hygiene, where they used pieces of linen, sponge or toothpicks to scrub their teeth. Due to poor oral hygiene, tooth decay and periodontal disease can occur (15, 16).

From the 14th until the 18th century, an instrument called "Pelican", as it reminded of the large-beaked bird, was used for tooth extraction (17). The instrument was hammered by the blacksmith and the treatment with such an instrument was very painful and it caused a severe laceration of the gums, haemorrhaging, and could fracture a jaw bone even when used proficiently (18). In order to use it properly, the claw of the instrument needed to be placed on the crown of the tooth and the bolster against the outside gum. In order to extract the tooth, the handle needed to be pressed down (18). The procedures were done depending on the economical status of the individuals. The rich people could afford "an operator for the teeth" whereas for others, the local blacksmith and "tooth drawer" would extract teeth (19, 20).

In this context it is interesting that stable isotope analysis was performed for the individual from the grave 22. The stable isotope analysis was conducted in 14CHRONO Centre, Queen's University Belfast. High value (11.9‰) of ^{13}C , which is also the highest value among 13 sampled individuals, indicates a better diet with more proteins of animal source, possibly young animals or even in combination with a diet rich in fish (21). This could be an argument for his higher social status.

Besides "Pelican" some other bladed instruments must come into consideration. Razor blades have been found at Bijela - St Margaret site (Figure 9) and due to their sharpness they could easily serve as an instrument for the

extraction. It is questionable if during those times the instruments have been properly sterilized, as the sterilization and decontamination process prevents cross infection and reduces the microbiological load in the operative environment (22). The transmission of the microbes occurs when the pathogens come into direct contact with tissue, either through blood or secretions by indirect contact with infected instruments (23). Thanks to the development of medicines, we have less post treatment infections today (24). When the wound is colonized by microorganisms, they can cause an infection and possibly create an abscess. If the pus from the abscess is created, it will first go through the bone (enoseal abscess), followed by the sensitive subperiosteal abscess which creates acute and severe pain until the periosteum is penetrated and the pus drains into the tissue (submucosal abscess) (15, 25, 26) This can explain the canals and openings on the mandibular bone as the pus tries to drain itself through "locus minoris resistentiae" sites. Odontogenic subacute and acute inflammation is most often limited to the area around the tooth where it goes through all or only some stages of inflammation until it "calms down" and becomes chronic again or heals temporarily. This is characteristic of all inflammations of odontogenic etiology regardless of whether the tooth is the source or the path of infection into the bone because when there are no teeth, there is neither apical nor pericoronoary nor periodontal pathway and when the tooth is extracted or if an adequate surgery is done, a complete healing is expected. The peculiarity of the odontogenic inflammations is that the infection rarely remains and spreads into the bones, but by the shortest path, or where there is least resistance, penetrates the surface of the bone into the soft tissues. Therefore, the inflammation from the periapical area tries to go through the shortest path through the bone, most commonly into the vestibulum, however the penetration can go through the skin as well (26). Historical cases of procedures involving oral cavity with the sharp blade instruments were previously recorded. A condition such as necrotizing ulcerative gingivitis (NUG) is a gum disease that causes bone destruction which leads to tooth loss. Due to its nature, people suffering from NUG have trouble eating and swallowing. Such a condition was greatly prevalent among soldiers who were stuck in trenches in World War I and barbers have been cutting the necrotizing tissue of soldiers that were suffering from gum necrosis in order to allow them to chew and swallow their meal (1).

As for the lack of information and data, it is unknown whether the individual odontogenic infection was the cause of death. Today, we know that oral health is connected with general health, and the relationship between oral and general health has been the focus of researchers' interest for decades. We know that the respiratory, cardiovascular, high blood pressure, diabetes, dementia and mortality are linked with the periodontal disease (27-29).

Conclusion

The human skeleton that was found at the Bijela-St. Margaret site, in grave 22, was in an atypical position for the burial customs and practices during that time, giving an impression that the individual had to be buried in the ground carelessly or without any pity. Due to the poor oral hygiene, the individual was suffering from periodontal disease (horizontal bone loss) and had decayed teeth, which could have caused the pain and the reason for the tooth extraction. The incision visible on the mandibular bone appears to be a trauma done during the tooth extraction, whereas the openings on the bone and the canals through which the openings are communicating in the same area where the incision is visible, could have appeared before the extraction itself due to the odontogenic infection. However, due to the lack of information it is unknown whether this clinical situation was the cause of death. Nevertheless, the fact that this patient was treated in order to alleviate the pain, as well as the small number of similar cases in the literature makes this presented example relevant for the history of dentistry and medicine in general.

Declarations of interest:

None.

Author contributions

T.C. and Ž.B. conceived of the presented idea. Ž.B. analysed the osteological material. T.C. developed the theory and wrote the manuscript with support from Ž.B. A.J. gave access to material, provided an archaeological and historical context. All authors discussed the results and contributed to the final manuscript.

References

1. Charlier P, Augias A, Benmoussa N, et al. The mandible of Saint-Louis (1270 AD): Retrospective diagnosis and circumstances of death. *J Stomatol Oral Maxillofac Surg.* 2020;121(2):172-174.

2. Byard RW, Maxwell-Stewart H. Scurvy-characteristic features and forensic issues. *Am J Forensic Med Pathol.* 2019;40:43–6.
3. Kumar GB, Dhupar V, Akkara F, Kumar SP. Patterns of maxillofacial fractures in Goa. *J Maxillofac Oral Surg.* 2015;14(2):138–141.
4. Rupani R, Singh M, Kumar V, Singh R, Kumar S, Yadav P. The maxillofacial injuries: A postmortem study. *Natl J Maxillofac Surg.* 2018;9(1):48–51.
5. Janeš A, Sekulić P. Rudina i Bijela: benediktinski samostani kasnosrednjovjekovne Slavonije. *SHP.* 2014; III, No. 41: 185–204.
6. Bedić Ž, Janeš A, Šlaus M. Anthropological analysis of trauma frequencies and distribution in the skeletal series from the Benedictine monastery of St Margaret in Bijela, Croatia. *Coll Antropol.* 2019; 43(2): 141–146.
7. Buikstra JE, Ubelaker DH. *Standards for Data Collection from Human Skeletal Remains.* Fayetteville; 1994.
8. Brooks S, Suchey JM. Skeletal age determination based on the os pubis: A comparison of the Acsádi-Nemeskéri and Suchey-Brooks methods. *Hum Evol.* 1990; 5:227–238.
9. Gilbert BM, McKern TW. A method for aging the female os pubis. *Am J Phys Anthropol.* 1973; 38:31–38.
10. Lovejoy CO, Meindl RS, Pryzbeck TR, Mensforth RP. Chronological metamorphosis of the auricular surface of the ilium: A new method for the determination of age at death. *Am J Phys Anthropol.* 1985; 68:15–28.
11. Brothwell D.R. *Digging Up Bones.* Oxford University Press: 1981.
12. Smith BH. Patterns of molar wear in hunter gatherers and agriculturalists. *Am J Phys Anthropol.* 1984; 63:39–56.
13. Duday H. *The Archaeology of the Dead: Lectures in Archaeoethnology,* Oxbowbooks, 2009.
14. Annand P. Preliminary Investigation of Trauma Inflicted Using Sharp Hacking Implements With Focus on Scanning Electron Microscopy To Distinguish Weapon and Blade Subtype [master's thesis]. Perth: University of Western Australia; 2018.
15. Lindhe J, Lang NP, Karring T. *Klinička parodontologija i dentalna implantologija.* 5. izd. editor. Zagreb: Nakladni zavod Globus; 2010.
16. Akinyamoju CA, Dairo DM, Adeoye IA, Akinyamoju AO. Dental caries and oral hygiene status: Survey of schoolchildren in rural communities, Southwest Nigeria. *Niger Postgrad Med J.* 2018;25(4):239–245.
17. Dental Solutions of Columbus. History of tooth extraction. 2017. Available online: <https://columbusdentalsolutions.com/history-tooth-extraction/> (Accessed 10 April 2021.)
18. British Dental Association (BDA). Pelican. Available online: <https://bda.org/museum/collections/dental-equipment/pelican> (Accessed 10 April 2021.)
19. Atkinson HF. Some early dental extraction instruments including the pelican, bird or axe?. *Aust Dent J.* 2002;47(2):90–93.
20. History Of Dentistry – Part 2 – The Middle Ages. Available online: <https://fortworthtexasdentist.com/history-of-dentistry-part-2-the-middle-ages/#> (Accessed 10 April 2021.)
21. Schoeninger MJ, DeNiro MJ, Tauber H. Stable isotope ratios of bone collagen reflect marine and terrestrial components of prehistoric diet. *Science.* 1983; 220: 1381–1383.
22. Ibrahim NK, Alwafi HA, Sangoof SO, Turkistani AK, Alattas BM. Cross-infection and infection control in dentistry: knowledge, attitude and practice of patients attended dental clinics in King Abdulaziz University Hospital, Jeddah, Saudi Arabia. *J Infect Public Health.* 2017;10(4):438–445.
23. Laneve E, Raddato B, Dioguardi M, Di Gioia G, Troiano G, Lo Muzio L. Sterilisation in Dentistry: A Review of the Literature. *Int J Dent.* 2019;2019:6507286. Published 2019 Jan 15.
24. Kolasiński W. Surgical site infections - review of current knowledge, methods of prevention. *Pol Przegl Chir.* 2018;91(4):41–47.
25. Torabinejad M, Walton RE. *Endodoncija, načela i praksa.* Zagreb: Naklada Slap; 2009.
26. Miše I. *Oralna Kirurgija.* Zagreb: Jugoslavenska medicinska naklada; 1982.
27. Morita I, Inagaki K, Nakamura F, et al. Relationship between periodontal status and levels of glycated hemoglobin. *J Dent Res.* 2012;91(2):161–166.
28. Sabbah W, Folyan MO, El Tantawi M. The Link between Oral and General Health. *Int J Dent.* 2019;2019:7862923. Published 2019 May 29. doi:10.1155/2019/7862923
29. Tsakos G, Sabbah W, Hingorani A., et al. Is periodontal inflammation associated with raised blood pressure? Evidence from a national US survey. *J Hypertens.* 2010;28:2386–2393.

