



UvA-DARE (Digital Academic Repository)

Solving Periprosthetic Leakage With a Novel Prosthetic Device

Petersen, J.F.; Lansaat, L.; Hilgers, F.; van den Brekel, M.

DOI

[10.1002/lary.27645](https://doi.org/10.1002/lary.27645)

Publication date

2019

Document Version

Final published version

Published in

Laryngoscope

License

CC BY-NC-ND

[Link to publication](#)

Citation for published version (APA):

Petersen, J. F., Lansaat, L., Hilgers, F., & van den Brekel, M. (2019). Solving Periprosthetic Leakage With a Novel Prosthetic Device. *Laryngoscope*, *129*(10), 2299-2302. <https://doi.org/10.1002/lary.27645>

General rights

It is not permitted to download or to forward/distribute the text or part of it without the consent of the author(s) and/or copyright holder(s), other than for strictly personal, individual use, unless the work is under an open content license (like Creative Commons).

Disclaimer/Complaints regulations

If you believe that digital publication of certain material infringes any of your rights or (privacy) interests, please let the Library know, stating your reasons. In case of a legitimate complaint, the Library will make the material inaccessible and/or remove it from the website. Please Ask the Library: <https://uba.uva.nl/en/contact>, or a letter to: Library of the University of Amsterdam, Secretariat, Singel 425, 1012 WP Amsterdam, The Netherlands. You will be contacted as soon as possible.

How I Do It

Solving Periprosthetic Leakage With a Novel Prosthetic Device

Japke F. Petersen, MD ; Liset Lansaat, Msc; Frans Hilgers, MD, PhD; Michiel van den Brekel, MD, PhD

INTRODUCTION

Total laryngectomy (TL) is still an indispensable surgical procedure for advanced and recurrent larynx and hypopharynx cancer. Tracheoesophageal prosthetic voice rehabilitation is the method of choice for restoring oral communication in most Western countries, with success rates of around 90%.¹ However, with an increasing rate of salvage TLs performed after failed chemo(radio)therapy, more attention is needed to maintain durable results.

Voice prostheses (VPs) have a median device lifetime of around 2 to 3 months, and the main indication for replacement is transprosthetic leakage, which is solvable by replacing the VP.²⁻⁴ Recurrent periprosthetic leakage is, however, a problem requiring more attention.³⁻⁶ It can be caused by normal gradual subsiding of postsurgical edema, making the VP too long and thereby permitting periprosthetic leakage, which is solvable by downsizing the VP.¹ Later in time, comorbidities such as gastric reflux, local infection, radiation effects, or recurrence of tumor can have a profound effect on the surrounding tissue. This can lead to atrophy and/or widening of the tracheoesophageal puncture (TEP) tract, also resulting in periprosthetic leakage.^{6,7} Therefore, comorbidities such as reflux first should be treated adequately when possible in order to prevent periprosthetic leakage on the long term.

Often, the easiest short-term solution is placing a thin silicone washer on the tracheal side of the VP if the VP is still functioning properly. This is a simple, effective, and cheap solution because there is no need to replace the

current VP. It is, however, obvious that in case of periprosthetic leakage the fluids originate from the esophageal side. A washer on that side is more effective than a washer on the tracheal side; otherwise, the fluids are still able to penetrate the TEP tract up to the tracheal side. However, this means replacement of the VP and thus higher costs. Patients known with recurrent periprosthetic leakage could benefit from instantly placing a VP with an enlarged esophageal flange. Thus, a new VP with an extraesophageal flange (Provox Vega XtraSeal [PVX], Atos Medical, Hörby, Sweden) was developed, which we tested at our institute.

MATERIALS AND METHODS

We performed a prospective evaluation on the efficacy, satisfaction, and ease of placement of the PVX among a consecutive cohort of patients seen in the outpatient clinic with periprosthetic leakage. After placement of the PVX, patients and physicians were asked to fill in a study-specific questionnaire regarding the satisfaction of (placement of) the PVX with regard to the handling of the insertion device and the procedure. Patients were excluded from follow-up (FU) if they had received two successive VPs other than a PVX.

Prosthesis

The PVX is an adjustment of the regular Provox Vega with an additional enlarged esophageal flange glued to the VP at the flange-shaft crossing (see Figure 1). The flange is angled, thin, and flexible, which should enhance its adherence to the surface around the TEP-tract to prevent leakage around the VP. The prosthesis is inserted with the regular insertion device, with special attention to the proper unfolding of the enlarged esophageal flange by inserting the entire VP into the esophagus (overshooting) and pulling the tracheal flange back in position.

Statistics

Descriptive statistics were used to report patient characteristics and Kaplan-Meier analysis to assess device lifetime. All analyses were done in SPSS Statistics 20.0 (IBM Corp., Armonk, NY).

This study does not fall under the scope of the Medical Research Involving Human Subjects Act, which was confirmed by the institutional review board (MREC16.1202).

RESULTS

We included 13 patients (85% male). The mean age at TL was 59 years, and median FU after TL was 117 months (see Table I).

Correction added on November 4, 2019, after first online publication: The copyright line for this article was changed in this PDF.

This is an open access article under the terms of the Creative Commons Attribution-NonCommercial-NoDerivs License, which permits use and distribution in any medium, provided the original work is properly cited, the use is non-commercial and no modifications or adaptations are made.

From the Department of Head and Neck Oncology and Surgery, The Netherlands Cancer Institute (J.F.P., L.L., F.H., M.V.B.); the Institute of Phonetic Sciences-Amsterdam Center of Language and Communication, University of Amsterdam (F.H., M.V.B.); and the Department of Oral and Maxillofacial Surgery, Academic Medical Center (M.V.B.), Amsterdam, The Netherlands.

Editor's Note: This Manuscript was accepted for publication on September 4, 2018.

The Netherlands Cancer Institute receives a research grant from Atos Medical, Sweden, which contributes to the existing infrastructure for health-related quality-of-life research of the Department of Head and Neck Oncology and Surgery. The authors have no other funding, financial relationships, or conflicts of interest to disclose.

Send correspondence to J.F. Petersen, MD, Plesmanlaan 121, 1066 CX Amsterdam, The Netherlands. E-mail: m.petersen@nki.nl

DOI: 10.1002/lary.27645

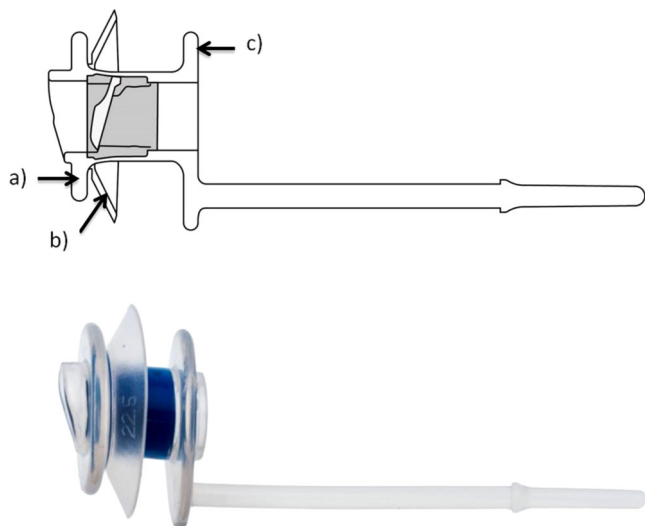


Fig. 1. Schematic drawing and actual photo of the Provox Vega XtraSeal (Atos Medical, Hörby, Sweden) showing (A) the location of the normal esophageal flange, (B) the extra thin, angled esophageal flange, (C) and the tracheal flange. [Color figure can be viewed in the online issue, which is available at www.laryngoscope.com.]

The reason for placement of the first PVX in each patient was periprosthetic leakage ($n = 11$), a too wide TEP tract ($n = 1$), or a lost VP ($n = 1$). These latter two replacements were performed in two patients who were known with recurrent leakage around the VP and were therefore included in this study. In these 13 patients, 26 PVXs were placed. Five patients received multiple PVXs during FU, with a maximum of seven PVXs in one patient (see Table II).

After replacement, the seal was checked by the patient drinking water. The seal was sufficient in 25 of 26 placements. In the remaining replacement, calcium hydroxyapatite (Radiesse; Merz Pharmaceuticals,

TABLE I.
Patient Characteristics

	No.	Percentage
Gender		
Male	11	85%
Female	2	15%
Mean age at TL (range)	59	40–79
Median FU in months* (range)	117	7–227
Indication TL		
Primary	5	39%
Salvage	5	39%
Dysfunctional	2	15%
Second primary	1	8%
Origin tumor		
Larynx	10	77%
Hypopharynx	1	8%
Other	2	15%

*FU in months was calculated from date of TL to date of removal of final VP.

FU = follow-up; TL = total laryngectomy; VP = voice prostheses.

Germany) was injected in the oval-shaped TEP-tract, which solved the persistent periprosthetic leakage.

Results from the study-specific questionnaire indicated that loading of the PVX in the insertion device went well in all cases except one, for which more force than usual was needed during the overshooting phase. All but one patient reported no difference in ease and discomfort during placement; this latter patient favored placement of the new VP.

Device Lifetime

The median device lifetime of the PVX was 68 days (95% CI 56–80). Median device lifetime of the former VP before placement of the first PVX was 38 days (95% CI 1–76). One patient died 3 days after placement of the PVX from a metastasized esophageal cancer. Former VPs led to aspiration problems; with the PVX, the patient was aspiration-free. A second patient with an irresectable tracheal recurrence also died with the third PVX in situ. The patient was free from periprosthetic leakage since insertion of the first PVX; the first two PVXs lasted 79 and 62 days, respectively.

Reason for Removal

The main reason for removal of the PVX was transprosthetic leakage in 50% (13 of 26), followed by leakage not otherwise specified in 15% (4 of 26), which probably all were cases of transprosthetic leakage. In one patient (4%) the PVX had to be removed because of periprosthetic leakage. See Table II for the other reasons. Two patients still had PVX in situ at last date of FU (June 2018), with device lifetime of 504 and 835 days, respectively. No adverse events occurred during the study period.

During FU, in seven patients the PVX was replaced with a Provox Vega, in three cases combined with a washer at the tracheal side. One patient went back to the usual ActiValve Light. The median in situ time of the subsequent non-PVX VP was 62 days. The reasons for removal of these non-PVX VPs were periprosthetic leakage ($n = 3$), transprosthetic leakage ($n = 3$), and surgical revision ($n = 1$). Of the five remaining patients, two still had a PVX in situ at last date of FU; two died; and the TEP-tract was closed in one patient.

DISCUSSION

In this prospective evaluation of the PVX, we were able to test the device lifetime, efficacy, and ease of placement. The median device lifetime was 68 days, comparable to the median device lifetimes of the Provox2 (63 days) or Provox Vega (66 days), which we recently found in a consecutive cohort of patients for over 13 years and is in line with other literature.^{2–4} Only one PVX needed replacement due to periprosthetic leakage, although in one patient the reason for removal was unknown and in four patients the leakage problem was not otherwise specified.

A recent meta-analysis reported an average rate of 7.2% of patients suffering from an enlarged TEP tract and/or periprosthetic leakage.⁸ The most commonly used

TABLE II.
Device Lifetime, Size, and Reason for Removal of PVX and Former VP for All Replacements

Pt	Indication TL	Type Old VP*	Size Old VP	DLT Old VP	Reason Removal Old VP	Size PVX	DLT PVX in Days	Reason Removal PVX
1	Salvage	ActiValve Light	4,5	147	PP leakage	10	3	Pt died
2	Second primary	Vega	8	7	PP leakage	8	22	TP leakage
3.1	Salvage	Vega	6	31	PP leakage	8	68	TP leakage
3.2	Salvage	PVX	8	NA	TP leakage	8	44	TP leakage
3.3	Salvage	Vega	8	NA	TP leakage	8	70	Unknown
3.4	Salvage	Vega	8	NA	PP leakage	8	232	Leakage NOS
3.5	Salvage	PVX	8	NA	Leakage NOS	8	42	TP leakage
3.6	Salvage	PVX	8	NA	TP leakage	8	92	TP leakage
3.7	Salvage	PVX	6	NA	TP leakage	6	27	TP leakage
3.8	Salvage	PVX	8	NA	TP leakage	8	504	NA, still in situ
4.1	Salvage	Vega + XtraFlange	10	105	PP leakage	10	133	TP leakage
4.2	Salvage	PVX	10	NA	TP leakage	10	223	TP leakage
4.3	Salvage	PVX	10	NA	TP leakage	10	835	NA, still in situ
5	DF larynx	Vega	8	99	PP leakage	8	34	Leakage NOS
6.1	Primary	Vega	10	28	PP leakage	10	63	Leakage NOS
6.2	Primary	PVX	10	NA	Leakage NOS	6	41	Leakage NOS
7.1	Salvage	Vega + XtraFlange	6	25	PP leakage	6	79	TP leakage
7.2	Salvage	PVX	8	NA	Unknown	8	62	TP leakage
7.3	Salvage	PVX	8	NA	Unknown	8	39	Pt died
8	Salvage	Vega	6	246	PP leakage	6	91	TP leakage
9	Primary	Vega	8	4	VP lost	8	15	PP leakage
10	Primary	Vega	8	38	PP leakage	8	156	TP leakage
11.1	Primary	Vega	8	20	Wide TEP tract	8	4	VP lost
11.2	Primary	PVX	8	NA	VP lost	8	28	Surgical revision
12	Dysfunctional larynx	ActiValve Light	8	60	PP leakage	8	36	TP leakage
13	Primary	Vega	8	222	PP leakage	8	232	Voice problems

*All VP used in this study are Atos Medical Products (Hörby, Sweden).
DF larynx = dysfunctional larynx; DLT = device lifetime; NOS = not otherwise specified; old VP = voice prostheses replaced with Provox Vega Xtra-Seal; PP leakage = periprosthesis leakage; Pt = patient; PVX = Provox Vega XtraSeal; TL = total laryngectomy; TP leakage = transprosthetic leakage; VP = voice prostheses.

treatments were temporary removal of the VP and injections at the TEP tract. Temporary removal and placement of a nasogastric feeding tube and cuffed canula is, however, quite cumbersome for the patient, and it might take several days before sufficient shrinkage is observed.⁸ Placement of a silicone washer is usually an elegant and conservative solution to manage periprosthesis leakage, especially when the VP is still functioning properly.⁹ If the insertion of a washer fails, other strategies such as injection of a filler-like hydroxy-apatite, fat, or collagen; the application of a purse string suture; or temporary removal of the VP to allow for shrinkage could be tried to prevent unwanted surgical closure of the TE fistula.

Earlier studies have reported success rates of 77% to 88% in managing periprosthesis leakage with an enlarged flange on the tracheal side.^{6,9-11} Kress et al. described 76 patients with periprosthesis leakage who were managed with custom fit VPs with an enlarged flange on the esophageal side and were highly successful (97%).¹² Choussy et al. evaluated 28 Blom-Singer large esophageal and tracheal flange VPs (InHealth technologies, Carpinteria, CA, USA) in 18 patients and reported success in all patients,

with a median device lifetime of 70 days (range 24–219).¹³ It indeed seems logical that an extra flange on the esophageal side is more successful than a flange on the tracheal side because it provides a better seal to the mucosa. However, a tracheal flange can be placed on an existing VP, whereas an esophageal flange usually necessitates replacement of the VP and thus higher costs.

Due to local reimbursement differences and costs of VPs in various countries, it is difficult to give exact numbers, but on average the costs of a Provox Vega combined with a silicone washer are quite comparable with that of a PVX, ranging from 90% to 110% of the costs of a PVX (communication by manufacturer, Atos Medical, Hörby, Sweden). If there is need for replacement of the VP, a washer on the esophageal side/PVX is most effective; however, if there is no need for replacement, a washer on the tracheal side is most cost-efficient.

CONCLUSION

With this prospective study, we have demonstrated that the new PVX adds a valuable new tool to solving

periprosthetic leakage, diminishing the burden of this uncomfortable adverse event both for the patient and the clinician. We were able to solve almost all cases of periprosthetic leakage and were able to reach an adequate median device lifetime of 68 days, comparable to current device lifetime of modern voice prostheses.

BIBLIOGRAPHY

1. Op de Coul BM, Hilgers FJ, Balm AJ, Tan IB, van den Hoogen FJ, van Tinteren H. A decade of postlaryngectomy vocal rehabilitation in 318 patients: a single Institution's experience with consistent application of provox indwelling voice prostheses. *Arch Otolaryngol Head Neck Surg* 2000;126:1320–1328.
2. Petersen JF, Lansaat L, Timmermans AJ, Van der Noort V, Hilgers FJM, Van den Brekel MWM. Postlaryngectomy prosthetic voice rehabilitation outcomes in a consecutive cohort of 232 patients over a 13-year period. *Head Neck* 2018. DOI: 10.1002/hed.25364
3. Kress P, Schafer P, Schwerdtfeger FP, Rosler S. Are modern voice prostheses better?. A lifetime comparison of 749 voice prostheses. *Eur Arch Otorhinolaryngol* 2014;271:133–140.
4. Lewin JS, Baumgart LM, Barrow MP, Hutcheson KA. Device life of the tracheoesophageal voice prosthesis revisited. *JAMA Otolaryngol Head Neck Surg* 2017;143:65–71.
5. Lorenz KJ. The development and treatment of periprosthetic leakage after prosthetic voice restoration. A literature review and personal experience Part I: the development of periprosthetic leakage. *Eur Arch Otorhinolaryngol* 2015;272:641–659.
6. Lorenz KJ. The development and treatment of periprosthetic leakage after prosthetic voice restoration: a literature review and personal experience. Part II: conservative and surgical management. *Eur Arch Otorhinolaryngol* 2015;272:661–672.
7. Lorenz KJ, Ehrhart T, Grieser L, Maier H. Coincidence of fistula enlargement and supra-oesophageal reflux in patients after laryngectomy and prosthetic voice restoration. *HNO* 2009;57:1253–1261.
8. Hutcheson KA, Lewin JS, Sturgis EM, Kapadia A, Risser J. Enlarged tracheoesophageal puncture after total laryngectomy: a systematic review and meta-analysis. *Head Neck* 2011;33:20–30.
9. Hilgers FJM, Soolsma J, Ackerstaff AH, Balm FJ, Tan IB, van den Brekel MW. A thin tracheal silicone washer to solve periprosthetic leakage in laryngectomies: direct results and long-term clinical effects. *Laryngoscope* 2008;118:640–645.
10. Lewin JS, Hutcheson KA, Barringer DA, Croegaert LE, Lisec A, Chambers MS. Customization of the voice prosthesis to prevent leakage from the enlarged tracheoesophageal puncture: results of a prospective trial. *Laryngoscope* 2012;122:1767–1772.
11. Hilgers FJM, Balm AJ. Long-term results of vocal rehabilitation after total laryngectomy with the low-resistance, indwelling Provox voice prosthesis system. *Clin Otolaryngol Allied Sci* 1993;18:517–523.
12. Kress P, Schafer P, Schwerdtfeger FP. The custom-fit voice prosthesis, for treatment of periprosthetic leakage after tracheoesophageal voice restoration. *Laryngorhinootologie* 2006;85:496–500.
13. Choussy O, Hixon R, Bon Mardion N, Dehesdin D. Management of voice prosthesis leakage with Blom-Singer large esophage and tracheal flange voice prostheses. *Eur Ann Otorhinolaryngol Head Neck Dis* 2013;130:49–53.