



UvA-DARE (Digital Academic Repository)

Computed tomographic angiographic imaging of abdominal aortic aneurysms: implications for transfemoral endovascular aneurysm management

Balm, R.; Stokking, R.; Kaatee, R.; Blankensteijn, J.D.; Eikelboom, B.C.; Leeuwen, M.W.

DOI

[10.1016/S0741-5214\(97\)70183-6](https://doi.org/10.1016/S0741-5214(97)70183-6)

Publication date

1997

Published in

Journal of vascular surgery

[Link to publication](#)

Citation for published version (APA):

Balm, R., Stokking, R., Kaatee, R., Blankensteijn, J. D., Eikelboom, B. C., & Leeuwen, M. W. (1997). Computed tomographic angiographic imaging of abdominal aortic aneurysms: implications for transfemoral endovascular aneurysm management. *Journal of vascular surgery*, 26, 231-237. [https://doi.org/10.1016/S0741-5214\(97\)70183-6](https://doi.org/10.1016/S0741-5214(97)70183-6)

General rights

It is not permitted to download or to forward/distribute the text or part of it without the consent of the author(s) and/or copyright holder(s), other than for strictly personal, individual use, unless the work is under an open content license (like Creative Commons).

Disclaimer/Complaints regulations

If you believe that digital publication of certain material infringes any of your rights or (privacy) interests, please let the Library know, stating your reasons. In case of a legitimate complaint, the Library will make the material inaccessible and/or remove it from the website. Please Ask the Library: <https://uba.uva.nl/en/contact>, or a letter to: Library of the University of Amsterdam, Secretariat, Singel 425, 1012 WP Amsterdam, The Netherlands. You will be contacted as soon as possible.

Computed tomographic angiographic imaging of abdominal aortic aneurysms: Implications for transfemoral endovascular aneurysm management

Ron Balm, MD, Rik Stokking, MSc, Rob Kaatee, MD, Jan D. Blankensteijn, MD, Bert C. Eikelboom, MD, and Maarten S. van Leeuwen, MD, *Utrecht, the Netherlands*

Purpose: To describe anatomic features pertinent to patient selection and graft design for transfemoral endovascular aneurysm management (TEAM) of the infrarenal aorta using computed tomographic (CT) angiography.

Methods: A prospective noncomparative analysis of 102 spiral CT scans of the abdominal aorta of patients with abdominal aortic aneurysms was performed. From the original CT data set, slices were reconstructed perpendicular to the vessel axis (central lumen line) at a 10 mm interval. In these reconstructed slices, diameter measurements were performed. Vessel length was measured along the central lumen line. In each patient possibilities for TEAM were analyzed.

Results: Because of technical reasons, 36 scans were excluded from the analysis. Of the remaining 66 patients, 18 could potentially be treated with a bifurcated endovascular device. The infrarenal aortic diameter-to-iliac artery diameter ratio was less than 2 in most patients. The vessel segments judged to be adequate for endovascular graft anchoring had a noncylindrical shape in the majority of cases.

Conclusion: Only a minority of patients with abdominal aortic aneurysms can at this stage be treated with an endovascular graft. The ideal endovascular graft should be a combination of rigid and flexible components. The proximal and distal attachment systems should have some flexibility with an intrinsic maximum diameter while the midsection of the graft can be relatively rigid. (*J Vasc Surg* 1997;26:231-7.)

In transfemoral endovascular aneurysm management (TEAM) of abdominal aortic aneurysms (AAAs), the aneurysm is excluded from the arterial circulation by an endoprosthesis introduced through the femoral artery.¹⁻⁸ The proximal and distal ends of the endoprosthesis have to be anchored to the arterial wall to exclude the aneurysm and to prevent graft migration. Consequently, one of the prerequisites for performing a successful TEAM procedure is having a proximal and distal

segment of relatively nondiseased vessel wall. The anatomic configuration of the proximal and distal graft attachment sites and the distance between them determine the dimensions of the endovascular graft.

The expected normal diameters of the infrarenal aorta, the distal aorta, and the common iliac arteries have been published previously.⁹⁻¹³ These reports describe patients without evident vascular disease. Most studies on patients who have AAAs focus on measuring the maximum aneurysm diameter, which is one of the important criteria for deciding whether to perform an operation on a patient.¹⁴ This study describes the anatomy of the infrarenal aorta and the common iliac arteries of patients who have AAAs.

The implications of computed tomographic (CT) angiographic measurements for patient selection and graft design will be discussed.

PATIENTS AND METHODS

In our hospital, the routine imaging method for all patients who require surgery for AAA is CT an-

From the Department of Vascular Surgery (Drs. Balm, Blankensteijn and Eikelboom), the Department of Computer Vision Research (R. Stokking), and the Department of Radiology (Drs. Kaatee and van Leeuwen), University Hospital Utrecht.

Supported in part by a grant from EndoVascular Technologies Inc., Menlo Park, Calif.

Reprint requests: R. Balm, Department of Vascular Surgery G4.105, University Hospital, University of Amsterdam, A.M.C. Meibergdreef 9, 1105 AZ Amsterdam, the Netherlands.

Copyright © 1997 by The Society for Vascular Surgery and International Society for Cardiovascular Surgery, North American Chapter.

0741-5214/97/\$5.00 + 0 24/1/82224

giography (CTA). CT data acquisition is performed with a spiral CT scanner (Philips SR 7000, Philips Medical Systems, Best, the Netherlands). In all patients, a bolus of nonionic contrast material was injected in an antecubital vein using a mechanical injector (130 ml, with a rate of 2 ml/sec and a scan delay of 35 seconds). The original raw data set of the spiral CT scanner is reformatted into 123 axial slices with a slice thickness of 5 mm and a slice overlap of 3 mm.^{15,16} Various image formats could be reconstructed on the basis of the original CT data set.

From October 1992 until October 1994, 102 patients had their first CTA for a suspected AAA. The axial slices of the CTAs of all patients were reviewed on an EasyVision workstation (Philips Medical Systems, Best, the Netherlands) to determine whether they could be used for further analysis. An infrarenal AAA was defined as an infrarenal aorta with a maximum external diameter of either >4.0 cm or exceeding the maximum diameter of the aorta between the origin of the superior mesenteric artery (SMA) and left renal artery by at least 0.5 cm.¹⁷ Only infrarenal aortic aneurysms that had complete data sets, including the SMA and both iliac artery bifurcations, were subsequently analyzed.

Thirty-six patients were excluded from the analysis. In 11 patients there was a suprarenal aortic aneurysm, in 11 patients the SMA or iliac bifurcations were not scanned, in 10 patients the scan was not performed according to protocol, rendering reconstructions impossible, and in three patients the presence of an aneurysm could not be confirmed. One patient was excluded because multiple renal arteries made it impractical to determine the length of the various vessel segments.

The remaining group of 66 patients consisted of 58 men with a median-age of 70 years (range, 42 to 90 years) and eight women with a median age of 70 years (range, 56 to 87 years).

In these patients, detailed length and diameter measurements were obtained in a special image format, the curved-linear multiplanar reconstruction. This format is created on the EasyVision workstation and is based on the line drawn through the center of the contrast-filled vessel lumen, the so-called vessel axis or central lumen line. This line is created by the operator by selecting the center of the lumen in several axial slices. These central lumen points are then automatically connected to form the central lumen line.^{16,18} Diameter measurements were obtained in slices that were perpendicular to this central lumen line and represent true cross-sections of the vessel. For practical purposes, we selected to perform

the diameter measurements in slices reconstructed at 10 mm intervals along the central lumen line, starting at the caudad margin of the SMA. In each reconstructed slice, the maximum diameter and the diameter perpendicular to it were measured. Length measurements were obtained along the central lumen line, thereby representing the true length of vessel segments including tortuosity. Based on the positions of the slices reconstructed perpendicular to the vessel axis that contained the caudad margins of the SMA, the renal arteries, and the flow divider in the aortic bifurcation and iliac bifurcations, the EasyVision workstation calculated the lengths of various vessel segments along the curved central lumen line. Tortuosity at the proximal and distal attachment sites was not separately analyzed in this study.

We consider a vessel segment to be an anatomical neck when it has a length of at least 10 mm with a diameter change of less than 5 mm. An anatomical neck is considered to be suitable for endovascular graft placement if it has a length of at least 15 mm with a diameter change of less than 5 mm and no mural thrombus. The definition of a suitable neck is based on our own experience with EVT endovascular prostheses (EndoVascular Technologies, Menlo Park, Calif.)⁷ and on reports on other devices.^{19,20} The maximum aortic neck diameter should not exceed the suprarenal aortic diameter by more than 5 mm.¹⁷ The maximum common iliac artery neck diameter should not be more than 20 mm. The neck configuration was divided into five groups (I to V), as displayed in Fig. 1.

The presence of calcification in the anatomical necks was quantified by counting the number of quadrants (anterior/left/posterior/right) per slice that contain calcifications larger than 5 mm. Calcifications larger than 5 mm are expected to hamper the anchoring of attachment systems that have hooks or barbs that need to penetrate the vessel wall. The number of quadrants that contained calcifications larger than 5 mm divided by the total number of quadrants (number of slices \times 4) in the anatomical neck or common iliac artery results in the calcification index (range, 0 to 1). A calcification index of 0.10, for instance, would imply that of all quadrants in the entire anatomical neck 10% contain calcifications larger than 5 mm.

Two separate analyses were performed. First, all vascular segments were independently analyzed. Then, measurements in individual patients were combined to determine the patient's suitability for endovascular treatment. A patient was considered suitable if a sufficient proximal aortic neck and either

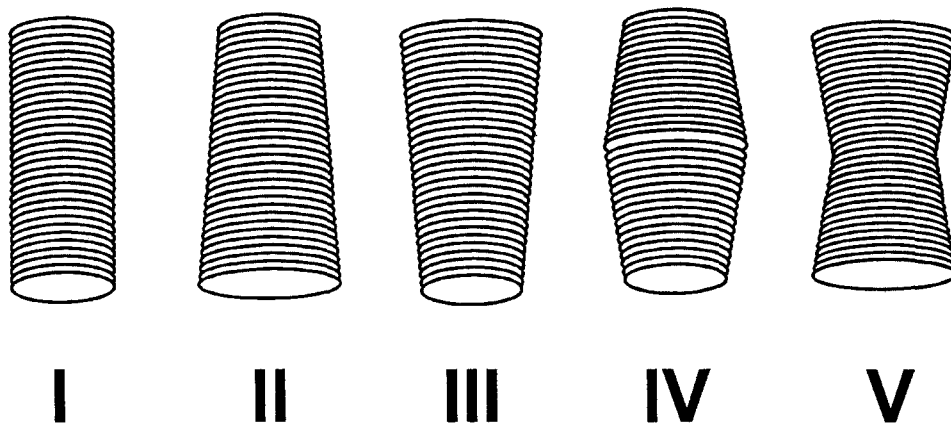


Fig. 1. Classification of the neck configuration in five categories.

a sufficient distal aortic neck or two sufficient iliac necks were present. The proposed graft diameter was based on the maximum diameter of the previously defined suitable necks.

The external iliac arteries, the angles between the various vascular segments, and the iliac artery tortuosity were not analyzed.

RESULTS

Length measurements. The positions of the caudad margin of the origins of the renal arteries, the aortic bifurcation, and the iliac bifurcations as measured along the central lumen line relative to the origin of the SMA are displayed in Table I. The positions of one left and one right renal artery as well as of one left internal iliac artery could not be determined because they were occluded.

The left renal artery was the most caudad in 30 patients, the right in 17 patients, and the difference in level between the two was less than 2 mm in 19 patients. The median distance between the most caudad renal artery and the aortic bifurcation was 128 mm (range, 97 to 180 mm), and the median distances between the most caudad renal artery and the left and right iliac artery bifurcation were 198 and 197 mm, respectively (ranges, 152 to 290 mm and 147 to 282 mm, respectively).

Suprarenal and aneurysm diameter measurements. The median diameter of the suprarenal aorta, as measured between the SMA and the uppermost renal artery, was 24 mm (range, 16 to 35 mm). The maximum aneurysm diameter in 66 patients ranged from 36.7 to 94.4 mm, with a median maximum diameter of 55.3 mm (men's median, 56.3 mm; range, 36.7 to 94.4 mm; women's median, 53.9 mm; range, 41.7 to 69.4 mm). In one patient

Table I. Positions of caudad margins measured along central lumen line and relative to SMA

Positions relative to SMA	n	Median (mm)	Range (mm)
Left renal artery	65	13	2 to 36
Right renal artery	65	11	-4 to 36
Aorta bifurcation	66	146	105 to 198
Left iliac bifurcation	65	215	175 to 300
Right iliac bifurcation	66	215	169 to 297

the maximum diameter was less than 40 mm but exceeded the suprarenal aortic diameter by more than 5 mm.¹⁷

Proximal aortic neck. In 11 patients the aneurysm started directly or within 10 mm below the renal arteries. In the remaining 55 patients the median neck length was 24 mm (range, 10 to 85 mm). The neck configuration according to Fig. 1 was type I in 22 patients, type II in 27 patients, type III in three patients, type IV in one patient, and type V in two patients.

Of the 55 anatomical necks, 26 were not suitable for endovascular surgery. In 10 patients this lack of suitability was because the length was less than 15 mm, in 13 patients because of mural thrombus, in two patients because of a combination of insufficient neck length and thrombus, and in one patient because the neck diameter was 5 mm more than that of the suprarenal aorta. The calcification index in these 26 patients ranged from 0.00 to 0.68 (median, 0.00).

The 29 suitable necks had a median length of 30 mm (range, 15 to 70 mm). The configuration of these necks was type I in 13 patients, type II in 10 patients, type III in three patients, type IV in one

patient, and type V in two patients. The calcification indexes ranged from 0.00 to 0.50 (median, 0.10). The proposed median graft diameter for these patients was 24 mm (range, 18 to 32 mm).

Distal aortic neck. In 57 patients there was no distal aortic neck. In the remaining nine patients the median neck length was 20 mm (range, 10 to 30 mm). The neck configuration was type II in one patient, type III in seven patients, and type IV in one patient. Of the nine distal necks, five were not suitable for endovascular surgery; four because of a neck length less than 15 mm and one because of mural thrombus in a 30 mm long neck. The median calcification index in these five necks was 0.50 (range, 0.25 to 0.75). All rejected distal necks were of configuration type III.

The median calcification index of the four suitable distal necks was 0.37 (range, 0.25 to 1.00), and the proposed graft diameter was 19 mm in two patients and 25 mm in the other two patients.

Left common iliac artery. The median length of the left common iliac artery was 65 mm (range, 31 to 124 mm). The minimum diameter ranged from 3 to 15 mm (median, 10 mm), and the maximum diameter ranged from 10 to 72 mm (median, 16 mm). The iliac artery configuration was type I in 31 patients, type II in seven patients, type III in 15 patients, type IV in nine patients, and type V in four patients.

Of all 66 left common iliac arteries, 48 had a suitable neck length of more than 15 mm with a change in diameter of less than 5 mm. In four of these iliac arteries there was a short segment with a diameter of more than 20 mm immediately distal from the aortic bifurcation (diameters, 21, 21, 22, and 23 mm), with a suitable iliac neck distal from this dilated segment. The median calcification index of all 48 patients was 0.11 (range, 0.00 to 0.78).

The other 18 iliac arteries were rejected because of mural thrombus in 10 patients and a diameter larger than 20 mm in eight patients. These 10 dilated iliac arteries had maximum diameters ranging from 21 to 72 mm (median, 26 mm). The median calcification index was 0.23 (range, 0.00 to 0.75).

The proposed graft diameter for the 48 suitable left iliac necks ranged from 10 to 18 mm (median, 14 mm).

Right common iliac artery. The median length of the right common iliac artery was 65 mm (range, 15 to 126 mm). The minimum diameter ranged from 4 to 18 mm (median, 10 mm), and the maximum diameter ranged from 10 to 59 mm (median, 17 mm). The iliac artery configuration was type I in

21 patients, type II in 16 patients, type III in 14 patients, type IV in 14 patients and type V in one patient.

Of all 66 right common iliac arteries, 44 had a suitable neck length of more than 15 mm with a diameter change of less than 5 mm, and four of these patients had short iliac segments with a diameter of more than 20 mm (24, 28, 29, and 40 mm). The median calcification index of all 44 suitable iliac arteries was 0.13 (range, 0.00 to 0.66).

The other 22 iliac segments were rejected because of mural thrombus in 11 patients and because the diameter was more than 20 mm in 11 patients. The maximum diameter of the iliac arteries with diameters larger than 20 mm ranged from 21 to 59 mm (median, 32 mm). The median calcification index in the 22 rejected segments was 0.16 (range, 0.00 to 1.00).

The proposed graft diameter in the 46 suitable right iliac necks ranged from 10 to 19 mm (median, 14 mm).

Analysis per patient. Combining the results in all individual patients, 55 of 66 had a proximal anatomical neck. Only 28 of these necks were considered suitable for endovascular surgery. However, of these 28 patients only five had a distal aortic segment, of which only one was considered to be suitable for endovascular grafting. Unfortunately, this patient also had an iliac artery aneurysm, leaving no patient in which a tube prosthesis would be a possibility. Of the other four patients with distal necks, two had bilateral common iliac arteries with sufficient graft attachment sites. Of 23 patients with a sufficient proximal segment without a distal aortic neck, 16 had bilateral common iliac arteries suitable for bifurcated graft placement. The proposed graft diameters for the proximal and both distal attachment sites are shown in Fig. 2.

If a subgroup of 11 patients with small aneurysms (<50 mm diameter) is separately analyzed, only one patient would be suitable for a bifurcated endovascular device. Two of these patients had an adequate proximal attachment site but did not have adequate distal attachment sites. In the eight remaining patients, the proximal neck was inadequate despite the small diameter of the aneurysm.

For the 18 patients in whom a bifurcated graft could be implanted, the median absolute difference between the proposed distal graft diameter on the left and on the right side was 0.5 mm (range, 0 to 5 mm).

The median distance from the most caudad renal artery to the left iliac bifurcation was 209 mm (range,

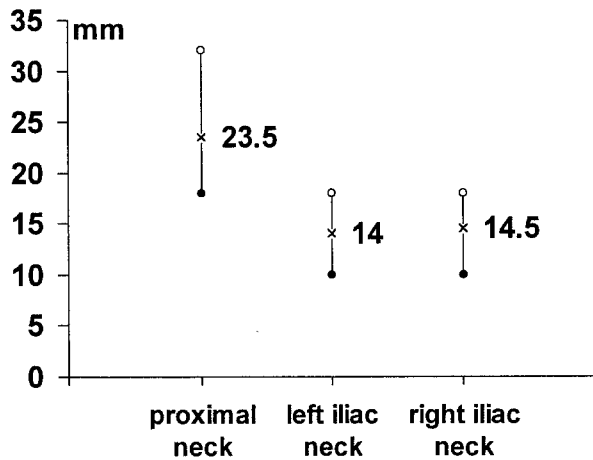


Fig. 2. Proposed proximal aortic and iliac graft diameters for the 18 patients who could be treated with a bifurcated endovascular device. Minimal, maximal, and median diameters are displayed.

177 to 229 mm) and to the right iliac bifurcation 202 mm (range, 172 to 272 mm). The median difference between the length on the left and right side was 10 mm (range, 2 to 40 mm).

The median ratio between the infrarenal attachment site diameter and the iliac attachment site diameters in these 18 patients was 1.81 (range, 1.13 to 2.60) for the left iliac artery and 1.57 (range, 1.20 to 2.60) for the right iliac artery. The ratios of proposed proximal diameter to proposed distal diameter for the left and right side are displayed in Fig. 3. The correlation between the ratio on the left and right side was 0.85, and nine patients had equal ratios on both sides.

DISCUSSION

We prefer preoperative imaging of AAAs using CT angiography.¹⁶ On the basis of the CTA, high-quality two- and three-dimensional reconstructions of the data set can be produced. The two-dimensional multiplanar reconstructions produce detailed anatomical information needed for accurate measurements. They are based on the entire set of information contained in the initial axial slices. The curved linear format of the multiplanar reconstructions was chosen because it makes it possible to accurately measure the diameters of the proximal and distal attachment sites in slices perpendicular to the vessel axis. Another advantage of the central lumen line is that it facilitates accurate length measurements of tortuous and elongated vessels. The creation of a central lumen line, however, requires a skilled opera-

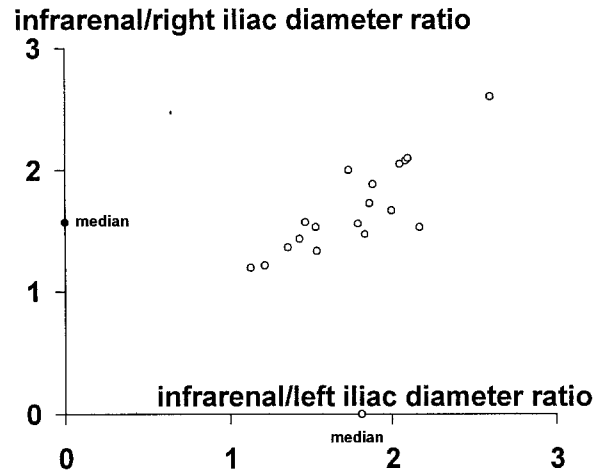


Fig. 3. Ratios of proposed proximal to proposed distal graft diameters for 18 patients who could be treated with a bifurcated endovascular device. The median proximal-to-right iliac diameter ratio is displayed on the Y axis, the median proximal-to-left iliac diameter ratio on the X axis. The correlation coefficient between the proximal-to-left and proximal-to-right ratios is 0.85.

tor, and the distortion of images in the curved linear format can be confusing to the inexperienced observer.

Length measurements were easy to obtain because the start and endpoint of the measurements, the margins of the SMA and renal arteries as well as the flow dividers in the aortic and iliac bifurcations, are well defined. Measurements of maximum and minimum diameters were also easy to perform. The description of proximal and distal necks, on the other hand, is quite difficult. The infrarenal aorta, for instance, had a noncylindrical shape in 44 of the 66 patients. We therefore use definitions that are practical both for the endovascular procedure and for the analysis. In this protocol, a neck should have a length of at least 10 mm with a diameter change of less than 5 mm. If these criteria were applied to the aorta, 11 proximal and 57 distal aortic segments did not have an anatomical neck.

TEAM is a new technique that still has to prove its efficacy in long-term follow-up studies.²¹ A major point of concern with the endovascular devices is extra-graft flow⁷ or "endoleak," a term recently introduced by White et al.²² Endoleaks are encountered with all currently available endovascular grafting devices. The cause of endoleaks at the proximal and distal attachment sites is a failed seal between the graft and the arterial wall. This can either be a result of a technical failure during implantation (graft dis-

location) or to a mismatch between vessel and endovascular graft size. A persistent endoleak is considered to be a grave sign when it is encountered during follow-up. If it is demonstrated, the aneurysm is not excluded from the arterial circulation and aneurysm growth should be expected. The treatment for a persistent endoleak is a reintervention.

Only 55 of our 66 patients had a proximal anatomical neck. Half of these necks were unsuitable because of mural thrombus. Thrombus is a contraindication for TEAM because the endovascular graft needs to be anchored in a relatively normal vessel segment. Mural thrombus is a sign of vascular disease that makes the quality of anchoring uncertain.

As expected, most of the proximal necks had a type I or II configuration. Types III, IV, and V were only seen in necks longer than 30 mm. Because of the variable neck configuration, overall neck diameters are not presented for the entire group. Usually, there is a gradual diameter increase, and because of the neck definition the variance in neck diameter can be as much as 5 mm. Only for suitable necks is the maximum neck diameter used as the proposed graft diameter. The suitable proximal neck diameter and length correspond with the results of a CT study by Chuter et al.²³ who has measured neck diameters of 24.9 ± 1.4 mm and neck lengths of 26.7 ± 4.1 mm in three-dimensional reconstructions of 22 patients with AAAs.

Of all distal aortic segments, nine had an anatomical neck, of which only four were suitable for grafting. This confirms that the emphasis in designing endovascular grafts should be on bifurcated systems. Using our conservative criteria of suitable necks, only very few patients will be treated with an endovascular tube graft. Because of the availability of bifurcated endovascular systems, we advocate using the endovascular tube graft only in patients who have excellent distal aortic attachment sites. By preferring a bifurcated graft when the distal aortic neck length is less than 15 mm, the number of distal endoleaks can probably be reduced.

There is not much difference between the left and right iliac artery. The length, maximum and minimum diameters, and proposed graft diameters are similar. Iliac aneurysm formation is the most common cause for rejection of the iliac arteries.

The combination of proximal and distal measurements to determine whether individual patients can be treated with an endovascular device revealed that only 18 out of 66 patients have both proximal and distal necks of adequate length. In the study population, the patients with small aneurysms did not have an advantage over those with larger aneurysms, as only one out of 11 had suitable anatomy.

All 18 patients would have required a bifurcated endovascular device because they did not have an adequate distal aortic neck. The proposed proximal and distal graft diameter equals the maximum diameter of the suitable neck.

There is a considerable range in measured diameters, and it should be taken into consideration that most necks show a 5 mm range in diameter, in accordance with the definition of suitable necks. This 5 mm diameter range can cause a variance in lumen circumference of 22% for the median proximal vessel lumen and of 36% for the median distal vessel lumen (circumference = $2\pi r$). The use of woven grafts with a fixed diameter may therefore cause folds in the graft in the narrow part of the attachment site and cause endoleaks. Note that the standard proximal-to-distal graft diameter ratio of 2.0 that is used in most vascular grafts does not apply to these patients because most of them have a ratio that is considerably less. If an endovascular graft with a 2.0 proximal-to-distal diameter ratio had to be used for these patients, only three would have had aortic and iliac necks suitable for such a device.

The vessel segment length measurements we used are very accurate because vessel elongation and tortuosity are taken into account. Accurate prediction of the length of the entire endovascular prosthesis is sometimes difficult, especially in patients who have a wide aortic lumen. The final position of the endovascular graft in the wide aneurysmatic lumen is unpredictable, and it does not necessarily follow the tract of the previously defined central lumen line.

This study was designed to provide measurements that can guide endovascular graft design. Several important issues are covered, such as the technique of measuring true cross-sectional diameters in slices perpendicular to the vessel axis and measuring the length of vessel segments along the curved vessel axis. The problem of grading aortic and iliac tortuosity and determining the impact of the tortuosity on patient selection and graft design is not solved yet. The three-dimensional format of CT angiography can probably help solving this complex anatomical dilemma.

The results of this study are applicable to a larger patient population only if there is no major bias in patient selection. The use of consecutive patients with suspected AAAs from our CT database minimizes this bias. Even from this small sample of patients, several recommendations for endovascular graft design can be made. On the basis of the neck configurations, a flexible proximal and distal attachment system that can adjust its diameter to the shape of the attachment site will provide a better contact

between the graft and the vessel wall. The graft material that is to be used at the proximal and distal ends of the system should, to a certain extent, be flexible to prevent folds in the graft at the narrow parts of the attachment sites. The proximal-to-distal diameter ratio should not be fixed at 2.0 but rather be in the range of 1.5 to 2.0. The problem of the variable distal diameter can probably be solved with the use of graft materials that have a fixed maximum diameter (with a proximal-to-distal diameter ratio of 1.5) but that can also be partially expanded (with a proximal to distal diameter ratio of 2.0). An endovascular graft design that incorporates flexible segments at the proximal and distal ends can probably not only better adjust to the variable proximal to distal diameter ratio but also to the variation in attachment site shape, because most attachment sites have a conical shape.

CONCLUSION

On the basis of strict selection criteria, only a minority of AAA patients can be treated with endovascular aortic graft. The majority of all suitable graft attachment sites have a conical shape. In patients who have a suitable anatomical configuration, the proximal to distal graft diameter ratio is less than 2. The ideal endovascular graft should be a combination of rigid and flexible components. The proximal and distal attachment systems should have some flexibility with an intrinsic maximum diameter while the midsection of the endograft can be relatively rigid.

REFERENCES

1. Parodi JC, Palmaz JC, Barone HD. Transfemoral intraluminal graft implantation for abdominal aortic aneurysms. *Ann Vasc Surg* 1991;5:491-9.
2. Parodi JC. Endovascular repair of abdominal aortic aneurysms. In: Whittemore AD, editor. *Advances in vascular surgery*, vol. 1. St. Louis: Mosby-Year Book, 1993:85-106.
3. Chuter TAM, Green RM, Ouriel K, Fiore WM, DeWeese JA. Transfemoral endovascular aortic graft placement. *J Vasc Surg* 1993;18:185-97.
4. Parodi JC, Criado FJ, Barone HD, Schoenholtz C, Queral LA. Endoluminal aortic aneurysm repair using a balloon-expandable stent-graft device: a progress report. *Ann Vasc Surg* 1994;8:523-9.
5. Moore WS, Vescera CL. Repair of abdominal aortic aneurysm by transfemoral endovascular graft placement. *Ann Surg* 1994;220(3):331-41.
6. Lazarus HM. Endovascular grafting for the treatment of abdominal aortic aneurysms. *Surg Clin North Am* 1992;72:959-68.
7. Balm R, Eikelboom BC, May J, Bell PRF, Swedenborg J, Collin J. Early experience with Transfemoral Endovascular Aneurysm Management (TEAM) in the treatment of aortic aneurysms. *Eur J Vasc Endovasc Surg* 1996;11:214-20.
8. White GH, May J, McGahan T, Yu W, Waugh RC, Stephen MS, Harris JP. Historic control comparison of outcome for matched groups of patients undergoing endoluminal versus open repair of abdominal aortic aneurysms. *J Vasc Surg* 1996;23:201-12.
9. Sonesson B, Lanne T, Hansen F, Sandgren T. Infra-renal aortic diameter in the healthy person. *Eur J Vasc Surg* 1994;8:89-95.
10. Sonesson B, Hansen F, Stale H, Lanne T. Compliance and diameter in the human abdominal aorta: the influence of age and sex. *Eur J Vasc Surg* 1993;7:690-7.
11. Johnston KW, Rutherford RB, Tilson MD, Shah DM, Hollier L, Stanley JC. Suggested standards for reporting on arterial aneurysms. *J Vasc Surg* 1991;13:452-8.
12. Horejs D, Gilbert PM, Burstein S, Vogelzang RL. Normal aortic diameters by CT. *J Comput Assist Tomogr* 1988;12:602-3.
13. Pedersen OM, Aslaksen A, Vik-Mo H. Ultrasound measurement of the luminal diameter of the abdominal aorta and iliac arteries in patients without vascular disease. *J Vasc Surg* 1993;17:596-601.
14. Hollier LH, Taylor LM, Ochsner J. Recommended indications for operative treatment of abdominal aortic aneurysms. *J Vasc Surg* 1992;15:1046-56.
15. Balm R, Eikelboom BC, van Leeuwen MS, Noordzij J. Spiral CT angiography of the aorta. *Eur J Vasc Surg* 1994;8:544-51.
16. Balm R, van Leeuwen MS, Noordzij J, Eikelboom BC. Spiral CT for aortic aneurysms. In: Greenhalgh RM, editor. *Vascular imaging for surgeons*. London: W.B. Saunders, 1995:191-202.
17. Collin J. A proposal for a precise definition of abdominal aortic aneurysm: a personal view. *J Cardiovasc Surg (Torino)* 1990;31:168-9.
18. Balm R, Kaatee R, Blankensteijn JD, Mall WPTM, Eikelboom BC. CT angiography of abdominal aortic aneurysms after transfemoral endovascular aneurysm management: diameter and volume measurements. *Eur J Vasc Endovasc Surg* 1996;12:182-8.
19. Moritz JD, Rotermund S, Keating DP, Oestmann JW. Infra-renal abdominal aortic aneurysms: implications of CT evaluation of size and configuration for placement of endovascular aortic grafts. *Radiology* 1996;198:463-6.
20. Blum U, Langer M, Spillner G, Mialhe C, Beyersdorf F, Buitrago-Tellez C, et al. Abdominal aortic aneurysms: preliminary technical and clinical results with transfemoral placement of endovascular self-expanding grafts. *Radiology* 1996;198:25-31.
21. Hovsepian DM. Stent-grafts for endovascular treatment of abdominal aortic aneurysms: how much do we really know? *Radiology* 1996;198:14-6.
22. White GH, Yu W, May J. "Endoleak"—a proposed new terminology to describe incomplete aneurysm exclusion by an endoluminal graft. *J Endovasc Surg* 1996;3:124-5.
23. Chuter TAM, Green RM, Ouriel K, DeWeese JA. Infra-renal aortic aneurysm structure: implications for transfemoral repair. *J Vasc Surg* 1994;20:44-50.

Submitted June 10, 1996; accepted Mar. 27, 1997.