



UvA-DARE (Digital Academic Repository)

Thrombosis of the cerebral veins and sinuses

Stam, J.

DOI

[10.1056/NEJMra042354](https://doi.org/10.1056/NEJMra042354)

Publication date

2005

Published in

The New England journal of medicine

[Link to publication](#)

Citation for published version (APA):

Stam, J. (2005). Thrombosis of the cerebral veins and sinuses. *The New England journal of medicine*, 352(17), 1791-1798. <https://doi.org/10.1056/NEJMra042354>

General rights

It is not permitted to download or to forward/distribute the text or part of it without the consent of the author(s) and/or copyright holder(s), other than for strictly personal, individual use, unless the work is under an open content license (like Creative Commons).

Disclaimer/Complaints regulations

If you believe that digital publication of certain material infringes any of your rights or (privacy) interests, please let the Library know, stating your reasons. In case of a legitimate complaint, the Library will make the material inaccessible and/or remove it from the website. Please Ask the Library: <https://uba.uva.nl/en/contact>, or a letter to: Library of the University of Amsterdam, Secretariat, Singel 425, 1012 WP Amsterdam, The Netherlands. You will be contacted as soon as possible.

REVIEW ARTICLE

CURRENT CONCEPTS

Thrombosis of the Cerebral Veins and Sinuses

Jan Stam, M.D., Ph.D.

THROMBOSIS OF THE CEREBRAL VEINS AND SINUSES IS A DISTINCT CEREBROVASCULAR disorder that, unlike arterial stroke, most often affects young adults and children. The symptoms and clinical course are highly variable. A teenager who has had recent headaches after starting oral contraception, a woman who has had seizures after delivery in the obstetrical ward, and a comatose man with a dilated pupil in the emergency room all may have sinus thrombosis. The estimated annual incidence is 3 to 4 cases per 1 million population and up to 7 cases per 1 million among children. About 75 percent of the adult patients are women. During the past decade, increased awareness of the diagnosis, improved neuroimaging techniques, and more effective treatment have improved the prognosis. More than 80 percent of all patients now have a good neurologic outcome. This review summarizes recent insights into the pathogenesis of sinus thrombosis, risk factors, and clinical and radiologic diagnosis and discusses the current evidence and controversies about the best treatment.

From the Department of Neurology, Academic Medical Center, University of Amsterdam, Amsterdam. Address reprint requests to Dr. Stam at the Department of Neurology, Academic Medical Center, University of Amsterdam, P.O. Box 22700, 1100 DE Amsterdam, the Netherlands, or at j.stam@amc.uva.nl.

N Engl J Med 2005;352:1791-8.

Copyright © 2005 Massachusetts Medical Society.

PATHOGENESIS

To understand the symptoms and signs of sinus thrombosis, two different mechanisms should be distinguished: thrombosis of the cerebral veins, with local effects caused by venous obstruction, and thrombosis of the major sinuses (Fig. 1), which causes intracranial hypertension. In the majority of patients, these two processes occur simultaneously.

The first mechanism, occlusion of the cerebral veins, can cause localized edema of the brain and venous infarction. Pathological examination shows enlarged, swollen veins, edema, ischemic neuronal damage, and petechial hemorrhages (Fig. 2). The latter can merge and become large hematomas, which have a characteristic appearance on computed tomographic (CT) scans (Fig. 3). Two different kinds of cerebral edema can develop. The first, cytotoxic edema, is caused by ischemia, which damages the energy-dependent cellular membrane pumps, leading to intracellular swelling. The second type, vasogenic edema, is caused by a disruption in the blood-brain barrier and leakage of blood plasma into the interstitial space. Vasogenic edema is reversible if the underlying condition is treated successfully. Magnetic resonance imaging (MRI) has shown that both cytotoxic and vasogenic edema occur in cerebral vein thrombosis.^{3,4}

The second mechanism is the development of intracranial hypertension as the result of occlusion of the major venous sinuses. Normally, the cerebrospinal fluid is transported from the cerebral ventricles through the subarachnoid spaces at the base and surface of the brain to the arachnoid villi, where it is absorbed and drained into the superior sagittal sinus. Thrombosis of the sinuses leads to increased venous pressure, impaired absorption of cerebrospinal fluid, and consequently, increased intracranial pressure. The obstruction to the drainage of cerebrospinal fluid is located at the end of its transport pathway, and no pressure gradient develops between the subarachnoid spaces at the surface of the brain and the ventricles. Hence, the ventricles do not dilate, and hydro-

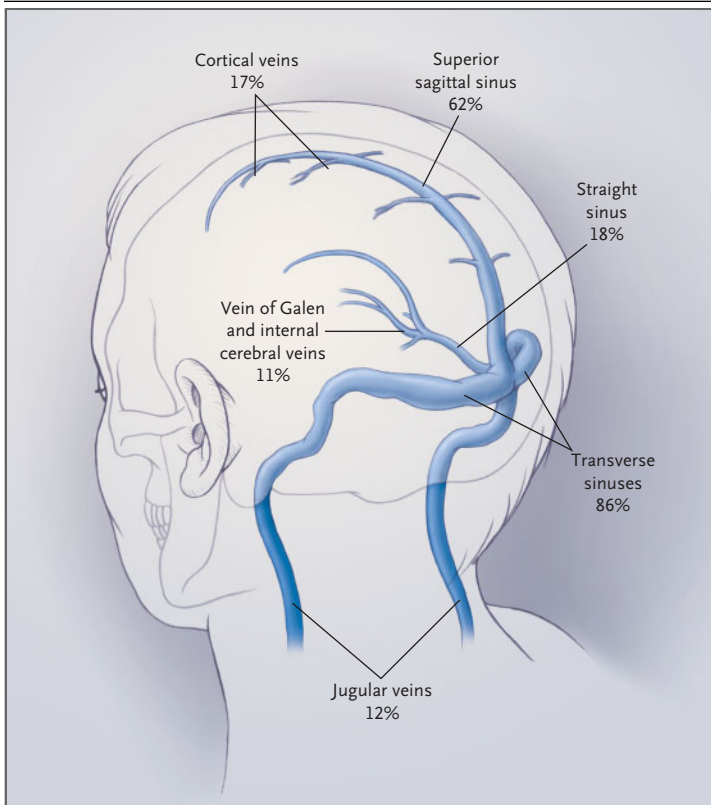


Figure 1. Frequency of Thrombosis of the Major Cerebral Veins and Sinuses.

The frequencies of thrombosis in the various sinuses are given as percentages and are based on data from the International Study on Cerebral Vein and Dural Sinus Thrombosis.¹ In most patients, thrombosis occurs in more than one sinus.

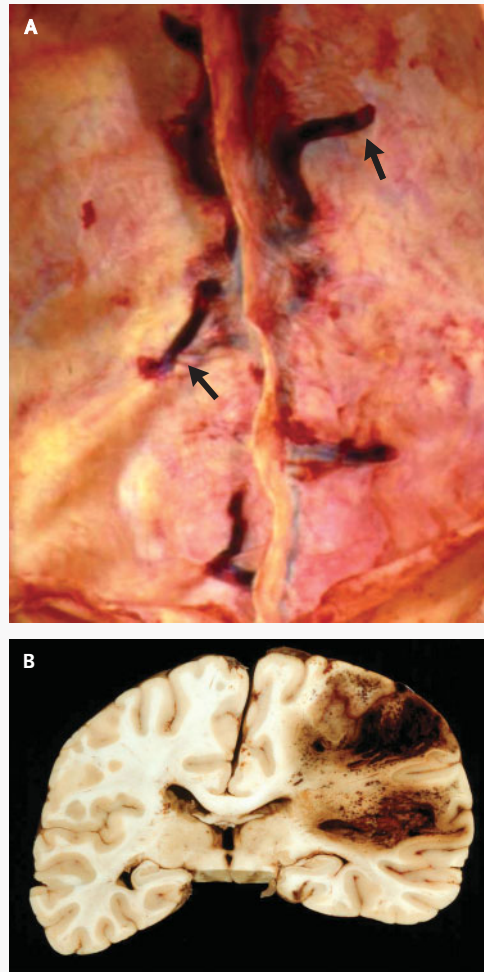


Figure 2. Postmortem Views of Sinus Thrombosis.

Panel A provides a caudal view of the inside of the skull after removal of the brain, with thrombosis of the cortical veins (arrows) evident on both sides of the superior sagittal sinus (not opened), which is also thrombosed. Panel B shows a large hemorrhagic venous infarct in the same patient.

cephalus does not normally complicate sinus thrombosis. About one fifth of patients with sinus thrombosis have intracranial hypertension only, without signs of cortical vein thrombosis.¹

CAUSES AND RISK FACTORS

A prothrombotic risk factor or a direct cause is identified in about 85 percent of patients with sinus thrombosis (Table 1). Often, a precipitating factor, such as a head injury or obstetrical delivery, causes sinus thrombosis in a person with a genetically increased risk. During the last trimester of pregnancy and after delivery, the risk of sinus thrombosis is increased.¹⁶ The frequency of peripartum and postpartum sinus thrombosis is about 12 cases per 100,000 deliveries, only slightly lower than that of peripartum and postpartum arterial stroke.¹⁷

Two case-control studies have shown an increased risk of sinus thrombosis in women who

use oral contraceptives,^{9,23} especially third-generation contraceptives that contain gestodene or desogestrel.²⁶ Additional evidence of an increased risk in women who use oral contraceptives is the change in the sex ratio of cases of sinus thrombosis over time. Until the mid-1970s, men and women were equally affected.²⁷ More recently, there has been a significant female predominance among young adults with sinus thrombosis (70 to 80 percent of cases are in women of childbearing age) but not among children or elderly persons.^{1,6,28} Labo-

ratory findings support the evidence that oral contraceptives have a prothrombotic effect.²⁹

TRAUMA AND LUMBAR PUNCTURE

The mechanical causes of sinus thrombosis are head injury, direct injury to the sinuses or the jugular veins — for instance, from jugular catheterization — and neurosurgical procedures. A lumbar puncture can also lead to sinus thrombosis.²⁵ A plausible reason is that low cerebrospinal fluid pressure after a lumbar puncture causes a downward shift of the brain, with traction on the cortical veins and sinuses. Deformation of the venous walls may induce thrombosis. The diagnosis of sinus thrombosis after a lumbar puncture is difficult, because the headache that follows is attributed not to sinus thrombosis but to the lumbar puncture itself.³⁰ However, the headache resulting from lumbar puncture typically disappears when the patient lies down, and it resolves within a few days, whereas the headache in patients with sinus thrombosis does not change with a shift in posture and worsens during the first stage of the disease.

INFECTIONS

Otitis and mastoiditis can be complicated by thrombosis of the adjacent sigmoid and transverse sinuses. If the contralateral transverse sinus is hypoplastic — a frequent anatomical variant — absorption of the cerebrospinal fluid becomes impaired. The resulting intracranial hypertension with accompanying papilledema was formerly known as “otitic hydrocephalus,” a classic misnomer, since the ventricles normally are not enlarged in cases of sinus thrombosis. The frequency of infectious sinus thrombosis has declined and varies from 6 to 12 percent in large series of adults with sinus thrombosis.^{1,5} Higher frequencies of both systemic infections (e.g., neonatal sepsis) and local infections (e.g., otitis) are reported in children.⁶ A special case is thrombosis of the cavernous sinuses, which is nearly always caused by an infection of the paranasal (ethmoid and sphenoid) sinuses, the orbit, or the face.

CLINICAL MANIFESTATIONS

The most frequent but least specific symptom of sinus thrombosis is severe headache, which is present in more than 90 percent of adult patients. It usually increases gradually over a couple of days but can also start in a split second, mimicking a subarach-

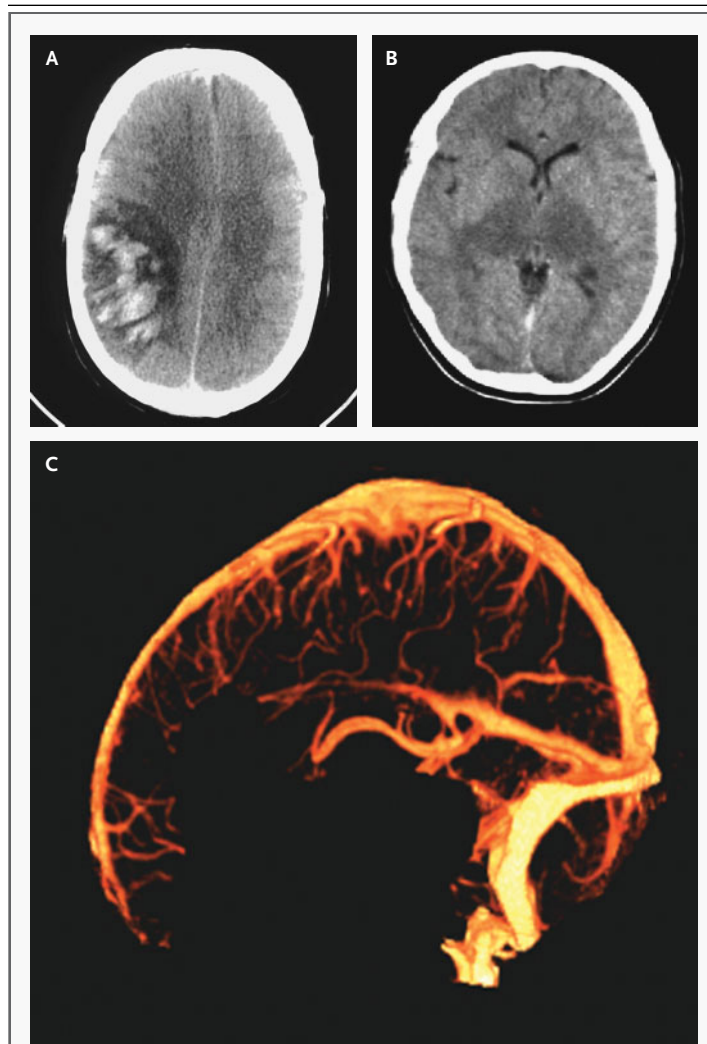


Figure 3. CT Imaging of Sinus Thrombosis.

A CT scan (Panel A) shows a large infarct in the right parietal lobe (at left in the image) in a patient with sinus thrombosis. The infarct is hemorrhagic (white patches). The falx cerebri is displaced to the left as a result of compression by the infarct. In the CT scan in Panel B, bilateral thalamic edema (dark area in center) has been caused by thrombosis of the straight sinus. In Panel C, an image obtained by CT venography shows reconstruction of the cerebral venous system after the injection of intravenous contrast material and removal of bone voxels.² This lateral view provides good visibility of the major sinuses, including the straight sinus and the cortical and deep cerebral veins (without thrombosis).

noid hemorrhage.³¹ Cerebral lesions and neurologic signs develop in half of patients with sinus thrombosis. Characteristic, but rare, is the occurrence of unilateral hemispheric symptoms such as hemiparesis or aphasia, followed within days by symptoms from the other hemisphere; these are caused by the

Table 1. Causes of and Risk Factors Associated with Cerebral Venous Sinus Thrombosis.

Genetic prothrombotic conditions
Antithrombin deficiency ⁵
Protein C and protein S deficiency ⁶⁻⁸
Factor V Leiden mutation ⁹⁻¹¹
Prothrombin mutation (the substitution of A for G at position 20210) ^{9,11,12}
Homocysteinemia caused by gene mutations in methylenetetrahydrofolate reductase ^{13,14}
Acquired prothrombotic states
Nephrotic syndrome
Antiphospholipid antibodies ^{7,15}
Homocysteinemia ¹⁴
Pregnancy ^{16,17}
Puerperium ¹⁷
Infections
Otitis, mastoiditis, sinusitis ⁶
Meningitis
Systemic infectious disease ⁶
Inflammatory disease
Systemic lupus erythematosus ¹⁸
Wegener's granulomatosis ⁸
Sarcoidosis
Inflammatory bowel disease
Behçet's syndrome ^{19,20}
Hematologic conditions
Polycythemia, primary and secondary
Thrombocytopenia
Leukemia ²¹
Anemia, including paroxysmal nocturnal hemoglobinuria ²²
Drugs
Oral contraceptives ^{9,23}
Asparaginase ^{6,21}
Mechanical causes, trauma
Head injury ²⁴
Injury to sinuses or jugular vein, jugular catheterization
Neurosurgical procedures
Lumbar puncture ²⁵
Miscellaneous
Dehydration, especially in children ⁶
Cancer ^{1,6}

development of cortical lesions on both sides of the superior sagittal sinus. Seizures occur in about 40 percent of patients, a far higher percentage than in patients with arterial stroke. Seizures are limited and focal in 50 percent of these patients but may generalize to a life-threatening status epilepticus. Thrombosis of the deep venous system — the straight sinus and its branches — causes centrally located, often bilateral thalamic lesions (Fig. 3), with behavioral symptoms such as delirium, amnesia, and mutism, which can be the only manifestation of sinus thrombosis.³² If large unilateral infarcts or hemorrhages compress the diencephalon and brain stem, patients may become comatose or

die from cerebral herniation if untreated. Other causes of coma are involvement of the thalamus and generalized seizures. Infectious cavernous sinus thrombosis is characterized by headache, fever, and eye symptoms such as periorbital edema, proptosis, chemosis, and paralysis of eye movements due to involvement of the oculomotor, abducent, or trochlear nerves.

Patients with isolated intracranial hypertension have headache but no other neurologic symptoms, with the exception of diplopia due to involvement of the sixth nerve when the intracranial pressure is quite high. Funduscopic examination will reveal papilledema. Severe papilledema can cause transient visual impairments, and even permanent blindness, if left untreated.

DIAGNOSIS

Although the clinical presentation is highly variable, the diagnosis should be considered in young and middle-aged patients with recent unusual headache or with stroke-like symptoms in the absence of the usual vascular risk factors, in patients with intracranial hypertension, and in patients with CT evidence of hemorrhagic infarcts, especially if the infarcts are multiple and not confined to the arterial vascular territories. The average delay from the onset of symptoms to the diagnosis is seven days.¹ The most sensitive examination technique is MRI in combination with magnetic resonance venography.^{33,34} T₁-weighted and T₂-weighted MRI will show a hyperintense signal from the thrombosed sinuses (Fig. 4). The characteristics of the signal depend on the age of the thrombus and are isointense on T₁-weighted images during the first five days and after one month.^{34,35} The combination of an abnormal signal in a sinus and a corresponding absence of flow on magnetic resonance venography confirms the diagnosis of thrombosis, but expert radiologic judgment is required to avoid diagnostic and technical pitfalls.³⁶ If MRI is not readily available, CT scanning is a useful technique for the initial examination, to rule out other acute cerebral disorders and to show venous infarcts or hemorrhages, but its results can also be entirely normal. High-resolution CT equipment may show the thrombus as a hyperintense signal in a sinus or even in the cortical veins (the "cord sign"). CT venography is a promising new technique for creating images of the cerebral venous system (Fig. 3).² If the diagnosis is still uncertain after MRI or CT venography has been per-

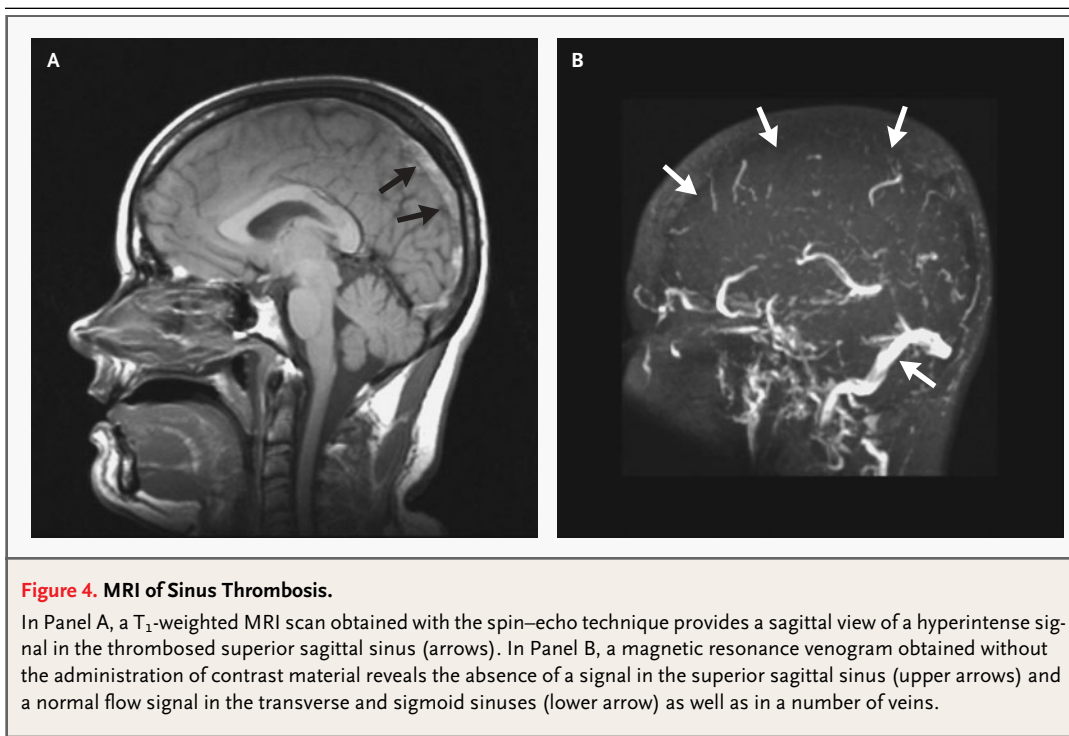


Figure 4. MRI of Sinus Thrombosis.

In Panel A, a T₁-weighted MRI scan obtained with the spin-echo technique provides a sagittal view of a hyperintense signal in the thrombosed superior sagittal sinus (arrows). In Panel B, a magnetic resonance venogram obtained without the administration of contrast material reveals the absence of a signal in the superior sagittal sinus (upper arrows) and a normal flow signal in the transverse and sigmoid sinuses (lower arrow) as well as in a number of veins.

formed, cerebral angiography may be indicated. Angiography provides better details of the cerebral veins and hence is useful in the diagnosis of rare cases of isolated thrombosis of the cortical veins without sinus thrombosis.³⁴ Angiography also shows dilated and tortuous (“corkscrew”) veins, which are evidence of thrombosis downstream in the sinuses (Fig. 5). Interpretation of the angiograms can be difficult because of anatomical variations such as a unilaterally hypoplastic or absent transverse sinus.⁵

TREATMENT

GENERAL MEASURES

The combination of acutely increased intracranial pressure and large venous infarcts is dangerous, and patients may die within hours from cerebral herniation. Impaired consciousness and cerebral hemorrhage are associated with a poor outcome,^{1,37} but even patients with these manifestations can make a remarkable recovery. The priority of treatment in the acute phase is to stabilize the patient’s condition and to prevent or reverse cerebral herniation. This may require the administration of intravenous mannitol, surgical removal of the hemorrhagic infarct, or decompressive hemicraniectomy.³⁸ It is not known

whether the administration of corticosteroids in the acute phase improves outcome. Possible causes of sinus thrombosis, such as infections, should be searched for and treated.

ANTICOAGULATION

The most obvious treatment option is anticoagulation with heparin to arrest the thrombotic process and to prevent pulmonary embolism, which may complicate sinus thrombosis.³⁹ However, anticoagulant treatment has raised much controversy because of the tendency of venous infarcts to become hemorrhagic: about 40 percent of all patients with sinus thrombosis have a hemorrhagic infarct even before anticoagulant treatment is started.¹

The effect of anticoagulant treatment has been examined in three small, randomized clinical trials.⁴⁰⁻⁴² The first trial compared the effect of intravenous heparin with that of placebo and was stopped after only 10 patients had been included in each treatment group, because an interim analysis showed a significant benefit with heparin, according to the investigators.⁴⁰ A repeated analysis, which was based on the usual scales of stroke outcome, did not show a statistically significant difference between the effect of heparin and that of placebo.⁴³ Also, the average delay of four weeks from the on-

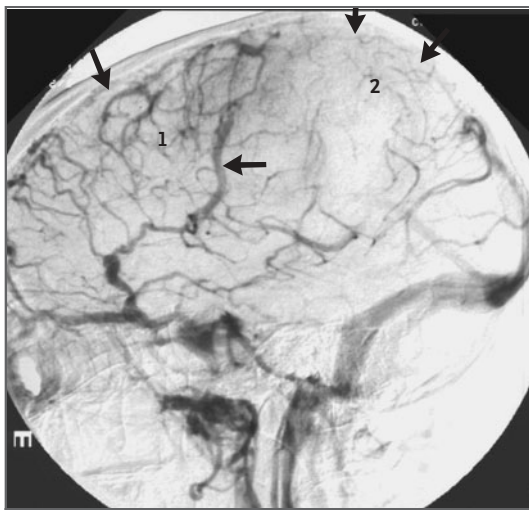


Figure 5. Angiographic Image (Venous Phase) of Sinus Thrombosis.

In this venous phase of a digital-subtraction angiogram that was obtained after the injection of contrast material into the right internal carotid artery (left lateral view), a large part of the superior sagittal sinus (arrows at upper perimeter) and some cortical veins (near 2) do not fill with contrast material. The sigmoid and transverse sinuses are normal. There is increased contrast in the frontal cortical veins (near 1) and increased filling of the superior anastomotic vein (Trolard's vein; lower arrow).

set of symptoms to the beginning of treatment was exceptionally long. The second study compared the effect of fixed high-dose, subcutaneous nadroparin with that of placebo in 60 patients and found no statistically significant difference.⁴¹ This study was criticized for an imbalance at baseline, which may have favored the placebo group.⁴⁴ The third study compared the effect of intravenous unfractionated heparin with that of placebo in 57 women from India who had puerperal sinus thrombosis but in whom the diagnosis had not been confirmed by MRI or angiography.⁴² All three trials showed a nonsignificant benefit of anticoagulant treatment as compared with placebo. In the two trials that involved adequate diagnostic imaging, 23 percent of the patients given placebo had poor outcomes (death or functional dependency), as compared with 10 percent of the group that received anticoagulant therapy. A meta-analysis of these studies showed a nonsignificant reduction in the pooled relative risk of death or dependency of 0.46 (95 percent confidence interval, 0.16 to 1.31).⁴³

A new trial with enough power to demonstrate a similar effect of treatment would require the recruit-

ment of 300 patients. With a rare disease such as sinus thrombosis, this would be challenging but feasible. In the absence of hard evidence from trials, circumstantial evidence can help in choosing the best treatment strategy. The main reason to avoid heparin in the treatment of sinus thrombosis has been concern about its safety. Although the trials mentioned above included patients who had had hemorrhagic infarcts before treatment, no increased or new cerebral hemorrhages developed after treatment with heparin. Moreover, two cases of pulmonary embolism occurred in the placebo groups. Most neurologists now start treatment with heparin as soon as the diagnosis is confirmed, even in the presence of hemorrhagic infarcts. This treatment was applied to more than 80 percent of the 624 patients in a recent prospective study.¹ In this study, 79 percent of the patients recovered, 8 percent had minor handicaps, 5 percent were severely handicapped, and 8 percent died. There have been no studies that compared the effect of fractionated heparin with that of unfractionated heparin in the treatment of sinus thrombosis. In the treatment of thrombosis of the leg veins, fixed high-dose, subcutaneous heparin of low molecular weight causes less major bleeding than does intravenous heparin and has similar antithrombotic efficacy.⁴⁵

The optimal duration of oral anticoagulant treatment after the acute phase is unknown. Recurrent sinus thrombosis occurs in 2 percent of patients, and about 4 percent of patients have an extracranial thrombotic event within one year.¹ Usually, vitamin K antagonists are given for six months after a first episode of sinus thrombosis, or longer in the presence of predisposing factors, with a target international normalized ratio of 2.5.

THROMBOLYSIS

Endovascular thrombolysis can be attempted with the administration of a thrombolytic enzyme, usually urokinase, into the sinus, sometimes in combination with mechanical thrombo-aspiration. Published reports are limited to case reports and uncontrolled studies, from which it is impossible to conclude that the results associated with endovascular thrombolysis are superior to those with systemic heparin.⁴⁶ Until better evidence is available, endovascular thrombolysis may be applied at centers where the staff have experience in interventional radiology, and this treatment method should be restricted to patients with a poor prognosis. A randomized trial is needed to compare the effect of

heparin with that of endovascular thrombolysis in high-risk patients.

INTRACRANIAL HYPERTENSION

In patients who have symptoms of chronic intracranial hypertension only, the first priority is to rule out a space-occupying process and to investigate whether sinus thrombosis is indeed the cause. If there are no contraindications, such as large infarcts or hemorrhages, a lumbar puncture is then performed to measure the cerebrospinal fluid pressure. This is also the start of treatment, the objective of which is to lower the intracranial pressure, to relieve headache, and to reduce papilledema. Oral acetazolamide (500 to 1000 mg daily) may reduce the intracranial pressure. Often, if effective and tolerated, this agent must be continued for weeks to months, as demonstrated among patients with idiopathic intracranial hypertension.⁴⁷ If repeated lumbar

punctures and treatment with acetazolamide do not control the intracranial pressure within about two weeks, surgical drainage of the cerebrospinal fluid is indicated, usually by a lumboperitoneal shunt. If the visual fields deteriorate, fenestration of the optic-nerve sheath should be considered.⁴⁸ Both of these procedures are associated with complications, and it is unknown which procedure yields the best long-term results.

In summary, important advances have been made in our understanding of the pathophysiology of sinus thrombosis. Sinus thrombosis remains a diagnostic challenge and a potentially disabling or lethal disease, but improved diagnosis and treatment now result in an excellent outcome for most patients.

I am indebted to Marinus Vermeulen and Wouter Wieling for their comments on early versions of the manuscript, to Dirk Troost for providing Figure 2, and to Charles B.L.M. Majoie for his help with Figures 3, 4, and 5.

REFERENCES

1. Ferro JM, Canhao P, Stam J, Bousser MG, Barinagarrementeria F. Prognosis of cerebral vein and dural sinus thrombosis: results of the International Study on Cerebral Vein and Dural Sinus Thrombosis (ISCVT). *Stroke* 2004;35:664-70.
2. Majoie CB, van Straten M, Venema HW, den Heeten GJ. Multisection CT venography of the dural sinuses and cerebral veins by using matched mask bone elimination. *AJNR Am J Neuroradiol* 2004;25:787-91.
3. Corvol JC, Oppenheim C, Manai R, et al. Diffusion-weighted magnetic resonance imaging in a case of cerebral venous thrombosis. *Stroke* 1998;29:2649-52.
4. Yoshikawa T, Abe O, Tsuchiya K, et al. Diffusion-weighted magnetic resonance imaging of dural sinus thrombosis. *Neuroradiology* 2002;44:481-8.
5. Bousser M-G, Ross Russell RW. Cerebral venous thrombosis. London: W.B. Saunders, 1997.
6. deVeber G, Andrew M. Cerebral sinus venous thrombosis in children. *N Engl J Med* 2001;345:417-23.
7. Deschiens MA, Conard J, Horellou MH, et al. Coagulation studies, factor V Leiden, and anticardiolipin antibodies in 40 cases of cerebral venous thrombosis. *Stroke* 1996;27:1724-30.
8. Enevoldson TP, Russell RW. Cerebral venous thrombosis: new causes for an old syndrome? *Q J Med* 1990;77:1255-75.
9. Martinelli I, Sacchi E, Landi G, Taioli E, Duca F, Mannucci PM. High risk of cerebral-vein thrombosis in carriers of a prothrombin-gene mutation and in users of oral contraceptives. *N Engl J Med* 1998;338:1793-7.
10. Ludemann P, Nabavi DG, Junker R, et al. Factor V Leiden mutation is a risk factor for cerebral venous thrombosis: a case-control study of 55 patients. *Stroke* 1998;29:2507-10.
11. Weih M, Junge-Hulsing J, Mehraein S, Ziemer S, Einhaupl KM. Hereditäre Thrombophilien bei ischamischem Schlaganfall und Sinusvenenthrombosen: Diagnostik, Therapie und Meta-Analyse. *Nervenarzt* 2000;71:936-45.
12. Reuner KH, Ruf A, Grau A, et al. Prothrombin gene G20210→A transition is a risk factor for cerebral venous thrombosis. *Stroke* 1998;29:1765-9.
13. Hillier CE, Collins PW, Bowen DJ, Bowley S, Wiles CM. Inherited prothrombotic risk factors and cerebral venous thrombosis. *QJM* 1998;91:677-80.
14. Cantu C, Alonso E, Jara A, et al. Hyperhomocysteinemia, low folate and vitamin B12 concentrations, and methylene tetrahydrofolate reductase mutation in cerebral venous thrombosis. *Stroke* 2004;35:1790-4.
15. Carhuapoma JR, Mitsias P, Levine SR. Cerebral venous thrombosis and anticardiolipin antibodies. *Stroke* 1997;28:2363-9.
16. Cantu C, Barinagarrementeria F. Cerebral venous thrombosis associated with pregnancy and puerperium: review of 67 cases. *Stroke* 1993;24:1880-4.
17. Lanska DJ, Kryscio RJ. Risk factors for peripartum and postpartum stroke and intracranial venous thrombosis. *Stroke* 2000;31:1274-82.
18. Vidailhet M, Piette JC, Wechsler B, Bousser MG, Brunet P. Cerebral venous thrombosis in systemic lupus erythematosus. *Stroke* 1990;21:1226-31.
19. Daif A, Awada A, al-Rajeh S, et al. Cerebral venous thrombosis in adults: a study of 40 cases from Saudi Arabia. *Stroke* 1995;26:1193-5.
20. Farah S, Al-Shubaili A, Montaser A, et al. Behcet's syndrome: a report of 41 patients with emphasis on neurological manifestations. *J Neurol Neurosurg Psychiatry* 1998;64:382-4.
21. Wermes C, Fleischhack G, Junker R, et al. Cerebral venous sinus thrombosis in children with acute lymphoblastic leukemia carrying the MTHFR TT677 genotype and further prothrombotic risk factors. *Klin Padiatr* 1999;211:211-4.
22. Hillmen P, Lewis SM, Bessler M, Luzzatto L, Dacie JV. Natural history of paroxysmal nocturnal hemoglobinuria. *N Engl J Med* 1995;333:1253-8.
23. de Bruijn SF, Stam J, Koopman MM, Vandenbroucke JP. Case-control study of risk of cerebral sinus thrombosis in oral contraceptive users and in [correction of who are] carriers of hereditary prothrombotic conditions. *BMJ* 1998;316:589-92. [Erratum, *BMJ* 1998;316:822.]
24. Stiefel D, Eich G, Sacher P. Posttraumatic dural sinus thrombosis in children. *Eur J Pediatr Surg* 2000;10:41-4.
25. Wilder-Smith E, Kothbauer-Margreiter I, Lammler B, Sturzenegger M, Ozdoba C, Hauser SP. Dural puncture and activated protein C resistance: risk factors for cerebral venous sinus thrombosis. *J Neurol Neurosurg Psychiatry* 1997;63:351-6.
26. de Bruijn SF, Stam J, Vandenbroucke JP. Increased risk of cerebral venous sinus thrombosis with third-generation oral contraceptives. *Lancet* 1998;351:1404.
27. Krabenbühl HA. Cerebral venous and sinus thrombosis. *Clin Neurosurg* 1966;14:1-24.
28. de Bruijn SFTM, ed. Cerebral venous sinus thrombosis: clinical and epidemiological studies. Amsterdam: Thesis, 1998.

29. Vandenbroucke JP, Rosing J, Bloemenkamp KW, et al. Oral contraceptives and the risk of venous thrombosis. *N Engl J Med* 2001;344:1527-35.
30. Aidi S, Chauun MP, Biousse V, Bousser MG. Changing pattern of headache pointing to cerebral venous thrombosis after lumbar puncture and intravenous high-dose corticosteroids. *Headache* 1999;39:559-64.
31. de Bruijn SF, Stam J, Kappelle LJ. Thunderclap headache as first symptom of cerebral venous sinus thrombosis. *Lancet* 1996;348:1623-5.
32. Kothare SV, Ebb DH, Rosenberger PB, Buonanno F, Schaefer PW, Krishnamoorthy KS. Acute confusion and mutism as a presentation of thalamic strokes secondary to deep cerebral venous thrombosis. *J Child Neurol* 1998;13:300-3.
33. Lafitte F, Boukobza M, Guichard JP, et al. MRI and MRA for diagnosis and follow-up of cerebral venous thrombosis (CVT). *Clin Radiol* 1997;52:672-9.
34. Dormont D, Anxionnat R, Evrard S, Louaille C, Chiras J, Marsault C. MRI in cerebral venous thrombosis. *J Neuroradiol* 1994;21:81-99.
35. Isensee C, Reul J, Thron A. Magnetic resonance imaging of thrombosed dural sinuses. *Stroke* 1994;25:29-34.
36. Ayanzen RH, Bird CR, Keller PJ, McCully FJ, Theobald MR, Heiserman JE. Cerebral MR venography: normal anatomy and potential diagnostic pitfalls. *AJNR Am J Neuroradiol* 2000;21:74-8.
37. de Bruijn SF, de Haan RJ, Stam J. Clinical features and prognostic factors of cerebral venous sinus thrombosis in a prospective series of 59 patients. *J Neurol Neurosurg Psychiatry* 2001;70:105-8.
38. Stefini R, Latronico N, Cornali C, Rasulo F, Bollati A. Emergent decompressive craniectomy in patients with fixed dilated pupils due to cerebral venous and dural sinus thrombosis: report of three cases. *Neurosurgery* 1999;45:626-9.
39. Diaz JM, Schiffman JS, Urban ES, Macario M. Superior sagittal sinus thrombosis and pulmonary embolism: a syndrome rediscovered. *Acta Neurol Scand* 1992;86:390-6.
40. Einhaupl KM, Villringer A, Meister W, et al. Heparin treatment in sinus venous thrombosis. *Lancet* 1991;338:597-600. [Erratum, *Lancet* 1991;338:958.]
41. de Bruijn SF, Stam J. Randomized, placebo-controlled trial of anticoagulant treatment with low-molecular-weight heparin for cerebral sinus thrombosis. *Stroke* 1999;30:484-8.
42. Nagaraja D, Rao BSS, Taly AB, Subhash MN. Randomized controlled trial of heparin in puerperal cerebral venous/sinus thrombosis. *Nimhans J* 1995;13:111-5.
43. Stam J, De Bruijn SF, DeVeber G. Anticoagulation for cerebral sinus thrombosis. *Cochrane Database Syst Rev* 2002;4:CD002005.
44. Bousser MG. Cerebral venous thrombosis: nothing, heparin, or local thrombolysis? *Stroke* 1999;30:481-3.
45. van den Belt A, Prins MH, Lensing AW, et al. Fixed dose subcutaneous low molecular weight heparins versus adjusted dose unfractionated heparin for venous thromboembolism. *Cochrane Database Syst Rev* 2002;2:CD001100.
46. Canhão P, Falcao F, Ferro JM. Thrombolytics for cerebral sinus thrombosis: a systematic review. *Cerebrovasc Dis* 2003;15:159-66.
47. Kesler A, Hadayer A, Goldhammer Y, Almog Y, Korczyn AD. Idiopathic intracranial hypertension: risk of recurrences. *Neurology* 2004;63:1737-9.
48. Tse DT, Chang WJ. Surgery of the orbit and optic nerve. In: Glaser JS, ed. *Neurophthalmology*. 3rd ed. Philadelphia: Lippincott Williams & Wilkins, 1999:520-3.

Copyright © 2005 Massachusetts Medical Society.

CLINICAL TRIAL REGISTRATION

The *Journal* encourages investigators to register their clinical trials in a public trials registry. The members of the International Committee of Medical Journal Editors plan to consider clinical trials for publication only if they have been registered (see *N Engl J Med* 2004;351:1250-1). The National Library of Medicine's www.clinicaltrials.gov is a free registry, open to all investigators, that meets the committee's requirements.