



UvA-DARE (Digital Academic Repository)

Assessment and preservation of liver function in hepatic ischemia and reperfusion

Heijnen, B.H.M.

Publication date
2003

[Link to publication](#)

Citation for published version (APA):

Heijnen, B. H. M. (2003). *Assessment and preservation of liver function in hepatic ischemia and reperfusion*.

General rights

It is not permitted to download or to forward/distribute the text or part of it without the consent of the author(s) and/or copyright holder(s), other than for strictly personal, individual use, unless the work is under an open content license (like Creative Commons).

Disclaimer/Complaints regulations

If you believe that digital publication of certain material infringes any of your rights or (privacy) interests, please let the Library know, stating your reasons. In case of a legitimate complaint, the Library will make the material inaccessible and/or remove it from the website. Please Ask the Library: <https://uba.uva.nl/en/contact>, or a letter to: Library of the University of Amsterdam, Secretariat, Singel 425, 1012 WP Amsterdam, The Netherlands. You will be contacted as soon as possible.

Chapter 7

Decrease in core liver temperature with 10°C by in situ hypothermic perfusion under total hepatic vascular exclusion reduces liver ischemia and reperfusion injury during partial hepatectomy in pigs.

Bob H.M. Heijnen, Irene H. Straatsburg, Dirk J. Gouma, Thomas M. van Gulik

Dept. of Surgery, Surgical Laboratory, Academic Medical Center, Amsterdam, The Netherlands

Surgery, in press

Abstract

Objective: The aim of this study was to assess liver I/R injury under a mild decrease in core liver temperature with 10°C by *in situ* hypothermic perfusion during ischemia.

Methods: Liver ischemia was induced by total hepatic vascular exclusion with concomitant *in situ* perfusion with hypothermic (4°C) Ringer-glucose (cold perfused group, core liver temperature maintained at 28°C), with normothermic (38°C) Ringer-glucose (warm perfused group) or without *in situ* perfusion (control group).

Results: In the cold perfused, warm perfused and control groups, 24 hrs survival was 5/5, 0/5 and 3/5 respectively. Hemodynamic parameters in the cold perfused group remained stable whereas pigs in both other groups required circulatory support. Plasma AST and IL-6 levels were lower in the cold perfused group than in both other groups. Hepatocellular function was best preserved in the cold perfused group as indicated by complete recovery of bile production during reperfusion and no loss of indocyanine green (ICG) clearance capacity. In both other groups, bile production and ICG clearance capacity were significantly reduced. Hyaluronic acid uptake capacity of pigs in the cold perfused group or control group did not differ, indicating preserved sinusoidal endothelial cell function. Histopathological injury-scores during reperfusion were significantly lower in the cold perfused group when compared to both other groups.

Conclusions: A mild decrease in core liver temperature with 10°C by *in situ* hypothermic liver perfusion during ischemia significantly protects the liver from I/R injury. This protection owes to cooling of the liver rather than the wash out of blood during perfusion.

Abbreviations

AST	aspartate aminotransferase
HA	hyaluronic acid
ICG	indocyanine green
I/R	ischemia/reperfusion
LHX	left hemihepatectomy
SEC	sinusoidal endothelial cell
THVE	total hepatic vascular exclusion

Introduction

During major liver resections, blood flow to the liver may be temporarily occluded to prevent massive blood loss. This maneuver, first described by Pringle in 1908, reduces intra-operative blood loss and significantly improves post-operative outcome¹⁻³. A second factor contributing to intraoperative blood loss during resection is back-bleeding from the hepatic veins. This problem can be tackled by occluding the supra- and infrahepatic caval vein in conjunction with vascular inflow occlusion. This technique of total hepatic vascular exclusion (THVE) has been reported to effectively reduce blood loss during extensive resectional procedures of the liver^{4,5}. At the same time, this maneuver induces ischemia of the liver by vascular inflow occlusion of the portal vein and hepatic artery. Subsequent reperfusion is initiated when the clamps are released and the circulation to the liver is restored, giving rise to ischemia/reperfusion (I/R) injury⁶.

Normothermic ischemia up to one hour is well tolerated in normal human livers, however morbidity rates in patients with chronic hepatic disease are significantly higher^{1,2,7}. Whereas in the majority of liver resections, parenchymal dissection can be completed within one hour, tumoral invasion in surrounding vascular structures may necessitate major liver resections with vascular reconstruction, leading to longer periods of normothermic ischemia^{8,9}. When liver I/R injury can be reduced, clamping times can be safely prolonged, allowing a more prudent, unhurried transection of liver parenchyma and consequent decrease in the risk of technical error, bile leakage and intra- and postoperative hemorrhage.

To attenuate ischemic injury, hypothermia is commonly used for the preservation of liver grafts and recently has also been applied during hepatic resections under THVE¹⁰⁻¹². The influence of ischemia on parenchymal cells and sinusoidal endothelial cells (SEC) under hypothermic conditions, are clearly distinct. Whereas parenchymal cells are protected from I/R injury, SEC injury is enhanced by hypothermic ischemia and subsequent reperfusion¹³. Recent studies have pointed out that the optimal temperature for cooling of organs has not been defined and that mild hypothermia (26-34°C instead of 4°C) effectively protects the liver microcirculation¹⁴.

The aim of this study was to assess liver I/R injury under 120 min of THVE while decreasing the core temperature of the liver with 10°C by *in situ* hypothermic perfusion of the liver during left hemihepatectomy (LHX). Perfusion of the liver prevents stasis of blood in the microcirculation, which could be in part responsible for the attenuation of liver I/R injury. Therefore, to distinguish between the effects of cooling per se, and blood clearance of the liver on

I/R injury, a second group of pigs underwent LHX during THVE in combination with *in situ*, normothermic liver perfusion. A third group of pigs underwent LHX during 120 min of THVE without *in situ* perfusion as control series. The main outcome parameters were survival of the animal, hemodynamic changes, parenchymal and SEC injury, functional capacity of hepatocytes and inflammatory response during 24 hrs of reperfusion.

Materials and methods

Animal preparation

This study was approved by the Animal Experiment Committee of the Academic Medical Center, University of Amsterdam, The Netherlands. Fifteen female pigs (36-46 kg; Vendrig, Amsterdam, The Netherlands) were used. All pigs were allowed to acclimatize to the laboratory environment for 7 days with free access to water and standard laboratory food (Blok, Woerden, The Netherlands). Pigs were housed under standard environmental conditions with a 12-hour light/dark cycle. Pigs were fasted overnight with free access to water before use in experiments.

Anesthesia

Female pigs were premedicated with ketamine (10mg/kg; Nimatec[®], Eurovet, Bladel, The Netherlands), clonidine (5µg/kg) and atropine (0.1mg/kg). After inhalation of a mixture of O₂ : N₂O (1 : 1 l/min) and isoflurane (1-1.5%; Florene[®], Abbott Laboratories Ltd., Queensborough, Kent, United Kingdom), pigs were intubated endotracheally and ventilated with a mixture of O₂ and air. Anesthesia was maintained by intravenous administration (25 ml/h before LHX and 12 ml/h after LHX) of a mixture of sufentanil citrate (20mg/l; Sufenta Forte[®], Janssen-Cilag, Tilburg, The Netherlands) and ketamine (20g/l). Muscle relaxation was accomplished by intravenous administration (2 ml/h) of pancuronium bromide (2 mg/ml; Pavulon[®], Organon Teknika B.V., Boxtel, The Netherlands). Arterial blood pressure was maintained by fluid infusion (Hartman, Ringer-glucose, NPBI B.V., Emmer-Compascum, The Netherlands and eloHaes, Fresenius B.V., 's-Hertogenbosch, The Netherlands). If fluid infusion alone could not maintain mean arterial blood pressure above 55 mmHg, phenylephrine (10 mg/ml; 2-25 ml/h i.v.) was administered. Plasma glucose level was controlled by infusion of 20% glucose solution in saline.

Surgical procedure

All operative procedures were performed under sterile conditions. A cannula was inserted in the ear vein for administration of all anesthetic drugs. A second cannula was inserted in the cephalic

vein for fluid infusion. Furthermore, a cannula was inserted in the popliteal artery for monitoring of blood pressure and heart rate and for the purpose of blood sampling and a Swann-Ganz catheter was inserted in the left jugular vein for measurement of pulmonary, wedge and central venous pressures. Urine production was monitored after surgical insertion of a catheter in the bladder. A cell-saver unit (Cellsaver[®] 3 plus, Haemonatics[®], Massachusetts, USA) was used during the procedure.

After midline laparotomy, all ligamentous connections to the liver were divided. After isolation of the hepatic pedicle, the common bile duct was cannulated to assess bile production during the experiment and the common hepatic artery, portal and caval vein were dissected free. In order to cut off any accessory blood supply to the liver, the right gastric and gastroduodenal artery were divided. The left main branch(es) of the portal vein and hepatic artery were ligated resulting in discoloration of the left liver lobes, thereby defining the resection plane. Ischemia of the liver was induced by clamping the portal vein, common hepatic artery as well as the suprahepatic and infrahepatic caval vein for total hepatic vascular exclusion (THVE). A Venflon[™] (16 GA) was inserted in the proximal stump of the severed, left hepatic artery for retrograde perfusion of cold or warm isotonic Ringer-glucose into the right liver. Because pigs do not resist splanchnic congestion, a polyethylene prosthesis with one side port was devised to bypass blood from the infrahepatic caval vein and the portal vein to the suprahepatic caval vein. After transverse incision in the infrahepatic caval vein, the prosthesis was inserted and guided in cranial direction after which the distal end was fixed with a sling cranial to the hepatic veins. Caudal to the incision in the infrahepatic caval vein, the prosthesis was fixed with a sling above the renal veins. A silicone tube (DLP[®] 16 Fr, Medtronic Cardiac Surgical Products, Grand Rapids, MI 49504-6393 USA) was inserted in the portal vein and attached to the side port of the prosthesis as a portal-systemic shunt (Figure 1). The bypass procedure did not last for more than 5 min on average to complete. During retrograde perfusion, the perfusate was drained from the caval vein via the previous incision. A left hemihepatectomy was performed using an electro-surgical knife. Hemostasis at the resection margin was achieved by suture closure of the resection plane of the remnant liver. Reperfusion was initiated by removing the clamps from the hepatic artery and portal vein. Just prior to reperfusion, the sling above the hepatic veins was released, allowing blood from the liver to drain again into the caval vein and a second ligature was placed distal of the caval incision (preventing blood from the liver to enter the abdominal cavity during reperfusion). The portal-systemic shunt was removed and the abdomen was closed.

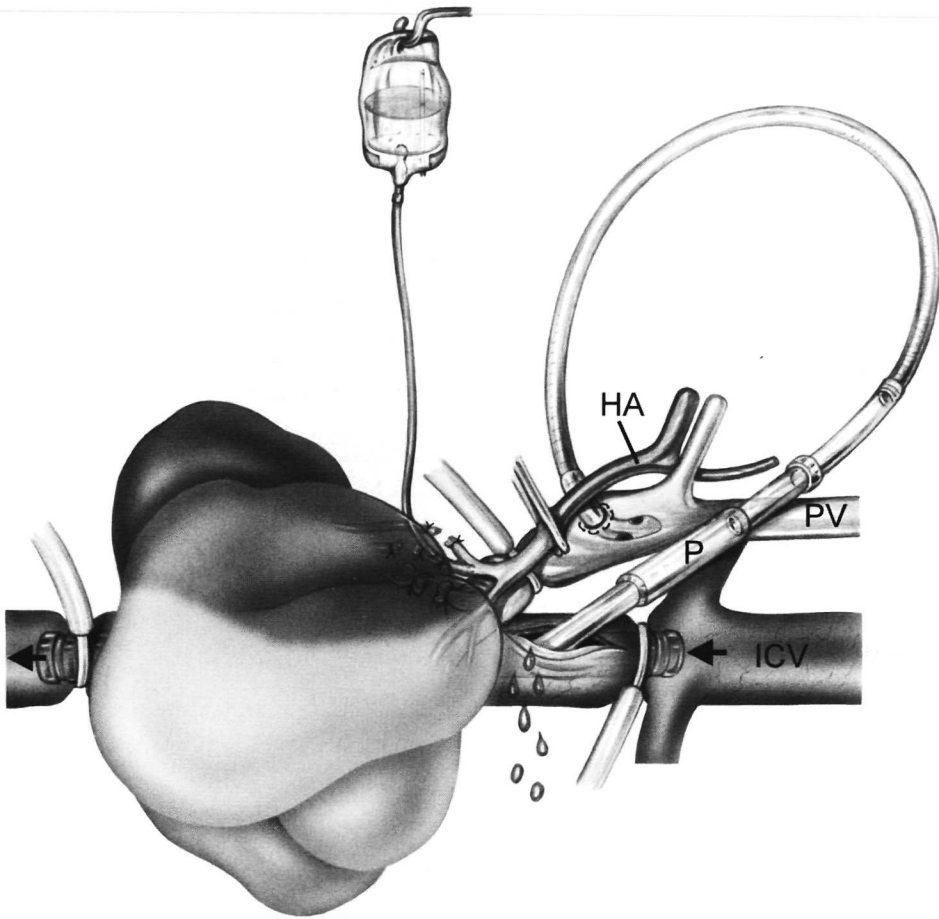


Figure 1.

Situation created during total hepatic vascular exclusion (THVE) in the pig. Both portal vein (PV) and hepatic artery (HA) are occluded. A polyethylene prosthesis (P) is inserted in the inferior caval vein (ICV) and slings are tightened at both ends, allowing blood from the infrahepatic vein to drain through the prosthesis to the heart. A silicone tube is inserted in the PV and is attached to the side-port of the prosthesis as a portal venous shunt. An infusion system is applied after division of left HA and retrograde perfusion is initiated, resulting in discoloration (with or without cooling) of the right hepatic lobes. The perfusate is drained from the caval vein via the incision used for access of the prosthesis. THVE was continued for 2 hrs in which time a left hemihepatectomy (LHX) was performed.

Experimental design

Fifteen female pigs underwent 120 min of continuous liver ischemia under THVE, followed by 24 hrs of reperfusion. The first group received a left hemihepatectomy while the future remnant liver was perfused with cold (4°C) isotonic Ringer-glucose (cold-LHX group). The second group underwent a left hemihepatectomy while the future remnant liver was perfused with normothermic (38°C) isotonic Ringer-glucose (warm-LHX group), to compare with the effects of *in situ* cooling. The third group underwent a left hemihepatectomy without *in situ* fluid perfusion (control-LHX group, n=5). In all pigs, both rectal and esophageal temperature were monitored continuously as well as core liver temperature (Mon-a-therm[®] Myocardial Thermistor YSI 400 series 30mm temperature probe connected to a Thermistor monitor model 4070, Mallinckrodt, St. Louis, USA).

A pressurized standard clinical infusion system (Flexline, Medisize, Hillegom, The Netherlands) was used to perfuse the right liver lobes by retrograde infusion of Ringer-glucose through the left hepatic artery. This infusion system allows for adjustment of flow rate. Immediately after induction of ischemia, maximum flow rate was used to rapidly drain the liver from blood with or without cooling. In case of cooling, maximum flow rate was maintained until the desired core liver temperature of 28°C was reached. To maintain a liver temperature of 28°C flow rate was adjusted accordingly. In case of normothermic ischemia, liver temperature was maintained at 38°C (= body temperature).

Assessment of hepatocellular injury

Hepatocellular injury was assessed by measurement of aspartate aminotransferase (AST) levels in plasma. In pigs, alanine aminotransferase (ALT) and lactate dehydrogenase (LDH) are less discriminative and less sensitive parameters for hepatocellular injury, as was concluded from previous experiments in our laboratory¹⁵. Plasma aspartate aminotransferase (AST) levels were measured before ischemia and after 10 min, 6, 12 and 24 hrs of reperfusion.

Assessment of hepatocellular function

Bile production is an active secretory process of hepatocytes involving bile salt-dependent and salt-independent mechanisms. Both bile salt-dependent and bile salt-independent bile productions are considered to be reliable parameters for the assessment of hepatocellular function¹⁶. Bile production, as parameter of excretory hepatocellular function, was monitored continuously and was expressed as ml/min. In order to make comparison between pre-ischemic and post-ischemic

values possible, reported pre-ischemic levels reflect the bile production of the functional mass of the future remnant liver after resection.

The indocyanine green (ICG) clearance test, expressed as % of ICG cleared from the circulation 15 min after intravenous infusion, was used to assess hepatocellular function¹⁷. ICG is a dark green synthetic dye which is exclusively cleared from the circulation by the liver and secreted into bile without being metabolized¹⁸⁻²¹. After intravenous administration of ICG (0,5 mg/kg bw, SIGMA[®], Steinheim, Germany), plasma samples were collected every 5 min until 20 min. ICG concentration in plasma was determined by spectrophotometric analysis ($\lambda=805\text{nm}$). The ICG clearance rate after 6 and 24 hrs of reperfusion was compared with baseline clearance before ischemia.

Assessment of SEC function

The SEC take up and metabolize more than 90% of circulating hyaluronic acid (HA)²²⁻²⁴. The percentage of administered HA taken up by the SEC during 60 min was used as parameter for SEC function. After intravenous infusion of 5 mg HA (Healon®, Pharmacia & Upjohn AB, Uppsala, Sweden), plasma samples were collected every 10 min during 60 min starting 1 min after infusion. Plasma HA concentrations were measured using a radio-labeled binding assay (Pharmacia & Upjohn AB, Uppsala, Sweden). We examined the ability of SEC to take up exogenous HA after 24 hours of reperfusion.

Assessment of inflammatory response

Several parameters can be used to assess a systemic inflammatory response. In this study, plasma TNF- α and IL-1 levels were measured in the pigs but proved undetectable in any sample at any given time. Plasma IL-6 levels, however, could be accurately measured and are considered to be a reliable indicator of inflammatory response²⁵⁻²⁷. IL-6 concentration was measured in plasma by cell proliferative assay using the B9 cell line²⁸ and rHuIL-6 as a standard (CLB, Amsterdam, The Netherlands) before ischemia and after 10 min, 6, 12 and 24 hrs of reperfusion.

Histopathology

Liver biopsies were taken before ischemia, and after 10 min and 24 hrs of reperfusion, respectively. For light microscopy, biopsies were fixed in 4% buffered formaldehyde and were routinely processed for paraffin embedding. Sections (4 μ) were cut and stained with haematoxylin and eosin. Semi-quantitative light microscopic evaluation was performed of all sections to assess

liver parenchymal injury. All sections were examined for hepatocellular cytoplasmic color fading, hepatocellular vacuolisation, hepatocellular nuclear condensation, hepatocellular nuclear fragmentation, hepatocellular nuclear fading and erythrocyte stasis. Each phenomenon was scored according to the percentage of cells showing this phenomenon per 10 microscopic fields (200x): 0=0%, 1=0-10%, 2=10-50%, 3=50-100%.

Statistical analysis

results are expressed as mean \pm standard error of the mean (SEM). Statistical analysis (Student t-test and ANOVA for repeated measurements) was performed using GraphPad Prism version 3.02 for Windows (GraphPad Software, San Diego California USA). A p-value <0.05 was considered significant.

Results

Survival

All pigs in the cold-LHX group survived 120 min ischemia and 24 hrs of subsequent reperfusion, whereas not one pig survived in the warm-LHX group. In the control-LHX group, 3 out of 5 animals survived. Survival rate of pigs in the warm-LHX group was significantly lower when compared to pigs in the cold-LHX and control-LHX group (figure 2).

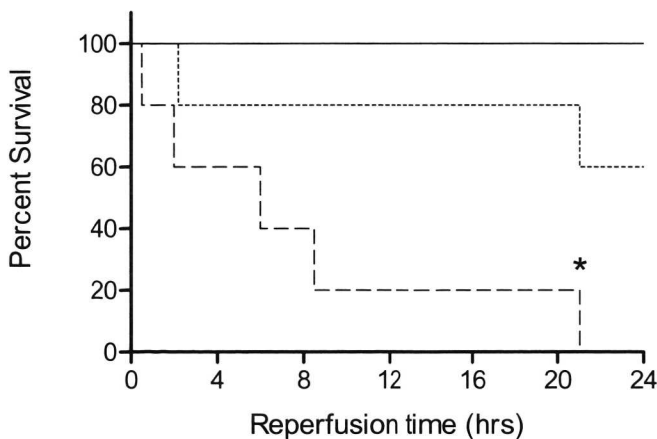


Figure 2.

Survival curves (Kaplan-Meier) of pigs after cold-LHX (straight line, n=5), warm-LHX (dashed line, n=5) and control-LHX (dotted line, n=5) and 24 hrs of reperfusion. All pigs survived after cold-LHX, whereas after warm-LHX and control-LHX, none and three pigs survived, respectively.

* Significantly lower when compared to the cold-LHX and control-LHX group.

General parameters

In pigs in the cold-LHX, warm-LHX and control-LHX groups, both resected liver weights (453 ± 25 , 472 ± 36 , 447 ± 18 gr, resp.) and remnant (736 ± 15 , 718 ± 30 , 728 ± 35 gr, resp.) liver weights (mean \pm SEM) were comparable.

Although normal body temperature of pigs is considered 38°C , pigs in this study showed higher pre-ischemic body temperatures of 39°C due to anesthesia-induced stress, a commonly observed phenomenon in our laboratory. Body temperature of pigs in all groups was significantly decreased with $1\text{-}2^\circ\text{C}$ after 2 hrs ischemia when compared to pre-ischemic levels, showing no significant differences between pigs in all groups. During reperfusion body temperature remained significantly below pre-ischemic temperature values in all groups (table 1).

Hemodynamic parameters changed significantly during the experiment (table 1). Hemodynamic parameters of pigs in the cold-LHX group remained stable during the experiment, without the need for intravenous phenylephrine administration.

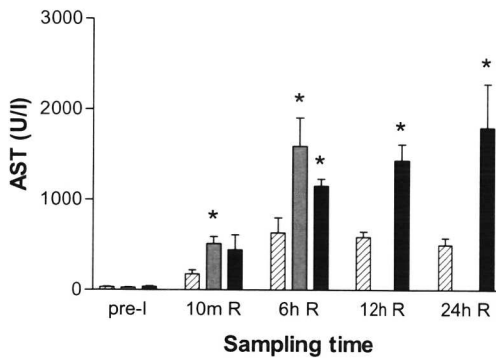
Experimental groups		Cold-LHX	Warm-LHX	Control-LHX
Body temp ($^\circ\text{C}$)	pre-I	39.1 ± 0.3^A	39.2 ± 0.4^B	38.7 ± 0.2^C
	0 hr R	37.1 ± 0.1^A	38.0 ± 0.2^B	37.4 ± 0.3^C
	6 hrs R	38.0 ± 0.2	38.3 ± 0.7	38.3 ± 0.2
	24 hrs R	38.1 ± 0.0		38.3 ± 0.1
SAP (mmHg)	pre-I	110.6 ± 2.6	107.8 ± 2.4^{DE}	106.4 ± 0.7^F
	0 hr R	99.8 ± 7.7	67.0 ± 12.9^D	75.6 ± 7.7^F
	6 hrs R	95.6 ± 3.2	87.0 ± 2.3^E	96.5 ± 2.8
	24 hrs R	105.8 ± 1.2		97.3 ± 4.3
DAP (mmHg)	pre-I	81.2 ± 3.1^{GH}	71.5 ± 3.7^{KL}	75.8 ± 3.2^{MN}
	0 hr R	59.6 ± 4.7^G	40.8 ± 7.5^K	43.2 ± 5.2^M
	6 hrs R	51.0 ± 2.6^{HJ}	37.3 ± 5.7^{JL}	46.3 ± 3.5^N
	24 hrs R	59.0 ± 4.3^I		46.0 ± 8.9
Heart rate (beats/min)	pre-I	69 ± 4	84 ± 5	79 ± 6
	0 hr R	94 ± 10	112 ± 6	132 ± 20
	6 hrs R	77 ± 6^O	111 ± 7^O	94 ± 10
	24 hrs R	81 ± 10		118 ± 30
Phenylephrine (mg/h)	pre-I	0	0	0
	0 hr R	0	0	3.3 ± 3.3
	6 hrs R	0^{PQ}	226 ± 81^P	90 ± 19^Q
	24 hrs R	0^R		106 ± 71^R

Table 1

Mean rectal body temperature, hemodynamic parameters and use of phenylephrine before induction of ischemia and after 0, 6 and 24 hrs of reperfusion. Hemodynamic parameters remain most stable in pigs after cold-LHX with no need for phenylephrine. Values are expressed as mean \pm SEM. Temp=temperature, SAP=systolic arterial pressure, DAP=diastolic arterial pressure. Significant differences exist between values tagged with equal fonts ($p < 0.05$).

Hepatocellular injury

After control-LHX, AST levels were significantly elevated during reperfusion when compared to pre-ischemic levels and continued to increase during reperfusion, reaching maximum levels at 24 hrs. AST levels after warm-LHX were higher when compared to pigs after control-LHX during reperfusion but this did not reach statistical significance ($p = 0.17$). After cold-LHX, AST levels were significantly lower than in pigs after warm-LHX and control-LHX at all time points and reached maximum levels after 6 hrs of reperfusion (figure 3).

**Figure 3**

Plasma aspartate aminotransferase (AST) assessed in pigs after cold-LHX (dashed bar, $n = 5$), warm-LHX (grey bar, $n = 5$, $n = 3$ at 6 hrs of reperfusion) and control-LHX (closed bar, $n = 5$, $n = 4$ at 6 and 12 hrs of reperfusion, $n = 3$ at 24 hrs of reperfusion) at pre-ischemia and after 10 min, 6, 12 and 24 hrs of reperfusion. After cold-LHX, AST levels were significantly lower than after warm-LHX and control-LHX. Bars represent mean \pm SEM. * Significantly different from pigs after cold-LHX.

Hepatocellular function

Bile production decreased to almost zero during ischemia in all pigs. During 24 hrs of reperfusion bile production in pigs after cold-LHX returned to pre-ischemic levels. In contrast, bile production in pigs after warm-LHX and control-LHX did not recover and remained significantly lower when compared to pigs after cold-LHX (figure 4).

Indocyanine green (ICG) clearance in pigs in the cold-LHX group did not change during the time course of the experiments. However, after warm-LHX and control-LHX, ICG clearance after 6 hrs of reperfusion was significantly decreased. Pigs in the control-LHX group did not show any recovery of ICG clearance after 24 hrs of reperfusion and ICG clearance remained significantly lower when compared to pigs after cold-LHX (figure 5).

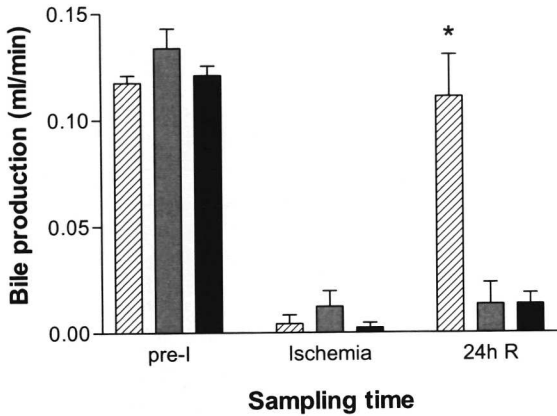


Figure 4

Bile production in pigs after cold-LHX (dashed bar, n=5), warm-LHX (grey bar, n=5, maximum n=4 during 21 hrs of reperfusion) and control-LHX (closed bar, n=5, n=4 during reperfusion) assessed pre-ischemia, during ischemia and during 24 hrs of reperfusion. In contrast to pigs after warm-LHX and control-LHX, bile production completely recovered during reperfusion after cold-LHX. Bars represent mean \pm SEM.

* Significantly different from pigs after warm-LHX and control-LHX.

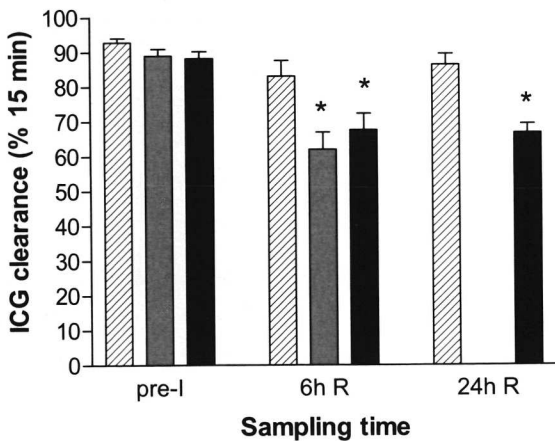


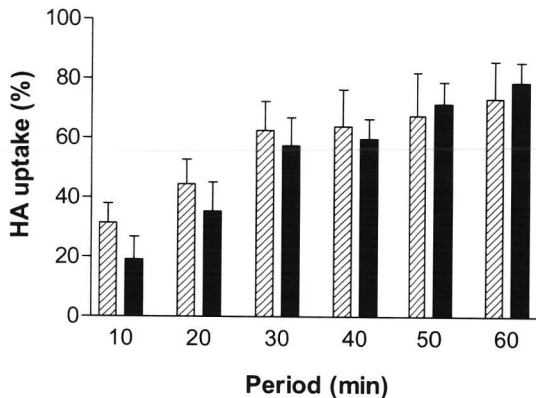
Figure 5

Indocyanine green (ICG) clearance in pigs after cold-LHX (dashed bar, n=5), warm-LHX (grey bar, n=5, n=3 at 6 hrs of reperfusion) and control-LHX (closed bar, n=5, n=4 at 6 hrs of reperfusion, n=3 at 24 hrs of reperfusion) at pre-ischemia and after 6 and 24 hrs of reperfusion. ICG clearance capacity was maintained during reperfusion after cold-LHX. After warm-LHX and control-LHX, ICG clearance was decreased during reperfusion, showing rates compatible with severely impaired liver function. Bars represent mean \pm SEM.

* Significantly different from pigs after cold-LHX.

SEC function

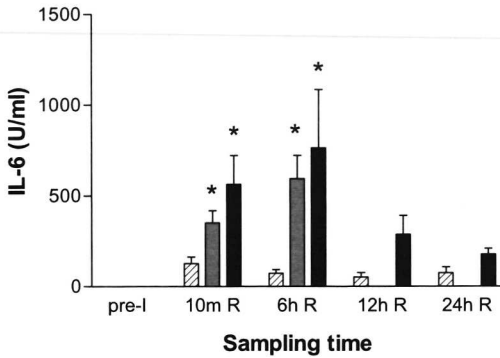
HA uptake could only be measured in pigs after cold-LHX and control-LHX since all pigs after warm-LHX died within 24 hrs of reperfusion. The HA uptake profile after 24 hrs of reperfusion was not significantly different between both groups during the 60 min sampling period. After cold-LHX and control-LHX, 74% and 78%, resp. of exogenous HA was cleared from the circulation indicating near normal SEC function²⁹ after 24 hrs of reperfusion in both groups.

**Figure 6**

Uptake of exogenous hyaluronic acid (HA) in a 60 min period following 2 hrs ischemia and 24 hrs of reperfusion after cold-LHX (dashed bar, n=5) and control-LHX (closed bar, n=3). There were no survivors in the warm-LHX group after 24 hrs of reperfusion. Results were expressed as the percentage of exogenous administered HA taken up by the sinusoidal endothelial cells (SEC) during 60 min. No decrease in SEC function was observed in pigs after cold-LHX when compared to pigs after control-LHX. Bars represent mean \pm SEM.

Inflammatory response

Inflammatory response was assessed by measurement of IL-6 in plasma. Plasma IL-6 was not detectable before induction of ischemia, indicating that none of the pigs suffered from infectious diseases prior to the experiment. After 10 min of reperfusion, pigs in all groups showed a marked increase in IL-6 levels, but levels in pigs after cold-LHX were significantly lower when compared to both other groups. At 6 hrs of reperfusion IL-6 levels of pigs in the warm-LHX and control-LHX group reached maximum values whereas IL-6 levels of pigs in the cold-LHX group showed a decrease. After 12 hrs and 24 hrs of reperfusion IL-6 levels of pigs after cold-LHX were still lower than in pigs after control-LHX but this did not reach statistical significance ($p=0.09$ and $p=0.08$ resp., figure 7).

**Figure 7**

Plasma IL-6 levels measured in pigs after cold-LHX (dashed bar, n=5), warm-LHX (grey bar, n=5, n=3 at 6 hrs of reperfusion) and control-LHX (closed bar, n=5, n=4 at 6 and 12 hrs of reperfusion, n=3 at 24 hrs of reperfusion) at pre-ischemia and after 10 min, 6, 12 and 24 hrs of reperfusion. After cold-LHX, IL-6 levels were significantly lower than after warm-LHX and control-LHX until 6 hrs of reperfusion. Bars represent mean \pm SEM.

* Significantly different from pigs after cold-LHX.

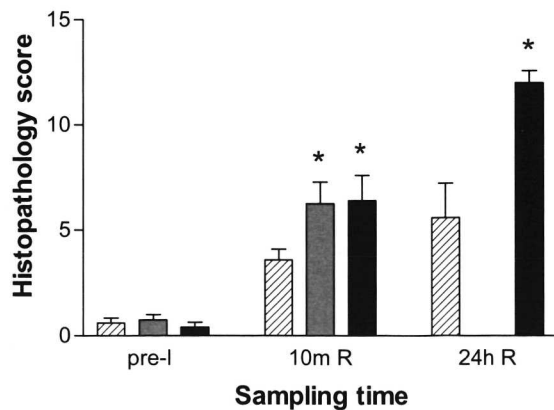
Histopathology

Microscopic evaluation of liver biopsies of all pigs showed a significant increase in histopathology score after 10 min of reperfusion when compared to pre-ischemia. The score in pigs after cold-LHX was significantly lower when compared to pigs after warm-LHX and control-LHX after 10 min of reperfusion. After 24 hrs of reperfusion, pigs in both the cold-LHX and the control-LHX group showed more pathologic changes when compared to 10 min of reperfusion although statistical significance was not reached ($p=0.25$ and $p=0.05$ resp.). The histopathological scores in biopsies collected at 24 hrs of reperfusion were significantly higher in pigs after control-LHX than after cold-LHX (figure 8). Histopathological scores in the warm-LHX group are lacking because there were no survivors in this group after 24 hrs of reperfusion.

Figure 8

Histopathology scores (min=0, max=18) of H&E stained liver sections of pigs after cold-LHX (dashed bar, n=5), warm-LHX (grey bar, n=5) and control-LHX (closed bar, n=5) at pre-ischemia and after 10 min as well as 24 hrs of reperfusion. After cold-LHX, histopathology scores were significantly lower than after warm-LHX and control-LHX. Bars represent mean \pm SEM.

* Significantly different from pigs after cold-LHX.



Discussion

Various vascular occlusion techniques have been used to prevent massive blood loss during partial hepatectomy. Portal triad clamping (Pringle maneuver) and THVE are two methods to reduce hemorrhage during parenchymal dissection. Although hemorrhage can be more effectively reduced during partial hepatectomy under THVE, there is evidence that by applying this technique, liver tissue oxygenation is further hampered due to the lack of back-perfusion from the caval vein thereby enhancing I/R injury^{30,31}. This finding underscores the use of protective measures when applying THVE, such as *in situ* hypothermic perfusion of the future remnant liver.

The objective of this study was to examine whether *in situ* hypothermic perfusion is a useful tool to attenuate liver I/R injury and to investigate if this protective effect resulted from clearance of the liver from blood or to cooling of the liver per se. Cooling of the organ leads to a decrease in cell metabolism, as was demonstrated by a reduction in the velocity of various organic reactions by a factor 2 for every 10°C reduction in temperature³². This results in a decrease in hepatic oxygen demand and uptake and thus provides an effective protection from hepatic oxygen deprivation thereby reducing reperfusion injury³³. In literature, a major role is attributed to the formation of reactive oxygen species during reperfusion³⁴⁻³⁶, which is attenuated by cooling of the organ. Other mechanistic factors, like maintenance of mitochondrial function by preventing calcium overload³⁷, suppression of nitric oxide formation³⁸ or preservation of important intracellular concentrations of metabolites are also shown to play a role in temperature related I/R injury. This study showed that clearance of the liver from blood without concomitant cooling severely aggravates liver I/R injury. The use of Ringer-glucose as perfusion fluid has several implications for the observed outcome in this study. Although the Ringer-glucose solution was isotonic, the lack of proteins and the acidotic pH (4.65) probably enhanced endothelial cell swelling at normothermic temperatures, leading to microvascular disturbances and ultimately enhanced liver injury during reperfusion³⁹. This explanation is corroborated by the extensive congestion of the liver observed at the onset of reperfusion in pigs of the warm perfused group.

In the present study, a decrease in core liver temperature of 10°C was chosen to investigate if hepatocytes could be protected from I/R injury at this temperature without hampering sinusoidal endothelial cell (SEC) function. Preserved hyaluronic acid (HA) uptake capacity after 24 hrs of reperfusion indicates that a drop of 10°C in liver core temperature did not affect SEC function. In fact, SEC still had a high reserve capacity for HA uptake after left

hemihepatectomy which is in agreement with previous experiments performed in our laboratory

29

This pig liver I/R model constitutes a clinically relevant, large animal model, but at the same time has its limitations. Relatively long THVE times were used in this protocol for optimal investigation of the protective effect of in situ cooling on liver I/R injury. A THVE time of 2 hrs results in sub-lethal liver failure, indicated by the survival of only 3 out of 5 pigs in the control-LHX group during 24 hrs of reperfusion. If circulatory support by infusion of phenylephrine was not provided in the control-LHX group, all pigs would have died during the 24 hrs of reperfusion period and a statistical significant difference with the cold-LHX group would have been easily reached. Pigs in the cold-LHX group did not require phenylephrine infusion. Whereas plasma AST levels in pigs in the cold-LHX group reached maximum levels after 6 hrs of reperfusion, AST levels in pigs in the control-LHX group continued to increase during the 24 hrs of reperfusion period. This indicates that only pigs in the cold-LHX group showed recovery from the sustained hepatic I/R injury.

In humans, an ICG clearance in livers of >90% is considered normal. In this study, ICG clearance in all pigs before induction of ischemia was 89.9 ± 1.01 (mean \pm SEM), which is comparable to the human situation. In literature, a correlation was observed between ICG clearance and functional liver mass⁴⁰. In this study however, no differences were observed between ICG clearance in pigs of the cold-LHX group before and after partial liver resection, indicating an ample reserve capacity of the liver for ICG clearance. Pigs after warm-LHX and control-LHX, however, showed clearance rates of <70%, compatible with severely impaired liver function.

Use of THVE can cause serious side effects like hemodynamic instability⁴¹. Because portosystemic collateral circulation is poorly developed in pigs, portal venous drainage is mandatory under THVE^{31,42}. In humans, however, collateral circulation of the portal venous system is better developed and therefore, a portal venous shunt is usually not required. Sustained hypotension by test clamping prior to resection¹, indicates the need for a venovenous bypass during THVE of which several systems have been described, both passive⁴³ and active^{12,31,33}. Usually in these cases, systemic heparinisation is required to minimize the risk of intra-shunt clotting, thereby increasing the risk of uncontrolled hemorrhage. In the present experiments, a custom made, stiff polycarbonate intraluminal prosthesis with one side-port was used to bypass blood from the infrahepatic caval vein to the suprahepatic caval vein while at the same time draining the portal venous system. Intra-shunt clotting was not observed and systemic

heparinisation or local use of heparin was not required, which can be a major advantage during these operative procedures.

Several methods have been described for *in situ* cooling of the liver. Yang-IL et al. used simple *in situ* cooling by rapid infusion of chilled 450 ml Ringer-lactate before clamping of the portal triad (Pringle maneuver). In their study, hypothermia of the liver lasted about one hour and no concomitant depression in body temperature was observed⁴⁴. These findings, however, could not be reproduced in our laboratory in which liver temperature in pigs could not be significantly reduced by rapid cold infusion without a concomitant decrease in body temperature (data not shown). Cooling of the liver can be achieved by infusion of different fluids via the hepatic artery^{11:12} or portal vein⁴³, or via both at the same time¹⁰. Alternatively, topical surface cooling during partial hepatectomy can be used^{45:46}. It is not yet known which perfusion method is most effective, although our study shows that perfusion via the hepatic artery alone provides sufficient cooling of the liver.

In conclusion, a mild decrease in core liver temperature with 10°C by *in situ* hypothermic perfusion proved effective in attenuating liver I/R injury as demonstrated by improved hepatocellular function, preservation of SEC function, less histopathological damage, decreased systemic inflammatory response and increased survival in this pig model. Clearance of the liver from blood using Ringer-glucose without concomitant cooling severely aggravated I/R injury.

References

1. Delva E, Camus,Y, Nordlinger,B, Hannoun,L, Parc,R, Deriaz,H, Lienhart,A, Huguet,C. Vascular occlusions for liver resections. Operative management and tolerance to hepatic ischemia: 142 cases. *Ann Surg* 1989;209:211-218.
2. Huguet C, Gavelli,A, Chieco,PA, Bona,S, Harb,J, Joseph,JM, Jobard,J, Gramaglia,M, Lasserre,M. Liver ischemia for hepatic resection: where is the limit? *Surgery* 1992;111:251-259.
3. Man K, Fan,ST, Ng,IO, Lo,CM, Liu,CL, Wong,J. Prospective evaluation of Pringle maneuver in hepatectomy for liver tumors by a randomized study. *Ann Surg* 1997;226:704-711.
4. Huguet C, Nordlinger,B, Galopin,JJ, Bloch,P, Gallot,D. Normothermic hepatic vascular exclusion for extensive hepatectomy. *Surg Gynecol Obstet* 1978;147:689-693.
5. Bismuth H, Castaing,D, Garden,OJ. Major hepatic resection under total vascular exclusion. *Ann Surg* 1989;210:13-19.
6. Jaeschke H. Mechanisms of reperfusion injury after warm ischemia of the liver. *J Hepatobiliary Pancreat Surg* 1998;5:402-408.
7. Huguet C, Gavelli,A, Bona,S. Hepatic resection with ischemia of the liver exceeding one hour. *J Am Coll Surg* 1994;178:454-458.
8. Neuhaus P, Jonas,S, Bechstein,WO, Lohmann,R, Radke,C, Kling,N, Wex,C, Lobeck,H, Hintze,R. Extended resections for hilar cholangiocarcinoma. *Ann Surg* 1999;230:808-818.
9. Hannoun L, Ballardur,P, Delva,E, Panis,Y, Camus,Y, Honiger,J, Levy,E, Parc,R. ["Ex situ-in vivo" surgery of the liver: a new technique in liver surgery. Principles and preliminary results]. *Gastroenterol Clin Biol* 1991;15:758-761.
10. Fortner JG, Shiu,MH, Kinne,DW, Kim,DK, Castro,EB, Watson,RC, Howland,WS, Beattie,EJ, Jr. Major hepatic resection using vascular isolation and hypothermic perfusion. *Ann Surg* 1974;180:644-652.
11. Hannoun L, Delriviere,L, gibbs,P, Borie,D, Vaillant,JC, Delva,E. Major extended hepatic resections in diseased livers using hypothermic protection: preliminary results from the first 12 patients treated with this new technique. *J Am Coll Surg* 1996;183:597-605.
12. Vaillant JC, Borie,DC, Hannoun,L. Hepatectomy with hypothermic perfusion of the liver. *Hepatogastroenterology* 1998;45:381-388.
13. Ikeda T, Yanaga,K, Kishikawa,K, Kakizoe,S, Shimada,M, Sugimachi,K. Ischemic injury in liver transplantation: difference in injury sites between warm and cold ischemia in rats. *Hepatology* 1992;16:454-461.
14. Biberthaler P, Luchting,B, Massberg,S, Teupser,D, Langer,S, Leiderer,R, Messmer,K, Krombach,F. THE INFLUENCE OF ORGAN TEMPERATURE ON HEPATIC ISCHEMIA-REPERFUSION INJURY: A Systematic Analysis1. *Transplantation* 2001;72:1486-1490.

15. van Wagenveld BA, van Gulik,TM, Gelderblom,HC, Scheepers,JJ, Bosma,A, Endert,E, Gouma,DJ. Prolonged continuous or intermittent vascular inflow occlusion during hemihepatectomy in pigs. *Ann Surg* 1999;229:376-384.
16. Bowers BA, Branum,GD, Rotolo,FS, Watters,CR, Meyers,WC. Bile flow--an index of ischemic injury. *J Surg Res* 1987;42:565-569.
17. El Desoky A, Seifalian,AM, Cope,M, Delpy,DT, Davidson,BR. Experimental study of liver dysfunction evaluated by direct indocyanine green clearance using near infrared spectroscopy. *Br J Surg* 1999;86:1005-1011.
18. Lau H, Man,K, Fan,ST, Yu,WC, Lo,CM, Wong,J. Evaluation of preoperative hepatic function in patients with hepatocellular carcinoma undergoing hepatectomy. *Br J Surg* 1997;84:1255-1259.
19. Hemming AW, Scudamore,CH, Shackleton,CR, Pudek,M, Erb, SR. Indocyanine green clearance as a predictor of successful hepatic resection in cirrhotic patients. *Am J Surg* 1992;163:515-518.
20. Gottlieb ME, Stratton,HH, Newell,JC, Shah,DM. Indocyanine green. Its use as an early indicator of hepatic dysfunction following injury in man. *Arch Surg* 1984;119:264-268.
21. Tsubono T, Todo,S, Jabbour,N, Mizoe,A, Warty,V, Demetris,AJ, Starzl,TE. Indocyanine green elimination test in orthotopic liver recipients. *Hepatology* 1996;24:1165-1171.
22. Tamaki S, Ueno,T, Torimura,T, Sata,M, Tanikawa,K. Evaluation of hyaluronic acid binding ability of hepatic sinusoidal endothelial cells in rats with liver cirrhosis. *Gastroenterology* 1996;111:1049-1057.
23. Deaciuc IV, Bagby,GJ, Lang,CH, Spitzer,JJ. Hyaluronic acid uptake by the isolated, perfused rat liver: an index of hepatic sinusoidal endothelial cell function. *Hepatology* 1993;17:266-272.
24. Reinders ME, van Wagenveld,BA, van Gulik,TM, Frederiks,WM, Chamuleau,RAFM, Enderd,E, Klopper,PJ. Hyaluronic acid uptake in the assessment of sinusoidal endothelial cell damage after cold storage and normothermic reperfusion of rat livers. *Transpl Int* 1996;9:446-453.
25. Namekata K, Takamori,S, Kojima,K, Beppu,T, Futagawa,S. Significant changes in the serum levels of IL-6, h-HGF, and type IV collagen 7S during the perioperative period of a hepatectomy: relevance to SIRS. *Surg Today* 2000;30:403-409.
26. Fattori E, Cappelletti,M, Costa,P, Sellitto,C, Cantoni,L, Carelli,M, Faggioni,R, Fantuzzi,G, Ghezzi,P, Poli,V. Defective inflammatory response in interleukin 6-deficient mice. *J Exp Med* 1994;180:1243-1250.
27. Ohzato H, Yoshizaki,K, Nishimoto,N, Ogata,A, Tagoh,H, Monden,M, Gotoh,M, Kishimoto,T, Mori,T. Interleukin-6 as a new indicator of inflammatory status: detection of serum levels of interleukin-6 and C-reactive protein after surgery. *Surgery* 1992;111:201-209.
28. Helle M, Boeijs,L, Aarden,LA. Functional discrimination between interleukin 6 and interleukin 1. *Eur J Immunol* 1988;18:1535-1540.

29. van Wagenveld BA, van Gulik, TM, Gelderblom, HC, Scheepers, JJ, Bosma, A, Endert, E, Obertop, H, Gouma, DJ. Continuous or intermittent vascular clamping during hemihepatectomy in pigs: hyaluronic acid kinetics in the assessment of early microvascular liver damage. *Eur J Surg* 2000;166:255-261.
30. Tatsuma T, Kim, YI, Kai, T, Ishii, T, Akizuki, S, Takayama, F, Egashira, T, Kobayashi, M. Importance of hepatovenous back-perfusion for maintenance of liver viability during the Pringle manoeuvre. *Br J Surg* 1995;82:1071-1075.
31. Hiratsuka K, Kim, YI, Nakashima, K, Kawano, K, Yoshida, T, Kitano, S. Tissue oxygen pressure during prolonged ischemia of the liver. *J Surg Res* 2000;92:250-254.
32. Belzer FO, Southard, JH. Principles of solid-organ preservation by cold storage. [Review] [27 refs]. *Transplantation* 1988;45:673-676.
33. Nagano K, Gelman, S, Bradley, EL, Jr., Parks, D. Hypothermia, hepatic oxygen supply-demand, and ischemia-reperfusion injury in pigs. *Am J Physiol* 1990;258:G910-8.
34. Zar HA, Tanigawa, K, Kim, YM, Lancaster, JR, Jr. Mild therapeutic hypothermia for postischemic vasoconstriction in the perfused rat liver. *Anesthesiology* 1999;90:1103-1111.
35. Karibe H, Chen, SF, Zarow, GJ, Gafni, J, Graham, SH, Chan, PH, Weinstein, PR. Mild intraischemic hypothermia suppresses consumption of endogenous antioxidants after temporary focal ischemia in rats. *Brain Res* 1994;649:12-18.
36. Globus MY, Busto, R, Lin, B, Schnippering, H, Ginsberg, MD. Detection of free radical activity during transient global ischemia and recirculation: effects of intraischemic brain temperature modulation. *J Neurochem* 1995;65:1250-1256.
37. Ferrari R, Raddino, R, Di Lisa, F, Ceconi, C, Curello, S, Albertini, A, Nayler, W. Effects of temperature on myocardial calcium homeostasis and mitochondrial function during ischemia and reperfusion. *J Thorac Cardiovasc Surg* 1990;99:919-928.
38. Kumura E, Yoshimine, T, Takaoka, M, Hayakawa, T, Shiga, T, Kosaka, H. Hypothermia suppresses nitric oxide elevation during reperfusion after focal cerebral ischemia in rats. *Neurosci Lett* 1996;220:45-48.
39. Mazzoni MC, Borgstrom, P, Warnke, KC, Skalak, TC, Intaglietta, M, Arfors, KE. Mechanisms and implications of capillary endothelial swelling and luminal narrowing in low-flow ischemias. *Int J Microcirc Clin Exp* 1995;15:265-270.
40. Bolognesi M, Merkel, C, Angeli, P, Caregaro, L, Gatta, A. [Liver metabolism of indocyanine green and aminopyrine in liver cirrhosis: relations with functioning liver cell mass]. *Minerva Med* 1988;79:1035-1041.
41. Belghiti J, Noun, R, Zante, E, Ballet, T, Sauvanet, A. Portal triad clamping or hepatic vascular exclusion for major liver resection. A controlled study. *Ann Surg* 1996;224:155-161.
42. van Wagenveld BA, van Gulik, TM, Gabeler, EE, van der kleij, AJ, Obertop, H, Gouma, DJ. Intrahepatic tissue pO₂ during continuous or intermittent vascular inflow occlusion in a pig liver resection model. *Eur Surg Res* 1998;30:13-25.

43. Takeuchi K, Ohira,M, Yamashita,T, Sowa,M. An experimental study of hepatic resection using an in situ hypothermic perfusion technique. *Hepatogastroenterology* 1997;44:1281-1294.
44. Kim YI, Hiratsuka,K, Kitano,S, Joo,DH, Kamada,N, Sugimachi,K. Simple in situ hypothermia reduced ischaemic injury to human liver during hepatectomy. *Eur J Surg* 1996;162:717-721.
45. Yamanaka N, Okamoto,E. [Topical cooling as an adjunct for hepatectomy with inflow occlusion]. *Nippon Geka Gakkai Zasshi* 1998;99:223-228.
46. Imakita M, Yamanaka,N, Kuroda,N, Kitayama,Y, Okamoto,E. Does topical cooling alleviate ischemia/reperfusion injury during inflow occlusion in hepatectomy? Results of an experimental and clinical study [In Process Citation]. *Surg Today* 2000;30:795-804.