



## UvA-DARE (Digital Academic Repository)

### The acute first-time anterior shoulder dislocation (AFASD)

te Slaa, R.L.

**Publication date**  
2003

[Link to publication](#)

#### **Citation for published version (APA):**

te Slaa, R. L. (2003). *The acute first-time anterior shoulder dislocation (AFASD)*. [Thesis, externally prepared, Universiteit van Amsterdam].

#### **General rights**

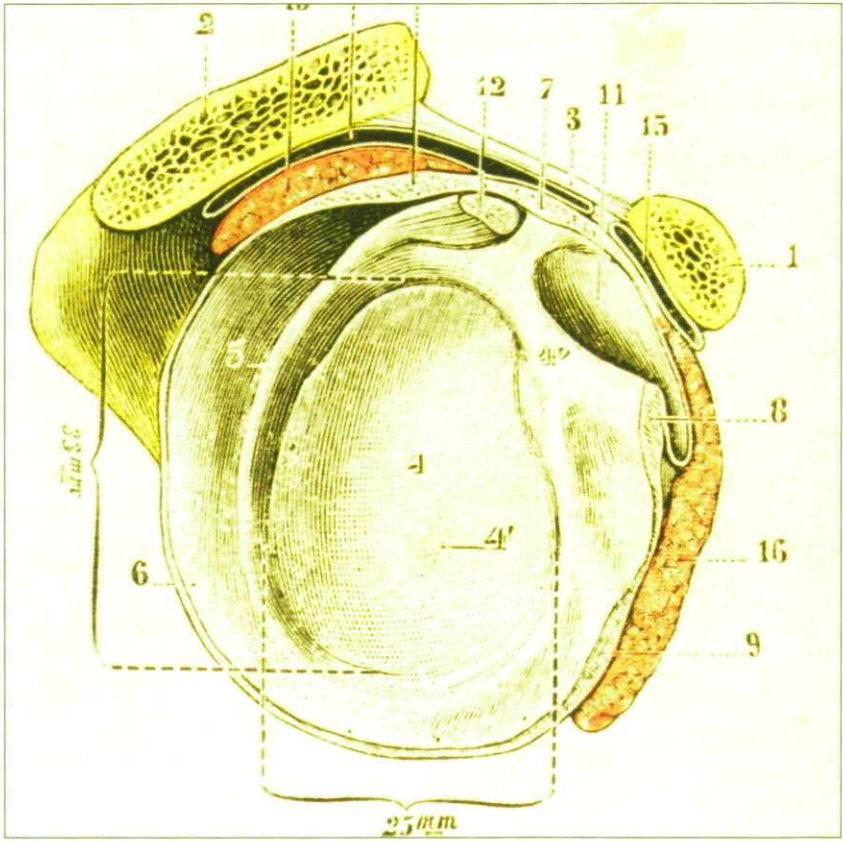
It is not permitted to download or to forward/distribute the text or part of it without the consent of the author(s) and/or copyright holder(s), other than for strictly personal, individual use, unless the work is under an open content license (like Creative Commons).

#### **Disclaimer/Complaints regulations**

If you believe that digital publication of certain material infringes any of your rights or (privacy) interests, please let the Library know, stating your reasons. In case of a legitimate complaint, the Library will make the material inaccessible and/or remove it from the website. Please Ask the Library: <https://uba.uva.nl/en/contact>, or a letter to: Library of the University of Amsterdam, Secretariat, Singel 425, 1012 WP Amsterdam, The Netherlands. You will be contacted as soon as possible.

# Chapter 15

Publications of the author / Illustrations





## Shoulder

### **Te Slaa RL, Nollen AJG.**

A Salter type 3 fracture of the proximal epiphysis of the humerus.  
Injury. The British Journal of Accident Surgery. 1987 Nov; 18 (6):429-31.

### **Te Slaa RL, Lim TE, Nollen AJG.**

Anterior subluxation of the shoulder. (De anterieure subluxatie van de schouder. (KL)).  
Ned. Tijdschr. Geneesk. 1989; 133 (40):1961-5.

### **Lansberg PJ, Te Slaa RL.**

Stijging van aantal schouderaanandoeningen, een 'teken des tijd'.  
Boerhaave magazine 1990 Sept; 45.

### **Te Slaa RL, Lim TE.**

Biceps tendon rupture (Bicepspeesrupturen).  
Ned. Tijdsch. Geneesk. 1990; 134 (41):2015.

### **Te Slaa RL.**

Schouderinstabiliteit.  
Schouderaanandoeningen in de huisartsenpraktijk en de orthopaedisch chirurgische benadering.  
PAOG Boerhaave. 1990 Nov; 49-68. (ISBN 9067672017)

### **Te Slaa RL.**

Schouder special: IVth congres SECEC Milaan  
Reuma & Trauma 1991 May; 70-71.

### **Te Slaa RL, Lim TE.**

Multi-directional instability of the shoulder. (Multidirectionele instabiliteit van de schouder: een nieuwe vorm van chronische schouderinstabiliteit.)  
Ned. Tijdsch. Geneesk. 1992 Aug; 136(32):1560-3.

### **Ritt MJPF, Te Slaa RL, Winter LHL, Jansen BRH.**

CT-scan arthrografie en arthroscopie van de schouder. Een prospectief vergelijkend onderzoek.  
Ned. Tijdsch. Traumatologie 1994; Nr. 5:126-30.

### **Van Laarhoven H, Te Slaa RL.**

De achterste schouderluxatie: een vaak gemiste diagnose.  
Modern Medicine 1994; Nr. 11:813-7.

**Ritt MJPF, Te Slaa RL, Winter LHL, Jansen BRH.**

CT-scan arthrografie en arthroscopie van de schouder een prospectief vergelijkend onderzoek. Medisch Journaal Delft ,jaargang 7, maart 1995, no 1:10-2

**Van Laarhoven H, Te Slaa RL, Van Laarhoven EW.**

Isolated avulsion fracture of the lesser tuberosity of the humerus. J. Trauma. 1995 Nov; 39(5):997-9.

**Van Noort A, te Slaa RL, Marti RK, Van der Werken C.**

The floating shoulder. A multicentre study. J. Bone Joint Surg. Br. 2001 Aug; 83(6):795-8.

**Te Slaa RL, Verburg H, Marti RK.**

Fracture of the coracoid process, the greater tuberosity and the glenoid rim after acute first-time anterior shoulder dislocation. J. Shoulder Elbow Surg 2001 Sep-Oct; 10(5):489-92.

**Te Slaa RL, Wijffels MPJM, Brand R, Marti RK.**

A prospective arthroscopic study of acute first-time anterior shoulder dislocation in the young. *(Accepted for publication Journal of Shoulder and Elbow Surgery 2002.)*

**Te Slaa RL, Wijffels MPJM, Marti RK.**

Questionnaire reveals variations in management of acute first-time shoulder dislocations in the Netherlands. European Journal of Emergency Medicine 2003 March; 10(1): 58-61

**Te Slaa RL, Uitterlinden EJ , Marti RK, Rozing P.**

Systemic review on reduction techniques of acute first-time anterior shoulder dislocations. *(Submitted to Journal of Shoulder and Elbow Surgery, 2002)*

**Te Slaa RL, Wijffels MPJM, Marti RK.**

Evaluation of radiographs in first-time anterior shoulder dislocations. *(Submitted to European Journal of Emergency Medicine, 2003)*

**Te Slaa RL, Wijffels MPJM, Brand R, Marti RK.**

Prognosis of the acute first-time anterior shoulder dislocation. A Dutch experience. *(Resubmitted (in shorter version) to Journal of Bone and Joint Surgery (British), 2003)*

## **General orthopaedics and traumatology**

**Te Slaa RL, Faber FWM, Nollen AJG, Van Straaten TJ.**

Supracondylar fractures of the humerus in children; a long-term followup study.  
Neth. J. Surg. 1988 Jun; 40(4):100-3

**Te Slaa RL, Lim TE, Van der Hoeven H.**

Hoe meet men nauwkeurig de beenlengte van een patiënt en wat zijn de medische consequenties van beenlengteverschillen? Vademecum permanente nascholing huisartsen. Aug.1988.

**Looij BJ, Te Slaa RL, Hogewind BL, Van de Kamp JJP.**

Genetic counseling in hereditary osteoonychodysplasia (HOOD, nail patellasyndrome)  
Med. Genet.1988 Oct; 25(10): 682-6.

**Te Slaa RL, Looij BJ, Nollen AJG, Lommen EJP.**

Hereditary onycho-osteodysplasia (HOOD) De hereditaire onychoosteodysplasie.  
Tijdschr. Kindergeneesk. Themanummer: Orthopaedie 1988; 56(6): 298-303.

**Te Slaa RL, Kortbeek LHTS, Nollen AJG, Van Straaten TJ, Winkelman PAM.**

De traumatische atlantooccipitale dislocatie.  
Medisch Journaal 1988; Nr. 4, 237-40.

**Lommen EJP, Hamel BCJ, te Slaa RL.**

Nephropathy in hereditary osteoonycho dysplasie (HOOD) Genetics of Kidney disorders  
Prog. Clinic. Biolog. 1989; 305:157-60. ISBN ( 0-8451-5155-X.)

**Van der Hoeven H, te Slaa RL, Keessen W, Kuis W, Van der Net J.**

Wrist disorders in juvenile chronic arthritis. Polsafwijkingen bij juveniele chronische artritis.  
Ned. Tijdsch.Geneeskd.1990; 134(47):2284-9.

**Te Slaa R, Lim TE, Van der Hoeven H.**

Beenlengteverschillen. Vademecum Voeten en Schoeisel. Jaargang 1, Nr.4, 1990 .

**Faber FWM, Te Slaa RL, Nollen AJG.**

Pain in the forefoot: a support is no panacea. (Pijn in de voorvoet: een steunzool is geen panacee). Ned. Tijdsch. Geneeskd 1992 Oct; 136(41):2029-32.

**Ritt MPJF, Te Slaa RL, Koning J, Bruyn JD.**

Popliteal Pseudoaneurysm after arthroscopic menisectomy.  
Clinical Orthopedics and related research 1993; 295:198-200.

**Te Slaa RL.**

Glinsterende oogjes.

“Zeg luister es”, Liber amicorum Dr. C.A. Broodman.

Publ. Meidema, Delft, 1993. ( ISBN 9037104673 )

**Van Alphen JC, Te Slaa RL, Eulderink F, Oberman WR.**

Solitary osteochondroma of the scaphoid: a case report.

J. Hand Surg 1996 May; 21(3):423-5.

**Polak A, Te Slaa RL, Jansen BRH.**

Treatment of a trochanteric femoral fracture with Joanknecht tube prosthesis in situ.

A technical report on two cases.

Problem solving in Traumatology 1999. (ISBN 9058050254)

**Te Slaa RL, Jansen BRH.**

Avulsie van de spina iliaca anterior inferior met grote gevolgen.

Sporttraumatologie Nov. 2000; (15):56-8. (ISBN 9064648204)

**Te Slaa RL, de Klerk LWL, Mostert AK.**

Bilaterale patellapeesruptuur bij een handballer.

Sporttraumatologie Nov. 2000; (26):91-3. (ISBN 9064648204)

**Mostert AK, Te Slaa RL.**

De bilaterale idiopathische patella peesrupturen.

Ned. Tijdschrift Orthopedie Mei 2000; 12-5.

**Bramer JAM, Maas M, Te Slaa RL, Dallinga RJ, Vergroesen D.**

Increased external tibial torsion and osteochondritis dissecans of the knee.

Clinical orthopaedics and related research 2003

*(Resubmitted for acceptance)*

## Illustrations

- Cover Front: Anatomical view of shoulder with Perthes – Bankart lesion. Testut L. Traite d'anatomie humaine. Sixieme edition. Octave Doin et ils, Editeurs, Paris 1911. Tome premier. pp.507-523
- Contents : Anatomical view of shoulder with ligaments. Testut L. Jacob O. Traite d'anatomie topograhique avec appllications medico-chirurgicales. Diexieme edition. Octave Doin et fils, Editeurs, Paris 1909. Tome second. pp.693.
- Chapter 1: Reduction of a dislocated shoulder over the operator's shoulder. From the Venice edition of Galen, 1625 Brockbank W, Griffiths D.L.L. J Bone Joint Surg 1948 may; 30(2): 365-75.
- Chapter 2: Reduction of a dislocated shoulder over rang of a ladder. From Vidus Vidius: Chirurgia Paris, 1544 Brockbank W, Griffiths D.L.L. J Bone Joint Surg 1948 may; 30(2): 365-75.
- Chapter 3: Reduction of a dislocated shoulder over a wooden yoke  
From Paré A, 1678 Brockbank W, Griffiths D.L.L. J Bone Joint Surg 1948 may; 30(2): 365-75.
- Chapter 4: Reduction of a dislocated shoulder over the back of a chair. From A.L. Richter Handbuche der Lehre von den Bruchen und verrenkungen der knochen, Berlin 1828. H.Goerke. Medizin und Technik. Afb. 215
- Chapter 5: Reduction of a dislocated shoulder over the operator's shoulder. The story of orthopaedics. Mercer Rang. W.B. Saunders Company.
- Chapter 6: Reduction of a dislocated shoulder over a cross-beam. (From A.L. Richter Handbuche der Lehre von den Bruchen und verrenkungen der knochen, Berlin 1828.) H.Goerke. Medizin und Technik. Afb. 214.



- Chapter 7: Renaissance representation of the reduction of a dislocated shoulder, according to Hippocrates. (From Francesco Rossi 1500-1569) R. Töllner. *Illustrierte Geschichte der Medizin*. 1612.
- Chapter 8: Radiograph of right shoulder following reduction of a dislocated shoulder. The Hill-Sachs lesion is visible.
- Chapter 9: Arthroscopic view of right shoulder of patient with AFASD.
- Chapter 10: Hippocratic reduction of a dislocated shoulder with the operator's foot in the axilla and the assistant applying counter traction. (From english translation of Paré 's work,1678. *Vidus Vidius Chirurgia é Graeco in Latinum Conversa*, 1544) *History of Orthopaedics*. 1980; 22 -23.
- Chapter 11: Computer- tomograph slide of shoulder following AFASD with a fracture of coracoid process, greater tuberosity and glenoid rim.
- Chapter 12: Reduction of a dislocated shoulde with the use of the rack.(From Vidus Vidius: *Chirurgia Paris*, 1544) Brockbank W, Griffiths D.L.L. *J Bone Joint Surg* 1948 may; 30(2):365-75.
- Chapter 13: Reduction of a dislocated shoulder over a split – door. (From *Chirurgie Francaise Jacques Daléchamps*, Lyon 1569.)R. Töllner. *Illustrierte Geschichte der Medizin*. 1679.
- Chapter 14: Immobilisation of right shoulder following AFASD.
- Chapter 15: Anatomical view of shoulder with labrum and ligaments.Testut L. Jacob O. *Traite d'anatomie topograhique avec appllications medico chirurgicales*. Deuxieme edition. Octave Doin et fils, Editeurs, Paris 1909.Tome second. p.693.

The author is indebted to the following authors and publishers and publications to reproduce text and illustrations. Every effort has been made to identify material covered by copyright. The author regrets any oversights.

American Journal of Sportsmedicine

The British editorial society of Bone and Joint Surgery

The Physician and Sportsmedicine:

Lippincott Williams & Wilkins

Royal College of Surgeons of Edinburgh

Champ Baker (illustrations)

Bob Griffioen (illustrations)

Lennart Hovelius (illustrations)

Anthony Mattick (illustrations)

Jaap Willems (illustrations)

**Baker CL, Uribe JW, Whitman C.** Arthroscopic evaluation of acute initial anterior shoulder dislocations. *Am J Sportsmed* 1990; 18:25-8.

**Brockbank W, Griffiths D.L.** Orthopaedic surgery in the sixteenth and seventeenth centuries. *J Bone Joint Surg [Br]* 1948 may; 30-B: 365-75.

**Hussein MK.** Kocher's method is 3000 years old; *J Bone Joint Surg [Br]* 1968 50-B: 669-71.

**Mattick A, Wyatt JP.** From Hippocrates to the Eskimo—a history of techniques used to reduce anterior dislocation of the shoulder. *J R Coll Surg Edinb* 2000 Oct; 45(5): 312-6.

**Joy EA:** J Self-reduction of anterior shoulder dislocation *Phys Sportsmed* 2000; 28(11): 65-6.

**S. Poulsen:** Reduction of acute shoulder dislocation using the eskimo technique.

*J of Trauma* 1988; Vol 28:1382

