



UvA-DARE (Digital Academic Repository)

Veno-occlusive disease of the liver in children treated for Wilms tumor

Bisogno, G.; de Kraker, J.; Weirich, A.; Masiero, L.; Ludwig, R.; Tournade, M-F.; Carli, M.

DOI

[10.1002/\(SICI\)1096-911X\(199710\)29:4<245::AID-MPO2>3.0.CO;2-M](https://doi.org/10.1002/(SICI)1096-911X(199710)29:4<245::AID-MPO2>3.0.CO;2-M)

Publication date

1997

Published in

Medical and Pediatric Oncology

[Link to publication](#)

Citation for published version (APA):

Bisogno, G., de Kraker, J., Weirich, A., Masiero, L., Ludwig, R., Tournade, M-F., & Carli, M. (1997). Veno-occlusive disease of the liver in children treated for Wilms tumor. *Medical and Pediatric Oncology*, 29, 245-251. [https://doi.org/10.1002/\(SICI\)1096-911X\(199710\)29:4<245::AID-MPO2>3.0.CO;2-M](https://doi.org/10.1002/(SICI)1096-911X(199710)29:4<245::AID-MPO2>3.0.CO;2-M)

General rights

It is not permitted to download or to forward/distribute the text or part of it without the consent of the author(s) and/or copyright holder(s), other than for strictly personal, individual use, unless the work is under an open content license (like Creative Commons).

Disclaimer/Complaints regulations

If you believe that digital publication of certain material infringes any of your rights or (privacy) interests, please let the Library know, stating your reasons. In case of a legitimate complaint, the Library will make the material inaccessible and/or remove it from the website. Please Ask the Library: <https://uba.uva.nl/en/contact>, or a letter to: Library of the University of Amsterdam, Secretariat, Singel 425, 1012 WP Amsterdam, The Netherlands. You will be contacted as soon as possible.

Veno-Occlusive Disease of the Liver in Children Treated for Wilms Tumor

Gianni Bisogno, MD,^{1*} Jan de Kraker, MD,² Angela Weirich, MD,³
Lucia Masiero, PhD,¹ Rolf Ludwig, MD,³ Marie France Tournade, MD,⁴ and
Modesto Carli, MD¹

Introduction. Hepatotoxicity consistent with the clinical diagnosis of veno-occlusive disease (VOD) of the liver has been suspected after conventional anti-cancer chemotherapy in children.

Methods. To establish the incidence of hepatotoxicity and its relationship with VOD, we analyzed toxicity data obtained on 511 children affected by Wilms tumor and treated according to the SIOP-9 protocol. They all received pre- and postnephrectomy chemotherapy using dactinomycin (AD) and vincristine (VCR) ± other drugs ± radiotherapy according to surgical stage and histology.

Results. Sixty-four patients suffered at least one episode of hepatotoxicity and 41 satisfied the criteria for a clinical diagnosis of VOD. In this latter group, toxicity occurred during pre-operative treatment in 15 patients and was confirmed histopathologically in 9 of the 16 liver biopsies obtained. There was a higher percentage of children aged less than 1 year at diagnosis in the VOD group than in the other pa-

tients (24% vs. 11.4%). The degree of liver damage in the younger patients seems important, as suggested by a higher increase in transaminases. VOD developed in 12% of the 68 irradiated children vs. 7% in the non-irradiated group. Statistical analysis showed an increased risk of VOD in younger patients ($p < 0.001$) and in those receiving radiotherapy ($p < 0.001$). All patients recovered after 6–180 days using supportive therapy only.

Conclusions. (1) 8% of children treated according to the SIOP-9 protocol, developed hepatotoxicity consistent with VOD. Excluding patients who received radiotherapy, the incidence was 6%. These figures are much higher than in earlier reports, though different diagnostic criteria were used. (2) Chemotherapy with AD and VCR seems to be a major cause of VOD. (3) Risk factors are young age and concomitant radiotherapy. (4) VOD does not prejudice positive outcome for these patients. *Med. Pediatr. Oncol.* 29:245–251, 1997.

© 1997 Wiley-Liss, Inc.

Key words: veno-occlusive disease; Wilms tumor; chemotherapy; radiotherapy

INTRODUCTION

Veno-occlusive disease of the liver (VOD) is a well-known complication in patients undergoing high-dose chemotherapy and bone marrow transplantation. The clinical signs of the disease are hepatomegaly, sudden weight gain with or without ascites, and jaundice. In 10–60% of patients it occurs within the first few weeks after transplantation. Pathological examination of affected liver shows obliteration of the small hepatic venules and damage to endothelial cells, sinusoids, and hepatocytes [1].

VOD has also been reported following conventional anti-cancer chemotherapy, with or without abdominal irradiation [2–5], particularly in children treated for Wilms tumor. The diagnosis of such cases has been based mainly on clinical findings, however, without histological confirmation [6–8]. To establish the incidence of hepatotoxicity in Wilms tumor patients, its relationship with VOD and any potential predisposing factors, we analyzed toxicity data obtained on children enrolled in the SIOP-9 nephroblastoma protocol.

PATIENTS AND METHODS

Patients

The SIOP-9 protocol was started in November 1987 and closed in November 1991. The German Pediatric Oncology Group (GPOH) joined in January 1989. Eligibility criteria for randomization in the trial were: (a) age over 6 months or under 16 years, (b) no previous treatment, (c) unilateral tumor presenting with certain clinical and radiological characteristics of nephroblastoma, (d) absence of metastases.

A total of 852 patients (228 from the GPOH) were registered. Three hundred- and forty-one patients were

¹Department of Pediatrics, Oncological Hematology Division, University of Padova, Italy; ²Emma Kinderziekenhuis/Academisch Medical Center, Amsterdam, The Netherlands; ³Kinderklinik, Sektion Hämatologie und Onkologie, University of Heidelberg, Germany; ⁴Institut Gustave Roussy, Villejuif, France.

*Correspondence to: Gianni Bisogno, Dipartimento di Pediatria, Divisione di Oncoematologia, Università di Padova, 35128 Padova, Italy.

Received 1 October 1996; Accepted 27 March 1997

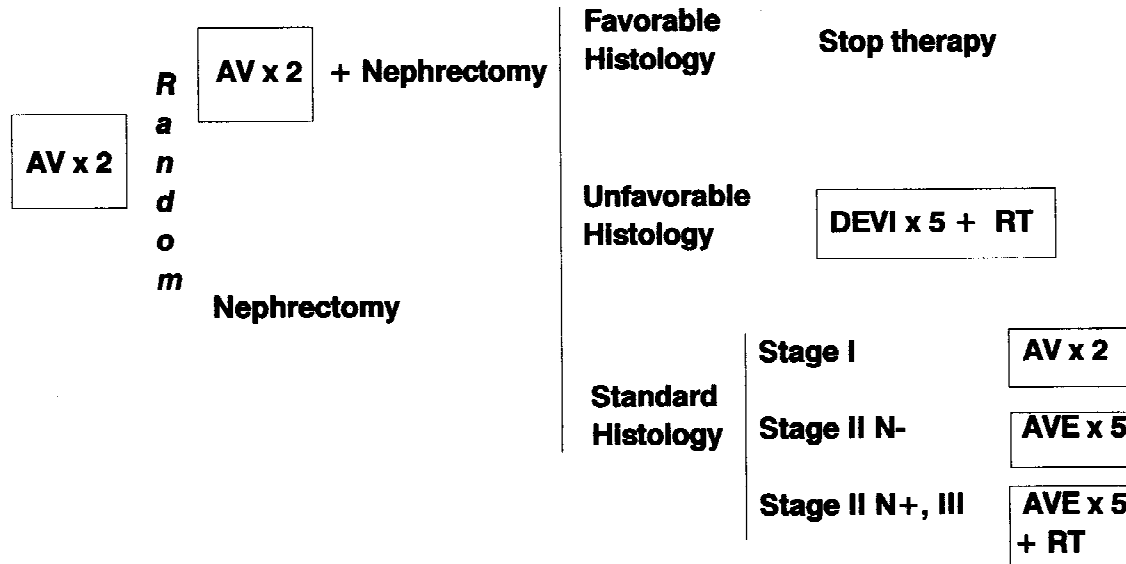


Fig. 1. SIOP PROTOCOL (stage I, II, III): Preoperative chemotherapy: A = dactinomycin 15 µg/kg × 3 days; V = vincristine 1.5 mg/m² × 1 day, weeks 1,2. Postoperative chemotherapy: a) Unfavorable histology: D = dactinomycin 30 µg/kg × 1 day, week 5; E = epirubicin 50 mg/m² × 1 day, week 1, V = vincristine 1.5 mg/m² × 1 day, weeks 1,2,3,5,7; I = ifosfamide 3 g/m² × 2 days, week 3; b) Favorable histology: A = dactinomycin 15 µg/kg × 5 days, week 2; V = vincristine 1.5 mg/m² × 1 day, weeks 1,2,3,4.; E = epirubicin 50 mg/m² × 1 day, week 4. RT = Radiotherapy:15 Gy + boost of 10 to 15 Gy to suspicious areas.

not randomized because they did not fulfill the eligibility criteria. They were therefore classified as “study patients”. Of the patients eligible for the trial, 129 were excluded because of lack of tumor response, significant toxicity or parents’ refusal of the randomization (107), or because they were registered after completion of the randomization (22). The remaining 382 were randomized after 4 weeks of pre-operative chemotherapy to receive another 4 weeks of chemotherapy or nephrectomy.

For the purpose of this review, the 341 “study patients” were not considered because of the variety of clinical characteristics and treatment modalities; the analysis was consequently restricted to the remaining 511 children.

Treatment

The SIOP-9 protocol treatment schedule is shown in Figure 1*. After 4 weeks of pre-operative chemotherapy with vincristine (VCR) and dactinomycin (AD), patients were randomized to undergo nephrectomy or receive another 4 weeks of chemotherapy followed by nephrectomy. Treatment was then stratified by stage and histology according to findings at surgery.

In order to ensure a uniform dosage in the children, the protocol established that the AD dose be calculated according to body surface area. After some cases of unexpected hepatotoxicity arousing the suspicion that AD

might be to blame, the SIOP Committee amended its protocol in April 1989, changing the dose of AD from 0.45 mg/m² to 15 µg/kg. In fact, dose calculations based on body surface area tend to overestimate the dosage in younger children [9].

The Committee also recommended a liver biopsy should be performed at nephrectomy if signs of hepatotoxicity were present, in order to compare the clinical picture with histological findings. Liver function tests were not routinely required, so they were performed on a clinical basis.

Liver Toxicity Study

A computer-based search and a review of the archives were performed to find suspicious episodes of hepatotoxicity on the SIOP-9 files and data sheets. An *ad hoc* questionnaire was sent to the responsible clinician to collect more detailed clinical information on signs, symptoms, laboratory findings (including viral serology), chemotherapy, and follow-up. A copy of the pathological report was obtained if a liver biopsy had been performed. Information regarding use of blood products and type of anesthesia were incomplete so they were not considered in this analysis.

We considered hepatic toxicity as compatible with the clinical diagnosis of VOD when no other causes of liver disease were identified and at least 2 of the following features were present: jaundice, hepatomegaly (≥2 cm below the costal margin), and/or right upper quadrant pain, ascites and/or sudden weight gain (>2% of baseline

*Children under 1 year and/or less than 10 kg in weight were recommended to have 2/3 of the dose of all drugs.

TABLE I. Characteristics of Patients

	No hepatotoxicity (n. 447)	Hepatotoxicity not VOD (n. 23)	VOD (n. 41)
Male	224	16	23
Female	223	7	18
Age (months): range (median)	6–163.7 (41)	10.3–79 (43.5)	6–118 (18.5)
—≤12	51	1	10
—12.1–48	223	12	22
—48.1–72	102	9	5
—>72.1	68	1	4
—unknown	3		
Weight (kg): range (median)	7–62 (15.5)	11–23 (15)	8–33 (12)
—≤10	78	2	10
—10.1–15	146	11	18
—15.1–20	131	7	7
—>20	76	3	6
—unknown	16		
Body Surface (m ²): range (median)	0.35–1.7 (0.6)	0.45–0.84 (0.69)	0.37–1.1 (0.5)
—≤0.4	39	0	5
—0.41–0.6	159	10	20
—0.61–0.8	157	10	9
—>0.81	70	3	5
—unknown	22		2
Stage			
—I	277	8	21
—II	118	9	9
—III	45	4	11
—unknown ^a	7	2	
Actinomycin dose (μg): range (median)	80–2200 (240)	94–350 (265)	80–480 (190)

^aIn 4 patients the diagnosis after nephrectomy was different from Wilms tumor.

body weight) due to fluid retention. The histological diagnosis was accepted when the local pathologist clearly stated a diagnosis of VOD and reported compatible pathological findings.

Patients were divided in two groups according to how the AD dose was calculated, i.e. by body area or weight. Fifteen patients with no data on the drug calculation method were assumed to have been treated according to protocol guidelines, i.e. per square meter or per kilogram, respectively, depending on whether chemotherapy was implemented before or after amending the protocol in April 1989.

Statistics

Patients and therapies were compared using Fisher's exact test and the chi-squared test. A multivariate analysis of possible risk factors for VOD was performed with a logistic regression model and the maximum likelihood method, using the SAS statistical package.

RESULTS

Sixty-four of the 511 patients (12.5%) had evidence of various degrees of hepatotoxicity. Forty-one of these showed clinical features compatible with the diagnosis of VOD in the absence of other cause of liver toxicity. Twenty-three patients were diagnosed as having liver

disease of uncertain origin: 5 with a concurrent infection (2 pneumopathy, 1 enterocolitis, 1 systemic candidiasis, and 1 adenovirus infection), 9 satisfied less than 2 criteria, 3 only had raised transaminases, 5 revealed obstruction of the inferior vena cava due to tumor mass, and 1 developed jaundice after ileostomy that regressed when ileal continuity was re-established. One patient suffered a second episode of hepatotoxicity after a subsequent AD + VCR administration.

The group of patients with clinical VOD included 18 females and 23 males, aged from 6 to 118 months (median 18.5). Ten children weighed less than 10 kg at diagnosis and weight ranged for the group as a whole between 8 and 33 kg. Body surface area ranged from 0.37 to 1.1 m² (median 0.5). Thirteen patients were randomized to the short and 15 to the long chemotherapy arm, while 13 were not randomized (because of toxicity in 7 cases). Twenty-one patients were classified as being in post-operative stage I, 9 in stage II and 11 in stage III (table I).

The AD dose was calculated on the basis of body surface area in 14 children. For the whole group, the median cumulative dose of AD administered before the onset of toxicity was 190 μg/kg (range 80–480).

The characteristics of 42 toxic events are summarized in table II. Hepatomegaly was a constant finding, often

TABLE II. Manifestations in Patients With VOD (42 Episodes)

	N. patients	%
—Hepatomegaly	42	100
—Ascites	34	81
—Weight gain (>2%)	27	64
—Jaundice	12	28
—Fever	33	78
—Neurologic manifestations	5	12
—Haemorrhages/haematomas	5	12
—Skin rash	4	9
—Abdominal pain	3	7
—Pleural effusion	2	5
—Paralytic ileum	2	5
—Isolated thrombocytopenia	9	21
—Liver enzymes >10 × normal values	20	47
—Other	2	5

Other: hyponatremia, increase of pancreatic enzymes.

combined with ascites. An increase in transaminases was nearly always found after initial signs of toxicity, and this was over 10 times higher than normal in 20 cases. Isolated thrombocytopenia was noted in 9 patients.

Toxicity compatible with VOD occurred 8–147 days after starting chemotherapy (median 55.5 days). In 15 cases, this occurred pre-operatively, so none of these patients had received anesthetics before the onset of toxicity.

Ultrasound showed no particular features: in most cases, the hepatomegaly coincided with a homogeneous echostructure or hyper-echogenicity. Doppler ultrasound was performed in 2 patients and showed normal findings. At the time of the toxic event, serological investigations were performed in 19 patients for hepatitis B, in 13 for hepatitis A, in 23 for cytomegalovirus, and in 18 for Epstein Barr virus. They were negative in all case.

Radiation therapy was administered to 68 of the 511 patients. In the VOD group, 3 stage II patients (with positive nodes) and 8 stage III patients were irradiated. In 10 of these patients, toxicity developed either during (2 cases) or after radiotherapy (range 2–70 days). The dose was 20 Gy or less in 5 patients and 25–30 Gy in the others, with right-sided fields of irradiation in 5 patients.

The duration of the toxicity episode was assessed in 32 patients. Recovery, defined as the disappearance of all clinical signs of VOD and normalization of liver function tests, occurred after 6–180 days (median 22 days). After recover, chemotherapy was continued at full doses in 6 patients, suspended in 5, and in the other patients, modified mainly by reducing the AD dose by 33–50%. In this latter group, one child suffered a second episode of hepatomegaly, ascites, weight gain, thrombocytopenia, and raised transaminases (5 times the normal values), but quickly recovered.

Liver biopsies were performed in 16 of the 41 VOD patients, 12 during nephrectomy after pre-operative chemotherapy and 4 post-operatively. VOD was diagnosed

by the local pathologist in 9 specimens. Other hepatic alterations included congestion and focal hemorrhage in 3 cases and single cases of hepatic peliosis and what was described as a “minimal lesion”. The specimen revealed no abnormality in 2 cases. Biopsy was performed in 8 patients when physical and biochemical signs of hepatic toxicity were still present and VOD was histologically confirmed in 7 of these. One further patient underwent biopsy 5 days after normalization of the abnormal signs and showed mild changes of VOD. Four patients with a normal histology or lesions other than VOD were biopsied after recovering from toxicity. Insufficient relevant information was available on the remaining 3 patients, one of whom was in the VOD group. The time elapsing between the onset of liver toxicity and the biopsy was not significantly different in patients with and without VOD. In one further child, the biopsy was performed at nephrectomy, before the onset of hepatic toxicity, and it showed hepatic peliosis. In the 23 patients with no VOD hepatotoxicity, 6 biopsies were performed: 3 showed normal findings, and single cases of fibrosis, peliosis, and alterations compatible with Budd-Chiari syndrome were found.

The overall survival of the VOD group is 94% and the event-free survival is 82% at 5 years. These values do not differ significantly from the results in the whole group of patients eligible for the trial.

There was a different age and weight distribution between the groups considered in this analysis (table I). On univariate analysis, the VOD cases were significantly younger ($p = 0.008$) and weighed less ($p = 0.07$) than the other patients in the study. In particular, there was a greater proportion of children aged less than 1 year in the VOD group: 24% (10/41) vs. 11.4% (78/444), suggesting that this age group is more at risk than the older children ($p = 0.01$). Moreover, 7 of the patients under 12 months old showed a marked increase in transaminases (>10 times normal values). Lower doses of AD were administered to the group with VOD (190 vs. 240 μg , $p < 0.0001$) because of the drug reduction recommended by the protocol in children under 12 months old. VOD developed in 10/68 irradiated patients (14%) and in 31/433 (7%) cases in the group receiving no radiotherapy. Patients who received post-operative abdominal irradiation proved to be more at risk of VOD ($p = 0.02$) and also marginally more at risk of hepatotoxicity ($p = 0.063$). Sex and body surface area were not significant variables, nor was the method of AD administration—even in babies under 12 months old or weighing less than 10 kg. A multivariate analysis considering patient characteristics (sex, age, weight, body surface area), AD dosage and administration method, and radiotherapy, confirmed the importance of age ($p = 0.001$) and radiotherapy ($p = 0.001$).

Age was even significantly associated with VOD (p

= 0.025) in the subset of 20 patients with very high transaminase levels (>10 times normal), while it was impossible to confirm the role of radiotherapy because only 2 children in this group were irradiated.

DISCUSSION

Hepatic VOD is a common complication after bone marrow transplantation and can affect up to 54% of patients. Severity varies, from mild and reversible to progressive and fatal [10]. The occlusion of small veins is often not limited to the liver, leading to a clinical picture of multiple organ failure [11].

VOD is primarily a clinical diagnosis based on criteria defined by McDonald et al. [1] in transplanted patients: jaundice or serum bilirubin > 2 mg/dl, hepatomegaly or right upper quadrant pain, ascites, or unexplained weight gain. At least two of these features are required for the clinical diagnosis of VOD if the onset is within 30 days of transplantation and providing that other potential causes have been excluded. Stricter criteria have been proposed (i.e. hyperbilirubinemia plus two of the following: hepatomegaly, weight gain, or ascites) [12], but they seem to identify a subgroup of patients who are more likely to have an unfavorable outcome [13]. We identified 11 out of 41 patients fulfilling the stricter criteria. However, their outcome as well as the recovering time from toxicity were similar to the ones of the other patients.

Radiological examination might show gallbladder wall thickening and/or reversed blood flow in the portal vein on Doppler ultrasound. Such findings are not clinically useful, however, because gallbladder wall thickening seems to occur in marrow transplant recipients without VOD while vascular changes are of late onset [14,15]. Proposed markers, e.g. protein C, protein S, or serum aminopropeptide of type III collagen, are only of interest in research at present [16,17].

Liver biopsy can confirm the clinical diagnosis of VOD by showing the small intrahepatic venules narrowed by an edematous concentric subendothelial zone containing fragmented red cells, debris, and fibrillar material; surrounding sinusoids are engorged and centrilobular hepatocytes are damaged. These changes lead to intrahepatic hypertension, hepatic enlargement, hyperbilirubinemia, peripheral edema, and ascites [1]. The severity of VOD seems proportional to the number of histologic changes [18]. However, open biopsy may not always be feasible (e.g., in the severely ill), especially if there are bleeding problems. Transvenous liver biopsy poses technical difficulties and may cause fatal complications [19].

Hepatotoxicity may be observed during conventional chemotherapy. A syndrome characterized by ascites and hyperbilirubinemia has been reported following the ad-

ministration of several antineoplastic drugs [3–8], particularly in children treated for Wilms tumor. In the National Wilms Tumor Study (NWTS)-4, the incidence of hepatotoxicity ranged from 2.8 to 14.3% for different schedules of AD administration in non-irradiated patients [6], and the frequency of reported cases seemed to rise after physicians were alerted by the publication of a preliminary report [20]. A lower incidence (1.4%) of hepatotoxicity in association with thrombocytopenia has been reported by the United Kingdom Cancer Study Group (UKW protocols 1 and 2) [7]. Only one case of severe hepatotoxicity was reported in 65 children observed in the Brazilian Wilms Tumor Study using dactinomycin doses identical to those considered in the NWTS-4 [21]. VOD was suspected as the basic lesion in these reports because of the similarity of symptoms seen in transplanted patients, but it was impossible in the Wilms tumor children to obtain any histological confirmation.

In our series, the incidence of hepatotoxicity with findings compatible with VOD was 8% for the whole group and 6% if patients who received radiotherapy were excluded. This figure is higher than the 2.8% reported by the NWTS in children treated with a similar dose of AD (15 µg/kg/day for 5 days).

As mentioned in the NWTS study, this could be partly explained by the greater attention of clinicians to this particular type of toxicity. SIOP-9 was a multinational study and a different attitude to the diagnosis of VOD is to be expected in different countries. In particular, we noticed that in Germany—where a study on VOD was conducted on a national basis [22]—a slightly higher incidence was reported (10% in the GPOH vs. 7% in the SIOP patients).

A more likely explanation, however, lies in the different definitions of hepatic toxicity used by our group as opposed to other investigators. The American and English reports are based on increased transaminases rather than on clinical criteria of VOD. A marked increase in transaminases is not necessarily characteristic of VOD [11] and 22 out of 42 episodes would have been excluded from our series using the NWTS criteria. Finally, although we were unable to correlate hyperbilirubinemia with the severity of hepatotoxicity, as reported in transplanted patients [10], it is possible that our definition enabled us to pinpoint milder cases of VOD. In fact high blood bilirubin level was found in only 23% of the patients of our series, while it was documented in 54% of the cases in the NWTS [6].

Chemotherapy with VCR and AD seem responsible for the toxicity described. This conclusion derives from the subset of patients who suffered from toxicity during pre-operative treatment when there were no other potential causal factors; e.g. radiotherapy, inhalation of halogenated hydrocarbons for anesthesia, or concomitant infection. Chemotherapy may have increased the already-

established radiotherapy-induced hepatotoxicity. This effect has already been analyzed in the patients enrolled by the GPOH group: AD administered during or immediately after radiotherapy has been implicated, as well as the amount of liver included in the target field and the radiation dose delivered [22].

Potential risk factors for VOD in bone marrow transplantation patients also partly apply to those receiving conventional chemotherapy. These factors are: pretransplant hepatitis, fever and antimicrobial therapy (especially vancomycin and amphotericin), female sex, age over 15 and positive cytomegalovirus serology [23]. Serological studies were not systematically performed in our series, but there was no evidence of hepatitis prior to cell reduction therapy, as demonstrated by normal transaminase levels at diagnosis in all patients. The possible influence of fever and antimicrobial therapy was not critically examined in our study, but at review, the data shows that antibiotic therapy was started after the onset of toxicity, when fever was already present.

The role of AD as cause of hepatotoxicity is not entirely clear. In the NWTS-4 fewer toxic events were reported when the AD dose was decreased from 60 $\mu\text{g}/\text{kg}$ to 45 $\mu\text{g}/\text{kg}$. The UKW studies found no cases of hepatotoxicity in 146 patients treated with VCR alone, but 5 cases were reported among 355 patients treated with combined VCR and AD. The pre-operative AD dose adopted in the SIOP study was the same as in the NWTS-4 after the decision adopted to reduce toxicity (45 $\mu\text{g}/\text{kg}$), though it was administered using a different schedule, but 3% of our patients developed VOD during the initial part of treatment. Furthermore, calculating the AD dose by patient weight led to a mean 25% reduction in the drug dose administered in our study, but this did not significantly protect children from VOD.

Some differences emerge between the hepatotoxicity seen in Wilms tumor and in transplanted patients: hyperbilirubinemia was found in 99% of transplanted patients [10], but only in 12/42 episodes in our study. On the other hand, we found ascites in 81% of our population as opposed to 60% of patients with edema and 23% with ascites in the transplant setting. Finally, the increase in liver enzymes seems much higher in chemotherapy-associated toxicity, especially in younger children.

VOD therapy in our patients was supportive, without using drugs such as gabexate mesylate [24], recombinant tissue plasminogen activator or heparin [1]. It seems unnecessary to withhold chemotherapy after the signs of VOD have disappeared, but clinicians must be aware that the toxicity may recur even with a lower drug dosage. No fatal hepatotoxicity was observed.

In conclusion, liver dysfunction with the clinical and pathological characteristics of VOD could affect children treated with VCR and AD for Wilms tumor. Younger children are especially at risk and the remarkable in-

crease in transaminase levels—especially in children less than 1 year old—may suggest a higher degree of liver toxicity. Neither AD schedule nor a dosage reduction in younger children (by calculating the dose according to body weight) seem to influence the incidence of toxicity, but a relationship between radiotherapy and concomitant AD administration has been suggested. VOD is primarily a clinical syndrome with a favorable outcome and liver biopsy should be reserved for selected cases when the clinical picture is doubtful. Supportive therapy seems adequate for these patients, but recurrence is a possibility when chemotherapy is restored. The overall good prognosis of patients with Wilms tumor is not significantly altered by the occurrence of hepatotoxicity.

ACKNOWLEDGMENTS

We thank J de Jonge and A. van Veen for their much-appreciated assistance. We also thank Dr. GJ D'Angio for reviewing the manuscript and for editorial assistance. This work was supported in part by an Italian Grant "MURST 60%".

REFERENCES

1. Mc Donald GB: Venous-occlusive disease of the liver following marrow transplantation. *Marrow Transpl Rev* 3:49–56, 1993/94.
2. Griner PF, Elbadawi A, Packman CH: Venous-occlusive disease of the liver after chemotherapy of acute leukemia. *Ann Intern Med* 85:578–82, 1976.
3. Satti MB, Winbren K, Gordon-Smith EC: 6-Thioguanine as a cause of toxic venous-occlusive disease of the liver. *J Clin Pathol* 35:1086–1091, 1982.
4. D'Cruz CA, Wimmer RS, Haecke HT, Huff DS, Naiman JL: Venous-occlusive disease of the liver in children following chemotherapy for acute myelocytic leukemia. *Cancer* 52:1803–1807, 1983.
5. Asbury RF, Rosenthal SN, Descalzi ME, Ratcliffe RL, Arseneau JC: Hepatic venous-occlusive disease due to DTIC. *Cancer* 45:2670–2674, 1980.
6. Green A, Norkool P, Breslow NE, Finklestein JZ, D'Angio GJ: Severe hepatic toxicity after treatment with vincristine and dactinomycin using single-dose or divided-dose schedules: a report from the National Wilms' Tumor Study. *J Clin Oncol* 8:1525–1530, 1990.
7. Raine J, Bowman A, Wallendszus K, Pritchard J: Hepatopathy-thrombocytopenia syndrome—a complication of dactinomycin therapy for Wilms tumor: a report from the United Kingdom Childrens Cancer Study Group. *J Clin Oncol* 9:268–273, 1991.
8. Oberlin O, Tournade MF, Daltroff G, Quintana E, Tron P, Chastagner P, Brunat-Metigny M, Lutz P, Otten J, Jullien M: Hepatic toxicity compatible with venous-occlusive disease after actinomycin-D in non-irradiated Wilms tumour. *Med Pediatr Oncol* 17:317, 1989.
9. Corn BW, Goldwein JW, Evans I, D'Angio JG: Outcome in low-risk babies treated with half dose chemotherapy according to the third National Wilms Tumor Study. *J Clin Oncol* 10:1305–1309, 1992.
10. Bearman SI: The syndrome of hepatic venous-occlusive disease after marrow transplantation. *Blood* 85:3005–3020, 1995.

11. McDonald GB, Hinds MS, Fisher LD, Schoch HG, Wolford JL, Banaji M, Hardin BJ, Shulman HM, Clift RA: Veno-occlusive disease of the liver and multiorgan failure after bone marrow transplantation: a cohort study of 355 patients. *Ann Intern Med* 118:255–67, 1993.
12. Jones RJ, Lee KSK, Beschoner WE, Vogel VG, Grochow LB, Braine HG, Vogelsang GB, Sensebrenner LL, Santos GW, Saral R: Veno-occlusive disease of the liver following bone marrow transplantation. *Transplantation* 44:778, 1987.
13. Blostein MD, Paltiel OB, Thibault A, Rybka WB: A comparison of clinical criteria for the diagnosis of veno-occlusive disease of the liver after bone marrow transplantation. *Bone Marrow Transplant* 10:439, 1992.
14. Nicolau C, Bru C, Carreras E, Bosch J, Bianchi L, Gilabert R, Vilana R: Sonographic diagnosis and hemodynamic correlation in veno-occlusive disease of the liver. *J Ultrasound Med* 12:437–40, 1993.
15. Hommeyer SC, Teefey SA, Jacobson AF, Higano CS, Bianco JA, Colacurcio CJ, McDonald GB: Veno-occlusive disease of the liver: prospective study of US evaluation. *Radiology* 184:683–686, 1992.
16. Eltumi M, Trivedi P, Hobbs JR, Portmann B, Cheeseman P, Downie C, Risteli J, Risteli L, Mowat AP: Monitoring of veno-occlusive disease after bone marrow transplantation by serum aminopropeptide of type III procollagen. *Lancet* 342:518–521, 1993.
17. Faioni EM, Krachmalnicoff A, Bearman SI, Federici AB, Decarli A, Gianni AM, McDonald GB, Mannucci PM: Naturally occurring anticoagulants and bone marrow transplantation: plasma protein C predicts the development of veno-occlusive disease of the liver. *Blood* 81:3458–3462, 1993.
18. Shulman HM, Fisher LB, Schoch HG, Henne KW, McDonald GB: Veno-occlusive disease of the liver after marrow transplantation: histological correlates of clinical signs and symptoms. *Hepatology* 19:1171–1181, 1994.
19. Shulman HM, McDonald GB: Transvenous liver biopsies and pressure measurements in bone marrow transplant recipients. *Hepatology* 16:148, 1992.