



## UvA-DARE (Digital Academic Repository)

### Vertebral abnormalities after treatment for Ewing sarcoma

Burgers, J.M.V.; Staalman, C.R.; de Kraker, J.; Oldenburger, F.; Delemarre, J.F.M.; vd Eijken, J.W.

**DOI**

[10.1002/\(SICI\)1096-911X\(199701\)28:1<54::AID-MPO10>3.0.CO;2-A](https://doi.org/10.1002/(SICI)1096-911X(199701)28:1<54::AID-MPO10>3.0.CO;2-A)

**Publication date**

1997

**Published in**

Medical and Pediatric Oncology

[Link to publication](#)

**Citation for published version (APA):**

Burgers, J. M. V., Staalman, C. R., de Kraker, J., Oldenburger, F., Delemarre, J. F. M., & vd Eijken, J. W. (1997). Vertebral abnormalities after treatment for Ewing sarcoma. *Medical and Pediatric Oncology*, 28, 54-58. [https://doi.org/10.1002/\(SICI\)1096-911X\(199701\)28:1<54::AID-MPO10>3.0.CO;2-A](https://doi.org/10.1002/(SICI)1096-911X(199701)28:1<54::AID-MPO10>3.0.CO;2-A)

**General rights**

It is not permitted to download or to forward/distribute the text or part of it without the consent of the author(s) and/or copyright holder(s), other than for strictly personal, individual use, unless the work is under an open content license (like Creative Commons).

**Disclaimer/Complaints regulations**

If you believe that digital publication of certain material infringes any of your rights or (privacy) interests, please let the Library know, stating your reasons. In case of a legitimate complaint, the Library will make the material inaccessible and/or remove it from the website. Please Ask the Library: <https://uba.uva.nl/en/contact>, or a letter to: Library of the University of Amsterdam, Secretariat, Singel 425, 1012 WP Amsterdam, The Netherlands. You will be contacted as soon as possible.

PROCEEDINGS OF THE TUMOR BOARD OF THE DEPARTMENT  
OF PEDIATRIC ONCOLOGY  
Emma Kinderziekenhuis/Academic Medical Center, University of Amsterdam, The Netherlands

J.M.V. Burgers, Guest Editor

Giulio J. D'Angio, MD, Series Editor and Audrey E. Evans, MD, Associate Editor

## Vertebral Abnormalities After Treatment for Ewing Sarcoma

J.M.V. Burgers, MD, C.R. Staalman, MD, J. De Kraker, MD, F. Oldenburger, MD,  
J.F.M. Delemarre, MD, and J.W. van der Eijken, MD

### J.W. van der Eijken, MD (Orthopedic Surgeon)

Miss E.O., born November 1, 1978, was seen for her regular follow-up today. She seemed to be in good health and spirits and even more plump than before. However, her chest radiograph shows increasing changes when compared with prior examinations, and I would like to discuss this problem.

### C.R. Staalman, MD (Pediatric Radiologist)

The radiograph of today (March 1991) reveals a decrease in the height of several midthoracic vertebrae (Fig. 1). Some indication of this could be seen in September 1990, but there has been clear progression, now with kyphosis added. T5–T9 are most affected with microfractures of the vertebral endplates and severe collapse of the vertebral bodies. Further, as before, the right hemithorax is reduced in volume, and there is retraction of the mediastinum.

### Pediatric Oncology Resident

To summarize the previous history: E.O. presented in May 1989, when 11 years old, because of an ache in the chest and ribs, especially when coughing. It had been present for 6 months, but was neither severe nor consistent. Examination by the general practitioner had not revealed a cause for the complaint. Subsequently, a 3-cm thickening appeared in the painful area paravertebrally under the right scapula. It was fixed to subcutaneous tissues but not to the skin. The chest X-ray film revealed an intrathoracic mass, which was further examined by a CT scan (Fig. 2). The mass there measured 10 cm, encroached on T6, 7, and 8, and was attached to the 7th rib, which showed destructive changes. The mass protruded through the foramen just reaching the vertebral canal. The vertebrae themselves had a normal structure.

On further examination, no neurologic or other signs or symptoms were found. Blood chemistry was normal,

and a skeletal scan showed no other lesions. A presumptive diagnosis of Ewing sarcoma was made and a biopsy performed.

### J.F.M. Delemarre, MD (Pediatric Pathologist)

The tissue showed a proliferation of small cells with scanty cytoplasm. The nuclei were round or oval, hyperchromatic, but without clear nucleoli. The cytoplasm was PAS positive and PHS diastase negative. Some strands of collagenous connective tissue were seen. The vimentin stain was positive. Other histochemical stains were negative. The pictures are consistent with a diagnosis of Ewing sarcoma, which was confirmed by the Dutch Bone Tumour Committee.

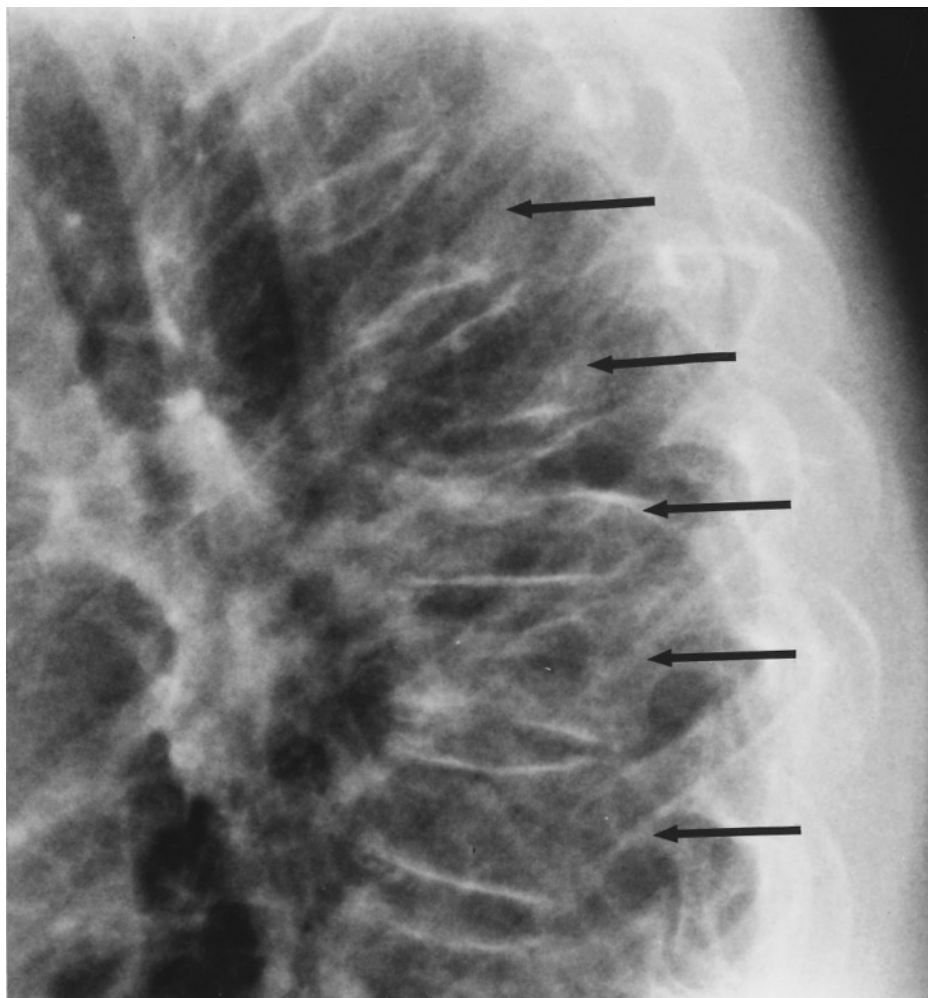
### J. de Kraker, MD (Pediatric Oncologist)

E.O. was started on chemotherapy in May 1989 according to the CESS 86 protocol of the Cooperative Ewing Sarcoma Study organized by the German Society of Pediatric Oncology. The study stratifies patients according to tumor volume. This patient had a mass defined as large (>100 ml)<sup>(1)</sup>, and therefore received vincristine, ifosfamide, doxorubicin, and dactinomycin. Local treatment—in this case, radiotherapy—is due after course 3, i.e., at week 9, and was given.

From the Radiotherapy Department, Academic Medical Center (J.M.V.B., F.O.), Department of Pediatric Oncology Emma Kinderziekenhuis/Academic Medical Center, University of Amsterdam (C.R.S., J.D.K., J.W.v.d.E.), and Department of Pediatric Oncology, Pathologist Netherlands Cancer Institute and Emma Kinderziekenhuis/Academic Medical Center, University of Amsterdam. (J.F.M.D.)

Received December 13, 1994; accepted January 29, 1995.

Address reprint requests to Giulio J. D'Angio, MD, Department of Radiation Oncology, Hospital of the University of Pennsylvania, 3400 Spruce Street, Philadelphia, PA 19104.



**Fig. 1.** Lateral X-ray film of vertebral column, May 1991, showing wedge-shaped deformities (collapse) in several thoracic vertebrae, most marked in T5-9 (arrows).

**Dr. Staalman.** The present lesions are seen in T5–T9, i.e., slightly longer than the level of the original tumor. However, at that time the bone structure of the vertebrae was normal since the tumor originated in the 7th rib. In the differential diagnosis could be mentioned tumor recurrence, radionecrosis, if this area was irradiated, and osteoporosis, although the patient is young and has normal activities. If the changes are considered a tumor relapse, has there been a local regrowth or are there metastases?

**J.M.V. Burgers, MD (Pediatric Radiation Oncologist)**

We have experience with flattened vertebrae with concave surfaces due to local osteoporosis that develop in the radiation field in adults.

**Dr. van der Eijken.** A growth disturbance may be seen, also with convex upper/lower surfaces of the vertebra, after irradiation of the vertebral column in a growing child.

**Resident.** Further workup of E.O. by general examination revealed no other abnormalities. Since the treatment ended in March 1990, the patient gained 12 kg and grew

in length 3 cm. Incidentally, a skeletal scan in 1991 had revealed, as before, some abnormalities in T3–4, T7–8, and in the 7th rib, so the present findings are not new.

Should we consider a bone biopsy?

**F. Oldenburger, MD (Pediatric Radiation Oncologist)**

We reviewed the charts of E.O., which showed that a good tumor reduction had taken place after chemotherapy. We therefore could situate the anterior border of the target volume just ventral to the vertebrae (Fig. 3). An oblique posterior and a lateral wedged pair were used to include part of the vertebrae and the original extension into the vertebral canal. At 40 Gy, the target volume was reduced by ~1 cm in all directions and an additional 20 Gy was given to a field 12 cm long. With this setup, 70% of the dose reached the lateral and inferior portion of the 7th rib, which was boosted by an electron field. The cord received 50 Gy maximum to part of its width, and the dose on the lateral aspects of T6–9 was 60 Gy. The risk of scoliosis by not treating the vertebrae homogeneously

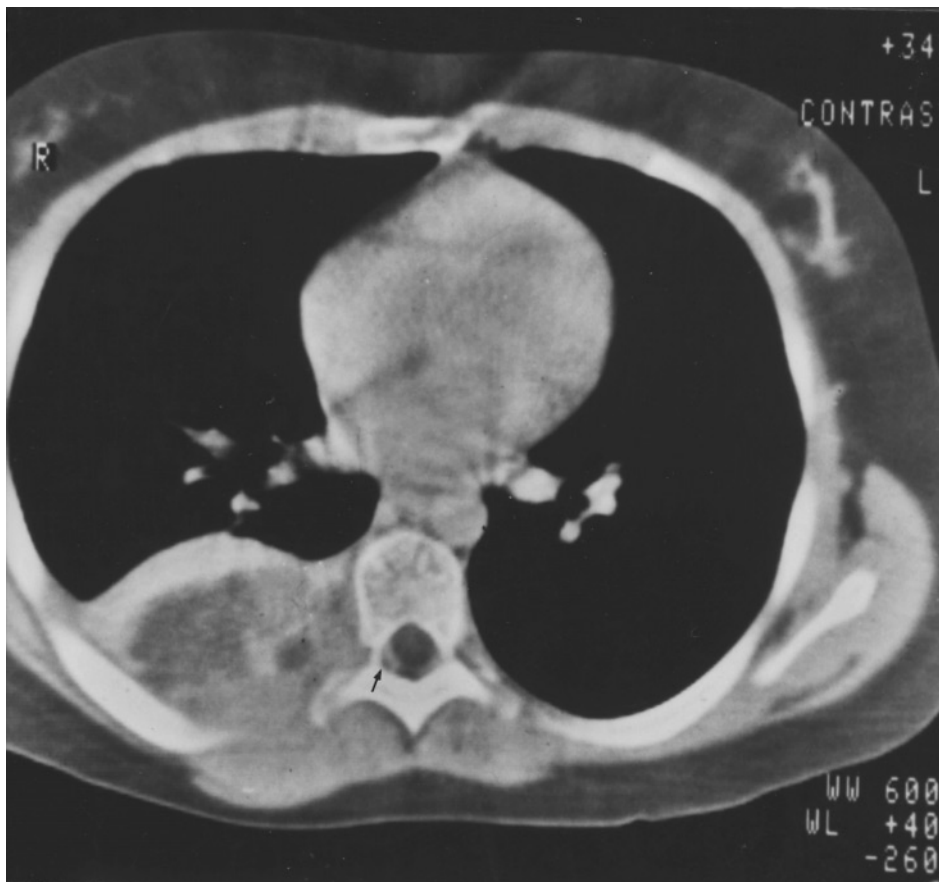

Fig. 2. CT scan of original tumour: Ewing sarcoma of right 7th rib with large soft tissue mass in the posterior thorax and early protrusion into the spinal canal (arrow).

had to be accepted; otherwise, the dose to the cord would have been too high.

Is it possible that the dose of radiation therapy given could induce osteoporosis?

**Dr. Burgers.** Adult patients who are curatively irradiated for lung carcinoma sometimes demonstrate this phenomenon, with an increasing kyphosis and some vertebrae becoming flatter or wedge-shaped. Usually, the general condition remains excellent and no pain is reported. Our attention was first drawn to this picture by the present chief of the radiotherapy department, Professor Gonzalez, and we call it the “Gonzalez syndrome” after him. These adult patients have received high doses in the 45–60 Gy range to several vertebrae while shielding the cord for the last part of the irradiation. The condition is self-limiting, and the main problem is to convince the pulmonologist of its innocent character.

One can only speculate regarding the pathophysiology of the Gonzalez syndrome. We believe that a combination of reduced vascularity and impaired osteogenic repair leads to a pseudo-avascular necrosis and osteopenia, rather like that seen in the pelvis after high-dose radiotherapy [2,3]. An overview of radiation changes in bone has recently been provided by Libshitz [4]. I do not know whether chemotherapy contributed to the development of

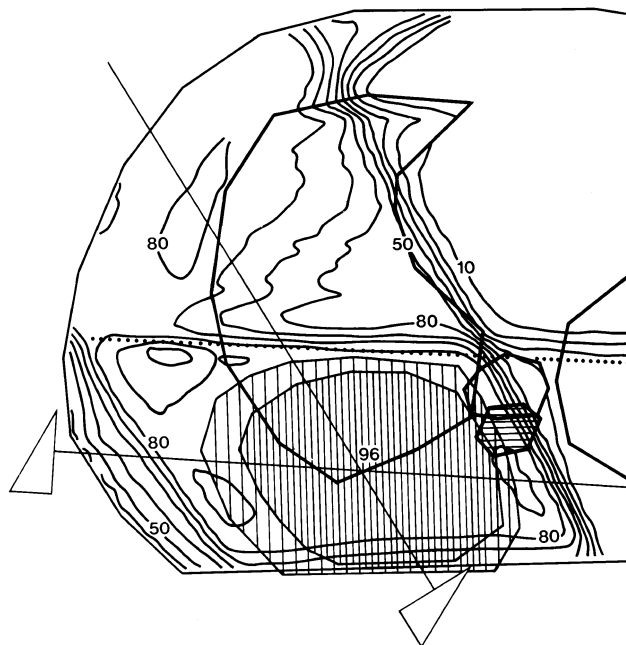


Fig. 3. Radiotherapy plan. The isodose distribution shows that the implicated vertebra is included in the target volume, the ipsilateral half receiving 85–90% of the nominal dose of 60 Gy.

this lesion. Certainly, Tefft et al. [5] have pointed out that combined chemo-radiotherapy can lead to pronounced osseous changes. This happens when radiation-enhancing drugs such as those used here are employed, i.e., dactinomycin and doxorubicin.

*Drs. van der Eijken and de Kraker.* Perhaps we can agree, in view of this experience, that further investigation can be avoided now, and our patient can be kept on close follow-up. She should, of course, continue to receive physiotherapy to strengthen the trunk musculature.

Addendum: Drs. van der Eijken and de Kraker reported in May 1994, 3 years later, that Miss E.O. was doing well and she had started her periods in January 1992. Her weight and length were 77 kg, 160 cm, so she had increased by 9 kg and 6 cm. She was plump, short in stature, and had an increase in the dorsal kyphosis, which could not be completely reduced in knee-elbow position. The X-ray films showed a midthoracic kyphosis of 60° with wedge-shaped T5-9 with practically no change over the last year. In view of her plumpness, a corrective corset was not prescribed because it would not have been

effective. Miss E.O. continues on physiotherapy; the mobility of the spine is excellent.

We conclude that the Gonzalez' syndrome, i.e., wedge-shaped flattening of vertebrae in a high-dose radiation fields is the explanation for the findings in E.O.

## REFERENCES

1. Dunst J, Sauer R: Therapie des Ewing-Sarkoms. Strahlentherapie und Onkologie 169:695–708, 1993.
2. Csuka M, Bruce BJ, Lynch KL, McCarthy DJ: Osteonecrosis, fractures and protrusion acetabulae secondary to x-irradiation therapy for prostatic carcinoma. J Rheumatol 14:165–170, 1987.
3. Lundin B, Bjorkholm F, Lundell M, Jacobsson H: Insufficiency fractures of the sacrum after radiotherapy for gynaecologic malignancy. Acta Oncologica 29:211–215, 1990.
4. Libshitz HI: Radiation changes in bone. Semin Roetgenol 29:15–37, 1994.
5. Tefft M, Lattin PB, Jereb B, Cham W, Ghavimi F, Rosen G, Exelby P, Marcove R, Murphy ML and D'Angio GJ: Acute and late effects on normal tissues following combined chemo-radiotherapy for childhood rhabdomyosarcoma and Ewing's sarcoma. Cancer (suppl) 137:1201–1231, 1976.

## Series Editor's Note

Dr. Burgers et al. discuss a patient who developed a treatment-related deformity. Disease also can cause deformity, of course, and brings to mind a very interesting Brazilian man. His crippling disease gave rise to his nickname (from Middle English and incorrect separation of the *n* in *an*: *an ekename*: *eke* = also + name).<sup>1</sup> Antonio Francisco Lisboa (1738–1814) was an artistic genius and the architect of many of the graceful churches in Ouro Preto in Brazil, which he further embellished as a painter and sculptor. All this is doubly remarkable because of a progressive destructive disease—probably leprosy (Greek: *lepros* = scabby or rough) or possibly *yaws* (perhaps of Caribbean-Creole origin; also known as *frambesia* from the French *framboise* = raspberry)—that left him with only stumps for hands. He therefore acquired the nickname *Aleijadinho* [Portuguese: Little Maimed (Lesioned) One]. Despite the loss of digits and then much of his hands, he nonetheless continued his carving, strapping tools to the stumps as needed.

Ouro Preto (Portuguese: Black Gold) derived its name from the black oxide that covered the first gold nuggets found in the region in 1689, it would seem. It brought wealth and prominence to the city, which became an

important provincial center. Ouro Preto continues to be a center for the mining and processing of these minerals. It is located in the state of Minas Gerais (General Mines), which takes its name from the abundant mineral resources found in the vast expanses of that region.

Ouro Preto is a charming city that retains much of the atmosphere of the high point of regal Brazil. There is a monument in the city square to the Brazilian patriot Joaquim Jose da Silva Xavier (1748–1792). An army officer and apparently a dentist, he was known and comes down in history as “*Tiradentes*” (Portuguese = teeth puller). He was an important figure in the revolutionary movement of the late 1700s, but was captured by loyalist troops and then hanged and quartered. His head was displayed in the Ouro Preto square where there is a monument to his memory.

Prominent persons in history thus sometimes derive their nicknames from real or imagined attributes. Two other examples of such sobriquets with medical overtones follow.

“*Caligula*” (Caius Caesar Germanicus) (12–41 AD) was the son of the very popular general Germanicus Caesar. As a boy, he wore small military boots (*caligula*) and became the mascot of his father's legionnaires. The name stuck. His medical history is important. Shortly after becoming proclaimed emperor in 37 AD, he was felled by a severe illness marked by coma (Greek: *koma*) and high

<sup>1</sup>Mis-application of the “*n*” in the word “*an*”, either way is not uncommon in English, e.g., “*a napron*” (Old English: *nape* = cloth, carried forward e.g. in *napkin*) became “*an apron*”; “*a nadder*” became “*an adder*.”

fever. This is considered by some to have been an encephalitis. His reign up to then had been popular and marked by moderation and good sense. His return to apparent health saw a marked change in his demeanor. He became hated for his despotism (Greek: *despotes* = master) and his cruel and erratic behavior. He was assassinated<sup>2</sup> after a few years in power. Many attribute the personality change to brain damage after the sickness of his early tenure.

James Buchanan “Diamond Jim” Brady (1856–1917), was a wealthy financier who collected diamonds and

---

<sup>2</sup>From Arabic *hashshashin* = those who smoke or chew hashish (Arabic). The aim of this secret sect was—while under the influence of hashish—to murder and thus terrorize Crusaders and other enemies.

other jewels, which he displayed prominently. He is of interest medically in that he founded the world-renowned Brady Urological Institute at Johns Hopkins Hospital, Baltimore.

“Peter” stems from theology, not medicine. When Jesus met Symeon (Simon), He said, “Thou art Simon the son of Jona. Thou shalt be called Cephas” (John 1:42). *Cephas* is *Kēphās* in Aramaic and means “rock.” The name comes down as *Peter* from the Greek *petros* = rock. This utterance proved to be prophetic when, later, Jesus said to Saint Peter, “Thou art Peter and upon this rock I will build my church” (Matthew, 16:18).

---

Source for Brazilian facts: Machado de Almeida L: *Passeio a Ouro Preto*. Universidade de Sao Paulo, Brazil. A Minas Gerais. Editora Itatiaia Limitada, Belo Horizonte, Brazil, 1980.