



## UvA-DARE (Digital Academic Repository)

### Treatment of Hodgkin's disease in children with alternating mechlorethamine, vincristine, procarbazine, and prednisone (MOPP) and adriamycin, bleomycin, vinblastine, and dacarbazine (ABVD) courses without radiotherapy

van den Berg, H.; Stuve, W.; Behrendt, H.

**DOI**

[10.1002/\(SICI\)1096-911X\(199707\)29:1<23::AID-MPO4>3.0.CO;2-U](https://doi.org/10.1002/(SICI)1096-911X(199707)29:1<23::AID-MPO4>3.0.CO;2-U)

**Publication date**

1997

**Published in**

Medical and Pediatric Oncology

[Link to publication](#)

**Citation for published version (APA):**

van den Berg, H., Stuve, W., & Behrendt, H. (1997). Treatment of Hodgkin's disease in children with alternating mechlorethamine, vincristine, procarbazine, and prednisone (MOPP) and adriamycin, bleomycin, vinblastine, and dacarbazine (ABVD) courses without radiotherapy. *Medical and Pediatric Oncology*, 29, 23-27. [https://doi.org/10.1002/\(SICI\)1096-911X\(199707\)29:1<23::AID-MPO4>3.0.CO;2-U](https://doi.org/10.1002/(SICI)1096-911X(199707)29:1<23::AID-MPO4>3.0.CO;2-U)

**General rights**

It is not permitted to download or to forward/distribute the text or part of it without the consent of the author(s) and/or copyright holder(s), other than for strictly personal, individual use, unless the work is under an open content license (like Creative Commons).

**Disclaimer/Complaints regulations**

If you believe that digital publication of certain material infringes any of your rights or (privacy) interests, please let the Library know, stating your reasons. In case of a legitimate complaint, the Library will make the material inaccessible and/or remove it from the website. Please Ask the Library: <https://uba.uva.nl/en/contact>, or a letter to: Library of the University of Amsterdam, Secretariat, Singel 425, 1012 WP Amsterdam, The Netherlands. You will be contacted as soon as possible.

*UvA-DARE is a service provided by the library of the University of Amsterdam (<https://dare.uva.nl>)*

# Treatment of Hodgkin's Disease in Children With Alternating Mechlorethamine, Vincristine, Procarbazine, and Prednisone (MOPP) and Adriamycin, Bleomycin, Vinblastine, and Dacarbazine (ABVD) Courses Without Radiotherapy

Henk van den Berg, MD, PhD,\* Wouter Stuve, MB, and Henk Behrendt, MD, PhD

Since the introduction of mechlorethamine, vincristine, procarbazine, and prednisone (MOPP) chemotherapy, children with Hodgkin's disease (HD) have been treated with chemotherapy alone. The occurrence of side effects related to irradiation (especially secondary solid tumors) is less likely to occur. Alkylating agents in the MOPP chemotherapy combinations are, however, known for their late effects, i.e., gonadal dysfunction and secondary malignancies. Combination with non-alkylating and non-cross-resistant drugs (as in the adriamycin, bleomycin, vinblastine, and dacarbazine [ABVD] combination) may give superior treatment results and possibly a decrease in the occurrence of side effects.

From 1988 to 1993 all children presenting with HD were treated with alternating MOPP and ABVD courses (3 × MOPP, 3 × ABVD). Twenty-one children (7 females, 14 males), ages 5-18 years (median 14 years) were included;

their clinical stages were I, 7 patients; II, 8 patients; III, 5 patients; IV, 1 patient. Their pathology revealed 2 lymphocytic predominance, 17 nodular sclerosis, 1 mixed cellularity. In 1 patient only cytology was done and thus histopathologic subclassification was not possible. Two children have relapsed; disease-free survival is 90%. Analysis of toxicity revealed no decrease in cardiac function by ultrasound examination and no pulmonary effects noted by carbon monoxide diffusion. In 1 of the 10 children tested, mild hypogonadism was noted. No secondary tumors occurred.

From this small population of children with HD we conclude that treatment with MOPP/ABVD for 6 cycles without radiotherapy may be adequate. The occurrence of gonadal dysfunction may be less frequent than with 6 cycles of MOPP. However, more patients and further follow-up are needed. *Med. Pediatr. Oncol.* 29: 23-27, 1997. © 1997 Wiley-Liss, Inc.

**Key words:** Hodgkin's disease; children; chemotherapy; radiotherapy; gonadal function; cardiac function; secondary malignancies; pulmonary function

## INTRODUCTION

From 1970 to 1975 we treated children with stage I and stage II Hodgkin's disease (HD) with extended field irradiation (EF) to a dose of 40 Gy. Patients with stage III and stage IV HD received mechlorethamine, vincristine, procarbazine, and prednisone (MOPP) in combination with irradiation. The occurrence of severe sequelae, including a diminished growth of soft tissue and bone, aseptic bone necrosis [1], hypothyroidism [2], gonadal dysfunction [3,4] and secondary malignancies [5,6] stimulated us to search for other treatment regimens. In 1975 we changed our policy. Children with HD were treated with 6 MOPP courses only. Although in those with bulky disease, with a tumor diameter more than 4 cm, radiotherapy (25 Gy involved field irradiation) was added. Disease-free survival rates for patients with non-bulky and bulky disease were 90 and 87.5%, respectively [7]. It should be emphasized that only some of the serious sequelae noted are associated with irradiation. The alkylating agents used in HD also have similar effects with

respect to secondary tumor induction and reproductive capacity [8-10]. Adriamycin, bleomycin, vinblastine, and dacarbazine (ABVD) course was introduced to improve cure without increasing toxicity associated with MOPP [11,12]. For this reason, we used from 1984 to 1987 6 courses of ABVD without radiotherapy for all children with HD. This, however, resulted in 5 relapses of 17 cases [13]. We found the number of relapses too high to be acceptable and stopped this treatment. From 1988 children suffering from HD were treated with alternating courses of MOPP and ABVD.

Department of Paediatric Oncology, University of Amsterdam, Academic Medical Centre, Emma Kinderziekenhuis, Amsterdam, The Netherlands.

\*Correspondence to: Dr. H. van den Berg, Department of Paediatric Oncology, University of Amsterdam, Academic Medical Centre, Emma Kinderziekenhuis, P.O. Box 22700, 1100 DE Amsterdam, The Netherlands.

Received 4 December 1995; Accepted 25 September 1996

TABLE I. ABVD/MOPP Treatment\*

Combination	Dose (mg/m <sup>2</sup> )	Days of treatment	Frequency
			Every 8 weeks
<i>ABVD</i>			
Adriamycin (i.v.)	25	1 and 14	
Bleomycin (i.v.)	6	1 and 14	
Vinblastine (i.v.)	6	1 and 14	
Dacarbazine (i.v.)	250	1 and 14	
<i>MOPP</i>			
Mechlorethamine (i.v.)	6	28 and 35	
Vincristine (i.v.)	1.5	28 and 35	
Procarbazine (p.o.)	80	28–42	
Prednisone (p.o.)	40	28–42	

\*These consecutive courses were repeated 3 times. i.v., intravenously; p.o., orally.

## PATIENTS AND METHODS

From 1988 to 1993, 21 children presenting with HD at our institution were included in this study. Pretreatment evaluation consisted of a detailed patient history, physical examination, histologic examination of the involved lymph node, complete blood count, urinalysis, liver function tests, serum uric acid, chest X-ray, bone marrow aspiration and biopsy, and abdominal ultrasound examination. None of the children underwent laparotomy with splenectomy. Clinical stage was determined according to the Ann Arbor recommendations [14]. The treatment given consisted of 3 modified ABVD courses and 3 MOPP courses; each ABVD course was followed by a MOPP course (see Table I). To decrease the risk of lung toxicity, bleomycin was not given as intravenous bolus injection, but was given by 6-hr infusion. In none of the patients cytokines were used. Supportive care measures were stable throughout the study. During treatment pulmonary carbon monoxide diffusion (COD) was measured prior to every ABVD administration and at the completion of therapy. Echocardiography was done prior to and at the end of therapy.

For the calculation of survival data a Cox-Mantel test was used. For comparisons of toxicity data a Wilcoxon test was applied.

## RESULTS

Seven girls and 14 boys were included in this study. Ages at diagnosis ranged from 5 to 18 years (median 14 years). The relation between clinical stage (CS) and pathologic findings is shown in Table II. The distribution of CS and histopathology is similar to other literature reports [15–19]. In one patient no histopathologic subtype was available, as the diagnosis of HD was made on cytologic criteria. Seven patients were staged as CS I, 8 patients as CS II, 5 patients as CS III, and 1 patient as CS IV. Event-free survival was 90% (SE ± 7.7). Disease-free survival (DFS) was 90% (SE ± 6.22); follow-up interval

TABLE II. Clinical Stage and Histopathology\*

CS	LP	NS	MC	LD	Total
<b>I</b>					
A	2	4	—	—	6
B	—	1	—	—	1
<b>II</b>					
A	—	4	—	—	4
B	—	3	1	—	4
<b>III</b>					
A	—	2	—	—	2
B <sup>a</sup>	—	2	—	—	3 <sup>a</sup>
<b>IV</b>					
A	—	—	—	—	0
B	—	1	—	—	1
Total	2	17	1	0	21 <sup>a</sup>

\*CS, clinical stage; LP, lymphocytic predominance; NS, nodular sclerosis; MC, mixed cellularity; LD, lymphocytic depletion.

<sup>a</sup>One patient with only cytologic data.

was 14–82 months (median 61 months) (Figs. 1, 2). Two children suffered a relapse. Clinical data on the relapsed patients are shown in Table III. In one additional child mediastinal widening persisted throughout the treatment. As this suggested persistent disease, irradiation of the area was added, but the radiographs did not change. Surgical removal revealed a benign thymic cyst and there was no evidence of HD. None of the 21 children died from toxic or infectious complications.

## Toxicity

**Cardiac toxicity.** Left ventricle shortening data (pretreatment as well as posttreatment) from 15 patients were available. In one child the shortening fraction could not be calculated due to pretreatment pericardial effusion. From the others pretreatment values ranged from 25 to 52%, with a median value of 37% (normal values 29–41%). After completion of therapy the shortening fractions ranged between 32 and 43% (median value 37%). The differences were not statistically significant.

**Pulmonary toxicity.** COD data taken at the start and at the end of treatment were available in 16 children. At the time of diagnosis, COD values ranged from 63 to 120% (median 87%) compared to mean control values. At the end of therapy, the COD values ranged from 64 to 108% (median 90%). The differences were not statistically significant.

**Gonadal and thyroid toxicity.** Of the patients who reached adolescence, luteinizing hormone (LH) and follicle stimulating hormone (FSH) values were measured in 10 cases. Six patients were found to have normal levels of both hormones (<15 mU/l). In one 16-year-old girl, a slight increase of LH was observed (19.5 mU/l), but the FSH was normal (11 mU/l), and her menstrual cycle was normal. One patient at age 18 years had a normal LH (9.0 mU/l), a slightly increased FSH (19.0 mU/l), and a low testosterone value (2.2 nmol/l). His physical examination

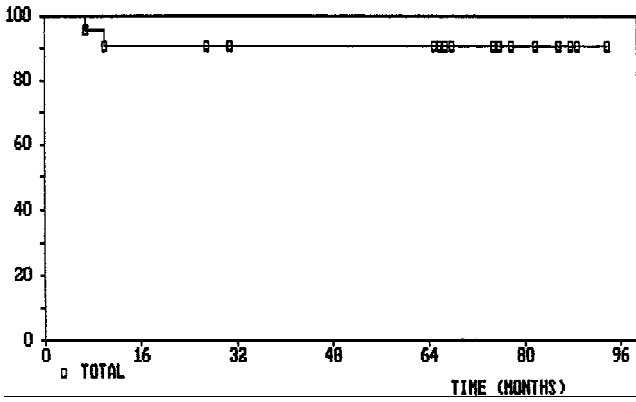


Fig. 1. Event-free survival of 21 children with HD.

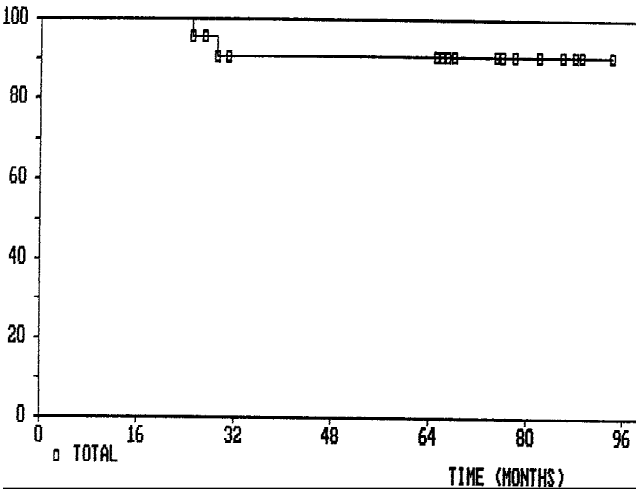


Fig. 2. Overall survival of 21 children with HD.

revealed delayed puberty. Another boy, the one who received mediastinal radiation plus chemotherapy, showed an increase of LH and FSH values of 20 and 18 mU/l and a testosterone value of 9.0 nmol/l. His thyroid function revealed mild hypothyroidism with a thyroxine of 65 nmol/l, T3 of 1.7 nmol/l, Free-T4 of 11.1 pmol/l, and thyroid stimulating hormone (TSH) of 4.2 mE/l. He has not yet begun hormone replacement therapy. None of the boys has submitted semen analysis yet. None of the girls has given birth to a child and none of the boys has fathered a child.

**Secondary tumors.** No secondary malignancies have been noted in this population.

**DISCUSSION**

Since the addition of MOPP chemotherapy to EF combined therapy has become standard treatment for HD in most centers [15,19,20]. Ziegler et al. [21] reported survival rates of 65% in CS I and CS II children following MOPP chemotherapy alone. Olweny et al. [6] later up-

**TABLE III. Clinical Data on Patients Experiencing a Relapse**

	Patient 1	Patient 2
Age at diagnosis (years)	15	16
Sex	Male	Male
Histology	Nodular sclerosis	Nodular sclerosis
Clinical stage at diagnosis	IIA	IA
Time from diagnosis to relapse (months)	7	10
Therapy for relapse	3× MOPP + radiotherapy 40 Gy	Radiotherapy 40 Gy
Outcome	No remission achieved	Second relapse <sup>a</sup>
Alive	No	No
Survival from diagnosis (months)	29	25

<sup>a</sup>Second relapse occurred 13 months after initial diagnosis; therapy: 2 courses dexamethasone, cisplatin, and cytarabine, followed by autologous bone marrow grafting after bis-chloro-ethyl-nitrosourea (BCNU), cyclophosphamide and etoposide conditioning.

dated these data and reported survival rates of 75% and 60% for early and late stage patients, respectively. We reported in 1987 that in children with non-bulky disease, i.e., lymph nodes <4 cm, chemotherapy alone resulted in a DFS of 90%. Those experiencing a relapse were salvaged with additional chemotherapy [7]. Ekert et al. [22] reported DFS rates of 92% for patients with all stages of disease using chemotherapy only. Sackman-Muriel et al. [23] concluded from a randomized study that comparable results can be achieved using chemotherapy with or without radiotherapy. Recently, Lobo-Sanahuja et al. [16] reported on 86 children with DFS rates of 90% and 60% for CS I-III A and CS II B-IV, treated with chemotherapy only. In most studies, however, only a few CS IV patients have been included. In a retrospective analysis, Bader et al. [24] showed that freedom from progression improved only in CS IV B patients receiving combined therapy compared to those treated with chemotherapy only. Our study indicates that ABVD/MOPP alone gives an acceptable survival rate, but the number of patients in our study is too small to make a reliable comparison with treatment including radiotherapy.

Using MOPP chemotherapy many long-term problems have been reported. In particular, the alkylating agents mechlorethamine and procarbazine are associated with gonadal dysfunction and secondary malignancies [5,6,10]. The hypothesis that the highest probability of cure can be achieved using non-cross-resistant drugs [25] and the reported long-term effects using MOPP led to the introduction of ABVD [26]. Santoro et al. [27] described good results (92% DFS) using ABVD courses in combination with radiotherapy [12]. This treatment, however, is associated with parenchymal lung damage and fibrosis [12,27]. Gonadal toxicity appears to be lower following

ABVD compared with MOPP [11]. The occurrence of secondary malignancies following MOPP or ABVD in combination with radiotherapy is probably similar [28]. The occurrence of secondary leukemias is estimated at 11% at 10 years and is probably related to the cumulative dose of alkylating agents [29]. Fewer cases of acute myeloid leukemia (AML) and non-Hodgkin's lymphoma are noted in ABVD-treated patients compared to MOPP-treated patients [11,30]. The occurrence of solid tumors seems related to the radiotherapy. In pediatric patients, results with ABVD/MOPP in combination with low dose radiotherapy are quite acceptable in these respects [19,31]. Instead of reducing irradiation we followed another strategy. Initially we treated patients with MOPP alone [7]. In an attempt to decrease toxicity, we switched our therapy to ABVD courses without radiotherapy. The results were less favorable [13]. As it has been reported that gonadal damage may be reversible after only 3 cycles of MOPP, we then changed our policy to the present protocol [32]. However, there are no data currently available on ABVD/MOPP-treated patients who were not also irradiated. Our results indicate that this treatment modality is feasible with a short-term EFS of 90% in a small number of patients. However, when a relapse occurs, the outcome, as based on our two observations, is poor. The decrease in DFS in patients with more advanced stage HD treated without radiotherapy as reported by Lobo-Sanahuja et al. [16] using CVPP (cyclophosphamide, vinblastine, procarbazine, prednisone)/EBO (epirubicin, bleomycin, and vincristine) has not been seen in our patients, but as only one of our patients was CS IV, we cannot make a conclusion for this category of patients.

In our study to date only one child with initially CS I and another child with CS II have relapsed. One wonders if pathologic staging would have improved these results. We did not perform laparotomy with splenectomy, as overwhelming postsplenectomy septicemia and bowel obstruction are serious complications [33,34]. A major bias in our cohort due to an artificially low number of patients with high stages of HD by omitting laparotomy is not likely considering the data of Pao and Kun [35]. In 201 children they showed that 1 of 32 cases with CS I and 25 of 123 cases with CS II were upstaged to stage III after laparotomy; on the other hand, their data showed downstaging in about half of the children with CS III [35].

Complications due to the use of bleomycin and adriamycin treatment could not be demonstrated by ultrasound examination of the heart and COD, although follow-up is short and these may not be the most sensitive tests to use. Comparison with other reports considering pulmonary function are favorable, however, our group is too small to draw firm conclusions. Late effects may become evident at longer follow-up. Anthracyclin-

related severe sequelae, even in low dosages, are well known [36]. Our preliminary data on gonadal function are encouraging, although in several patients this cannot be assessed as they did not reach puberty yet. Nine of the 10 patients have normal endocrine function by laboratory tests. In one patient increased gonadotropic hormones may possibly indicate gonadal dysfunction. Thyroid function was also decreased in this patient. This was, however, the only child who received radiotherapy for what proved to be a thymic cyst. It should be emphasized that reproductive capacity can ultimately only be ascertained by a pregnancy. Although boys were offered semen analysis, many adolescent patients are reluctant to proceed with this testing. No statement can be made to the incidence of secondary solid tumors, which occur more than 10 years following treatment [29,33].

We conclude that 6 cycles ABVD/MOPP treatment without radiotherapy gives a high cure rate in our patients with HD and short-term side effects seem low. However, larger studies are needed to confirm these findings.

## REFERENCES

1. Prosnitz LR, Lawson JP, Friedlaender GE, et al.: Avascular necrosis of bone in Hodgkin's disease patients treated with combined modality therapy. *Cancer* 47:2793-2797, 1981.
2. Constine LS, Donaldson SS, McDougal R, et al.: Thyroid dysfunction after radiotherapy in children with Hodgkin's disease. *Cancer* 53:878-883, 1984.
3. Ramona M, Chapman MC, Sutcliffe SB, et al.: Male gonadal dysfunction in Hodgkin's disease. *JAMA* 245:1323-1328, 1981.
4. Sherins RJ, Olweny CL, Ziegler JL: Gynecomastia and gonadal dysfunction in adolescent boys treated with combination chemotherapy for Hodgkin's disease. *N Engl J Med* 299:12-16, 1978.
5. Sullivan M: Hodgkin's disease in children. *Hematol Oncol Clin North Am* 1:603-620, 1987.
6. Olweny CLM, Katongole-Mbidde E, Kiire C, et al.: Childhood's Hodgkin's disease in Uganda. *Cancer* 42:787-792, 1978.
7. Behrendt H, Van Bunningen BNFM, Van Leeuwen EF: Treatment of Hodgkin's disease in children with and without radiotherapy. *Cancer* 59:1870-1873, 1987.
8. Coleman CN: Secondary malignancy after treatment of Hodgkin's disease: An evolving picture. *J Clin Oncol* 4:821-824, 1986.
9. Connors TA: Antitumor alkylating agents: Cytotoxic action and organ toxicity. In Schmahl D, Kaldor JM (eds): "Carcinogenicity of Alkylating Cytostatic Drugs." Proceedings of a Symposium by the International Agency for Research on Cancer, Lyon, France, 1986.
10. Van Leeuwen FE, Chorus AMJ, Van den Belt-Dusebout AW, Hagenbeek A, Noyon R, Van Kerkhoff EHM, Pinedo HM, Somers R: Leukemia risk following Hodgkin's disease: Relation to cumulative dose of alkylating agents, treatment with teniposide combinations, number of episodes of chemotherapy, and bone marrow damage. *J Clin Oncol* 12:1063-1073, 1994.
11. Valagussa P, Santoro A, Fossati-Bellani F, Banfi A, Bonadonna G: Second acute leukemia and other malignancies following treatment for Hodgkin's disease. *J Clin Oncol* 4:830-837, 1986.
12. Santoro A, Bonfante V, Bonadonna G: Salvage chemotherapy with ABVD in MOPP resistant Hodgkin's. *Ann Intern Med* 96: 139-143, 1982.
13. Behrendt H, Brinkhuis M, Van Leeuwen EF: Treatment of child-

- hood Hodgkin's disease with ABVD without radiotherapy. *Med Pediatr Oncol* 26:244–248, 1996.
14. Carbone PP, Kaplan HS, Musshoff K, Smither DW, Tubiana M: Report of the committee on Hodgkin's disease staging classification. *Cancer Res* 31:1860–1861, 1971.
  15. Schellong G, Brämswig JH, Hörnig-Franz I: Treatment of children with Hodgkin's disease—Results of the German Pediatric Oncology Group. *Ann Oncol* 3:S73–76, 1992.
  16. Lobo-Sanahuja F, Garcia I, Barrantes JC, Barrantes M, Gonzales M, Jimenez R: Pediatric Hodgkin's disease in Costa Rica: Twelve years experience of primary treatment by chemotherapy alone, without staging laparotomy. *Med Pediatr Oncol* 22:398–403, 1994.
  17. Medeiros LJ, Greiner TC: Hodgkin's disease. *Cancer* 75:357–369, 1995.
  18. Miller RW, Young JL, Novakovic B: Childhood cancer. *Cancer* 75:395–405, 1994.
  19. Hunger SP, Link MP, Donaldson S: ABVD/MOPP and low-dose involved-field radiotherapy in pediatric Hodgkin's disease: The Stanford experience. *J Clin Oncol* 10:2160–2166, 1994.
  20. DeVita VT, Serpick A, Carbone PP: Combination chemotherapy in the treatment of advanced Hodgkin's disease. *Ann Intern Med* 73:881–895, 1970.
  21. Ziegler JL, Bluming AZ, Fass L, Margrath IT, Templeton AC: Chemotherapy of childhood Hodgkin's disease in Uganda. *Lancet* 11:679–682, 1972.
  22. Ekert H, Waters KD, Smith PJ, Toogood I, Mauger D: Treatment with MOPP or ChlVPP chemotherapy only for all stages of childhood Hodgkin's disease. *J Clin Oncol* 6:1845–1850, 1988.
  23. Sackman-Muriel F, Maschio M, Santarelli MT, Pavlovsky S: Hodgkin's disease in children. Results for Hodgkin's disease in childhood. *Cancer Treat Res* 41:271–275, 1989.
  24. Bader SB, Weinstein H, Mauch P, Silver B, Tarbell NJ: Pediatric stage IV Hodgkin's disease. Long-term survival. *Cancer* 72:249–255, 1993.
  25. Goldie JH, Coltman A, Gudauskas GA: Rationale for the use of alternating cross resistant chemotherapy. *Cancer Treat Rep* 66:439–449, 1982.
  26. Bonadonna G, Zucali R, Monfardini S, et al.: Combination chemotherapy of Hodgkin's disease with adriamycin, bleomycin, vinblastine and imidazole carboxamide versus MOPP. *Cancer* 36:252–259, 1975.
  27. Santoro A, Bonadonna G, Valagussa P, et al.: Long term results of combined chemotherapy-radiotherapy approach in Hodgkin's disease: Superiority of ABVD plus radiotherapy versus MOPP plus radiotherapy. *J Clin Oncol* 5:27–37, 1987.
  28. Oza AM, Rohatiner AZS, Lister TA: Chemotherapy of Hodgkin's disease. *Balliere's Clin Haematol* 4:131–156, 1991.
  29. Donaldson SS, Kaplan HS: Complications of treatment of Hodgkin's disease in children. *Cancer Treat Rep* 66:977–989, 1982.
  30. Henry-Amar M: Quantitative risk of second cancer in patients in first complete remission from early stages of Hodgkin's disease. *Natl Cancer Inst Monogr* 6:65–72, 1988.
  31. Weiner MA, Leventhal BG, Marcus R, Brecher M, Ternberg J, Behm FG, et al.: Intensive chemotherapy and low-dose radiotherapy for the treatment of advanced-stage Hodgkin's disease in pediatric patients: A Pediatric Oncology Group Study. *J Clin Oncol* 9:1591–1598, 1991.
  32. DaCunha MF, Meistrich M, Cundiff JH, Hagemester FB, Velasquez WS, McLaughlin P, Riggs SA, Cabanillas FF, Salvador PG: Recovery of spermatogenesis after treatment for Hodgkin's: Limiting dose of MOPP chemotherapy. *J Clin Oncol* 2:571–577, 1984.
  33. Rosenberg SA: Exploratory laparotomy and splenectomy for Hodgkin's disease: A commentary. *J Clin Oncol* 6:574–575, 1988.
  34. Hancock SL, Hoppe RT, Horning SJ, Rosenberg SA: Intercurrent death after Hodgkin's disease in radiotherapy and adjuvant MOPP trials. *Ann Intern Med* 109:183–189, 1988.
  35. Pao WJ, Kun LE: Hodgkin's disease in children. *Hematol/Oncol Clin North Am* 3:345–365, 1989.
  36. Lipshultz SE, Colan SD, Gelber RD, Perez-Atayde AR, Sallan SE, Sanders SP: Late cardiac effects of doxorubicin therapy for acute lymphoblastic leukemia in childhood. *N Engl J Med* 324:808–815, 1991.