



## UvA-DARE (Digital Academic Repository)

### Helicobacter pylori and Epstein-Barr virus infection and the p53 tumour suppressor pathway in gastric stump cancer compared with carcinoma in the non-operated stomach

Baas, I.O.; van Rees, B.P.; Musler, A.R.; Craanen, M.E.; Tytgat, G.N.J.; van den Berg, F.M.; Offerhaus, G.J.A.

**DOI**

[10.1136/jcp.51.9.662](https://doi.org/10.1136/jcp.51.9.662)

**Publication date**

1998

**Published in**

Journal of clinical pathology

[Link to publication](#)

**Citation for published version (APA):**

Baas, I. O., van Rees, B. P., Musler, A. R., Craanen, M. E., Tytgat, G. N. J., van den Berg, F. M., & Offerhaus, G. J. A. (1998). Helicobacter pylori and Epstein-Barr virus infection and the p53 tumour suppressor pathway in gastric stump cancer compared with carcinoma in the non-operated stomach. *Journal of clinical pathology*, 51, 662-666.  
<https://doi.org/10.1136/jcp.51.9.662>

**General rights**

It is not permitted to download or to forward/distribute the text or part of it without the consent of the author(s) and/or copyright holder(s), other than for strictly personal, individual use, unless the work is under an open content license (like Creative Commons).

**Disclaimer/Complaints regulations**

If you believe that digital publication of certain material infringes any of your rights or (privacy) interests, please let the Library know, stating your reasons. In case of a legitimate complaint, the Library will make the material inaccessible and/or remove it from the website. Please Ask the Library: <https://uba.uva.nl/en/contact>, or a letter to: Library of the University of Amsterdam, Secretariat, Singel 425, 1012 WP Amsterdam, The Netherlands. You will be contacted as soon as possible.

UvA-DARE is a service provided by the Library of the University of Amsterdam (<https://dare.uva.nl>)

# *Helicobacter pylori* and Epstein-Barr virus infection and the p53 tumour suppressor pathway in gastric stump cancer compared with carcinoma in the non-operated stomach

Inge O Baas, Bastiaan P van Rees, Alex Musler, Mike E Craanen, Guido N J Tytgat, Frank M van den Berg, G Johan A Offerhaus

## Abstract

**Aim**—To evaluate similarities and differences between gastric stump cancer and conventional carcinoma in the non-operated stomach.

**Methods**—26 stump carcinomas were compared with 24 conventional stomach cancers. Stage, histological type, and demographics were comparable in the two groups. Expression of p53 and p21-Waf1/Cip1 was evaluated by immunohistochemical staining. *Helicobacter pylori* infection was evaluated by examining haematoxylin-eosin stained slides and immunohistochemistry. Epstein-Barr virus infection was evaluated by RNA in situ hybridisation.

**Results**—Expression of p53 and p21-Waf1/Cip1 was similar in both groups and positive in more than half of the patients. *H. pylori* infection was observed in six stump carcinomas and 17 conventional carcinomas in the intact stomach ( $p < 0.01$ ). RNA in situ hybridisation (EBER1-ISH) for Epstein-Barr virus was positive in nine stump carcinomas and two carcinomas in the non-operated stomach ( $p < 0.05$ ).

**Conclusions**—There appear to be aetiological differences between stump carcinoma and cancer in the intact stomach. Further study of these differences may improve our understanding of gastric carcinogenesis in general.

(J Clin Pathol 1998;51:662-666)

Keywords: stomach; gastric stump; carcinoma; p53; *H. pylori*; Epstein-Barr virus

Despite its declining incidence, gastric cancer remains an important cause of death in the western world.<sup>1,2</sup> The prognosis of gastric carcinoma is poor, because most patients present in an advanced stage when the disease is symptomatic.<sup>3</sup> Patients with early gastric cancer have an excellent prognosis and can be detected by surveillance of high risk groups.<sup>4</sup> The natural history of the disease is not well established. Of the two distinctive types of stomach cancer, the one that is thought to be governed by environmental factors, which is referred to as intestinal type of gastric cancer,<sup>5</sup> is best understood. The intestinal type of gastric cancer is preceded by a precancerous process, characterised by precursor lesions of the gastric mucosa.<sup>6</sup> These precursor lesions

represent the morphological substrates of a multistep tumour progression model in which there is an interplay between oncogene activation and loss of tumour suppressor function, similar to the adenoma-carcinoma sequence in the colorectum.<sup>7,8</sup>

Remote partial gastrectomy is a premalignant condition.<sup>9,10</sup> After peptic ulcer surgery, patients enter an accelerated neoplastic process that looks very similar to that proposed for the intestinal type of gastric cancer in the non-operated stomach. There is a steady increase in the gastric cancer risk with increasing length of the postoperative interval.<sup>11</sup> In the long term after partial gastrectomy, atrophy with intestinal metaplasia and dysplasia becomes more frequent and these changes resemble the precursors of the intestinal type of stomach cancer.<sup>12,13</sup> Also the cell proliferation kinetics of the premalignant mucosa in the gastric remnant are similar to those observed in the non-operated stomach.<sup>14</sup> Therefore we have postulated that gastric stump cancer could provide a suitable model to study the molecular genetics of gastric carcinogenesis in general.<sup>15</sup>

The specific molecular changes accompanying the gastric dysplasia-carcinoma sequence are less well defined than in the colorectum.<sup>7,8,16-18</sup> Alterations of the p53 tumour suppressor gene, associated with the transition of an in situ into an invasive neoplasm in the colorectum, probably plays a similar role in the stomach.<sup>19,20</sup> Disruption of the p53 protein function can be detected by immunohistochemistry, since it is mostly accompanied by a prolonged half life of the protein.<sup>21</sup> Wild-type p53 protein, but not the mutant p53 protein, binds specifically to DNA and acts as a transcription factor for several genes, including p21-Waf1/Cip1, a potent cyclin dependent kinase inhibitor that controls progression through the cell cycle.<sup>22,23</sup> Immunohistochemistry for expression of p21-Waf1/Cip1 therefore forms another indicator of the integrity of the p53 tumour suppressor pathway, even though its expression appears not exclusively dependent on intact p53 function.<sup>24,25</sup>

*Helicobacter pylori* infection is a well established carcinogenic factor in the non-operated stomach, but its role in carcinogenesis in the gastric remnant is unknown, and has not been studied in detail.<sup>7,8</sup> Recently, it has been suggested that Epstein-Barr virus (EBV) plays

Academic Medical Centre, University of Amsterdam, Amsterdam, The Netherlands  
Department of Pathology

I O Baas  
B P van Rees  
A Musler  
F M van den Berg  
G J A Offerhaus

Department of Gastroenterology  
M E Craanen  
G N J Tytgat

Correspondence to:  
Dr I O Baas, Department of Pathology, Academic Medical Centre, University of Amsterdam, PO Box 22700, 1100 DE Amsterdam, The Netherlands; email: i.o.baas@amc.uva.nl

Accepted for publication  
13 May 1998

Table 1 Comparison of baseline characteristics in the group of gastric stump carcinomas and conventional primary carcinomas in the intact stomach

	Stump carcinoma (n = 26)	Primary carcinoma (n = 24)
Sex		
Male	20	12
Female	6	12
Age (mean, years)	64.8	66.8
Tumour stage		
Early	12	9
Advanced	14	15
Morphological classification		
Intestinal	19	16
Diffuse	2	4
Mixed	5	4

a role in gastric carcinogenesis, particularly in gastric stump cancer.<sup>26-29</sup> In addition, binding of one of the EBV encoded proteins to p53 has been found to inactivate this tumour suppressor pathway.<sup>30</sup>

In the present study we have compared gastric stump cancer with stomach cancer in the non-operated stomach for these various genotypic and phenotypic molecular markers (p53, p21-Waf1/Cip1, *H pylori*, EBV) to further explore the possible similarities and differences between these two types of tumour.

### Methods

Twenty six stump cancers from the Amsterdam postgastrectomy cohort—of which 10 were detected by the screening programme—were available for study.<sup>31 32</sup> These were compared with 24 conventional gastric cancers in the non-operated stomach, which had a similar stage (early carcinoma defined as limited to the mucosa or submucosa) and a comparable morphology according to the Lauren classification.<sup>5</sup> The patients' age was the same in the two groups, but there was a male predominance among the stump carcinomas compared with the primary cancers. The demographic and other features are listed in table 1. Importantly, carcinomas of the cardia were not included in the study, and all the primary carcinomas were located in the distal

stomach; the stump cancers were located near the gastro-enterostoma.

Formalin fixed and paraffin embedded tissue blocks of the tumour and environment were cut into 5 µm sections for haematoxylin-eosin (H&E) staining, immunohistochemistry, and in situ hybridisation. Typing and staging of the tumours was done by histopathological examination of the H&E stained slides.

### IMMUNOHISTOCHEMISTRY

Immunohistochemistry for p53 and p21-Waf1/Cip1 was performed as described previously.<sup>21 23 25</sup> DO-7 (Dako, Glostrup, Denmark) was used as primary antibody to detect the p53 protein (fig 1), Ab-1 (Oncogene Science, Cambridge, Massachusetts, USA) as primary antibody to detect p21-Waf1/Cip1. As in previous studies, nuclear staining of at least 10% of the tumour cell population was regarded as positive. Tumours were scored for positivity by three independent observers without knowledge of the clinical data. Where there was disagreement, consensus was reached using a multiheaded microscope.

### RNA IN SITU HYBRIDISATION FOR EBV DETECTION

Sections (5 µm) were deparaffinised to 70% ethyl alcohol and directly treated with 0.5 M EDTA, pH 8.0, for 15 minutes at 37°C, followed by incubation with 5 µg/ml proteinase K (Boehringer Mannheim, Mannheim, Germany) in TE buffer (TE = 100 mM Tris-HCl, pH 7.5, 50 mM EDTA) for 30 minutes at 37°C. Sections were rinsed in 70% ethyl alcohol, dehydrated in 96% ethyl alcohol, and air dried.

Probe mixture (12 µl/slide) of 0.45 M NaCl, 45 mM sodium citrate, pH 7.0, 25% formalin, 10× Denhardt's solution, 10% dextran sulphate, 1% Triton X100, and 0.1% sodium dodecyl sulphate (SDS), containing 1 µg/ml fluorescein labelled EB1f oligonucleotide, was applied to the sections and overlaid with an 18 × 18 mm glass coverslip. The EB1f probe is a newly designed 30 mer antisense oligonucleotide (5'-CTAGCAAACCTCTAGGGCAGCGTAGGTCC-3') with fluorescein molecules at both 3' and 5' ends which hybridises with the EBER1 EBV infected cell nuclear RNA molecules. Results with this probe are the same as a detection kit (Dako) against EBER1 nuclear RNA molecules when tested on lymphomas. Hybridisation was for 18 hours at 37°C in a sealed humidified container.

All subsequent steps were performed at room temperature and washing in between steps was done with PBST (phosphate buffered saline, 0.05% Tween20). Cover slips were slid off by gently submerging the sections sideways in PBST, and sections were then rinsed thoroughly in PBST. Endogenous peroxidase activity was blocked with 0.3% H<sub>2</sub>O<sub>2</sub> in PBST containing 1% sodium azide for 15 minutes.

The fluorescein label of the hybridised probe molecules was detected by subsequent incubation for 30 minutes with rabbit anti-FITC (Dako; 1/400 diluted in PBST containing 10% human AB serum), biotinylated swine anti-rabbit immunoglobulins (Dako; 30 minutes,

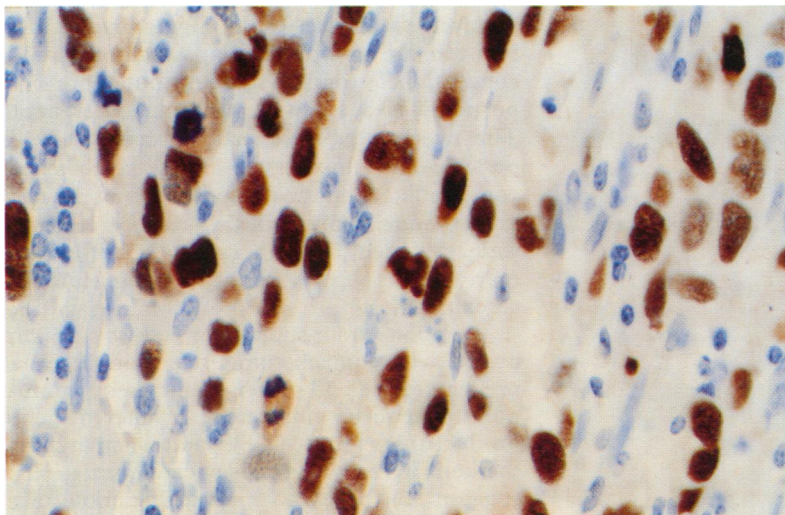


Figure 1 Immunohistochemical detection of p53 tumour suppressor gene product with monoclonal antibody DO-7 in a gastric stump carcinoma (SA23). Typical nuclear staining is confined to the carcinoma cells.

Table 2 p53, p21-Waf1/Cip1, *H pylori* (HP), and Epstein-Barr virus (EBV) positivity in stump cancers compared with carcinomas of the non-operated stomach

	Stump carcinoma (n = 26)	Primary carcinoma (n = 24)
p53 +/-	14/12	14/10
p21-Waf1/Cip1 +/-	20/6	17/7
HP +/-**	6/20	17/7
EBV +/-*	9/17	2/22

\*\*p<0.01; \*p<0.05.

diluted 1/500) and avidin biotinylated horseradish peroxidase complex (ABC; Dako; 30 minutes, diluted 1/200). Staining was for three to seven minutes in 50 mM TRIS buffer (pH = 7.5) with 0.03% H<sub>2</sub>O<sub>2</sub> and 0.1% diaminobenzidine (DAB) as chromogen. After rinsing in tap water, nuclei were counterstained with haematoxylin (fig 2).

#### H PYLORI DETECTION

Assessment for the presence of *H pylori* was done by histopathological examination of the H&E stained sections. To enhance the sensitivity of our study we subsequently performed immunohistochemistry on cases that were negative for *H pylori*. Antigen enhancement was done by boiling in 0.1 M sodium citrate (pH 6.0) for 10 minutes. The B 471 polyclonal rabbit anti-*H pylori* antibody (Dako) was used as a primary antibody. Subsequently, the sections were incubated with biotinylated swine anti-rabbit secondary antibody and avidin biotinylated horseradish peroxidase complex (both Dako). Finally, staining was done with DAB as a chromogen.

#### STATISTICS

Comparison of frequencies among the different groups was tested for statistical significance by a conventional Fisher's exact test. Statistical significance levels were set at 5% (two sided).

#### Results

The results of our analyses are summarised in table 2.

p53 Immunohistochemistry was positive in 14 stump carcinomas (54%) and 14 conventional carcinomas (58%) (fig 1); p21-Waf1/

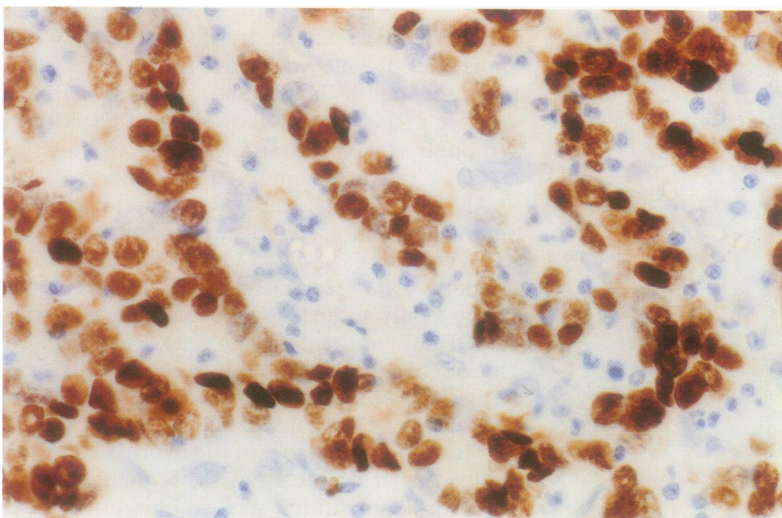


Figure 2 RNA in situ hybridisation with EBER1 specific EB1f oligonucleotide probe in a gastric carcinoma (SE8). Typical nuclear staining is only observed in carcinoma cells; the relatively dense lymphocytic infiltrate does not show positive staining.

Table 3 Relation between Epstein-Barr virus (EBV) and p53, according to stage in the EBV positive stump carcinomas and carcinomas in the intact stomach

	Stump carcinoma		Primary carcinoma	
	Early	Advanced	Early	Advanced
EBV+ and p53- (n = 4)	3	1	0	0
EBV+ and p53+ (n = 7)	5	0	1	1

Cip1 immunohistochemistry was positive in 20 stump carcinomas (77%) and 17 conventional stomach cancers (71%). There was no inverse correlation between p53 positivity and p21-Waf1/Cip1 expression in any of the two groups, nor was a correlation present with tumour type or extension of the tumour and immunohistochemistry for p53 or p21-Waf1/Cip1.

The prevalence of *H pylori* was significantly ( $p < 0.01$ ) greater in conventional stomach cancers (17 positive cancers, 71%) than in the stump carcinomas (six positive carcinomas, 23%).

Non-radioactive RNA in situ hybridisation for EBV was positive in nine stump carcinomas (35%) and two conventional stomach carcinomas (8%) ( $p < 0.05$ ) (fig 2). The staining was in general strongly positive, with a specific nuclear pattern limited to the epithelial tumour cells. There was heterogeneity, with only parts of the tumour strongly positive. The two EBV positive conventional cancers were an early and an advanced carcinoma; both occurred in male patients. The EBV positive stump cancers comprised eight early and one advanced carcinoma. One EBV positive early stump cancer occurred in a female patient. The other EBV positive stump carcinomas (seven early and one advanced) occurred in male patients. None of the EBV positive carcinomas was a typical lymphoepithelioma, but in some cases there was a relatively dense infiltrate (fig 2). There was no correlation between p53 positivity and EBV positivity (table 3).

#### Discussion

Although the numbers in the present study are relatively small, the results suggest similarities between the group of stump carcinomas and conventional stomach cancers, but more importantly also a few remarkable differences. The two groups were matched as closely as possible for tumour type and stage to avoid confounding, and the demographics of the two groups were comparable. Cardia carcinomas were excluded from the study because they may form a separate entity among stomach carcinomas.

The p53 tumour suppressor pathway is often involved in stomach tumour formation.<sup>20</sup> Expression of the p53 protein detected by immunohistochemistry indicates an altered gene product that is more stable, and positivity was the same in the two groups of carcinomas. This suggests, but does not prove, that molecular change of the p53 tumour suppressor gene is the same, and the similarity in expression of p21-Waf1/Cip1—an intermediate in the p53

tumour suppressor pathway—lends support to this notion.<sup>24-33</sup> It is our experience that immunohistochemistry suffices as a first screening test and on the basis of the results one can then decide to do further analyses.<sup>21</sup> However, sequencing of the p53 gene would be needed for precise comparison of the molecular genetic changes in p53 in the two groups.

*H pylori* infection was initially assessed by evaluation of the available H&E stained slides of the gastric stump cancers and primary gastric carcinomas. This obviously is not the optimal assessment of differences in infection rate between the two groups and such differences should be interpreted cautiously. Negative cases were, however, also stained immunohistochemically against *H pylori* and only a few extra positives were found, which did not change the comparison between the two groups. Bile reflux may provide an explanation for the observed low prevalence of *H pylori* in the stomach epithelium bordering stump carcinomas (table 2). Bile salts seem to have a bactericidal effect on *H pylori* and after a Billroth resection *H pylori* disappears rapidly from the gastro-enterostoma.<sup>34</sup> Since the role of *H pylori* in the carcinogenesis of the intact stomach has now been accepted, a possible difference at the gastro-enterostoma anastomosis—a well established premalignant condition—is intriguing and needs further study.

Epstein-Barr virus involvement in gastric carcinoma has been demonstrated previously by the presence of EBV genome and EBV encoded small RNA (EBER) in the carcinoma cells, monoclonal proliferation of EBV infected carcinoma cells, and raised antibody titres.<sup>26-29</sup> Our study shows that the prevalence of EBV involvement among gastric carcinomas may be more prominent in gastric remnant cancer, and this has been suggested before.<sup>27</sup> Whether this implies a direct causal relation cannot be concluded from these results, however. It might be that the virus infection is related to the baseline disease (previous peptic ulcer) for example and not to cancer. Further research will be necessary to clarify this question. In situ hybridisation for EBER1 applied to paraffin sections revealed 35% positivity in stump cancers versus 8% in primary cancers. The presence of EBV in the carcinoma cells implies that the EBV encoded EBNA-5 protein (alternatively designated EBNA-LP), which can form a molecular complex with the p53 tumour suppressor protein,<sup>30</sup> may cause a prolonged lifespan of wild type p53 in the EBV infected stump carcinomas, resulting in positive p53 immunohistochemistry. However, in confirmation of published observations<sup>26</sup> and as shown in table 3, p53 positivity was not correlated with EBV positivity in stump carcinomas. Previous reports on involvement of EBV in carcinogenesis in the gastric stump were from studies performed in Taiwan and Japan.<sup>26-29</sup> To our knowledge this study is the first to establish an increased prevalence of EBV in gastric stump cancers in the western world, suggesting that EBV infection is a global phenomenon, independent of geographical

area. The question of why EBV preferentially infects (pre)malignant stomach epithelial cells in the vicinity of the Billroth junction of stomach and duodenum remains obscure. One possible explanation may be bile reflux into the stomach which could act as a cofactor mediating EBV infection of the epithelial cells, for instance by inducing fusion of EBV carrying B cells and epithelial cells. There was no correlation with tumour type.

The EBV positive carcinomas were predominantly of the early type, which is consistent with previous observations that EBV infection perhaps occurs early in carcinogenesis. As in previous reports, in our present study EBV positivity was strongly correlated with gender, all positive cases except one being males. Although there was a more striking male predominance in the stump carcinoma group, it seems unlikely that this gender difference could be the sole explanation of our observations.

In summary then, two important differences were observed between gastric stump carcinomas and conventional primary stomach cancers. *H pylori* infection, which is associated with the occurrence of cancer in the intact stomach, appears rare near the anastomosis of the gastric remnant, the site prone to carcinogenesis. In contrast, EBV infection appears more common in gastric stump cancer, not only in Asian countries, but in the western world as well. Further studies of these differences may help us gain a better understanding of gastric carcinogenesis in general.

We thank Dr A C Tersmette, PhD, for statistical assistance and Ms Gina Beekelaar for preparing the manuscript. Supported by NWO grant 950-10-643.

- Howson CP, Hiyama T, Wynders EL. The decline in gastric cancer: epidemiology of an unplanned triumph. *Epidemiol Rev* 1986;8:1-27.
- La Vecchia C, Luccini F, Negri E, et al. Trends of cancer mortality in Europe, 1955-1989. I. Digestive sites. *Eur J Cancer* 1992;28:132-5.
- Saini A, Waxman J. Chemotherapy for gastric cancer. *Gut* 1992;33:1153-4.
- Murayama K, Okabayashi K, Kinoshita T. The progress in gastric cancer surgery in Japan and its limits of radicality. *World J Surg* 1987;11:418-26.
- Lauren P. The two histological main types of gastric carcinoma: diffuse and so-called intestinal-type carcinoma: a pathological classification. *Cancer* 1977;39:2475-85.
- Correa P. Precursors of gastric and esophageal cancers. *Cancer* 1982;50:2554-65.
- Goldstone AR, Quirke P, Dixon MF. Helicobacter pylori infection and gastric cancer. *J Pathol* 1996;179:129-37.
- Solcia E, Fiocca R, Luinetti O, et al. Intestinal and diffuse gastric cancers arise in a different background of Helicobacter pylori gastritis through different gene involvement. *Am J Surg Pathol* 1996;20(suppl 1):S8-22.
- Caygill CPJ, Hill MJ, Kirkham JS, et al. Mortality from gastric cancer following gastric surgery for peptic ulcer. *Lancet* 1986;i:929-31.
- Offerhaus GJA, Tersmette AC, Huibregtse K, et al. Mortality caused by stomach cancer after remote partial gastrectomy for benign conditions: 40 years of follow up of an Amsterdam cohort of 2633 postgastrectomy patients. *Gut* 1988;29:1588-90.
- Tersmette AC, Goodman SN, Offerhaus GJA, et al. Multivariate analysis of the risk of gastric cancer after peptic ulcer surgery in an Amsterdam cohort of postgastrectomy patients. *Am J Epidemiol* 1991;134:14-21.
- Offerhaus GJA, Stadt J van de, Huibregtse K, et al. Endoscopic screening for malignancy in the gastric remnant. The clinical significance of dysplasia in gastric mucosa. *J Clin Pathol* 1984;37:748-54.
- Offerhaus GJA, Stadt J van de, Huibregtse K, et al. The mucosa of the gastric remnant harboring malignancy. Histological findings in the biopsies of 504 asymptomatic patients 15-46 years after partial gastrectomy with the emphasis on non-malignant lesions. *Cancer* 1989;64:698-703.

- 14 Offerhaus GJA, Stadt J van de, Samson G, et al. Cell proliferation kinetics in the gastric remnant. *Eur J Cancer Res Clin Oncol* 1985;21:73-9.
- 15 Offerhaus GJA. Gastric stump cancer: lessons from old specimens. *Lancet* 1994;343:66-7.
- 16 Uchino S, Noguchi M, Ochiai A, et al. p53 Mutation in gastric cancer: a genetic model for carcinogenesis is common to gastric and colorectal cancer. *Int J Cancer* 1993;54:759-64.
- 17 Wright PA, Williams GT. Molecular biology and gastric carcinoma. *Gut* 1993;34:145-7.
- 18 Correa P. A human model of gastric carcinogenesis. *Cancer Res* 1988;48:3554-60.
- 19 Baker SJ, Preisinger AC, Jessup JM, et al. p53 Gene mutations occur in combination with 17p allelic deletions as late events in colorectal tumorigenesis. *Cancer Res* 1990;50:7717-22.
- 20 Craanen ME, Blok P, Dekker W, et al. Chronology of p53 protein accumulation in gastric carcinogenesis. *Gut* 1995;36:848-52.
- 21 Baas IO, Mulder JWR, Offerhaus GJA, et al. An evaluation of six antibodies for immunohistochemistry of mutant p53 gene product in archival colorectal neoplasms. *J Pathol* 1994;172:5-12.
- 22 Kern SE, Kinzler KW, Bruskin A, et al. Identification of p53 as a sequence-specific DNA-binding protein. *Science* 1991;252:1708-11.
- 23 El-Deiry WS, Tokino T, Velculescu VE, et al. Waf1, a potential mediator of p53 tumor suppression. *Cell* 1993;75:817-25.
- 24 El-Deiry WS, Takahashi T, Waldman T, et al. Topological control of p21 WAF/CIP1 expression in normal and neoplastic tissue. *Cancer Res* 1995;55:2910-19.
- 25 Slebos RJC, Baas IO, Clement MJ, et al. Clinical and pathological associations with p53 tumour-suppressor gene mutations and expression of p21<sup>WAF1/CIP1</sup> in colorectal carcinoma. *Br J Cancer* 1996;74:165-71.
- 26 Harn HJ, Chang JY, Wang MW, et al. Epstein-Barr virus-associated gastric adenocarcinoma in Taiwan. *Hum Pathol* 1995;26:267-71.
- 27 Tokunaga M, Uemura Y, Tokudome T, et al. Epstein-Barr virus related gastric cancer in Japan: a molecular patho-epidemiological study. *Acta Pathol Japon* 1993;43:574-81.
- 28 Imai S, Koizumi S, Sugiura M, et al. Gastric carcinoma: monoclonal epithelial malignant cells expressing Epstein-Barr virus latent infection protein. *Proc Natl Acad Sci USA* 1994;91:9131-5.
- 29 Tokunaga M, Land CE, Uemura Y, et al. Epstein-Barr Virus in gastric carcinoma. *Am J Pathol* 1993;143:1250-4.
- 30 Szekeley L, Selivanova G, Magnusson KP, et al. EBNA-5, an Epstein-Barr virus-encoded nuclear antigen, binds to the retinoblastoma and p53 proteins. *Proc Natl Acad Sci USA* 1993;90:5455-9.
- 31 Tersmette AC, Offerhaus GJA, Giardiello FM, et al. Longterm prognosis of partial gastrectomy for benign conditions: survival and smoking related death of 2633 Amsterdam postgastrectomy patients followed since surgery between 1931 and 1960. *Gastroenterology* 1991;101:148-53.
- 32 Offerhaus GJA, Tersmette AC, Giardiello FM, et al. Evaluation of endoscopy for early detection of gastric stump cancer. *Lancet* 1992;340:33-5.
- 33 Baas IO, Berg FM van den, Mulder JWR, et al. Potential false positive results with antigen enhancement for immuno-histochemistry of the p53 gene product in colorectal neoplasms. *J Pathol* 1996;178:264-7.
- 34 Offerhaus GJA, Rieu PNM, Jansen JBMJ, et al. Prospective comparative study of the influence of bile reflux on human mucosal histology and Campylobacter pylori infection. *Gut* 1989;30:1552-7.