



UvA-DARE (Digital Academic Repository)

Anal intraepithelial neoplasia in HIV+ men

Richel, O.

Publication date
2014

[Link to publication](#)

Citation for published version (APA):

Richel, O. (2014). *Anal intraepithelial neoplasia in HIV+ men.*

General rights

It is not permitted to download or to forward/distribute the text or part of it without the consent of the author(s) and/or copyright holder(s), other than for strictly personal, individual use, unless the work is under an open content license (like Creative Commons).

Disclaimer/Complaints regulations

If you believe that digital publication of certain material infringes any of your rights or (privacy) interests, please let the Library know, stating your reasons. In case of a legitimate complaint, the Library will make the material inaccessible and/or remove it from the website. Please Ask the Library: <https://uba.uva.nl/en/contact>, or a letter to: Library of the University of Amsterdam, Secretariat, Singel 425, 1012 WP Amsterdam, The Netherlands. You will be contacted as soon as possible.

Chapter



Topical 5-fluorouracil treatment of anal intraepithelial neoplasia in HIV+ men

Olivier Richel, Ulrike Wieland, Henry J.C. de Vries, Norbert H. Brockmeyer,
Carel J.M. van Noesel, Anja Potthoff, Jan M. Prins, Alexander Kreuter

British Journal of Dermatology. 2010 Dec;163(6):1301-7.

Abstract

Background Anal intraepithelial neoplasia (AIN), a human papillomavirus (HPV)-induced potential precursor lesion of anal cancer, is frequent among human immunodeficiency virus (HIV)-positive men who have sex with men (MSM). So far, only a few prospective studies have been performed on the topical treatment of AIN, especially at the intra-anal location. *Objectives* To evaluate the efficacy and safety of self-administered topical 5-fluorouracil (5-FU) treatment of AIN in HIV-positive MSM.

Methods High-resolution anoscopy (HRA) was performed and patients with AIN (grade 1–3) were treated with 5-FU twice weekly for a total of 16 weeks. HRA-guided lesional biopsies were repeated after 5-FU treatment for histopathological evaluation. Lesional swabs were obtained before and after treatment for HPV typing and HPV-DNA load determination of the high-risk types HPV16, 18, 31 and 33. Responding patients returned 6 months after treatment for follow-up.

Results A total of 46 patients with AIN were included in this open prospective pilot study; 76% had multifocal disease and 74% had high-grade lesions (AIN 2 or 3). In an intention-to-treat analysis, 26 of 46 patients (57%) responded to 5-FU treatment. Eighteen patients (39%) had a complete clearance of AIN and eight patients (17%) had a partial response. Seventeen patients (37%) did not respond (unchanged grade of AIN in 16 patients and progression from low- to high-grade AIN in one patient). 5-FU treatment led to a significant decrease of HPV16-DNA load and cumulative high-risk HPV-DNA load in both responding and nonresponding patients. Thirty-nine patients (85%) experienced side-effects during therapy, but only two discontinued 5-FU treatment. One patient was lost to follow-up. Six months later, 50% of the complete responders had a recurrence.

Conclusions A substantial proportion of HIV-positive MSM with AIN completely cleared their lesions with topical 5-FU treatment. In those with partial response, pretreatment with topical 5-FU might facilitate subsequent ablative therapy.

Background

Since the introduction of highly active antiretroviral therapy (HAART), human immunodeficiency virus (HIV)-related morbidity and mortality have considerably decreased.¹ However, as a result of the significantly prolonged life span of HIV-positive patients in the HAART era, new causes of morbidity and mortality have become evident. Several malignancies, in particular anal carcinoma, are observed in excess among HIV-positive patients. Between the early 1990s and 2001–2004, the incidence of anal cancer in HIV-positive individuals has risen from 11–19 per 100 000 in the pre-HAART era to 40–78 per 100 000 person-years in the post-HAART era.^{2,3} Particularly in HIV-positive men, annual anal cancer incidences have increased dramatically, from 11–49 to 128–144 per 100 000, and the relative risk of anal carcinoma development in HIV-positive men on HAART has been reported to be 352 times higher compared with HIV-negative men.^{4,5}

Like cervical cancer, anal cancer is causally linked to infections with high-risk α -human papillomaviruses (HPV), and is preceded by cancer precursor lesions called anal intraepithelial neoplasia (AIN).^{6–8} Increasing evidence indicates that high-grade anal dysplasia might progress to invasive anal carcinoma over time.^{7,9,10} Considering the biological similarities of cervical cancer and anal cancer, anal cytology in at-risk populations has been recommended by several research groups according to the principles of cervical screening. However, the most appropriate way to diagnose AIN is high-resolution anoscopy (HRA) followed by lesional biopsy for histopathological evaluation in the case of abnormal findings.⁶

Anal HPV infection and AIN are highly prevalent in HIV-positive men who have sex with men (MSM). Over 90% of HIV-positive MSM have anal HPV infection, and in 88% of patients, high-risk HPV is present. AIN of any grade has been reported to be present in 68–81% of HIV-positive MSM, and high-grade disease (AIN 2 or 3) in 25–52%.^{7,8,11}

As in cervical intraepithelial neoplasia (CIN), early diagnosis and treatment of AIN have been advocated to prevent malignancy.¹² Several treatment options exist for AIN, but there is a lack of controlled studies and treatment guidelines have so far not been implemented. The mainstay of AIN management is ablative or surgical treatment.^{13,14} Intra-anal dysplasia, especially in patients with extensive



circumferential disease, is a therapeutic challenge because of possible severe post-treatment side-effects such as anal stenosis, incontinence, scarring or disfiguration.¹⁴ Thus, there is a need for additional strategies in AIN management.

A promising alternative option for AIN treatment might be topical application of 5-fluorouracil (5-FU). Topical 5-FU treatment is licensed for the treatment of actinic keratosis, Bowen disease and superficial basal cell carcinoma. 5-FU is a pyrimidine analogue, which inhibits DNA synthesis through inhibition of the enzyme thymidylate synthase in neoplastic tissue.

In previous smaller pilot studies, topical 5-FU has been demonstrated to be effective in several anogenital premalignant intraepithelial lesions such as CIN, vaginal intraepithelial neoplasia (VAIN) and penile intraepithelial neoplasia (PIN).¹⁵⁻¹⁷ Considering the biological similarities between these entities and AIN, we hypothesized that topical 5-FU might be beneficial in anal dysplasia as well. The present open prospective pilot study was initiated to evaluate the efficacy and safety of topical 5-FU treatment in HIV-positive MSM with intra-anal dysplasia. Moreover, we assessed the effects of 5-FU treatment on the number of HPV types and HPV-DNA load in these patients.

Material and Methods

Patient population and baseline examination with high-resolution anoscopy

Between October 2007 and December 2008, a total of 135 HIV-positive MSM were screened for AIN at two medical centres (Amsterdam and Bochum) by using HRA, as previously described.⁷ In brief, a disposable plastic anoscope was inserted into the anal canal after the application of 5% acetic acid. HRA was performed using a conventional colposcope (Kolposkop 150 FC; Zeiss, Oberkochen, Germany). In the case of abnormal clinical findings (e.g. punctuation, mosaicism, leucoplakic lesions or neovascularization) suspicious for anal dysplasia, lesional biopsies were taken for histopathological evaluation using an endoscopic forceps (Hildyard postnasal forceps 3-5 mm; GYRUS ENT LCC, Bartlett, TN, U.S.A.). Patients with clinical signs of proctitis were screened for anal gonorrhoea and anal chlamydia infection and if present, were treated before 5-FU therapy was initiated.

Topical 5-fluorouracil treatment

In the case of histologically confirmed intra-anal dysplasia (AIN grade 1–3), topical 5-FU treatment (Efudix® cream; MEDA Pharma, Bad Homburg, Germany) was initiated for a total of 16 weeks. One gram of 5-FU cream was self-applied intra-anally by the patient twice weekly at night with a standard anal applicator for cream. During 5-FU treatment, clinical control visits with HRA were performed every 4–8 weeks depending on the side-effects of 5-FU treatment and if necessary, the frequency of 5-FU application was adjusted. In the case of strong side-effects related to 5-FU application (anal pain, strong urge to defecate), treatment was allowed to be interrupted for a week. In the case of mild side-effects (mild local irritation or minor urge to defecate), frequency of 5-FU application was allowed to be reduced to once weekly. Patients that inquired about the possibility of having sexual intercourse during the study were recommended to refrain from insertive anal intercourse during the 16-week 5-FU treatment period.

The efficacy of 5-FU treatment was assessed 4 weeks after the end of treatment. HRA was performed, and biopsies were taken from the same location as the previously diagnosed lesions. Complete response was defined as clinical and histological resolution of AIN and partial response was defined as regression from high-grade anal dysplasia (AIN 2 or 3) to low-grade AIN (AIN 1). Persisting high-grade or low-grade AIN was considered stable disease, and increase from low-grade to high-grade AIN was considered progressive disease. Nonresponding patients, i.e. those with stable disease or progressive disease, at the end of 16 weeks of 5-FU treatment were treated with a conventional ablative approach (electrocautery of residual AIN lesions).

In the case of complete or partial response, patients returned to the respective centre 6 months after the end of treatment for a final follow-up visit. At this visit, HRA was performed again with biopsies in the case of abnormal clinical findings. Residual AIN lesions were then treated with electrocautery. All patients provided written informed consent at study entry, and the study was approved by the local ethics committee and conducted according to Declaration of Helsinki principles.



Human papillomavirus analysis

Lesional swabs for quantitative and qualitative HPV analysis were taken before and after 16 weeks of 5-FU treatment. HPV typing was performed by polymerase chain reaction (PCR) and hybridization of PCR products with type-specific probes as previously described.¹⁸ HPV16, 18, 26, 31, 33, 35, 39, 45, 51, 52, 53, 56, 58, 59, 66, 68, 73 and 82 were considered high-risk α -HPV-types. HPV6, 11, 34, 40, 42, 43, 44, 54, 55, 57, 61, 70, 71, 72, 81, 83, 84 and 89 were considered low-risk α -HPV-types.¹⁹ Real-time PCR was performed for determination of HPV-DNA loads of high-risk HPV types 16, 18, 31 and 33. HPV-DNA load was expressed as HPV-DNA copies per β -globin gene copy. If more than one quantified HPV-type was present, cumulative HPV-DNA loads were calculated.¹⁸

Statistical Analysis

Statistical analyses were performed using SPSS software (version 16.0.2 for Windows; SPSS Inc., Chicago, IL, U.S.A.). Non-normally distributed data were expressed as medians including the range. The χ^2 test was used to compare response rates between patients with multifocal and monofocal disease. HPV data were analysed using the Wilcoxon test for paired samples. Corrected values of $P < 0.05$ were considered significant.

Results

Clinical response to topical 5-fluorouracil treatment

Forty-six patients with histologically confirmed intra-anal dysplasia were included in this study. The patients' median age was 46 years (range, 32–72 years) and their median CD4+ cell count was 526 cells μL^{-1} (range, 33–1160 cells μL^{-1}); 38 (83%) patients had a plasma HIV-RNA below 40 copies mL^{-1} and 41 (89%) patients were on HAART. All patients' baseline characteristics are detailed in Table 1.

Thirty-five (76%) had multifocal disease (AIN lesions were present in two or more quadrants of the anal circumference) and 11 patients (24%) had monofocal disease (a single lesion was present in one quadrant of the anal circumference). All lesions were located at the transformation zone (close to the linea dentata). Twelve patients had AIN 1, 17 patients had AIN 2 and 17 patients AIN 3. Accordingly, 74% of all included patients had high-grade disease.

Table 1. Patients' baseline characteristics

Description	Data
No. of patients	46
Age (years)	46 (32–72) ^a
Years since first diagnosis of HIV	9 (0–25)
No. of patients on HAART	41
CD4+ cell count (cells μL^{-1})	526 (33–1160) ^a
No. of patients with plasma HIV-RNA < 40 copies mL^{-1}	38

^aMedian (range)

In an intention-to-treat analysis, 26 of 46 patients (57%) had a complete or partial response. Eighteen patients (39%) had a complete response, and eight patients (17%) had a partial response. Six of 12 (50%) patients with AIN 1, 11 of 17 (65%) patients with AIN 2, and nine of 17 (53%) patients with AIN 3 showed a complete or partial response (Table 2). There were no differences between patients with multifocal and monofocal disease in the overall (complete and partial) and complete response rates ($P=0.88$ and $P=0.82$), respectively. Overall, 17 patients (37%) did not respond. Of these nonresponding patients, 16 (35%) had a stable grade of AIN and one progressed from low- to high-grade AIN during 5-FU treatment. There was no progression to invasive anal carcinoma under 5-FU treatment. Three patients dropped out before the early evaluation, two of whom discontinued treatment because of side-effects. The third patient did finish the treatment but refused evaluation (Table 2).

Table 2. Response rates after 16 weeks of 5-fluorouracil treatment in all patients and by baseline grade of AIN

	CR	PR	SD	PD	Drop-out
All patients ($n = 46$)	18 (39%, CI 25–53%)	8 (17%, CI 6–28%)	16 (35%, CI 21–49%)	1 (2%, CI 0–6%)	3 (7%)
AIN 1 ($n = 12$)	6 (50%, CI 21–79%)	–	3 (25%, CI 0–50%)	1 (8%, CI 0–24%)	2 (17%)
AIN 2 ($n = 17$)	6 (35%, CI 12–58%)	5 (29%, CI 7–51%)	6 (35%, CI 12–58%)	–	–
AIN 3 ($n = 17$)	6 (35%, CI 12–58%)	3 (18%, CI 0–37%)	7 (41%, CI 17–65%)	–	1 (6%)

AIN, anal intraepithelial neoplasia; CR, complete response; PR, partial response; SD, stable disease; PD, progressive disease; CI, 95 % confidence interval



At the 6-month follow-up visit, two further patients were lost to follow-up. In the remaining 24 completely or partially responding patients, HRA was repeated 6 months after treatment for final follow-up examination. Eight of 16 (50%) patients who completely responded had a recurrence of their AIN, of which four had AIN 1, two had AIN 2, and two AIN 3. Of the eight patients who had initially partially responded, at the 6-month follow-up visit three had completely cleared their AIN lesions, three patients were stable (no changes in the grade of AIN) and two patients had progressed from low- to high-grade AIN. All patients with residual AIN at the last follow-up visit were treated with electrocautery.

Changes in the number of human papillomavirus (HPV) types and high-risk HPV-DNA loads

In 44 of 46 (96%) patients, HPV-analysis was performed before 5-FU treatment. Forty-three patients (98%) were HPV-DNA positive and 42 (95%) carried high-risk HPV types. Thirty-four (77%) patients had more than one high-risk HPV type. The median number of high-risk HPV types was 2.0. Overall, 33 different HPV types were found (Fig. 1).

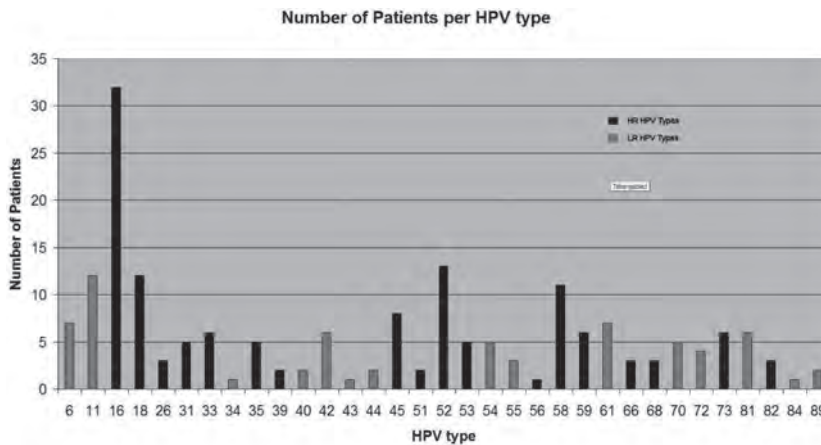


Fig 1. Human papillomavirus (HPV) types found in the study population. LR, low risk; HR, high risk

In 42 of 46 (91%) patients, anal swabs for HPV analysis were available before and after 5-FU treatment. After 5-FU treatment, for the whole group a significant decrease was found in the total number of HPV types ($P=0.03$), the number of high-risk HPV types ($P=0.03$), HPV16-DNA load ($P=0.004$) and cumulative high-

risk HPV-DNA load (evaluated for HPV16, 18, 31 and 33; $P = 0.004$). Completely and partially responding patients had a significant decrease in HPV16-DNA load and cumulative high-risk HPV-DNA load. In these patients the total number of HPV types and the number of high-risk HPV types was lower after 5-FU therapy, but the decrease was not significant. Nonresponding patients showed not only a significant decrease in HPV16-DNA load and cumulative high-risk HPV-DNA load, but also a significant decrease in the number of high-risk HPV types and the total number of HPV types. In most patients with detectable HPV18, 31 and 33 before 5-FU therapy, a (nonsignificant) decrease in HPV-DNA load was seen (Tables 3 and 4).

Table 3. HPV-DNA loads before and after 5-FU treatment

	Before treatment		After treatment		<i>P</i> -value ^a
	Median	IQR	Median	IQR	
<i>All patients</i>					
HPV16 VL (<i>n</i> = 30)	4.35	0.10–17.18	0.08	0.00–1.67	0.00 ^a
HPV18 VL (<i>n</i> = 10)	23.61	1.67–78.14	5.54	0.003–39.23	0.24
HPV31 VL (<i>n</i> = 5)	36.25	10.67–42.48	0.00	0.00–26.08	0.08
HPV33 VL (<i>n</i> = 4)	3.77	0.05–51.59	0.00	0.00–37.50	0.11
Cum. VL (<i>n</i> = 35) ^b	9.33	3.09–36.00	0.94	0.004–12.82	0.00 ^a
<i>Responding patients</i>					
HPV16 VL (<i>n</i> = 15)	0.44	0.07–9.75	0.10	0.00–1.46	0.00 ^a
HPV18 VL (<i>n</i> = 4)	31.29	7.96–162.43	48.40	10.91–133.90	1.00
HPV31 VL (<i>n</i> = 3)	36.26	–	12.75	–	0.29
HPV33 VL (<i>n</i> = 3)	7.35	–	0.00	–	0.18
Cum. VL (<i>n</i> = 17) ^b	9.75	0.93–49.74	2.29	0.13–34.39	0.04 ^a
<i>Nonresponding patients</i>					
HPV16 VL (<i>n</i> = 14)	7.68	2.33–22.28	0.01	0.01–1.71	0.04 ^a
HPV18 VL (<i>n</i> = 5)	20.6	0.72–342.24	0.004	0.00–4.51	0.08
HPV31 VL (<i>n</i> = 2)	28.38	–	–	–	0.18
HPV33 VL (<i>n</i> = 1)	–	–	–	–	–
Cum. VL (<i>n</i> = 16) ^b	12.77	3.25–31.03	0.24	0.00–3.39	0.01 ^a

HPV viral load is expressed as HPV-DNA copies per β -globin gene copy; VL, HPV-DNA viral load; –, not done; IQR, interquartile range

^aWilcoxon analysis for paired samples; ^bCumulative viral load of HPV types 16, 18, 31 and 33



Table 4. Overall number (median) of human papillomavirus (HPV) types and number of high-risk (HR) HPV types before and after 5-fluorouracil treatment

		Before tx	After tx	P-value
All patients	All HPV types (<i>n</i> = 42)	4	3	0.03 ^a
	HR HPV types (<i>n</i> = 42)	2	2	0.03 ^a
Responding patients	All HPV types (<i>n</i> = 23)	4	3	0.25
	HR HPV types (<i>n</i> = 23)	2	2	0.20
Nonresponding patients	All HPV types (<i>n</i> = 16)	4	3	0.03 ^a
	HR HPV types (<i>n</i> = 16)	2.5	2	0.02 ^a

tx, treatment; HR = high-risk; ^aWilcoxon analysis for paired samples

Side-effects

Thirty-nine patients (85%) experienced side-effects during 5-FU treatment. Seventeen patients (37%) had mild side-effects, consisting of mild local irritation or minor urge to defecate. Moderate to strong side-effects were seen in 22 patients (48%). They reported anal pain, a strong urge to defecate and/or had clinical signs of proctitis (mucosal oedema, discharge, fragile or bleeding mucosa) on HRA. Severe side-effects (acute anal bleeding or anal/rectal perforation) did not occur. Because of strong side-effects, two patients stopped 5-FU application after approximately 4 weeks of treatment; all other patients completed the 16-week treatment period. Five patients interrupted the treatment for a maximum of 3 weeks and/or reduced treatment frequency to once a week.

Discussion

Anal dysplasia is present in a high proportion of HIV-positive MSM. Accumulating evidence exists that high-grade AIN is the precursor of anal carcinoma, and progression from anal dysplasia to invasive cancer in HIV-positive MSM might occur within a short period of time.^{7,9,10} Experts therefore generally recommend treating high-grade lesions in order to prevent cancer development.¹⁴ Treatment options for AIN can be divided into ablative (e.g. electrocautery, laser therapy, surgical excision or infrared coagulation) and topical (85% trichloroacetic acid, liquid nitrogen or imiquimod) therapy.^{13,14,20} In the majority of patients, monofocal AIN lesions can be effectively treated with HRA-guided electrocautery or infrared coagulation in an outpatient setting.^{21,22}

In contrast, widespread disease remains a therapeutic challenge inasmuch as extensive surgery or electrocautery is frequently associated with considerable side-effects. Accordingly, there is need for alternative approaches.

The present prospective study is one of few studies of topical therapy of AIN. Patients with multi- and monofocal disease as well as high- and low-grade lesions were included, reflecting the entire spectrum of anal dysplasia. Several previous studies have shown that topical 5-FU is an effective treatment option for CIN, VAIN and PIN.¹⁵⁻¹⁷ However, there is a paucity of data on topical 5-FU treatment of AIN. In a case series of eight patients with anal Bowen disease treated with topical 5-FU for a total of 16 weeks, seven (88%) had cleared their lesions. The only nonresponding patient was HIV-positive.²³ In a recent poster presentation shown at the 25th International Papillomavirus Conference in 2009, Jay *et al.*²⁴ reported the results of a case series of 28 patients (25 HIV-positive, three HIV-negative; 25 men, three women) treated with topical 5-FU for diffuse high-grade AIN affecting more than 75% of the entire anal circumference. Of the 20 patients who finished at least three cycles of topical 5-FU, 15% (three of 20) had a complete response and 80% (16 of 20) had a partial response. All partially responding patients were subsequently treated successfully with infrared coagulation. Although these observations are basically in line with our results, we found a higher rate of complete responders (39%) and a lower rate of partial responders (17%). This discrepancy might be explained by differences in the application schedule (5 g of 5-FU per site twice daily in up to four cycles of 5 days on and 9 days off vs. 1 g of 5-FU twice weekly for 16 weeks) and disease severity (100% multifocal and 100% high-grade AIN vs. 76% multifocal and 74% high-grade AIN).

Comparing the complete response rates of the present study with those of previous investigations, topical 5-FU therapy is slightly less effective. For example, a retrospective study of infrared coagulation in 68 HIV-positive MSM showed a 35% complete response rate after the first, 42% after the second, and 60% after the third treatment session.²¹ Similarly, a small prospective study of infrared coagulation in 16 HIV-positive men and two HIV-positive women revealed a complete response in 62.5% of patients.²² An 'overall response' of 81% has been reported in a prospective study of surgical excision of AIN lesions in 37 men (29 were HIV-positive and eight were HIV-negative).²⁵ A



recent retrospective review of treatment with 85% trichloroacetic acid for AIN grade 1–3 in 54 men (35 were HIV-positive and 19 were HIV-negative) revealed a complete clearance of AIN 2 or AIN 3 in 32%.²⁶ A prospective study by our group of treatment with imiquimod 5% cream in 28 patients with AIN grade 1–3 demonstrated a complete response in 61% of patients.²⁷ Compared with the 5-FU results of the present study it should be considered that most studies included much less severely affected cases of AIN (e.g. 60% of patients in the study of 85% trichloroacetic acid had one or two lesions; 50% of the patients in the imiquimod study had monofocal disease and 82% had perianal lesions), whereas in the present study, 76% of patients had multifocal disease and 74% of patients had high-grade AIN.

Recurrences of anal dysplasia after treatment are common, especially in HIV-positive individuals. The recurrence rate of 50% of all complete responders in this study is slightly lower than those of other treatment options for intra-anal dysplasia (trichloroacetic acid: 75% recurrences after a mean period of 6 months; surgical excision: 79% recurrences after 12 months; infrared coagulation: 37.5% and 65% recurrences after 12 and 18 months, respectively).^{21,22,25,26} However, the follow-up period (6 months) was shorter in the present study.

To our best knowledge, only two previous studies have evaluated the changes of HPV types and HPV-DNA load in the course of AIN treatment. Infrared coagulation affected neither the number of HPV types nor the HPV-DNA loads.²² In contrast, imiquimod significantly decreased both the number of lesional HPV types and the high-risk HPV-DNA loads in patients who responded to treatment, and resulted in long-term depression of high-risk HPV-DNA loads.^{27,28} Surprisingly, the decrease of HPV16-DNA loads and cumulative high-risk HPV-DNA loads following 5-FU treatment in this study was independent of the clinical/histological response. It is tempting to speculate that, in contrast to an imiquimod-induced specific anti-HPV immune response, 5-FU decreases HPV-DNA load via unspecific mucosal cell destruction.

The results reported herein should be viewed in light of the limitations of the study. This was an uncontrolled open pilot study including a relatively small number of patients with multi- and monofocal as well as high- and low-grade AIN, and the follow-up period of 6 months was relatively short. Moreover, comparing our results with those of Jay *et al.*,²⁴ the optimal dosage and application schedule of 5-FU in AIN still needs to be determined.

In conclusion, this prospective study of topical 5-FU treatment for intra-anal dysplasia in HIV-positive MSM demonstrated a reasonable complete and partial response rate. Considering the potential side-effects, 5-FU should be used primarily in severe multifocal disease which is inaccessible to primary ablative therapy. Given the increasing number of open pilot studies of AIN treatment, a large controlled multicentre study comparing different ablative and topical treatment options (including topical 5-FU) for AIN is mandatory.



References

1. Palella FJ Jr, Delaney KM, Moorman AC *et al.* Declining morbidity and mortality among patients with advanced human immunodeficiency virus infection. *N Engl J Med* 1998; 338:853–60.
2. Patel P, Hanson DL, Sullivan PS *et al.* Incidence of types of cancer among HIV-infected persons compared with the general population in the United States, 1992–2003. *Ann Intern Med* 2008; 148:728–36
3. Piketty C, Selinger-Leneman H, Grabar S *et al.* Marked increase in the incidence of invasive anal cancer among HIV-infected patients despite treatment with combination antiretroviral therapy. *AIDS* 2008; 22:1203–11.
4. Diamond C, Taylor TH, Aboumrad T *et al.* Increased incidence of squamous cell anal cancer among men with AIDS in the era of highly active antiretroviral therapy. *Sex Transm Dis* 2005; 32:314–20.
5. Crum-Cianflone NF, Hullsiek KH, Marconi VC *et al.* Anal cancers among HIV-infected persons: HAART is not slowing rising incidence. *AIDS* 2010; 24:535–43.
6. Chiao EY, Giordano TP, Palefsky JM *et al.* Screening HIV-infected individuals for anal cancer precursor lesions: a systematic review. *Clin Infect Dis* 2006; 43:223–33.
7. Kreuter A, Potthoff A, Brockmeyer NH *et al.* Anal carcinoma in HIV-positive men: results of a prospective study from Germany. *Br J Dermatol* 2010; 162:1269–77.
8. Palefsky JM, Holly EA, Efrirdc JT *et al.* Anal intraepithelial neoplasia in the highly active antiretroviral therapy era among HIV-positive men who have sex with men. *AIDS* 2005; 19:1407–14.
9. Scholefield JH, Castle MT, Watson NF. Malignant transformation of high-grade anal intraepithelial neoplasia. *Br J Surg* 2005; 92:1133–6.
10. Berry M, Jay N, Cranston R *et al.* Progression of high-grade anal intraepithelial neoplasia to invasive anal cancer among HIV+ men who have sex with men. Poster presentation (no. 867) in session 154, 16th Conference on Retroviruses and Opportunistic Infections, Montréal, Canada, 2009.
11. Salit IE, Lytwyn A, Raboud J *et al.* The role of cytology (Pap tests) and human papillomavirus testing in anal cancer screening. *AIDS* 2010; 24:1307–13.
12. Fox PA. Human papillomavirus and anal intraepithelial neoplasia. *Curr Opin Infect Dis* 2006; 19:62–6.
13. Kreuter A, Wieland U. Human papillomavirus-associated diseases in HIV-infected men who have sex with men. *Curr Opin Infect Dis* 2009; 22:109–14.
14. Park IU, Palefsky JM. Evaluation and management of anal intraepithelial neoplasia in HIV-negative and HIV-positive men who have sex with men. *Curr Infect Dis Rep* 2010; 12:126–33.
15. Goette DK, Carson TE. Erythroplasia of Queyrat: treatment with topical 5-fluorouracil. *Cancer* 1976; 38:1498–502.
16. González Sánchez JL, Flores Murrieta G, Chávez Brambila J *et al.* Topical 5-fluorouracil for treatment of vaginal intraepithelial neoplasms. *Ginecol Obstet Mex* 2002; 70:244–7.
17. Maiman M, Watts DH, Andersen J *et al.* Vaginal 5-fluorouracil for high-grade cervical dysplasia in human immunodeficiency virus infection: a randomized trial. *Obstet Gynecol* 1999; 94:954–61.
18. Kreuter A, Brockmeyer NH, Weissenborn SJ *et al.* Penile intraepithelial neoplasia is frequent in HIV-positive men with anal dysplasia. *J Invest Dermatol* 2008; 128:2316–24.
19. Munoz N, Bosch FX, de Sanjose S *et al.* Epidemiologic classification of human papillomavirus types associated with cervical cancer. *N Engl J Med* 2003; 348:518–27.
20. Kreuter A, Wieland U. Anal intraepithelial neoplasia in HIV infection. *J Dtsch Dermatol Ges* 2008; 6:925–34.
21. Goldstone SE, Hundert JS, Huyett JW. Infrared coagulator: a useful tool for treating anal squamous intraepithelial lesions. *Dis Colon Rectum* 2005; 48:1042–54.
22. Stier EA, Goldstone SE, Berry JM *et al.* Infrared coagulator treatment of high-grade anal dysplasia in HIV-infected individuals: an AIDS Malignancy Consortium pilot study. *J Acquir Immune Defic Syndr* 2008; 47:56–61.
23. Graham BD, Jetmore AB, Foote JE, Arnold LK. Topical 5-fluorouracil in the management of extensive anal Bowen's disease: a preferred approach. *Dis Colon Rectum* 2005; 48:444–50.

24. Jay N, Berry JM, Darrgh T, Palefsky J. Treatment of diffuse high-grade anal intraepithelial neoplasia with 5%-fluorouracil cream. Poster presentation (P-19.16), 25th International Papillomavirus Conference, Malmö, Sweden, 2009.
25. Chang GJ, Berry JM, Jay N *et al.* Surgical treatment of high-grade anal squamous intraepithelial lesions: a prospective study. *Dis Colon Rectum* 2002; 45:453–8.
26. Singh JC, Kuohung V, Palefsky JM. Efficacy of trichloroacetic acid in the treatment of anal intraepithelial neoplasia in HIV-positive and HIV-negative men who have sex with men. *J Acquir Immune Defic Syndr* 2009; 52:474–9.
27. Wieland U, Brockmeyer NH, Weissenborn SJ *et al.* Imiquimod treatment of anal intraepithelial neoplasia in HIV-positive men. *Arch Dermatol* 2006; 142:1438–44.
28. Kreuter A, Potthoff A, Brockmeyer NH *et al.* Imiquimod leads to a decrease of human papillomavirus DNA and to a sustained clearance of anal intraepithelial neoplasia in HIV-infected men. *J Invest Dermatol* 2008; 128:2078–83.

