



UvA-DARE (Digital Academic Repository)

Adult peroxisomal acyl-coenzyme A oxidase deficiency with cerebellar and brainstem atrophy

Ferdinandusse, S.; Barker, S.; Lachlan, K.; Duran, M.; Waterham, H.R.; Wanders, R.J.A.; Hammans, S.

DOI

[10.1136/jnnp.2009.176255](https://doi.org/10.1136/jnnp.2009.176255)

Publication date

2010

Document Version

Final published version

Published in

Journal of Neurology, Neurosurgery and Psychiatry

[Link to publication](#)

Citation for published version (APA):

Ferdinandusse, S., Barker, S., Lachlan, K., Duran, M., Waterham, H. R., Wanders, R. J. A., & Hammans, S. (2010). Adult peroxisomal acyl-coenzyme A oxidase deficiency with cerebellar and brainstem atrophy. *Journal of Neurology, Neurosurgery and Psychiatry*, *81*(3), 310-312. <https://doi.org/10.1136/jnnp.2009.176255>

General rights

It is not permitted to download or to forward/distribute the text or part of it without the consent of the author(s) and/or copyright holder(s), other than for strictly personal, individual use, unless the work is under an open content license (like Creative Commons).

Disclaimer/Complaints regulations

If you believe that digital publication of certain material infringes any of your rights or (privacy) interests, please let the Library know, stating your reasons. In case of a legitimate complaint, the Library will make the material inaccessible and/or remove it from the website. Please Ask the Library: <https://uba.uva.nl/en/contact>, or a letter to: Library of the University of Amsterdam, Secretariat, Singel 425, 1012 WP Amsterdam, The Netherlands. You will be contacted as soon as possible.

UvA-DARE is a service provided by the library of the University of Amsterdam (<https://dare.uva.nl>)

Adult peroxisomal acyl-coenzyme A oxidase deficiency with cerebellar and brainstem atrophy

Sacha Ferdinandusse,¹ Simon Barker,² Katherine Lachlan,³ Marinus Duran,¹
Hans R Waterham,¹ Ronald J A Wanders,¹ Simon Hammans²

¹Laboratory Genetic Metabolic Diseases, Academic Medical Center at the University of Amsterdam, Amsterdam, The Netherlands

²Wessex Neurological Centre, Southampton General Hospital, Southampton, UK

³Wessex Clinical Genetics Service, Princess Anne Hospital, Southampton, UK

Correspondence to

Dr Sacha Ferdinandusse, Laboratory Genetic Metabolic Diseases, F0-220, Academic Medical Center, Meibergdreef 9, 1105 AZ Amsterdam, The Netherlands; S.Ferdinandusse@amc.uva.nl

Received 2 March 2009

Revised 2 March 2009

Accepted 27 March 2009

ABSTRACT

Peroxisomal acyl-coenzyme A oxidase deficiency (formerly also called pseudoneonatal adrenoleucodystrophy) is a disorder of peroxisomal fatty acid oxidation with a severe presentation. Most patients present at birth or in early infancy, and the mean age of death was 5 years in a recently published cohort of 22 patients. Brain imaging shows a progressive leucodystrophy. The authors report here the first adult patients (two siblings, 52 and 55 years old) with peroxisomal acyl-coenzyme A oxidase deficiency with a remarkably mild clinical presentation. Magnetic resonance brain imaging revealed profound atrophy of the brainstem and cerebellum.

Peroxisomal acyl-coenzyme A oxidase deficiency (MIM264470) is a disorder of peroxisomal fatty acid oxidation caused by a deficiency of straight-chain acyl-coenzyme A oxidase (SCOX). SCOX is the first enzyme of the peroxisomal β -oxidation system and is involved in the oxidation of various fatty acids. These include very-long-chain fatty acids (VLCFAs \geq C24:0), long-chain dicarboxylic acids and polyunsaturated fatty acids, but not branched-chain fatty acids such as pristanic acid and the C27-bile acid intermediates. Accumulation of VLCFAs is the only diagnostic marker for SCOX deficiency.

The first patients with SCOX deficiency, reported in 1988,¹ were two siblings with neonatal hypotonia, seizures, apnoeic spells, delayed psychomotor development and neurological regression after the age of 2 years. Brain imaging showed progressive white-matter demyelination without cortical malformations. Following this report, a few additional cases have been described.^{2–6} Recently, the clinical, biochemical and mutational findings in a cohort of 22 patients have been published.⁷ All patients were children with a severe clinical presentation including psychomotor retardation, but they acquired limited skills such as sitting and standing without support. Almost all patients, however, showed a progressive loss of their motor achievements, and the mean age of regression was 28 months. The mean age of death was 5 years, with the oldest patient surviving until the age of 10.

Here we describe two SCOX-deficient siblings with a remarkable clinical presentation. The male proband was aged 52 when diagnosed as having SCOX deficiency. His early developmental milestones were normal. At age 10, he was noted to have scoliosis and a clumsy right hand. His gait showed progressive unsteadiness until the age of 28, when he became wheelchair-bound. He had

some urinary and faecal urgency. On examination, at 52 years of age, he had mildly impaired cognitive function. His memory was poor, but he was well oriented and could give an adequate description of his present problems. The visual acuity in the right eye was restricted to hand movements; left eye 6/12. He had small lens opacities. Retinitis pigmentosa was observed in both fundi, more advanced in the right eye. There was no optic disc pallor. Gaze-evoked nystagmus on upgaze, downgaze and lateral gaze was present. He had a slurring dysarthric speech but near normal tongue movements. He had a jerky head tremor. There was some dystonic posturing of his arms, and ataxia was seen on finger–nose testing. There was spastic tone in the legs, which was not present in the arms. Reflexes were symmetrical but pathologically brisk throughout. Clonus was present in both ankles with impaired heel–shin testing. Plantar responses were extensor. Sensation was normal with all modalities.

Magnetic resonance brain imaging showed profound atrophy of the brainstem and cerebellum, particularly evident in the pons, and modest cerebral atrophy. No other abnormality was seen. Nerve-conduction studies were normal. ERG showed a virtually absent response from either eye.

The patient's sister was 55 upon diagnosis. Her development was normal until 8 years of age when clumsiness and unsteady gait were noted. Examination, at age 55, showed cognitive impairment with disorientation in time and place. She had poor memory but could follow simple commands. She was confined to a wheelchair. She had bilateral cataracts, and fundi were not visible. She had limitation of eye movement in all directions, and gaze-evoked nystagmus in all directions. Her hearing was normal. She had slow tongue movements. There was preserved strength and normal tone in the arms but markedly impaired finger–nose testing. She was unable to move any muscle group in her legs, but reflexes were within normal limits. Plantar responses were extensor. There was normal sensation with all modalities.

The MRI scan of the sister also showed marked cerebellar and brainstem atrophy with modest atrophy of the cerebral hemispheres. There was no evidence of parenchymal signal abnormality (figure 1A–C).

Because of a clinical suspicion of a peroxisomal disorder, plasma VLCFAs were measured (table 1). The level of C26:0 was increased in plasma from both the brother (3.31 μ mol/l) and the sister (1.59 μ mol/l; control range 0.45–1.32 μ mol/l). However, the C26:0/C22:0 and C24:0/C22:0 ratios

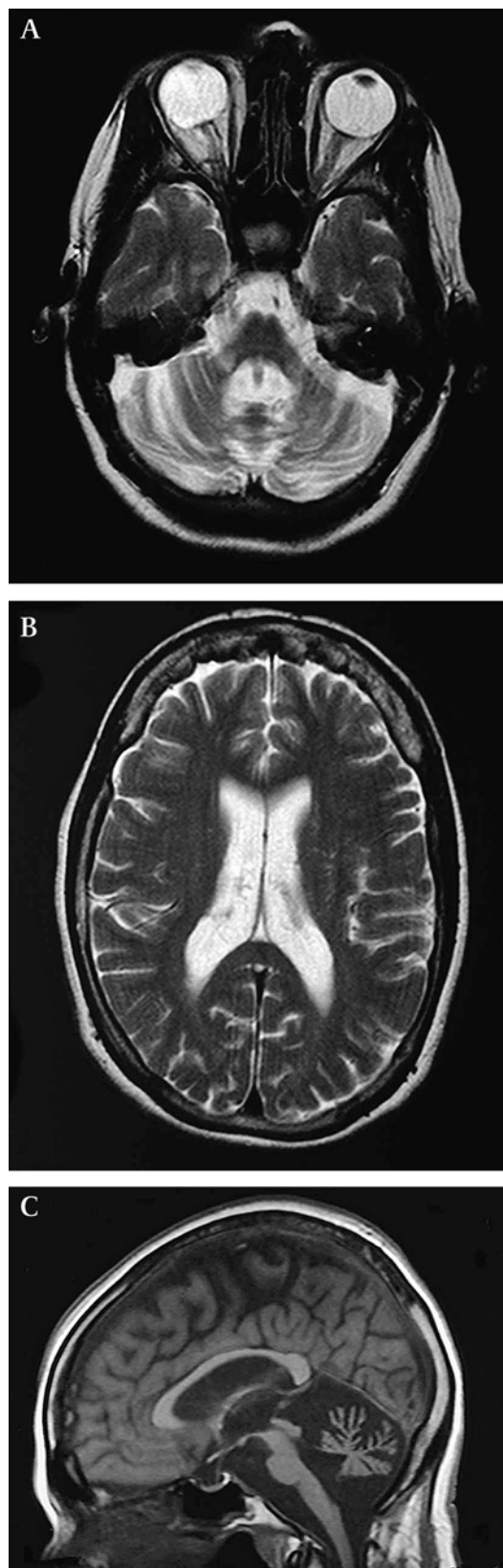


Figure 1 Axial T2 weighted images at the level of the middle cerebellar peduncles (A) and the lateral ventricles (B), and midline sagittal T1 weighted image (C). There is marked atrophy of the cerebellum, middle cerebellar peduncles and brainstem, with modest atrophy of the cerebrum. No parenchymal signal abnormality is seen.

Table 1 Biochemical analyses in plasma and skin fibroblasts

	Brother	Sister	Range
Plasma			
C26:0 ($\mu\text{mol/l}$)	3.31	1.59	0.45 to 1.32
C24:0 ($\mu\text{mol/l}$)	100.3	86.1	33 to 82
C22:0 ($\mu\text{mol/l}$)	98.0	98.0	40 to 119
C26/C22 ratio	0.03	0.02	<0.02
C24/C22 ratio	1.02	0.88	<0.94
Phytanic acid ($\mu\text{mol/l}$)	3.8	3.4	0 to 9
Pristanic acid ($\mu\text{mol/l}$)	0.8	0.4	0 to 3.1
Erythrocytes			
DHA ($\text{pmol}/10^6$ cells)	23.6	19.6	15.2 to 37.6
Skin fibroblasts			
SCOX activity ($\text{pmol}/(\text{min}\cdot\text{mg protein})$)	16	ND	49 to 151
C26:0 β -oxidation ($\text{pmol}/(\text{h}\cdot\text{mg protein})$)	590	ND	1025 to 2994
Pristanic acid β -oxidation ($\text{pmol}/(\text{h}\cdot\text{mg protein})$)	1616	ND	691 to 2178
C16:0 β -oxidation ($\text{pmol}/(\text{h}\cdot\text{mg protein})$)	2964	ND	1729 to 5361

ND, not determined.

were only marginally increased in the brother and even normal in the sister. Interestingly, acylcarnitine analysis in plasma revealed the presence of trace amounts of C26-carnitine, C24-carnitine and C16-dicarboxyl-carnitine.⁸ The level of the polyunsaturated fatty acids, including docosahexaenoic acid (C22:6 ω 3), were normal in both plasma and erythrocytes of the siblings. Bile acid analysis in plasma as well as the analysis of pristanic and phytanic acid did not reveal any abnormalities. Organic acid profiling in urine showed increased excretion of sebacic acid (C10-dicarboxylic acid), 2-hydroxy-sebacic acid, 3-hydroxy-sebacic acid and suberic acid (C8-dicarboxylic acid). The prominent excretion of these dicarboxylic acids is characteristic for patients with a peroxisomal fatty acid oxidation disorder.⁹

Subsequent investigations in cultured skin fibroblasts of the brother revealed a strongly reduced β -oxidation activity with C26:0 as substrate (590 pmol/(h.mg protein); control range 1025–2994 pmol/(h.mg protein)) (table 1). The activities of pristanic acid and C16:0 β -oxidation were completely normal. Immunofluorescence with antibodies against the peroxisomal matrix enzyme catalase and the peroxisomal membrane protein adrenoleucodystrophy protein (ALDP) revealed peroxisomes that were increased in size and reduced in number compared with control fibroblasts. These results prompted us to measure the activity of different β -oxidation enzymes in fibroblast homogenates. SCOX activity was clearly deficient (16 pmol/(min.mg protein); control range 49–151 pmol/(min.mg protein)), whereas normal activities were measured for branched-chain acyl-coenzyme A oxidase, D-bifunctional protein and Sterol carrier protein X (not shown). To confirm the SCOX deficiency at the molecular level, we performed mutation analysis of the *ACOX1* gene encoding SCOX. An apparent homozygous missense mutation, c.629G→A, was identified in DNA isolated from skin fibroblasts of the brother. The same apparent homozygous mutation was also identified in DNA isolated from lymphocytes of the sister. No material from the patients' parents, who were first cousins, was available to confirm homozygosity. The mutation c.629G→A leads to the amino acid substitution p.R210H. Immunoblot analysis with antibodies against SCOX revealed the normal presence of the 72 kDa full-length protein and the 51 and 21 kDa bands, the products of the proteolytical cleavage of the full-length protein, in fibroblast homogenates of the brother.

Virtually all SCOX-deficient patients die early in childhood. Up to now, the oldest surviving patient with an SCOX deficiency described in the literature was a 19-year-old Japanese boy

who manifested psychomotor retardation and regression during the late infantile period and who required respiration and tube feeding since the age of 11.^{5–10} The siblings described in this report have a remarkably mild presentation of SCOX deficiency and are alive at 52 and 55 years of age. The brain imaging contrasts with reported findings in the literature which describe changes occurring in early childhood: initially there is signal abnormality in cerebellar white matter, the middle cerebellar peduncles and brainstem tracts, with vermian atrophy; later, abnormal signal appears in the pyramidal tracts more superiorly in the brainstem, and in the posterior limb of the internal capsule; the parieto-occipital periventricular white matter and splenium of corpus callosum are then involved with later spread to frontal white matter.^{3–5}

In agreement with the relatively mild clinical presentation, the biochemical parameters in skin fibroblasts of the brother were only mildly abnormal. The residual C26:0 β -oxidation activity was one of the highest of a cohort of 20 SCOX-deficient skin fibroblasts available in our laboratory (590 compared with a patient range of 161–598 pmol/(h.mg protein)). This suggests that the SCOX protein displays some residual activity. This is difficult to ascertain in skin fibroblasts because the other peroxisomal acyl-coenzyme A oxidase, which primarily handles branched-chain substrates, has been shown also to display a low activity towards straight-chain fatty acids.¹¹ However, the amino acid substitution identified in the siblings does not affect the catalytic unit or the co-factor (FAD) binding site when analysing the crystal structure of rat SCOX,¹² in contrast to almost all the other amino acid substitutions described in SCOX-deficient patients.

In conclusion, we present the first adult patients with peroxisomal acyl-coenzyme A oxidase deficiency. This diagnosis should be considered even when imaging findings are not typical of a peroxisomal disorder, and may also be suggested by abnormal VLCFAs in patients clinically atypical of the adrenoleukodystrophy/myeloneuropathy spectrum.

Acknowledgements We thank PAW Mooyer, C Dekker, H Rusch, S Denis, W Smit and EM Hogenhout for technical assistance. We thank G Warner for referring the patient to us. We would like to thank Dr Jeremy Quiney for his kind help in analysis and despatch of samples.

Funding This work was supported by The Netherlands Organisation for Scientific Research (NWO, grant number 916.46.109) and the FP6 European Union Project 'Peroxisomes' (grant number LSHG-CT-2004512018).

Competing interests None.

Provenance and peer review Not commissioned; externally peer reviewed.

REFERENCES

1. **Poll-The BT**, Roels F, Ogier H, *et al.* A new peroxisomal disorder with enlarged peroxisomes and a specific deficiency of acyl-CoA oxidase (pseudo-neonatal adrenoleukodystrophy). *Am J Hum Genet* 1988;**42**:422–34.
2. **Watkins PA**, McGuinness MC, Raymond GV, *et al.* Distinction between peroxisomal bifunctional enzyme and acyl-CoA oxidase deficiencies. *Ann Neurol* 1995;**38**:472–7.
3. **Kurian MA**, Ryan S, Besley GT, *et al.* Straight-chain acyl-CoA oxidase deficiency presenting with dysmorphia, neurodevelopmental autistic-type regression and a selective pattern of leukodystrophy. *J Inherit Metab Dis* 2004;**27**:105–8.
4. **Rosewich H**, Waterham HR, Wanders RJ, *et al.* Pitfall in metabolic screening in a patient with fatal peroxisomal beta-oxidation defect. *Neuropediatrics* 2006;**37**:95–8.
5. **Suzuki Y**, Iai M, Kamei A, *et al.* Peroxisomal acyl CoA oxidase deficiency. *J Pediatr* 2002;**140**:128–30.
6. **Carrozzo R**, Bellini C, Lucioi S, *et al.* Peroxisomal acyl-CoA-oxidase deficiency: two new cases. *Am J Med Genet A* 2008;**146A**:1676–81.
7. **Ferdinandusse S**, Denis S, Hogenhout EM, *et al.* Clinical, biochemical, and mutational spectrum of peroxisomal acyl-coenzyme A oxidase deficiency. *Hum Mutat* 2007;**28**:904–12.
8. **Rizzo C**, Boenzi S, Wanders RJ, *et al.* Characteristic acylcarnitine profiles in inherited defects of peroxisome biogenesis: a novel tool for screening diagnosis using tandem mass spectrometry. *Pediatr Res* 2003;**53**:1013–8.
9. **Korman SH**, Mandel H, Gutman A. Characteristic urine organic acid profile in peroxisomal biogenesis disorders. *J Inherit Metab Dis* 2000;**23**:425–8.
10. **Funato M**, Shimosawa N, Nagase T, *et al.* Aberrant peroxisome morphology in peroxisomal beta-oxidation enzyme deficiencies. *Brain Dev* 2006;**28**:287–92.
11. **Vanhove GF**, Van Veldhoven PP, Fransen M, *et al.* The CoA esters of 2-methyl-branched chain fatty acids and of the bile acid intermediates di- and trihydroxycoprostanic acids are oxidized by one single peroxisomal branched chain acyl-CoA oxidase in human liver and kidney. *J Biol Chem* 1993;**268**:10335–44.
12. **Nakajima Y**, Miyahara I, Hirotsu K, *et al.* Three-dimensional structure of the flavoenzyme acyl-CoA oxidase-II from rat liver, the peroxisomal counterpart of mitochondrial acyl-CoA dehydrogenase. *J Biochem* 2002;**131**:365–74.