



UvA-DARE (Digital Academic Repository)

Outcome of orbital decompression for disfiguring proptosis in patients with Graves' orbitopathy using various surgical procedures

Mourits, M.P.; Bijl, H.; Altea, M.A.; Baldeschi, L.; Boboridis, K.; Currò, N.; Dickinson, A.J.; Eckstein, A.; Freidel, M.; Guastella, C.; Kahaly, G.J.; Kalmann, R.; Krassas, G.E.; Lane, C.M.; Lareida, J.; Marcocci, C.; Marino, M.; Nardi, M.; Mohr, C.; Neoh, C.; Pinchera, A.; Orgiazzi, J.; Pitz, S.; Saeed, P.; Salvi, M.; Sellari-Franceschini, S.; Stahl, M.; von Arx, G.; Wiersinga, W.M.

DOI

[10.1136/bjo.2008.149302](https://doi.org/10.1136/bjo.2008.149302)

Publication date

2009

Document Version

Final published version

Published in

British journal of ophthalmology

[Link to publication](#)

Citation for published version (APA):

Mourits, M. P., Bijl, H., Altea, M. A., Baldeschi, L., Boboridis, K., Currò, N., Dickinson, A. J., Eckstein, A., Freidel, M., Guastella, C., Kahaly, G. J., Kalmann, R., Krassas, G. E., Lane, C. M., Lareida, J., Marcocci, C., Marino, M., Nardi, M., Mohr, C., ... Wiersinga, W. M. (2009). Outcome of orbital decompression for disfiguring proptosis in patients with Graves' orbitopathy using various surgical procedures. *British journal of ophthalmology*, 93(11), 1518-1523. <https://doi.org/10.1136/bjo.2008.149302>

General rights

It is not permitted to download or to forward/distribute the text or part of it without the consent of the author(s) and/or copyright holder(s), other than for strictly personal, individual use, unless the work is under an open content license (like Creative Commons).

Disclaimer/Complaints regulations

If you believe that digital publication of certain material infringes any of your rights or (privacy) interests, please let the Library know, stating your reasons. In case of a legitimate complaint, the Library will make the material inaccessible and/or remove it from the website. Please Ask the Library, <https://uba.uva.nl/en/contact>, or a letter to: Library of the University of Amsterdam, Secretariat, Singel 425, 1012 WP Amsterdam, The Netherlands. You will be contacted as soon as possible.



Outcome of orbital decompression for disfiguring proptosis in patients with Graves' orbitopathy using various surgical procedures

European Group on Graves' Orbitopathy (EUGOGO), M P Mourits, H Bijl, et al.

Br J Ophthalmol 2009 93: 1518-1523 originally published online November 21, 2008
doi: 10.1136/bjo.2008.149302

Updated information and services can be found at:
<http://bjo.bmj.com/content/93/11/1518.full.html>

These include:

References

This article cites 20 articles, 7 of which can be accessed free at:
<http://bjo.bmj.com/content/93/11/1518.full.html#ref-list-1>

Email alerting service

Receive free email alerts when new articles cite this article. Sign up in the box at the top right corner of the online article.

Notes

To request permissions go to:
<http://group.bmj.com/group/rights-licensing/permissions>

To order reprints go to:
<http://journals.bmj.com/cgi/reprintform>

To subscribe to BMJ go to:
<http://journals.bmj.com/cgi/ep>

Outcome of orbital decompression for disfiguring proptosis in patients with Graves' orbitopathy using various surgical procedures

European Group on Graves' Orbitopathy (EUGOGO), M P Mourits,¹ H Bijl,¹ M A Altea,² L Baldeschi,¹ K Boboridis,³ N Currò,⁴ A J Dickinson,⁵ A Eckstein,⁶ M Freidel,⁷ C Guastella,⁴ G J Kahaly,⁸ R Kalmann,⁹ G E Krassas,³ C M Lane,¹⁰ J Lareida,¹¹ C Marcocci,² M Marino,² M Nardi,² Ch Mohr,⁶ C Neoh,⁵ A Pinchera,² J Orgiazzi,⁷ S Pitz,⁸ P Saeed,¹ M Salvi,⁴ S Sellari-Franceschini,² M Stahl,¹¹ G von Arx,¹¹ W M Wiersinga¹

¹ Academic Medical Centre, Amsterdam, the Netherlands;

² Azienda Ospedaliero-Universitaria Pisana, Italy;

³ Panagia General Hospital Thessaloniki, Greece;

⁴ Fondazione Ospedale Policlinico Istituto di Ricovero e Cura a Carattere Scientifico, Milano, Italy;

⁵ Newcastle upon Tyne Hospitals NHS Trust, Newcastle, UK;

⁶ Essen University Clinic, Essen, Germany;

⁷ Centre Hospitalier Lyon-Sud, Lyon, France;

⁸ Gutenberg University Hospital, Mainz, Germany;

⁹ University Medical Centre, Utrecht, the Netherlands;

¹⁰ University Hospital of Wales, Cardiff, UK;

¹¹ Basedow.ch – Interdisziplinäres Zentrum für Endokrine Orbitopathie, Olten, Switzerland

Correspondence to:

Professor M P Mourits, Department of Ophthalmology, Academic Medical Centre, Meibergdreef 9, 1105 AZ Amsterdam, the Netherlands; M.P.Mourits@amc.uva.nl

Accepted 15 October 2008

Published Online First

21 November 2009

ABSTRACT

Aim: To compare the outcome of various surgical approaches of orbital decompression in patients with Graves' orbitopathy (GO) receiving surgery for disfiguring proptosis.

Method: Data forms and questionnaires from consecutive, euthyroid patients with inactive GO who had undergone orbital decompression for disfiguring proptosis in 11 European centres were analysed.

Results: Eighteen different (combinations of) approaches were used, the swinging eyelid approach being the most popular followed by the coronal and transconjunctival approaches. The average proptosis reduction for all decompressions was 5.0 (SD 2.1) mm. After three-wall decompression the proptosis reduction was significantly greater than after two-wall decompression. Additional fat removal resulted in greater proptosis reduction. Complications were rare, the most frequent being worsening of motility, occurring more frequently after coronal decompression. The average change in quality of life (QOL) in the appearance arm of the GO-QOL questionnaire was 20.5 (SD 24.8) points.

Conclusions: In Europe, a wide range of surgical approaches is used to reduce disfiguring proptosis in patients with GO. The extent of proptosis reduction depends on the number of walls removed and whether or not fat is removed. Serious complications are infrequent. Worsening of ocular motility is still a major complication, but was rare in this series after the swinging eyelid approach.

Orbital decompression surgery is a well established procedure performed worldwide to restore visual function in patients with dysthyroid optic neuropathy (DON),¹ to rehabilitate patients with disfiguring exophthalmos due to Graves' orbitopathy (GO), and to cure and prevent corneal ulceration in GO with lagophthalmos and increased lid aperture.^{2,3} It is also done in GO patients with persistent retrobulbar pain.⁴ Decompression is achieved by removing orbital bone, fat or a combination of these. Several approaches for bony wall removal are in use, with ongoing debate as to which approach is the most desirable.⁵ Comparison of different procedures in the past has been biased by inclusion of different indications (DON versus disfiguring proptosis), different stages of the disease (active versus

inactive), evaluation at different intervals after surgery and by the fact that no commonly accepted system for the evaluation of motility impairment in GO had been used.⁶ In this study, we attempted to eliminate these factors by evaluating prospectively and after a fixed interval outcomes of the various surgical procedures in inactive GO patients operated on for disfiguring proptosis. Our aim was to compare the outcome of different decompression procedures the way they are usually done in the centres tested.

PATIENTS AND METHODS

The study was carried out in 11 European centres, all belonging to the European Group on Graves' Orbitopathy (EUGOGO), during the period 1 January 2006 to 1 January 2007. Consecutive patients with GO were included prospectively: they were euthyroid and had stable GO with unchanged clinical activity scores⁷ for at least 3 months and underwent orbital decompression solely for rehabilitative reasons. In each centre, all patients were seen by a multidisciplinary team consisting of an endocrinologist and an ophthalmologist.⁸ Surgeons, ophthalmologists and orthoptists were asked to deliver specific pre- and postoperative data for analysis. No restrictions were made as to the kind of orbital decompression. Thus, shortly before or on the day of the operation a data form and a GO-quality of life (QOL) questionnaire were completed. (The GO-QOL is a validated instrument to measure QOL in patients with GO and consists of a visual function and an appearance score. Each score has a range of 0 to 100, higher values meaning better quality of life.⁹) Approximately 3 months later, and prior to any additional surgical or medical treatment except for lubricants, a follow-up data form and questionnaire were completed. The data thus collected were analysed in the Academic Medical Centre of Amsterdam. Very similar procedures were grouped and then compared.

Eyelid retraction was assessed with the patient in primary position.¹⁰ Proptosis was measured using a Hertel exophthalmometer.¹¹ Different types of exophthalmometers were applied (eg Oculus (Oculus Optikgeräte GmbH, Wetzlar, Germany), Inami (Inami & Co., Tokyo, Japan)), but in each centre the same instrument was always used. A

full orthoptic assessment was performed in each centre, including assessment of head tilt, squint angle if present, fusional amplitude, ocular ductions and the field of binocular single vision. Diplopia was considered present when the patient experienced double vision (in any gaze direction) that disappeared with one eye closed. Diplopia was rated using the Gorman score (no diplopia, intermittent diplopia, gaze-dependent diplopia, constant diplopia).¹² Visual acuity was measured using a pinhole and Snellen optotypes.

The techniques of the different surgical approaches mentioned in this paper have been described in detail previously.^{13–16}

Statistical analysis

For data analysis the statistical program SPSS 14.0 was used. Independent sample t test was used for normally distributed data sets. Chi-square test was used for non-parametric statistical analysis. Significance was assumed if $p \leq 0.05$. Multiple regression analysis was used to assess the independent influence of preoperative Hertel values on the proptosis reduction and any diplopia induced.

RESULTS

During the year 2006, 139 euthyroid patients (103 women, mean age 47.6 (range 16–75) years) with inactive GO underwent orbital decompression (248 orbits) for disfiguring proptosis. Eighteen different approaches or combinations of approaches were used (table 1).

The most frequently performed procedures are shown and compared in table 2. The operations were performed by specialised ophthalmologists (eg orbitologists) (n = 9), by ear,

nose and throat (ENT) specialists (n = 2), or by oro-maxillary surgeons (n = 2).

There was no clinically relevant change in visual acuity in any patient. The preoperative Hertel values for all patients included ranged from 17 to 35 mm. The average preoperative proptosis in the three-wall decompression groups (112 orbits, mean proptosis 25.7 (SD 3.0) mm) was significantly higher than in the two-wall decompression groups (132 orbits, mean proptosis 23.8 (SD 2.7) mm) ($p = 0.000$).

The amount of proptosis reduction after various orbital decompressions is shown in table 3. The average proptosis reduction after three-wall decompression was significantly more than after two-wall decompression. Multiple linear regression analysis demonstrated that this difference was not caused by the difference of preoperative Hertel values alone (fig. 1). In addition, comparing two-wall with three-wall decompression in subsets of patients with the same preoperative Hertel value distribution (eg between 23 and 26 mm), the proptosis reduction in the first subgroup was 4.6 (SD 1.0) mm and in the second 5.8 (SD 1.7) mm ($p = 0.000$). When proptosis reduction was compared between decompressions with and without fat removal per centre, for instance in centres A and K, where comparable numbers of patients underwent no fat or fat removal, a difference in favour of those with fat removal was found in all comparisons, but these differences did not reach statistical significance. However, comparing all three-wall decompressions with fat removal with those without fat excision, a significant difference was found ($p = 0.05$, table 3). Comparing three-wall swinging eyelid (\pm transcaruncular) with three-wall coronal and with three-wall translid and endoscopic decompressions, a significant difference of

Table 1 Surgical approaches, number of walls removed and average proptosis reduction in 11 European centres

| Centre | Orbits (n) | Approach | Walls (n) | Mean reduction (mm)* |
|--------|------------|---|-----------|----------------------|
| A | 26 | Swinging eyelid | 2/3 | 4.8 (1.8) |
| A | 19 | Transconjunctival | 2 | 4.7 (2.1) |
| A | 11 | Transconjunctival + transcaruncular | 2 | 5.2 (2.3) |
| A | 4 | Transcaruncular | 2 | 4.8 (0.5) |
| A | 7 | Swinging eyelid + transcaruncular | 3 | 6.7 (1.8) |
| A | 2 | Coronal + transconjunctival | 3 | 8.5 (2.1) |
| A | 1 | Transcaruncular + upper lid crease | 2 | 4.0 (0) |
| B | 4 | Transconjunctival + lynch | 2 | 4.0 (0) |
| B | 2 | Upperlid crease | 1 | 5.5 (0.7) |
| B | 1 | Transconjunctival + lynch + ULC | 2 | 3.0 (0) |
| C | 22 | Coronal | 3 | 6.5 (1.4) |
| C | 14 | Endoscopic | 2 | 3.2 (1.5) |
| D | 13 | Translid | 2 | 3.8 (1.4) |
| E | 22 | Swinging eyelid | 2/3 | 4.0 (1.3) |
| F | 12 | Upper lid crease + endoscopic | 2 | 3.4 (2.4) |
| G | 16 | Swinging eyelid + transcaruncular | 2/3 | 5.8 (1.6) |
| G | 1 | Swinging eyelid | 2 | 6.0 (0) |
| H | 6 | Coronal | 3 | 6.5 (0.8) |
| H | 3 | Transconjunctival | 2 | 3.7 (0.6) |
| I | 28 | Translid + endoscopic | 3 | 6.2 (2.9) |
| I | 3 | Translid | 2 | 5.7 (2.3) |
| I | 2 | ULC + swinging eyelid | 2 | 5.5 (0.7) |
| I | 2 | Endoscopic | 1 | 3.0 (0) |
| I | 2 | Translid + swinging eyelid + endoscopic | 3 | 4.0 (2.8) |
| J | 3 | Swinging eyelid + ULC | 3 | 5.3 (1.2) |
| K | 20 | Swinging eyelid | 2/3 | 5.5 (2.2) |
| K | 2 | Translid | 2 | 2.5 (0.7) |

*Values are mean (SD).
ULC, Upper lid crease.

Table 2 Comparison of most frequently used procedures

| Variable | Swinging eyelid ± transcar | Coronal | Translid + endo | Swinging eyelid ± transcar | Transcon ± transcar | Endo | Translid |
|-----------------------------|--|--|-----------------|------------------------------------|---------------------|---------------|---------------|
| Decompression | Three-wall | Three-wall | Three-wall | Two-wall | Two-wall | Two-wall | Two-wall |
| Patients (n) | 26 | 14 | 14 | 25 | 18 | 10 | 11 |
| Orbits (n) | 49 | 28 | 28 | 43 | 33 | 14 | 18 |
| Age | 47.5 | 52.4 | 47.8 | 50.7 | 44.7 | 42.7 | 47.7 |
| Male/female | 8/18 | 1/13 | 7/7 | 7/18 | 2/16 | 2/8 | 1/10 |
| DM | 2/26 | 0/14 | 2/13 | 3/25 | 0/18 | 1/8* | 0/11 |
| Smoking | 16/19* | 11/14 | 6/12 | 11/24* | 5/18 | 5/5 | 4/11 |
| Immunosup + RT | 19/24 | 12/14 | 14/14 | 14/25 | 10/18 | 9/10 | 6/11 |
| Preoperative Hertel | 23.0 (3.6) | 24.8 (2.7) | 27.0 (2.9) | 22.8 (4.0) | 22.3 (2.7) | 21.3 (2.5) | 23.2 (1.7) |
| Postoperative Hertel | 17.4 (3.1) | 18.3 (2.8) | 20.8 (3.6) | 18.3 (3.8) | 17.5 (2.0) | 18.1 (2.1) | 19.2 (1.8) |
| ΔProptosis | 5.6 (1.9) | 6.5 (1.3) | 6.2 (2.9) | 4.5 (1.7) | 4.8 (2.0) | 3.2 (1.5) | 4.0 (1.7) |
| Complications | 2 eyelid swelling 2 sinus obstruction 1 scar dissatisfaction 1 hypoglobus | 5 dysesthesia 3 eyelid swelling 3 bossing 3 paralysis† 1 CSF | 1 CSF | 4 eyelid swelling 1 dysesthesia | None reported | None reported | None reported |
| Preoperative diplopia | 14/25* | 9/14 | 12/14 | 14/25 | 6/18 | 4/10 | 6/11 |
| Postoperative diplopia | 9/25 | 14/14 | 12/14 | 14/24* | 8/18 | 6/10 | 6/11 |
| QOL-App preoperative | 46.3 (26.2) | 17.7 (18.4) | 55.1 (26.0) | 44.0 (32.2) | 47.4 (23.8) | 38.8 (31.9) | 43.9 (23.0) |
| QOL-App postoperative | 63.6 (20.9) | 57.2 (24.9) | 56.9 (27.4) | 64.0 (28.1) | 67.1 (30.7) | 73.3 (24.4) | 66.0 (23.8) |
| ΔQOL-App | 17.4 (24.5) | 39.9 (27.0) | 1.8 (9.5) | 19.9 (22.9) | 19.7 (18.9) | 34.5 (30.4) | 22.1 (25.3) |
| QOL-Visfunc preoperative | 51.7 (24.5) | 57.5 (32.7) | 52.4 (26.4) | 60.8 (26.6) | 64.5 (27.8) | 70.2 (40.3) | 61.5 (28.9) |
| Qol-Visfunc postoperative | 69.1 (23.7) | 55.8 (27.7) | 51.6 (29.1) | 69.3 (27.1) | 72.5 (28.1) | 72.5 (30.7) | 75.2 (22.0) |
| ΔQOL-Visfunc | 17.5 (20.8) | -1.7 (35.9) | -0.8 (9.5) | 8.5 (20.9) | 7.9 (21.8) | 2.3 (30.0) | 13.6 (18.7) |
| Hospitalisation time (days) | 4.4 (1.8) | 9.8 (1.8) | 4.4 (1.2) | 3.8 (1.7) | 3.1 (0.6) | 5.6 (0.7) | 3.1 (0.7) |

Values are mean (SD).

Δ, change in Graves' orbitopathy specific quality of life questionnaire.

*Denominators do not always equal the totals because a few data were missing. However, conclusions are not influenced by these few missing data.

†Paralysis of the frontal muscle(s).

App, appearance; CSF, cerebrospinal fluid; DM, diabetes mellitus; Endo, endoscopic approach; Immunosup, treated with immunosuppressive modalities; QOL, quality of life; RT, radiotherapy; Transcar, transcaruncular approach; Transcon, transconjunctival approach; Visfunc, visual functioning.

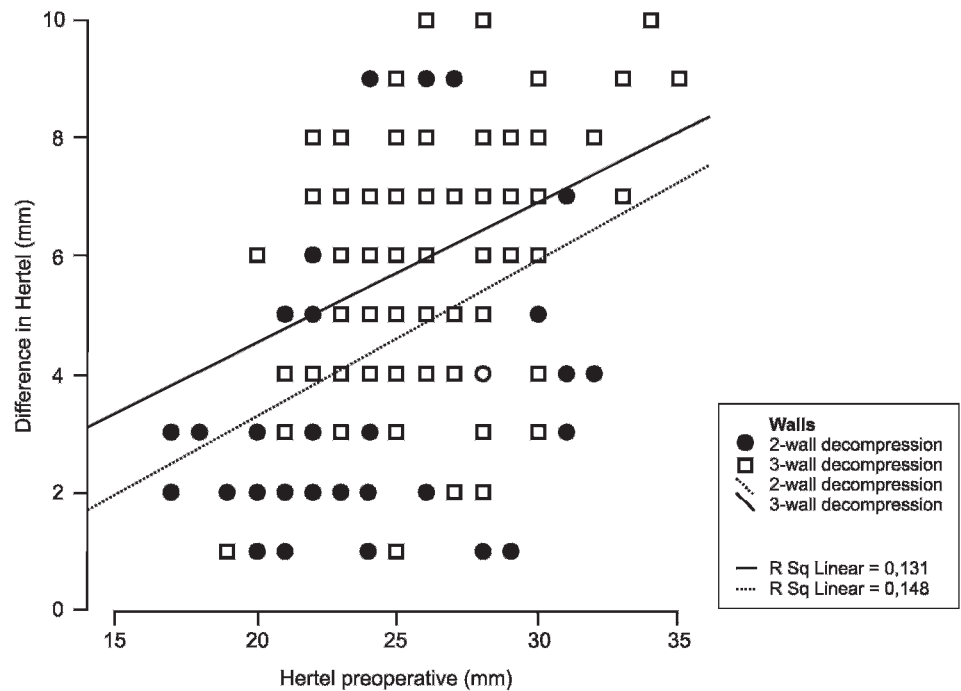
proptosis reduction in favour of the coronal approach was found (table 3). Comparing two-wall decompressions, the endoscopic approach resulted in a small but significantly lower proptosis reduction compared with swinging eyelid ($p = 0.012$) or transconjunctival/transcaruncular approaches ($p = 0.007$), but not compared with the translid approach ($p = 0.213$). The role of leaving or removing the maxillo-ethmoidal strut and/or the posterior lateral or medial wall could not be evaluated because of lack of data.

Overall there were few complications, but three-wall decompressions were associated with more complications than two-wall decompressions. Significant postoperative eyelid swelling and chemosis lasting several weeks were reported after three- and two-wall swinging eyelid and after coronal approaches (table 2). Maxillary sinus obstruction due to herniated fat was seen twice after three-wall swinging eyelid decompression. Hypoglobus and scar dissatisfaction were noted sporadically after swinging eyelid decompression. Temporal bossing was found in three patients and paralysis of the frontal muscle(s)

lasting at least 3 months in another three patients after coronal decompression. A cerebrospinal fluid (CSF) leakage occurred in one patient after a coronal approach and in another one after a translid and endoscopic approach. In the coronal group, complications were more frequent and more serious.

In terms of changes of diplopia and Gorman score, both the three- and two-wall swinging eyelid decompression techniques compared favourably with the other approaches used. After three-wall swinging eyelid decompression, binocular single vision in all directions of gaze returned in five out of 25 patients, corresponding with an improvement of the Gorman score. In this subgroup only one patient reported a worsening of the Gorman score. In contrast, five out of 14 patients who underwent a coronal decompression showed de novo diplopia, whereas another two reported a worsening of the Gorman score. De novo diplopia was also seen in two out of 18 patients after transconjunctival/transcaruncular two-wall decompression and in two out of two patients after endoscopic two-wall decompression. Except for the swinging eyelid two- and

Figure 1 Plotter diagram showing the relationship between preoperative Hertel values (x-axis) and proptosis reduction (y-axis) after three- and two-wall orbital decompressions. The oblique lines show the greater extent of proptosis reduction after three-wall decompression compared with two-wall.



three-wall decompression, improvements of diplopia were rarely seen (table 2). To assess the influence of preoperative values on the origin of de novo diplopia, we compared the preoperative Hertel values in the subgroup of patients that developed de novo diplopia ($n = 17$, Hertel value 25.2 (SD 2.6)) with those who remained aligned ($n = 122$, Hertel value 24.8 (SD 3.1)). This difference was not significant ($p = 0.57$).

The average preoperative GO-QOL appearance score varied from 17.7 (SD 18.4) to 55.1 (SD 26.0). A few individuals had a lower score postoperatively, but most improved: the average change after surgery was +20.5 (SD 24.8) (table 2). Variations in the average change of the appearance score were between 17.4 and 39.9 points, except for the translid and endoscopic approach, in which the change was no more than 1.8 points. With this exception, no significant differences were seen. A decrease of the visual functioning score after orbital decompression was seen especially after the coronal approach, in which group de novo diplopia occurred most frequently.

No significant differences in hospitalisation times were found, except for one centre in which patients were admitted

to the hospital several days before the operation to complete preoperative procedures.

DISCUSSION

To our knowledge, this is the first study in which various orbital decompression approaches for disfiguring proptosis in GO have been studied in a prospective manner and in which an attempt has been made to include subjective outcomes, eg outcomes as perceived by the patients. Orbital bony wall decompression has been performed since the 1950s for patients with optic nerve compression,¹⁷ but was not an accepted procedure for patients with disfiguring proptosis before the early 1990s.¹⁸ Many approaches have since been described and this study shows that at present many of different approaches are in use. Evidence suggests that three-wall decompressions were chosen for patients with more extreme proptosis and two-wall for those with less proptosis. Furthermore, most surgeons involved in this study reported that the choice of their approach depended on personal training and experience and institutional

Table 3 Proptosis reduction after orbital decompression

| Reference no. | Number of walls removed | n | Reduction* | p Value |
|---------------|--|------|------------|----------------|
| 1 | All | 248† | 5.0 (2.1) | |
| 2 | All three-wall | 112 | 6.0 (2.1) | 0.00 (2 vs 3) |
| 3 | All two-wall | 130 | 4.3 (1.8) | 0.00 (5 vs 7) |
| 4 | Three-wall + fat | 71 | 6.3 (2.2) | 0.05 (4 vs 5) |
| 5 | Three-wall - fat | 41 | 5.5 (1.9) | |
| 6 | Two-wall + fat | 73 | 4.4 (1.9) | 0.32 (6 vs 7) |
| 7 | Two-wall - fat | 57 | 4.1 (1.7) | |
| 8 | Three-wall swinging eyelid decompression ± transcaruncular | 49 | 5.6 (1.0) | 0.25 (8 vs 9) |
| 9 | Three-wall translid ± endoscopic | 28 | 6.2 (2.9) | 0.03 (8 vs 10) |
| 10 | Three-wall coronal | 28 | 6.5 (1.3) | 0.68 (9 vs 10) |

*Values are mean (SD).

†Including six one-wall decompressions.

tradition, while some tailored the choice of their surgery to the specific conditions of their patient.

In line with previous studies, our study confirms that the more walls are removed the more proptosis reduction can be achieved. It could be argued that this difference was found because those who underwent three-wall decompression were more proptosed initially. However, linear regression and t test analysis showed that a significant difference of proptosis reduction after three- and two-wall decompression was also present in subsets of patients with comparable preoperative Hertel values. While pure fat removal may still be a matter of dispute, fat removal in addition with bone removal increases the degree of proptosis reduction.

This study confirms previous reports stating that induction of diplopia is the most common complication.^{5 10 19} Many theories have been proposed to explain the cause of this phenomenon (removal of the posterior medial wall, removal of the inferomedial strut, the displacement of the extraocular muscle paths), but no theory has been commonly accepted. It has been suggested that a balanced orbital decompression causes less diplopia than other techniques and recent studies show new onset or worsening of diplopia varying from 10% to 20%.^{20 21} Comparison of induced diplopia rates after different orbital approaches is hampered by many factors: Which patients are included? How is motility measured? At what moment is the outcome assessed? Which criteria for diplopia and which definition of improvement or worsening are used? In this study we used two tools to assess diplopia: patients were asked to score diplopia using the Gorman score. In addition, the orthoptist and ophthalmologist determined whether or not there was diplopia in any direction of gaze. The complete orthoptic evaluation differed slightly between centres, making it difficult to draw accurate conclusions on the preoperative motility and whether it differed significantly between the surgical groups. However, there can be no doubt about the final conclusion given the simple definition of diplopia we used: diplopia yes or no. With these criteria, there seems to be a tendency for the swinging eyelid approaches to be associated with less induced diplopia and even reduction of diplopia. In the group of three-wall swinging eyelid decompression, the incidence of diplopia decreased and the Gorman score improved. We can only speculate what would be the reason for this finding. The coronal approach differs from other approaches, because only in this approach is the trochlea detached. However, we would expect detachment of the trochlea to cause vertical tropias, whereas convergent squint with reduced abduction is what is usually seen. Coronal decompression in this series was applied in patients with more extreme proptosis and a higher rate of preoperative diplopia. However, corrected for preoperative Hertel values, the difference in de novo diplopia after coronal decompression remained significantly higher than after swinging eyelid procedures (coronal 5/14; swinging eyelid + transcaruncular 0/25, $p = 0.003$). In the absence of a generally accepted policy for evaluating motility changes and consequent diplopia, it is not yet possible to elucidate the aetiology of induced diplopia and guide patient counselling regarding this important complication.

In this study, the subjective response to treatment was measured using Terwee's GO-QOL, a validated disease specific questionnaire to assess changes in visual function and changes in appearance.⁹ As our patients were operated on for disfiguring proptosis only, we expected the greatest changes to occur in the appearance score, which was indeed the case (table 2). For large interventions such as orbital decompression, the "Minimal

Clinically Important Difference" (MCID) has been calculated as 10 points.²² An increase of at least 10 points in the appearance score was found after all but one approach. The results are grossly comparable to previous measurements,²² but surprising variations were found. In spite of the relatively high incidence of induced diplopia and other complications, the coronal approach scored most highly. Nevertheless, the coronal approach seems less attractive because of its side effects and possible longer hospitalisation time. The three-wall translid and endoscopic approach from one centre scored extremely low on the GO-QOL score. The local ophthalmologists and endocrinologists have interpreted this as reflecting the fact that (persistent) squint had been associated by their patients not only with functional, but also with aesthetic deficits.

Most centres preferred their patients to stay in the hospital for 3 to 5 days. In one centre patients were hospitalised several days prior to their surgery for their preoperative work-up. This partly explains the relative long stay in that hospital.

We chose to evaluate our results 3 months after surgery because most complications become apparent within the first months after surgery. Moreover, we considered it medically unacceptable to postpone strabismus surgery in patients with stable diplopia or lid-lengthening in patients with significant lid retraction for longer than 3 months. Once these operations are performed, the exclusive effects of orbital decompression are no longer assessable. We realise, however, that complications such as sinus obstruction do occur and diplopia might still improve after more than 3 months postoperatively. For these reasons, our results are only valid within the limitations we chose.

In conclusion, different approaches for orbital decompression in patients with GO with disfiguring proptosis resulted in proptosis regression varying from 5.6 to 6.5 mm after three-wall decompression and of 3.2 to 4.8 mm after two-wall decompression (table 2). Except for diplopia, side effects were rare for all approaches tested. With regard to changes of eye motility, both the three- and two-wall swinging eyelid decompression techniques compared favourably with the other approaches used.

Funding: None

Competing interests: None declared.

Ethics approval: Obtained.

Patient consent: Obtained.

Provenance and peer review: Not commissioned; externally peer reviewed.

REFERENCES

1. **McKeag D**, Lane CM, Lazarus JH, *et al*. Clinical features of dysthyroid optic neuropathy: a European Group on Graves' Orbitopathy (EUGOGO) survey. *Br J Ophthalmol* 2007;**91**:455–8.
2. **Perros P**, Baldeschi L, Boboridis, *et al*. A questionnaire survey on the management of Graves' orbitopathy in Europe. *Eur J Endocrinol* 2006;**155**:387–9.
3. **Prummel MF**, Bakker A, Wiersinga WM, *et al*. A Multi-center study on the characteristics and treatment strategies of patients with Graves' orbitopathy: the first European Group on Graves' Orbitopathy experience. *Eur J Endocrinol* 2003;**148**:491–5.
4. **Mourits MP**, Rose GE, Garrity JA, *et al*. Surgical management of Graves' ophthalmopathy. In: Prummel MF, ed. *Recent developments in Graves' ophthalmopathy*. Boston, Dordrecht, London: Kluwer Academic Publishers, 2000:133–52.
5. **McCord CD Jr**. Current trends in orbital decompression. *Ophthalmology* 1985;**92**:21–33.
6. **Paridaens D**, Hans K, van Buitenen S, *et al*. The incidence of diplopia following coronal and translid orbital decompression in Graves' orbitopathy. *Eye* 1998;**12**:800–5.
7. **Mourits MP**, Koornneef L, Wiersinga WM, *et al*. Clinical criteria for the assessment of disease activity in Graves' ophthalmopathy: a novel approach. *Br J Ophthalmol* 1989;**73**:639–44.
8. **Wiersinga WM**, Kahaly GJ, eds. *Graves' orbitopathy. A multidisciplinary approach*. Basel: Karger, 2007

9. **Terwee CB**, Gerding MN, Dekker FW, *et al*. Development of a disease specific quality of life questionnaire for patients with Graves' ophthalmopathy: the GO-QOL. *Br J Ophthalmol* 1998;**82**:773–9.
10. **Wiersinga WM**, Perros P, Kahaly GJ, *et al*. Clinical assessment of patients with Graves' orbitopathy: The European Group on Graves' Orbitopathy (EUGOGO) recommendations to generalists, specialists and clinical researchers. *Eur J Endocrinol* 2006;**155**:207–11.
11. **Hertel E**, Simonsz HJ. Hertel: a simple exophthalmometer. *Strabismus* 2008;**16**:89–91.
12. **Gorman CA**, Garrity JA, Fatourechi V, *et al*. A prospective, randomized, double-blind, placebo-controlled study of orbital radiotherapy for Graves' ophthalmopathy. *Ophthalmology* 2001;**108**:1523–34.
13. **McCord CD Jr**. Orbital decompression for Graves' disease: exposure through lateral canthal and inferior fornix incision. *Ophthalmology* 1981;**88**:533–41.
14. **Shorr N**, Baylis HI, Goldberg RA, *et al*. Transcaruncular approach to the medial orbit and orbital apex. *Ophthalmology* 2000;**107**:1459–63.
15. **Krastinova D**, Rodallec A. Orbitopathie basedowienne [Basedowian orbitopathy]. *Ann Chir Plast Esthet* 1985;**30**:351–8.
16. **Kennedy DW**, Goodstein ML, Miller NR, *et al*. Endoscopic transnasal orbital decompression. *Arch Otolaryngol Head Neck Surg* 1990;**116**:275–82.
17. **Walsh TE**, Ogura JH. Transantral orbital decompression for malignant exophthalmus. *Laryngoscope* 1957;**67**:544–67.
18. **Kalmann R**, Mourits MP, van der Pol JP, *et al*. Coronal approach for rehabilitative orbital decompression in Graves' ophthalmopathy. *Br J Ophthalmol* 1997;**81**:41–5.
19. **Baldeschi L**, MacAndie K, Hintschich C, *et al*. The removal of the deep lateral wall in orbital decompression: its contribution to exophthalmos reduction and influence on consecutive diplopia. *Am J Ophthalmol* 2005;**140**:642–7.
20. **Kacker A**, Kazim M, Murphy M, *et al*. "Balanced" orbital decompression for severe Graves' orbitopathy: technique with treatment algorithm. *Otolaryngol Head Neck Surg* 2003;**182**:228–35.
21. **Sellari-Franceschini S**, Berrettini S, Santoro A, *et al*. Orbital decompression in Graves' ophthalmopathy by medial and lateral wall decompression. *Otolaryngol Head Neck Surg* 2005;**133**:185–9.
22. **Terwee CB**, Dekker FW, Mourits MP, *et al*. Interpretation and validity of changes in scores on the Graves' ophthalmopathy quality of life questionnaire (GO-QOL) after different treatments. *Clin Endocrinol* 2001;**54**:391–8.