

Severe Complication of Thiopurine Treatment in a Young Woman with Crohn's Disease

MPJ Voet¹, TGA Calon¹, MMC Hendriks¹, RM Schreuder²

¹Department of Internal Medicine, Catharina Ziekenhuis, Eindhoven, The Netherlands

²Department of Gastroenterology and Hepatology, Catharina Ziekenhuis, Eindhoven, The Netherlands

Doi: 10.12890/2021_002350- European Journal of Case Reports in Internal Medicine - © EFIM 2021

Received: 03/02/2021

Accepted: 25/02/2021

Published: 29/03/2021

How to cite this article: Voet MPJ, Calon TGA, Hendriks MMC, Schreuder RM. Severe complication of thiopurine treatment in a young woman with Crohn's disease. *EJCRIM* 2021;8: doi:10.12890/2021_002350.

Conflicts of Interests: The Authors declare that there are no competing interests.

This article is licensed under a [Commons Attribution Non-Commercial 4.0 License](https://creativecommons.org/licenses/by-nc/4.0/)

ABSTRACT

Case description: A 28-year old woman receiving thiopurine treatment for Crohn's disease presented with a systemic primo cytomegalovirus (CMV) infection affecting the gut (colitis), liver (hepatitis), lungs (pneumonitis) and eyes (retinitis). Secondary to this systemic infection, she developed splenomegaly, pancytopenia and lymphadenopathy. Anti-viral treatment resulted in complete resolution of clinical, biochemical and radiological abnormalities within 6 weeks.

Conclusion: Early recognition is crucial since CMV infection in a patient receiving thiopurine treatment may result in serious complications.

LEARNING POINTS

- Cytomegalovirus (CMV) infection in patients receiving thiopurine treatment may result in serious complications.
- This case report describes extensive primo CMV infection causing colitis, hepatitis, pneumonitis and retinitis in a patient receiving thiopurine treatment.
- Early recognition and treatment of the infection is crucial.

KEYWORDS

Cytomegalovirus, thiopurine, pneumonitis, colitis, hepatitis

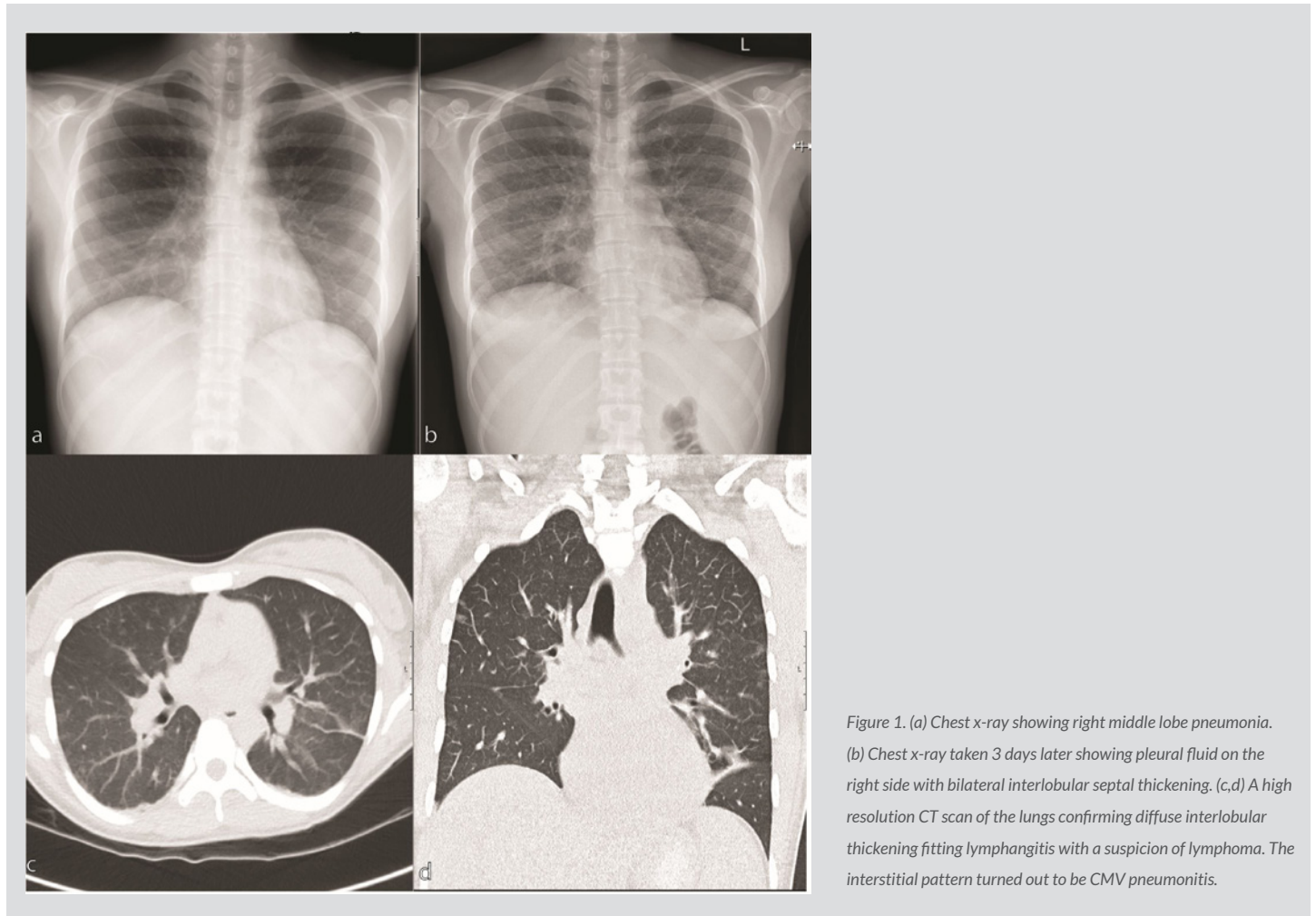
CASE DESCRIPTION

A 28-year-old Caucasian woman was referred to our emergency department with fever, diarrhoea, cough and visual disturbances. Her medical history reported Crohn's disease, which had been remission with 6-mercaptopurine (Puri-nethol, Aspen, KwaZulu-Natal, South Africa) for the previous 4 years.

Physical examination revealed no abnormalities. Laboratory assessment showed pancytopenia and elevated liver enzymes, but was otherwise unremarkable. The initial chest x-ray showed an infiltrate in the right middle lobe (*Fig. 1a*). Abdominal ultrasound showed splenomegaly, enlarged para-aortal lymph nodes and a thickened wall of the ascending colon.

During admission, the patient's condition deteriorated and she developed high fever (>40°C) and progressive shortness of breath. She also still had diarrhoea. Blood cultures remained negative. Faeces PCR testing was negative for viruses, bacteria and parasites. A follow-up chest x-ray showed an interstitial pattern suggestive for lymphangitis and, retrospectively, pneumonitis (*Fig. 1b*). A chest CT scan confirmed lymphangitis with a suspicion of lymphoma (*Fig. 1c,d*).

Bone marrow biopsy showed no evidence of a haemophagocytic syndrome or haematological malignancy. The tuberculin skin test was negative. Serological testing revealed a primo cytomegalovirus (CMV) infection (IgM-positive, IgG-positive) with a viral load of 870,000 IU/ml. The consulted ophthalmologist noticed a cotton wool spot on the retina of the right eye.



Systemic CMV infection affecting the gut (colitis), liver (hepatitis), eyes (retinitis) and lungs (pneumonitis) was diagnosed. The patient had also developed splenomegaly, pancytopenia and lymphadenopathy secondary to this infection.

The patient was treated with intra-venous ganciclovir for 14 days followed by oral valganciclovir for 4 weeks, resulting in complete resolution of her clinical, biochemical, radiographic and ophthalmological abnormalities.

DISCUSSION

Seropositivity for CMV in the adult population can vary between 45% and 100% [1]. The rate of positivity is higher in non-Caucasian populations and in older adults [1]. In Western Europe, the majority of young adults are seronegative for CMV. In immunocompetent individuals, CMV infection is usually asymptomatic or causes non-specific viral symptoms.

The risk of a severe systemic CMV infection is increased among individuals on immunosuppressive medication, like thiopurines [2,3]. In case of systemic disease, there can be involvement of the gastrointestinal tract and central nervous system, and haematological disorders [4-6]. Less frequently, retinitis, pneumonitis and vascular thrombosis can occur [6,7].

A review by Cascio et al. found 13 cases of CMV pneumonitis in subjects receiving thiopurines for inflammatory bowel disease, of whom eight were transferred to intensive care and four (30%) died [8]. In previously published cases, pneumonitis was seen as infiltrates or an interstitial pattern on chest radiography [8]. In our case, the second x-ray and following CT scan of the lungs showed diffuse interlobular septal thickening with a pattern fitting lymphangitis suggestive for lymphoma. As thiopurines have been associated with an increased risk

of lymphoma, haematological malignancies should be considered in patients on immunosuppressive medication with enlarged lymph nodes^[9]. However, benign diffuse lymph node enlargement can be seen as well in CMV infection^[10]. In our patient, these anomalies resolved after she completed anti-viral treatment.

Primary or reactivated CMV infection is preferably diagnosed using a PCR test with CMV DNA^[11]. Histological evaluation of biopsy specimens from involved organs also has high sensitivity^[11]. IgM and IgG serology is not recommended^[11]. Viral cultures are not advised due to their time-consuming nature^[11]. The possibility of monitoring viral load is an additional benefit of PCR testing. Treatment should be continued until an undetectable viral load is achieved^[8].

The European Crohn's and Colitis Organization recommends treating CMV infection with ganciclovir^[11]. Primary treatment should be initiated intravenously with a switch to oral valganciclovir whenever possible^[11]. In severe cases, early treatment is recommended to improve outcomes^[8, 11]. Haemophagocytic lymphohistiocytosis is the most severe complication associated with thiopurine treatment for Crohn's disease. It is mostly observed in cases of primo Epstein-Barr virus (EBV) infection, but may occur in primo CMV infection as well^[12,13]. Therefore, a bone marrow biopsy should be performed in individuals receiving thiopurines who present with pancytopenia, elevated ferritin levels and unexplained fever. In our case, bone marrow evaluation excluded haemophagocytic lymphohistiocytosis.

Screening for previous EBV and CMV infection before initiation of thiopurine treatment is not routinely recommended in the Dutch guideline for Crohn's disease^[3]. Therefore, a primo infection might occur during treatment with possibly severe complications^[14]. As the occurrence of a severe primo infection seems to be rare, in our opinion there is no reason for withholding thiopurine treatment if screening is negative for previous infection. However, a patient on thiopurine treatment presenting with symptoms that might fit EBV or CMV infection should be tested early as long as there is no other proven cause of the symptoms.

Conclusion

We present a case of severe generalized primo CMV infection in an immunocompromised patient receiving thiopurines for Crohn's disease. This case illustrates the risks related to thiopurine treatment, and so early recognition of possible complications is crucial.

REFERENCES

1. Cannon MJ, Schmid DS, Hyde TB. Review of cytomegalovirus seroprevalence and demographic characteristics associated with infection. *Rev Med Virol* 2010;**20**:202–213.
2. Gomollón F, Dignass A, Annesse V, Tilg H, Van Assche G, Lindsay JO, et al. 3rd European evidence-based consensus on the diagnosis and management of Crohn's disease 2016: Part 1: Diagnosis and medical management. *J Crohn's Colitis* 2017;**11**:3–25.
3. Richtlijn diagnostiek en behandeling van inflammatoire darmziekten bij volwassenen. Haarlem: The Netherlands: Nederlandse Vereniging van Maag-Darm-Leverartsen; 2008.
4. Papadakis KA, Tung JK, Binder SW, Kam LY, Abreu MT, Targan SR, et al. Outcome of cytomegalovirus infections in patients with inflammatory bowel disease. *Am J Gastroenterol* 2001;**96**:2137–2142.
5. Kandiel A, Lashner B. Cytomegalovirus colitis complicating inflammatory bowel disease. *Am J Gastroenterol* 2006;**101**:2857–2865.
6. Rafailidis PI, Mourtzoukou EG, Varbobitis IC, Falagas ME. Severe cytomegalovirus infection in apparently immunocompetent patients: a systematic review. *Virol J* 2008;**5**:1–7.
7. Shukla T, Singh S, Tandon P, McCurdy JD. Corticosteroids and thiopurines, but not tumor necrosis factor antagonists, are associated with cytomegalovirus reactivation in inflammatory bowel disease. *J Clin Gastroenterol* 2017;**51**(5):394–401.
8. Cascio A, Iaria C, Ruggeri P, Fries W. Cytomegalovirus pneumonia in patients with inflammatory bowel disease: a systematic review. *Int J Infect Dis* 2012;**16**:e474–e479.
9. Beaugerie L, Brousse N, Bouvier AM, Colombel JF, Lémann M, Cosnes J, et al. Lymphoproliferative disorders in patients receiving thiopurines for inflammatory bowel disease: a prospective observational cohort study. *Lancet* 2009;**374**:1617–1625.
10. Lum EL, Schaenman JM, DiNicola M, Reddy UG, Shen JI, Pullarkat ST. A case report of CMV lymphadenitis in an adult kidney transplant recipient. *Transpl Proc* 2015;**47**:141–145.
11. Rahier JF, Ben-Horin S, Chowers Y, Conlon C, De Munter P, D'Haens G, et al. European evidence-based consensus on the prevention, diagnosis and management of opportunistic infections in inflammatory bowel disease. *J Crohn's Colitis* 2009;**3**:47–91.
12. Biank VF, Sheth MK, Talano J, Margolis D, Simpson P, Kugathasan S, et al. Association of Crohn's disease, thiopurines and primary EBV infection with hemophagocytic lymphohistiocytosis. *J Pediatr* 2011;**159**:808–812.
13. Van Langenberg DR, Morrison G, Foley A, Buttigieg RJ, Gibson PR. Cytomegalovirus disease, haemophagocytic syndrome, immunosuppression in patients with IBD: 'A cocktail best avoided, not stirred'. *J Crohn's Colitis* 2011;**5**:469–472.
14. Abreu C, Sarmiento A, Magro F. Screening, prophylaxis and counselling before the start of biological therapies: a practical approach focused on IBD patients. *Dig Liver Dis* 2017;**49**:1289–1297.