

University of Groningen

Airway granulation response to lung-implantable medical devices

Roodenburg, Sharyn A.; Pouwels, Simon D.; Slebos, Dirk-Jan

Published in:
European Respiratory Review

DOI:
[10.1183/16000617.0066-2021](https://doi.org/10.1183/16000617.0066-2021)

IMPORTANT NOTE: You are advised to consult the publisher's version (publisher's PDF) if you wish to cite from it. Please check the document version below.

Document Version
Publisher's PDF, also known as Version of record

Publication date:
2021

[Link to publication in University of Groningen/UMCG research database](#)

Citation for published version (APA):

Roodenburg, S. A., Pouwels, S. D., & Slebos, D-J. (2021). Airway granulation response to lung-implantable medical devices: a concise overview. *European Respiratory Review*, 30(161), [210066].
<https://doi.org/10.1183/16000617.0066-2021>

Copyright

Other than for strictly personal use, it is not permitted to download or to forward/distribute the text or part of it without the consent of the author(s) and/or copyright holder(s), unless the work is under an open content license (like Creative Commons).

The publication may also be distributed here under the terms of Article 25fa of the Dutch Copyright Act, indicated by the "Taverne" license. More information can be found on the University of Groningen website: <https://www.rug.nl/library/open-access/self-archiving-pure/taverne-amendment>.

Take-down policy

If you believe that this document breaches copyright please contact us providing details, and we will remove access to the work immediately and investigate your claim.

Downloaded from the University of Groningen/UMCG research database (Pure): <http://www.rug.nl/research/portal>. For technical reasons the number of authors shown on this cover page is limited to 10 maximum.



Airway granulation response to lung-implantable medical devices: a concise overview

Sharyn A. Roodenburg^{1,2}, Simon D. Pouwels ^{1,2,3} and Dirk-Jan Slebos ^{1,2}

¹Dept of Pulmonary Diseases, University of Groningen, University Medical Center Groningen, Groningen, The Netherlands. ²Groningen Research Institute for Asthma and COPD, University of Groningen, University Medical Center Groningen, Groningen, The Netherlands. ³Dept of Pathology and Medical Biology, University of Groningen, University Medical Center Groningen, Groningen, The Netherlands.

Corresponding author: Sharyn Roodenburg (s.a.roodenburg@umcg.nl)



Shareable abstract (@ERSpublications)

Medical implantable devices are increasingly used in pulmonary medicine. Complications related to the tissue-device interaction are often present, but our knowledge of the underlying processes is limited. <https://bit.ly/2RdWVvK>

Cite this article as: Roodenburg SA, Pouwels SD, Slebos D-J. Airway granulation response to lung-implantable medical devices: a concise overview. *Eur Respir Rev* 2021; 30: 210066 [DOI: 10.1183/16000617.0066-2021].

Copyright ©The authors 2021

This version is distributed under the terms of the Creative Commons Attribution Non-Commercial Licence 4.0. For commercial reproduction rights and permissions contact permissions@ersnet.org

Received: 10 March 2021
Accepted: 26 May 2021

Abstract

Increasing numbers of endoscopically implantable devices are implanted in the airways, such as airway stents, one-way valves and coils, to treat both malignant and benign diseases. They significantly improve patient outcomes, but their long-term effectiveness and sustainability is hampered by the reaction of the formation of granulation tissue. Factors including procedural-related tissue injury; micro-organism presence; device-related factors, such as the material, design and sizing in relation to the airway; and patient-related factors, including genetic susceptibility, comorbidities and medication use, might all effect the severity of the tissue response and the subsequent degree of granulation tissue formation. However, research into the underlying mechanism and risk factors is scarce and therefore our knowledge is limited. Joint efforts from the scientific community, both pre-clinical and clinical, are needed to gain a deeper understanding and eventually improve the long-term treatment effectiveness of lung-implantable devices.

Introduction

Interventional pulmonology is a rapidly developing field within pulmonary medicine. Minimally invasive techniques are used to perform diagnostic and therapeutic procedures for lung diseases. Increasing numbers of endoscopically implantable devices are being placed in the airways, including a wide variety of airway stents, one-way valves and coils [1]. These implantable devices are used for both malignant (e.g. lung cancer) and benign (e.g. post-lung transplant pathology and lung volume reduction) diseases [2, 3]. They provide significant improvements in patient outcomes, but their long-term effectiveness and sustainability is hampered by the tissue reaction of the airways upon implantation. One of the most common complications associated with lung-implantable devices is the formation of granulation tissue [2, 4–6]. Granulation tissue is formed as part of the natural wound healing process and consists of accumulated inflammatory cells, newly formed connective tissue and small blood vessels (figure 1). It often presents asymptotically, but it is also frequently associated with loss of treatment effectiveness [5, 7]. Furthermore, it is one of the most common reasons for additional bronchoscopic procedures, which form a risk and burden for the patient [5–7].

Since their introduction in the 1960s, airway stents have been widely used to manage both benign and malignant central airway stenosis, airway fistulas and post-lung transplant anastomotic complications [8]. The two main types of airway stents available are silicone and self-expandable metallic stents. All stent types are associated with a substantial risk of granulation tissue formation, but the risk varies greatly between studies. It can cause (re-)stenosis of the central airway requiring frequent additional bronchoscopic interventions. Furthermore, it is the main reason their usage is discouraged in benign diseases, especially when patients have an expected long-term survival and when other treatment options are available [2].



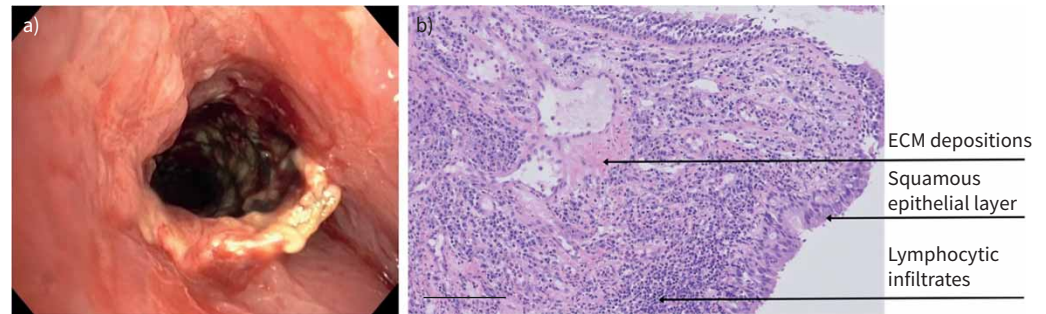


FIGURE 1 Granulation tissue in the airway formed after implantation of a covered self-expanding nitinol bronchial airway stent. **a)** Bronchoscopic image of granulation tissue with stent in place. **b)** Haematoxylin and eosin stain image of airway granulation tissue (10× magnification). ECM: extracellular matrix. Scale bar=100 µm.

Both one-way valves and coils are bronchoscopic treatment options for patients suffering from severe emphysema with evident hyperinflation [9–11]. Valves and coils function through a separate mechanism of action, but both aim for lung volume reduction. Valves have a one-way mechanism allowing air to leave the treated lobe during expiration, but block air from flowing in during inspiration aiming for complete atelectasis of the treated lobe [9]. Endobronchial coils are preformed nitinol wires that regain their shape following deployment in the airways, mainly causing a local reduction in hyperinflation and decreased airway resistance [12–14]. To date, valves have been adopted into treatment guidelines where coils have only been used in clinical trials [14–19]. Clinically significant granulation tissue formation is a common finding following valve treatment [5, 6, 20, 21]. In a significant number of cases, it results in a loss of initial treatment effect due to valve dysfunction caused by the formed granulation tissue [20]. In contrast, granulation tissue formation after coil treatment has not been described.

The success of all these treatments is heavily affected by the tissue response upon device implantation. However, research dedicated to unravelling the underlying mechanism and the driving forces of airway granulation tissue formation after device implantation is limited. A deeper understanding will help to improve the devices, treatments and subsequently the quality of life of the treated patients. This review will serve as an introduction into the current understanding. Furthermore, we will discuss the remaining questions and unknowns guiding future research.

Host response to device implantation

Implantation of any medical device causes some degree of injury to the local tissue [22]. Following this injury, an interaction between the host immune system and the implanted device will occur. The implanted device acquires a layer of host proteins forming a provisional matrix [23]. The (surface) properties of the implanted device and the severity of tissue disruption influence the types, concentrations and conformations of the absorbed proteins, which in turn influence the subsequent inflammatory response [23, 24]. The acute inflammation phase is characterised by the infiltration of neutrophils to the site of implantation [23, 25]. This phase is short-lived, usually lasting less than 1 week [23, 25]. The presence of a device (*i.e.* a foreign body) initiates a pro-inflammatory state attracting mononuclear cells (such as monocytes and lymphocytes), initiating the chronic inflammatory phase [23, 24, 26]. Macrophages try to phagocytose the implanted device and in an attempt to increase their phagocytic capacity they can fuse and form foreign body giant cells (FBGCs), which are described as a hallmark of the foreign body reaction [24]. However, to form FBGCs, appropriate fusion-inducing stimuli need to be present as well as a material with the appropriate adherent proteins on the surface [23]. Therefore, not all implanted devices will cause FBGC formation. The inflammatory and foreign body response attract fibroblasts and endothelial cells to the implantation site [24]. These cells deposit collagen and other extracellular matrix proteins, which form granulation tissue around the implanted device [24, 27]. Eventually, this granulation tissue matures into fibrous tissue [24]. The amount of granulation and fibrous tissue formed is dependent on the severity of the previous inflammatory response [28]. A summary of the foreign body reaction is shown in figure 2. Surprisingly, this reaction has not been studied for airway tissue upon device implantation.

Micro-organism presence

The implantation of airway devices is associated with an increase in microbiological colonisation [29, 30]. It has been hypothesised that micro-organism presence at the site of implantation leads to a more severe or

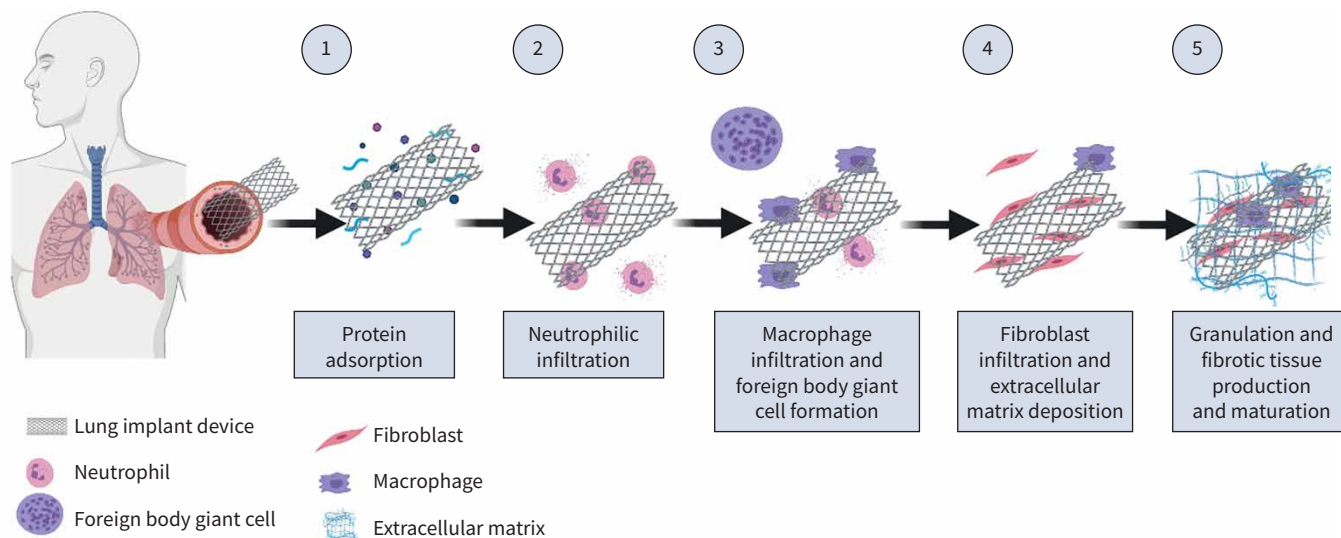


FIGURE 2 Foreign body reaction upon device implantation.

persistent tissue response upon device implantation causing significant granulation tissue formation [22, 27]. Two studies described a correlation between granulation tissue formation after airway stenting and airway colonisation [31, 32]. Both studies identified a correlation between airway colonisation with *Pseudomonas aeruginosa* and granulation tissue formation after airway stenting [31, 32]. One of the studies also identified a correlation between airway colonisation with *Staphylococcus aureus* and granulation tissue formation [32]. However, the findings in these studies should be interpreted with caution. Both studies used culture-based methods to identify the presence of micro-organisms. A disadvantage of culture-based methods is that the constituents of the growth medium determine which micro-organisms can be cultured. Therefore, micro-organisms that might play a role in the tissue response may be undetected. Furthermore, both studies had a small sample size and a causal relationship between micro-organism presence and granulation tissue formation cannot be determined, because the cultures were obtained when granulation tissue was already present.

OST *et al.* studied the relationship between respiratory tract infections and granulation tissue formation after airway stenting [33]. Their multivariate analysis identified respiratory tract infections as a risk factor for granulation tissue development. However, not all patients underwent bronchoscopy at time of the respiratory tract infection. Therefore, it is unknown if granulation tissue was already present at the time of infection.

Based on these studies, no hard conclusions can be drawn on the effects of micro-organism presence on the development of granulation tissue formation. Future well-designed, prospective studies using more advanced culture methods and structured sampling are needed to identify if micro-organisms play a role in the tissue response upon device implantation in the airways, and, if so, what their contribution is.

Device-related factors

The airway tissue is continuously being stretched during inspiration. If the surrounding tissue is rubbing against the implant, mechanical friction occurs, which could cause repetitive injury to the tissue, mainly at the “sharper” edges of the device [7, 33, 34]. McGRATH *et al.* [7] used a computer model to study stent–tissue interactions. Contact pressure change during the respiratory cycle was used as a measure for relative motion between the stent and adjacent tissue. The highest pressure change was observed at the proximal end of the stent, with areas of high pressure change also found at the distal end of the stent. In contrast, only a minor pressure change was observed in the medial portion of the stented region. These findings are in accordance with the *in vivo* situation at which granulation tissue formation is mainly observed at the stent–mucosal interface and is most frequent and/or severe at the proximal end [7, 35, 36]. The shape and design of the device and the material(s) it is composed of will likely affect the amount of friction and the amount of tissue damage. It could be speculated that devices with sharper edges or rougher surfaces cause more damage to the surrounding tissue and if friction is present this damage will be repetitive and result in (more severe) granulation tissue formation (figure 3).




FIGURE 3 Scanning electron microscope image of uncovered airway stent (Ultraflex™ Tracheobronchial stent, Boston Scientific, Galway, Ireland). Macroscopically, the stent surface appears even. Magnification shows the roughness of the surface that could accommodate cell adhesion which drives the foreign body response upon implantation, leading to a more severe repetitive injury during the respiratory cycle than a device with a smoother surface. a) 50× magnification. b) 250× magnification. c) 2500× magnification. d) 15000× magnification.

Implanted airway devices almost always exert some pressure on the airway wall, which is necessary to keep the device in place. However, excessive pressure to the airway mucosa could result in impaired microcirculation, which might stimulate granulation tissue formation [37]. A computer model from McGRATH *et al.* [7] found that wall stress was minimally affected by the insertion of an airway stent and the highest amount of wall stress was found at the distal end of the stent due to tapering of the airways, which does not correspond with *in vivo* observations. However, in this model only one stent size was tested. A clinical study found an association between a higher implant-to-airway size ratio and granulation tissue formation [36]. A computer model also found a positive correlation between implant-to-airway size ratios and wall stress [37]. However, in this model wall stress was not particularly high at any specific stent region, which does not correspond with the *in vivo* observations. Furthermore, this model found that the stiffness of the material and the stent design affected wall stress independent of the implant-to-airway size ratio [37].

None of the studies investigated the biological mechanism involved in increased mucosal-device friction and/or pressure and the development of granulation and fibrotic tissue. It is, however, tempting to speculate that these factors, especially friction, repetitively cause tissue injury accompanied by cellular damage. Cellular damage can induce the release of danger signals, named damage-associated molecular patterns (DAMPs), molecular signals which alert and activate the innate immune system to resolve the damage and danger [38, 39]. DAMPs are molecules that under physiological conditions reside intracellularly, but upon cellular damage or necrotic cell death are released into the extracellular space. Once released into the extra cellular space, DAMPs can activate pattern recognition receptors on cells of the innate immune systems, including airway epithelial cells, ultimately resulting in a local inflammatory reaction [40]. The cellular damage induced by devices implanted into the airway will induce acute DAMP release upon implantation, but DAMP release may become chronic upon friction or pressure induced by lung implants, potentially resulting in the formation of granulation and subsequently fibrotic tissue [39].

Patient-related factors

In contrast to the device-related factors, which remain largely the same from implantation to months and years later, patient-related factors, such as age, comorbidities and medication use, could significantly change over time. Since plasma proteins and the immune system are the main modulators of the foreign body response, factors influencing these might be the strongest influencers of the tissue response.

Medication use

A number of patients receiving a lung-implantable device use medications with immunomodulatory effects, such as immunosuppressives used by lung transplant patients or (inhaled) corticosteroids in patients with COPD. In the study by SHLOMI *et al.* [41], patients using immunosuppressives after lung transplantation showed a significant lower degree of granulation tissue formation after airway stenting compared with patients not taking immunosuppressives. In contrast, SAAD *et al.* [34] found the rate of granulation tissue formation to be equal for post-lung transplant patients and patients who underwent airway stenting for other benign causes. The main difference between these studies is that in the first, patients routinely underwent a bronchoscopic evaluation every 3 months and, in the latter, only 6 and 12 weeks after implantation and on indication. The difference in outcomes could be explained by patients with asymptomatic granulation tissue formation. To the best of our knowledge, no studies have been performed investigating the effect of corticosteroids on granulation tissue formation.

Genetic susceptibility

Abundant granulation tissue formation upon device implantation can be interpreted as “wound healing gone wrong”. A possible comparable condition is keloid scarring in skin wound healing. This is a dermal fibroproliferative disease in which there is an excessive deposition of collagen at the site of healed injury [42]. There is strong evidence that keloid formation is associated with different genetic and epigenetic factors, which is highlighted by the fact that keloid formation is more common in individuals with a nonwhite ethnicity and a positive family history of keloid formation [42]. EOM *et al.* [43] identified tracheal wall thickness as an independent predictor for granulation tissue formation after airway stenting in patients suffering from post-tuberculosis tracheal stenosis. This might be explained by inter-individual differences in healing responses. It is likely that for airway granulation tissue formation after device implantation individual differences in susceptibility are also present. Future studies should be directed at identifying genetic factors associated with susceptibility for the development of granulation tissue upon endoscopic device implantation, using genome-wide approaches.

Concluding remarks and future directions

In this review we have provided an overview of the factors involved in the development of granulation tissue after device implantation in the airways. The evidence for a potential key role of micro-organisms in instigating the formation of granulation tissue is minimal and mainly based on small, culture-based, retrospective studies. Future studies should investigate the presence of micro-organisms on explanted devices using a metagenomics sequencing approach to fully investigate the presence of micro-organisms in a nonbiased way, both in patients with granulation tissue and those without. We propose that, in addition to micro-organisms, DAMPs, released from lung cells damaged by the presence of a nonflexible foreign material device in a flexible and continuously dynamic airway, can also contribute to the onset of an inflammatory response, ultimately leading to the formation of granulation tissue around the implanted device. Furthermore, host factors, such as genetic susceptibility to develop airway inflammation or a more severe inflammatory response in general upon a damaging stimulus, may contribute to the development of granulation tissue [39, 44]. In addition to host factors, device-related factors, such as the physical and chemical characteristics of the device, will most certainly play a role in the reaction upon implantation. The surface characteristics of the device in particular can affect protein adsorption, cell adhesion and differentiation and, with that, affect the following inflammatory response [24].

For decades, intervention pulmonologists have been implanting devices into the airways. The development of these lung-implantable devices has provided us with new treatment opportunities and less invasive

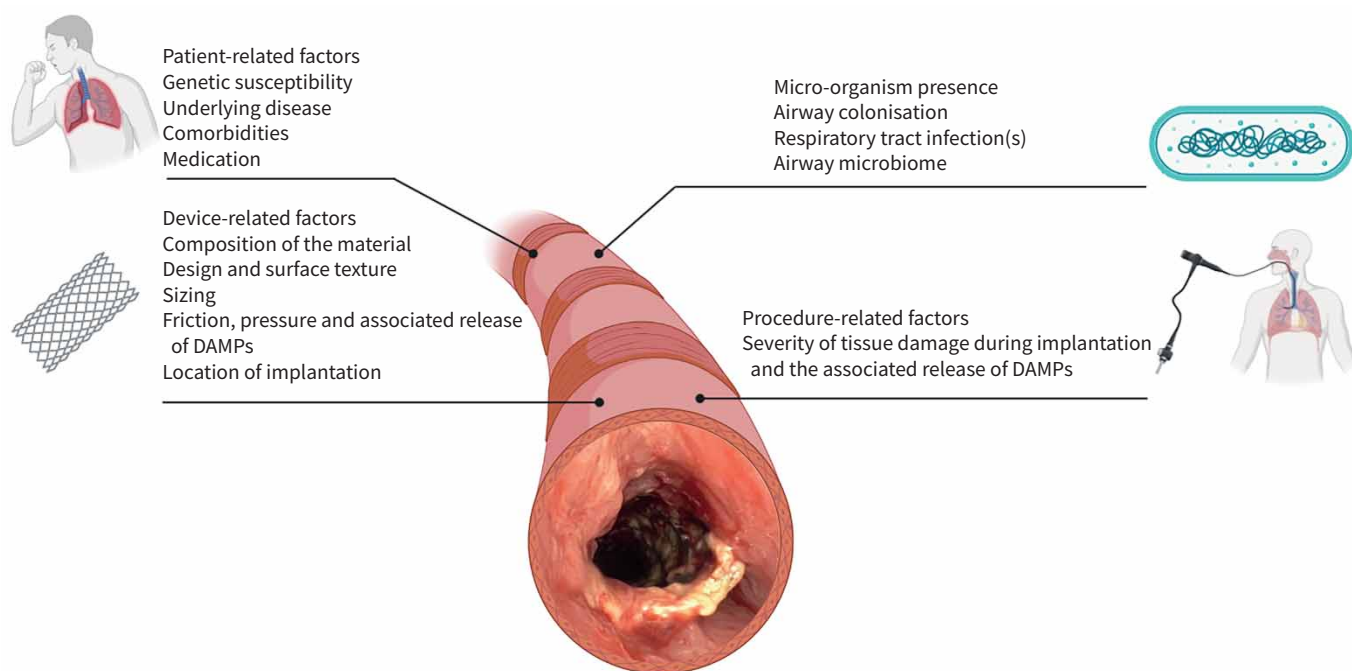


FIGURE 4 Hypothetical model of factors that might influence the airway tissue response upon device implantation. DAMP: damage-associated molecular pattern.

treatment options. However, the tissue response following implementation is one of the major challenges, but our knowledge limited. Innovative attempts are being made to reduce complications, such as 3D-printed stents or bioresorbable stents [45, 46], but a better understanding of the underlying processes and factors contributing to this tissue response is urgently needed. As the number of patients treated with lung-implantable devices will likely increase with the development of new devices, this knowledge will help to guide the attempts to reduce this response. A large variety of factors can influence multiple phases of the tissue response. The complex nature of this response requires joint efforts from the scientific community to combine both pre-clinical as well as clinical evidence to gain more insights into the mechanisms and factors driving and influencing the tissue response of the airways upon device implantation. To direct future research, we propose a hypothetical model of factors that might influence the tissue response (figure 4).

Provenance: Submitted article, peer reviewed.

Conflict of interest: S.A. Roodenburg has nothing to disclose. S.D. Pouwels has nothing to disclose. D-J. Slebos reports grants or contracts, consulting fees, honoraria and travel expenses from PulmonX Corp USA; and grants or contracts, honoraria and travel expenses from PneumRX/BTG USA, outside the submitted works.

References

- 1 Criner GJ, Eberhardt R, Fernandez-Bussy S, *et al.* Interventional bronchoscopy. *Am J Respir Crit Care Med* 2020; 202: 29–50.
- 2 Guibert N, Saka H, Dutau H. Airway stenting: technological advancements and its role in interventional pulmonology. *Respirology* 2020; 25: 953–962.
- 3 Shah PL, Slebos D. Bronchoscopic interventions for severe emphysema: where are we now? *Respirology* 2020; 25: 972–980.
- 4 Murgu SD, Egressy K, Laxmanan B, *et al.* Central airway obstruction. *Chest* 2016; 150: 426–441.
- 5 Gompelmann D, Gerovasili V, Kontogianni K, *et al.* Endoscopic valve removal >180 days since implantation in patients with severe emphysema. *Respiration* 2018; 96: 348–354.
- 6 Roodenburg SA, Klooster K, Hartman JE, *et al.* Revision bronchoscopy after endobronchial valve treatment for emphysema: indications, findings and outcomes. *Int J COPD* 2021; 16: 1127–1136.
- 7 McGrath DJ, Thiebes AL, Cornelissen CG, *et al.* Evaluating the interaction of a tracheobronchial stent in an ovine in-vivo model. *Biomech Model Mechanobiol.* 2018; 17: 499–516.
- 8 Ayub A, Al-Ayoubi AM, Bhora FY. Stents for airway strictures: selection and results. *J Thorac Dis* 2017; 9: S116–S121.
- 9 Slebos D-J, Shah PL, Herth FJF, *et al.* Endobronchial valves for endoscopic lung volume reduction: best practice recommendations from expert panel on endoscopic lung volume reduction. *Respiration* 2017; 93: 138–150.
- 10 Slebos DJ, Ten Hacken NH, Hetzel M, *et al.* Endobronchial coils for endoscopic lung volume reduction: best practice recommendations from an expert panel. *Respiration* 2018; 96: 1–11.
- 11 Criner GJ, Delage A, Voelker K, *et al.* Improving lung function in severe heterogenous emphysema with the spiration valve system (emprove). A multicenter, open-label randomized controlled clinical trial. *Am J Respir Crit Care Med* 2019; 200: 1354–1362.
- 12 Herth FJF, Slebos DJ, Shah PL, *et al.* Protocol of a Randomized Controlled Study of the Pneumrx Endobronchial Coil System Versus Standard-of-Care Medical Management in the Treatment of Subjects with Severe Emphysema (ELEVATE). *Respiration* 2019; 98: 512–520.
- 13 Hartman JE, Shah PL, Sciruba F, *et al.* Endobronchial coils for emphysema: dual mechanism of action on lobar residual volume reduction. *Respirology* 2020; 25: 1160–1166.
- 14 Sciruba FC, Criner GJ, Strange C, *et al.* Effect of endobronchial coils vs usual care on exercise tolerance in patients with severe emphysema. *JAMA* 2016; 315: 2178–2189.
- 15 Deslée G, Mal H, Dutau H, *et al.* Lung volume reduction coil treatment vs usual care in patients with severe emphysema. *JAMA* 2016; 315: 175.
- 16 Shah PL, Zoumot Z, Singh S, *et al.* Endobronchial coils for the treatment of severe emphysema with hyperinflation (RESET): a randomised controlled trial. *Lancet Respir Med* 2013; 1: 233–240.
- 17 Zoumot Z, Kemp SV, Singh S, *et al.* Endobronchial coils for severe emphysema are effective up to 12 months following treatment: medium term and cross-over results from a randomised controlled trial. *PLoS ONE* 2015; 10: e0122656.
- 18 Global Initiative for Chronic Obstructive Lung Disease (GOLD). Global Strategy for the Diagnosis, Management, and Prevention of Chronic Obstructive Pulmonary Disease. 2020. Available from: www.goldcopd.org.
- 19 National Institute for Health and Care Excellence. Endobronchial valve insertion to reduce lung volume in emphysema. 2017. Available from: <https://www.nice.org.uk/guidance/ipg600/chapter/3-The-procedure>

- 20 Koster TD, Klooster K, Ten Hacken NHT, *et al.* Endobronchial valve therapy for severe emphysema: an overview of valve-related complications and its management. *Expert Rev Respir Med* 2020; 14: 1235–1247.
- 21 Fiorelli A, D’Andrilli A, Bezzi M, *et al.* Complications related to endoscopic lung volume reduction for emphysema with endobronchial valves: results of a multicenter study. *J Thorac Dis* 2018; 10: 3315–3325.
- 22 Jones K. Chapter 9: Fibrotic response to biomaterials and all associated sequence of fibrosis. In: Badylak SF, ed. *Host Response to Biomaterials*. Cambridge, MA, Academic Press, 2015; pp. 189–237.
- 23 Anderson JM, Rodriguez A, Chang DT. Foreign body reaction to biomaterials. *Semin Immunol* 2008; 20: 86–100.
- 24 Klopffleisch R, Jung F. The pathology of the foreign body reaction against biomaterials. *J Biomed Mater Res Part A* 2017; 105: 927–940.
- 25 Selders GS, Fetz AE, Radic MZ, *et al.* An overview of the role of neutrophils in innate immunity, inflammation and host-biomaterial integration. *Regen Biomater* 2017; 4: 55–68.
- 26 Zhou G, Groth T. Host responses to biomaterials and anti-inflammatory design – a brief review. *Macromol Biosci* 2018; 18: 1800112.
- 27 Anderson J, Cramer S. Perspectives on the inflammatory, healing, and foreign body responses to biomaterials and medical devices. *Host Response to Biomater* 2015; 13–36.
- 28 Major MR, Wong VW, Nelson ER, *et al.* The foreign body response. *Plast Reconstr Surg* 2015; 135: 1489–1498.
- 29 Sarmand N, Gompelmann D, Kontogianni K, *et al.* New bacterial growth in bronchial secretions after bronchoscopic valve implantation. *Int J Chron Obstruct Pulmon Dis* 2018; 13: 565–570.
- 30 Noppen M, Piérard D, Meysman M, *et al.* Bacterial colonization of central airways after stenting. *Am J Respir Crit Care Med* 1999; 160: 672–677.
- 31 Schmäl F, Fegeler W, Terpe HJ, *et al.* Bacteria and granulation tissue associated with montgomery T-tubes. *Laryngoscope* 2003; 113: 1394–1400.
- 32 Nouraei SAR, Petrou MA, Randhawa PS, *et al.* Bacterial colonization of airway stents. *Arch Otolaryngol Neck Surg* 2006; 132: 1086.
- 33 Ost DE, Shah AM, Lei X, *et al.* Respiratory infections increase the risk of granulation tissue formation following airway stenting in patients with malignant airway obstruction. *Chest* 2012; 141: 1473–1481.
- 34 Saad CP, Murthy S, Krizmanich G, *et al.* Self-expandable metallic airway stents and flexible bronchoscopy. *Chest* 2003; 124: 1993–1999.
- 35 Debiane L, Reitzel R, Rosenblatt J, *et al.* A design-based stereologic method to quantify the tissue changes associated with a novel drug-eluting tracheobronchial stent. *Respiration* 2019; 98: 60–69.
- 36 Hu H-C, Liu Y-H, Wu Y-C, *et al.* Granulation tissue formation following dumon airway stenting: the influence of stent diameter. *Thorac Cardiovasc Surg* 2011; 59: 163–168.
- 37 Ratnovsky A, Regev N, Wald S, *et al.* Mechanical properties of different airway stents. *Med Eng Phys* 2015; 37: 408–415.
- 38 Zindel J, Kubes P. DAMPs, PAMPs, and LAMPs in immunity and sterile inflammation. *Annu Rev Pathol Mech Dis* 2020; 15: 493–518.
- 39 Pouwels SD, Heijink IH, ten Hacken NH, *et al.* DAMPs activating innate and adaptive immune responses in COPD. *Mucosal Immunol* 2014; 7: 215–226.
- 40 Pouwels SD, Hesse L, Faiz A, *et al.* Susceptibility for cigarette smoke-induced DAMP release and DAMP-induced inflammation in COPD. *Am J Physiol Cell Mol Physiol* 2016; 311: L881–L892.
- 41 Shlomi D, Peled N, Shitrit D, *et al.* Protective effect of immunosuppression on granulation tissue formation in metallic airway stents. *Laryngoscope* 2008; 118: 1383–1388.
- 42 Tsai C-H, Ogawa R. Keloid research: current status and future directions. *Scars, Burn Heal* 2019; 5.
- 43 Eom JS, Kim H, Jeon K, *et al.* Tracheal wall thickening is associated with the granulation tissue formation around silicone stents in patients with post-tuberculosis tracheal stenosis. *Yonsei Med J* 2013; 54: 949.
- 44 Pouwels SD, Heijink IH, Brouwer U, *et al.* Genetic variation associates with susceptibility for cigarette smoke-induced neutrophilia in mice. *Am J Physiol Cell Mol Physiol* 2015; 308: L693–L709.
- 45 Stramiello JA, Mohammadzadeh A, Ryan J, *et al.* The role of bioresorbable intraluminal airway stents in pediatric tracheobronchial obstruction: a systematic review. *Int J Pediatr Otorhinolaryngol.* 2020; 139: 110405.
- 46 Xu J, Ong HX, Traini D, *et al.* The utility of 3D-printed airway stents to improve treatment strategies for central airway obstructions. *Drug Dev Ind Pharm.* 2019; 45: 1–10.