

University of Groningen

First-line treatment of persistent and long-standing persistent atrial fibrillation with single-stage hybrid ablation

Magni, Federico T; Al-Jazairi, Meelad I H; Mulder, Bart A; Klinkenberg, Theo; Van Gelder, Isabelle C; Rienstra, Michiel; Mariani, Massimo A; Blaauw, Yuri

Published in:
Europace

DOI:
[10.1093/europace/euab093](https://doi.org/10.1093/europace/euab093)

IMPORTANT NOTE: You are advised to consult the publisher's version (publisher's PDF) if you wish to cite from it. Please check the document version below.

Document Version
Publisher's PDF, also known as Version of record

Publication date:
2021

[Link to publication in University of Groningen/UMCG research database](#)

Citation for published version (APA):

Magni, F. T., Al-Jazairi, M. I. H., Mulder, B. A., Klinkenberg, T., Van Gelder, I. C., Rienstra, M., Mariani, M. A., & Blaauw, Y. (2021). First-line treatment of persistent and long-standing persistent atrial fibrillation with single-stage hybrid ablation: a 2-year follow-up study. *Europace*, 23(10), 1568-1576. [euab093]. <https://doi.org/10.1093/europace/euab093>

Copyright

Other than for strictly personal use, it is not permitted to download or to forward/distribute the text or part of it without the consent of the author(s) and/or copyright holder(s), unless the work is under an open content license (like Creative Commons).

The publication may also be distributed here under the terms of Article 25fa of the Dutch Copyright Act, indicated by the "Taverne" license. More information can be found on the University of Groningen website: <https://www.rug.nl/library/open-access/self-archiving-pure/taverne-amendment>.

Take-down policy

If you believe that this document breaches copyright please contact us providing details, and we will remove access to the work immediately and investigate your claim.

Downloaded from the University of Groningen/UMCG research database (Pure): <http://www.rug.nl/research/portal>. For technical reasons the number of authors shown on this cover page is limited to 10 maximum.

First-line treatment of persistent and long-standing persistent atrial fibrillation with single-stage hybrid ablation: a 2-year follow-up study

Federico T. Magni ^{1,2}, Meelad I.H. Al-Jazairi¹, Bart A. Mulder¹, Theo Klinkenberg², Isabelle C. Van Gelder¹, Michiel Rienstra ¹, Massimo A. Mariani², and Yuri Blaauw^{1*}

¹Department of Cardiology, University of Groningen, University Medical Center Groningen, PO Box 30.001, 9700 RB Groningen, The Netherlands; and ²Department of Cardiothoracic Surgery, University of Groningen, University Medical Center Groningen, Groningen, The Netherlands

Received 9 September 2020; editorial decision 20 March 2021; accepted after revision 26 March 2021

Aims

This study evaluates the efficacy and safety of *first-line* single-stage hybrid ablation of (long-standing) persistent atrial fibrillation (AF), over a follow-up period of 2 years, and provides additional information on arrhythmia recurrences and electrophysiological findings at repeat ablation.

Methods and results

This is a prospective cohort study that included 49 patients (65% persistent AF; 35% long-standing persistent AF) who underwent hybrid ablation as first-line ablation treatment (no previous endocardial ablation). Patients were relatively young (57.0 ± 8.5 years) and predominantly male (89.8%). Median CHA₂DS₂-VASc score was 1.0 (0.5; 2.0) and mean left atrium volume index was 43.7 ± 10.9 mL/m². Efficacy was assessed by 12-lead electrocardiography and 72-h Holter monitoring after 3, 6, 12, and 24 months. Recurrence was defined as AF/atrial flutter (AFL)/tachycardia (AT) recorded by electrocardiography or Holter monitoring lasting >30 s during 2-year follow-up. At 2-year follow-up, single and multiple procedure success rates were 67% and 82%, respectively. Two (4%) patients experienced a major complication (bleeding) requiring intervention following hybrid ablation. Among the 16 (33%) patients who experienced an AF/AFL/AT recurrence, 13 (81%) were ATs/AFLs and only 3 (19%) were AF. Repeat ablation was performed in 10 (20%) patients and resulted in sinus rhythm in 7 (70%) at 2-year follow-up.

Conclusion

First-line single-stage hybrid AF ablation is an effective treatment strategy for patients with persistent and long-standing persistent AF with an acceptable rate of major complications. Recurrences are predominantly AFL/AT that can be successfully ablated percutaneously. Hybrid ablation seems a feasible approach for first-line ablation of (long-standing) persistent AF.

Keywords

Atrial fibrillation • Catheter ablation • Surgical ablation • Hybrid atrial fibrillation ablation • Persistent atrial fibrillation

* Corresponding author. Tel: +31 62 290 8714. E-mail address: y.blaauw01@umcg.nl

© The Author(s) 2021. Published by Oxford University Press on behalf of the European Society of Cardiology.

This is an Open Access article distributed under the terms of the Creative Commons Attribution Non-Commercial License (<http://creativecommons.org/licenses/by-nc/4.0/>), which permits non-commercial re-use, distribution, and reproduction in any medium, provided the original work is properly cited. For commercial re-use, please contact journals.permissions@oup.com

What's new?

- Present study is among the first investigating the efficacy and safety of single-stage hybrid atrial fibrillation (AF) ablation in patients with exclusively persistent forms of AF who did not receive a prior catheter ablation.
- The majority of recurrences were atrial flutters/tachycardias that could be ablated successfully during repeat percutaneous ablation.
- Electrophysiological study during repeat interventions showed that the majority of patients had reconduction of the posterior box.

Introduction

Atrial fibrillation (AF) is the most commonly sustained arrhythmia worldwide.¹ With an ageing population, the incidence and prevalence of AF are increasing.¹ Furthermore, AF represents a major cause of cardiovascular morbidity and mortality.¹ Catheter ablation has become an important treatment modality for patients with symptomatic AF.^{1,2} The hallmark of catheter ablation is isolation of the pulmonary veins (PVs).² Pulmonary vein isolation (PVI) has been shown to be especially effective in patients with paroxysmal AF, with success rates of over 70%.²

In patients with persistent and long-standing persistent AF, catheter ablation is less successful as persistent AF patients have a more advanced substrate for AF.² Electroanatomical mapping data in persistent AF patients usually demonstrate atrial areas of low voltages, indicative of atrial fibrosis.³ Even with effective PVI, the long-term success of catheter ablation appears to be lower in this category of patients than in patients with paroxysmal AF.¹ Surgical thoracoscopic AF ablation has emerged as a potential effective treatment modality for patients with persistent AF.^{1,2} Currently, the procedure is performed thoracoscopically and consists of PVI, roof and inferior lines for the creation of a posterior box, left atrial appendage closure and linear lesions.² More recently, single-stage hybrid AF ablation strategies have been developed to leverage selectively the advantages of catheter and surgical ablation. The surgical component allows direct visualization of the PVs and the myocardium, and surgical ablation tools, especially the PVI clamps, create long-lasting transmural lesions. The endocardial strategy allows detailed mapping of atrial tachycardias (ATs) and the atrial substrate. In addition, the surgically placed lesion set can be mapped and corrected where necessary.⁴

Previous publications support the efficacy of surgical and hybrid AF ablation but the patients described in these studies consisted of mixed types of AF (paroxysmal and persistent AF) and many patients had previous failed catheter ablation(s).⁴⁻⁶ The aim of our present study is to evaluate the efficacy and safety of *first-line* single-stage hybrid AF ablation of persistent and long-standing persistent AF, over a follow-up period of 2 years. Procedural data, type of recurrence as well as electrophysiological findings during redo procedures are described.

Methods

Patient population

From a prospective registry of 104 patients who underwent hybrid ablation between January 2015 and December 2018 at the University Medical Center Groningen, The Netherlands, 49 patients who underwent single-stage hybrid ablation as first-line ablation treatment of persistent and long-standing persistent AF were included in the present analysis. Patients who were selected for hybrid AF ablation had either long-standing persistent AF or persistent AF with (markedly) dilated atria or patients with previous failed catheter ablations. For this study, patients were excluded if they had previously undergone one or more (failed) catheter ablation(s) prior to hybrid AF ablation. The first 50 patients of this series were described previously but included also patients with paroxysmal AF and previous failed ablations.⁷

AF was defined as persistent if episodes lasted more than 7 consecutive days but still had periods in sinus rhythm and as long-standing persistent if AF episodes lasted more than 365 consecutive days without the occurrence of sinus rhythm.² The institutional ethical review board approved the study protocol, and all patients provided written informed consent.

Study procedures

All patients were assessed at baseline for clinical history, physical examination, current medication use, an electrocardiogram (ECG), blood samples, 24-h Holter, and an echocardiogram. Baseline characteristics were registered, and a baseline assessment of AF was conducted for all patients.

All patients were scheduled to receive periodic ECG controls at the outpatient clinic at 1, 3, 6, and 12 months after procedure. A 72-h Holter monitoring was performed at 3, 6, 12, and 24 months to check for evidence of AF recurrence. The following information was collected during all visits: information about recurrences of AF, atrial flutter (AFL), or AT documented by the general practitioner, during emergency room visits or during hospital admissions, as well as adverse events associated with the procedure. Anti-arrhythmic drugs (AADs) were continued during the first 3 months and then discontinued in symptom-free patients. All patients were on vitamin K antagonist treatment for at least 4 weeks before the procedure. This line of treatment was not interrupted periprocedurally (target international normalized ratio 2–2.5) and continued thereafter for at least 3 months. All patients resumed use of oral anticoagulants after the procedure based to their CHA₂DS₂-VASc score, regardless of undergoing left atrial appendage exclusion. A repeat radiofrequency catheter ablation was performed if patients experienced a symptomatic recurrence within 2-year follow-up.

Single-stage hybrid atrial fibrillation ablation procedure

The procedure was performed under general anaesthesia in the hybrid operation room. The surgical epicardial procedures were performed by two surgeons (M.A.M. and T.K.), while the endocardial procedures were performed by the same electrophysiologist (Y.B.). The surgeons performing the procedures had experience for more than a decade with thoracoscopic AF surgery. In addition, the cases reported in this study are part of a larger series of hybrid AF ablation procedures. For the present analysis, we included patients who did not have a previous AF ablation procedure. A double-lumen endotracheal tube was placed for selective lung ventilation. A detailed description of the epicardial and endocardial procedures has been reported in an earlier publication.⁷ In brief, through three

thoracoscopic ports, the pericardium was accessed and opened anterior to the phrenic nerve. The right PVs were ablated, followed by ablation of the superior caval vein, utilizing the same bipolar clamp (Isolator Synergy Clamps; AtriCure Inc., Mason, OH, USA). Roof and inferior lines for the creation of a posterior box were created using a linear ablation device (Coolrail; Atricure Inc.). Next, ablation was performed via a left thoracoscopic approach using similar access ports. The left PVs were isolated with the clamp and if necessary, the previous created linear lines for the creation of a posterior box were connected with the left PV line. In patients with CHA₂DS₂-VASc scores of two or higher, surgical exclusion of the left atrial appendage was performed utilizing a minimally invasive occlusion device (AtriClip; AtriCure Inc., Mason, OH, USA).

Once the surgical procedure was completed, the left atrium (LA) was accessed via the femoral vein with a single trans-septal puncture, after which 100 E/kg bolus dose of unfractionated heparin was administered (target activating clotting time >300 s). A circular multipolar catheter was used to create a high density three-dimensional electroanatomical map of the LA using the EnSite Precision mapping system. Additional endocardial ablation was done with the TactiCath SE ablation catheter (Abbott, Chicago, IL, USA) if the PVs or posterior box isolation were incomplete. ATs/AFLs were mapped and ablated. In all patients, a cavotricuspid isthmus (CTI) line was created and tested for bidirectional block. Evidence for isolation of the superior caval vein was not routinely investigated.

Repeat percutaneous radiofrequency ablation

For recurrences of symptomatic AF/AT/AFL, repeat percutaneous procedures were performed. Mapping and ablation were performed with the EnSite Precision mapping system and multipolar mapping catheters Advisor HD Grid (Abbott) or with the Rhythmia HDx mapping system (Boston Scientific, Marlborough, MA, USA) using the Intellamap Orion mapping catheter and the IntellaNav ablation catheter (Boston Scientific). In all cases, a double trans-septal puncture was performed. Anticoagulation strategy and heparin administration were performed as described above. If the patient presented in AT/AFL, left atrial mapping was performed. In patients with sinus rhythm, atrial programmed stimulation or burst pacing was performed to induce the clinical tachycardia. If the cycle length and P-wave morphology of the induced atrial arrhythmia was similar to those of the previously documented arrhythmia, the clinical tachycardia was confirmed. In patients with AF during the procedure, electrical cardioversion was performed before left atrial mapping. Besides mapping ATs, all previously made ablation lines were assessed and lines were completed when gaps were demonstrated. A high-density LA map was made during distal coronary sinus pacing. Absence of electrograms and exit block during pacing within the box was taken as evidence of box isolation. Conduction gaps in the posterior box were identified by activation patterns and electrogram analysis. If gaps were demonstrated, ablation was performed. Bidirectional block of CTI and mitral isthmus (MI) lines was confirmed by mapping during CS pacing (CTI line) and LAA pacing (MI line) and by differential pacing manoeuvres.

Outcomes

The primary outcome was maintenance of sinus rhythm at 2-year follow-up. This was measured for both single procedure (hybrid) and multiple procedure (hybrid + repeat) success rates. Failure was defined as a recurrence of AF/AFL/AT lasting more than 30 s documented by ECG, Holter monitoring or an event recorder during the 24-month follow-up, excluding recurrences in the first 90-day post-procedure (blinking period). Only documented arrhythmias were registered as recurrences (i.e. failures). In case patients experienced symptoms, an active evaluation of the rhythm was performed with event monitors. Secondary outcomes

Table 1 Patient clinical characteristics of study population at baseline (n = 49)

Characteristics	Value
Sex (M)—n (%)	44 (89.8)
Age (years)—mean ± SD	57.0 ± 8.5
AF duration (days)—median (IQR)	1080 (594–2031)
BMI—mean ± SD	29.0 ± 3.5
Days follow-up—median (IQR)	753 (472–976)
Type of AF—n (%)	
Persistent AF	32 (65.3)
Long-standing persistent AF	17 (34.7)
Comorbidities—n (%)	
Heart failure	4 (8.2)
Coronary artery disease	5 (10.2)
Cerebrovascular accident	2 (4.1)
Implanted device	1 (2.0)
Chronic obstructive pulmonary disease	1 (2.0)
Vascular disease	2 (8.2)
Hypertension	21 (42.9)
Diabetes mellitus	6 (12.2)
Anti-arrhythmic drugs—n (%)	31 (63.2)
Clinical factors—mean ± SD	
LVEF	52.4 ± 7.5
LAVI	43.7 ± 10.9
eGFR	76.5 ± 16.7
CHA ₂ DS ₂ -VASc—median (IQR)	1.0 (0.5–2.0)

BMI, body mass index; eGFR, estimated glomerular filtration rate; LAVI, left atrium volume index; LVEF, left ventricular ejection fraction.

included the rate of procedure-related complications and freedom from AADs at 2-year follow-up. Procedure-related complications were classified into major and minor complications, in accordance with the consensus statement on surgical and catheter ablation and the classifications utilized by previous similar studies.^{4–7} Lastly, an electrophysiological qualitative analysis of repeat ablations was conducted with the aim of identifying the source of the recurrent arrhythmia and its relation to the lesion set created during the index hybrid ablation.

Statistical analysis

Patient characteristics, rate of complications, and procedure-related data are presented as mean and standard deviation or median and interquartile range for continuous and categorical variables, respectively. Kaplan–Meier survival analysis was used to show outcomes of success rate analyses. The analyses were conducted using SPSS (IBM Corp. Released 2015. IBM SPSS Statistics for Windows, Version 23.0. Armonk, NY: IBM Corp.), and statistical significance was set at a *P*-value <0.05.

Results

Patient population and clinical characteristics

Table 1 shows the patient characteristics of the 49 patients with (long-standing) persistent AF who underwent hybrid ablation as first-line ablation treatment. The patients were relatively young men,

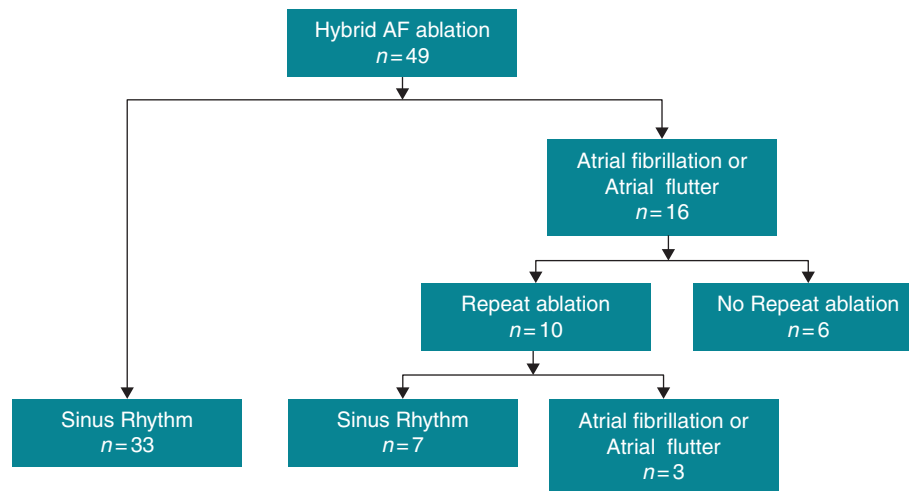


Figure 1 Flow chart showing the outcomes of first-line hybrid ablation during 2-year follow-up.

mean age of 57.0 ± 8.5 years. The distribution of persistent AF and long-standing persistent AF was 65% ($n = 32$) and 35% ($n = 17$), respectively. The median CHA₂DS₂-VASc score was 1.0 (0.5–2.0) and mean LA volume index was 43.7 ± 10.9 mL/m².

Index single-stage hybrid ablation procedure

In 47 of 49 patients, both epicardial and endocardial mapping/ablation were performed. In the two remaining patients, a bleeding complication occurred during the epicardial part of the procedure and we decided not to perform endocardial LA mapping and ablation. The epicardial lesion set consisted of ablation of the PVs (49/49 patients), epicardial creation of a posterior box (49/49), ablation of the superior caval vein (46/49), and clipping of the left atrial appendage (16/49). Ablation of the superior caval vein was not performed in two patients because a pacemaker/defibrillator leads were present and in one patient because of bleeding following manipulation/ablation of the right-sided veins. Total duration time of the surgical part of the procedure was 204 ± 77 min. Endocardial mapping of the LA demonstrated isolation of all PVs. The posterior box was isolated in 31/47 (68%) cases. The electrical connection was observed in 14/16 (88%) patients at the superior line, in 7/16 (43%) at the inferior line, and in 5/16 (31%) patients, gaps were observed in both the superior and inferior line. Following endocardial ablation, entrance and exit block of the posterior box was achieved in all patients. In 47/49 (96%) patients, CTI ablation was performed and bidirectional block was achieved in all. The total duration of the endocardial part of the procedure was 117 ± 34 min.

At the beginning of the procedure, 39/49 (80%) patients were in AF. Conversion to AT/AFL or sinus rhythm was observed after completion of surgical ablation in, respectively, 7/49 (14%) and 5/49 (10%) patients [total 12/49 (25%) patients]. AT/AFL was mapped, and ablation resulted in sinus rhythm in 6/7 patients. Various ATs or AFLs were observed. In three patients, multiple AFLs/ATs were observed. Sinus rhythm was achieved by CTI ablation or MI ablation in,

respectively, three and two patients. In the remainder of the patients, sinus rhythm was obtained by electrical cardioversion. Mean hospital stay after single-stage hybrid ablation was 5.5 ± 2.1 days.

Success rate of single-stage hybrid atrial fibrillation ablation: single procedure and multiple procedure success

Patients were followed for a median of 753 (472–976) days after hybrid ablation. *Figure 1* shows the outcomes of ablation treatment among our study population. Following single-stage hybrid AF ablation procedure at 2-year follow-up, a total of 33 (67%) patients had no evidence of AF/AFL recurrence. Of the 16 patients who did experience a recurrence during follow-up, 10 (20%) received a repeat ablation within the follow-up period. In the remaining six patients, a redo procedure was not performed because of various reasons. Four of six patients considered their AF burden acceptable, one had only a single AF episode followed by long-term sinus rhythm and in one patient AF was accepted and further ablation was no longer pursued.

Of the 10 patients who underwent redo ablation, 3 experienced another recurrence of AF/AFL within the 2-year follow-up while the remaining 7 maintained sinus rhythm. After multiple procedures, a total of nine patients were classified as recurrent cases at 2-year follow-up, resulting in a multiple procedure success rate of 82%. *Figure 2* displays the Kaplan–Meier curves showing the success rates for a single and multiple procedure treatment strategy during the 2-year follow-up. Of the 49 patients, 47 (96%) were AAD-free at 2 years. *Figure 2* also reports the frequency and type of arrhythmia of the 16 patients who experienced a recurrence after the index procedure. Of these patients, 3 (19%) had a recurrence of AF, whereas 13 (81%) had a recurrence of AFL/AT.

Safety

Six (12%) patients experienced a complication following hybrid ablation. *Table 2* shows the frequency and type of procedural complications. In two patients, a bleeding occurred during the epicardial part

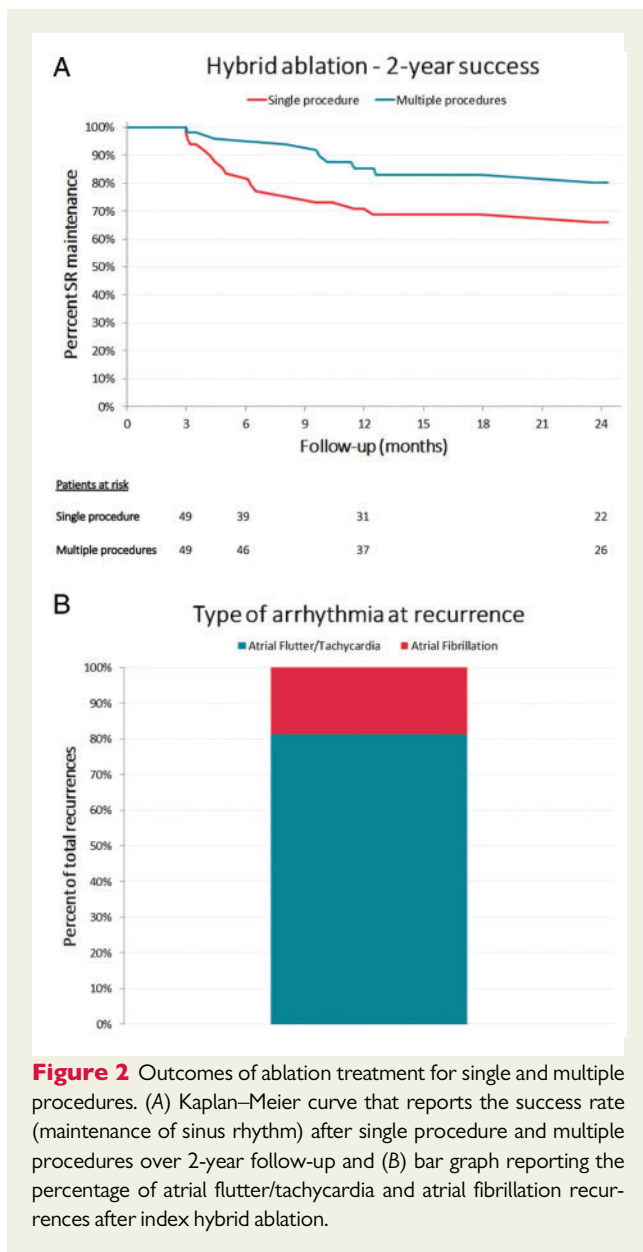


Figure 2 Outcomes of ablation treatment for single and multiple procedures. (A) Kaplan–Meier curve that reports the success rate (maintenance of sinus rhythm) after single procedure and multiple procedures over 2-year follow-up and (B) bar graph reporting the percentage of atrial flutter/tachycardia and atrial fibrillation recurrences after index hybrid ablation.

of the procedure in which one resulted in conversion to sternotomy (2%) and in the other was managed thoracoscopically. One patient required pacemaker implantation for sick sinus node following termination of the arrhythmia (2%). Four (8%) patients experienced a minor complication: two had evidence of pneumonia and two had evidence of a temporary phrenic nerve paralysis after the procedure. Phrenic nerve paralysis likely occurred during epicardial procedure. No difference in incidence of procedure-related complications was observed between the first and second half of patients, respectively, 4 and 2.

Electrophysiological findings and outcome of repeat percutaneous atrial fibrillation ablation

In 10/49 patients (20%), a redo procedure was performed for recurrence of AF in 1 patient (10%) and AT/AFL in 9 (90%) patients. Redo

Table 2 Rate of procedural complications

Total complications	12.2% (n = 6)
Total major complications	4.1% (n = 2)
Bleeding requiring thoracotomy or transfusion	2.0% (n = 1)
Permanent phrenic nerve paralysis	0%
Pacemaker device implantation	2.0% (n = 1)
Stroke	0%
Atrio-oesophageal fistula requiring surgery	0%
Death	0%
Total minor complications	8.2% (n = 4)
Haemoptysis	0%
Pneumonia	4.1% (n = 2)
Transient ischaemic attack	0%
Temporary phrenic nerve paralysis	4.1% (n = 2)

ablation was performed 249 ± 121 days after index ablation. Figure 3A shows an overview of the main electrophysiological findings at repeat ablation. In all 10 patients, isolation of the PVs was demonstrated. Overall, in 7/10 patients, there was reconduction of the posterior box with gaps in the superior line in 3/10 patients, in the inferior line in 1/10 patient, and in both superior and inferior lines in 3/10 patients. After repeat ablation, posterior wall isolation was achieved in all patients. CTI demonstrated bidirectional block in 9/10 patients (see Figure 3A).

Mapping of the recurrent arrhythmias was performed. Five patients presented with AT/AFL, in three AFL was induced, one patient had AF and one was non-inducible. All ATs/AFLs could be mapped (Table 3). The mechanisms responsible for these recurrent arrhythmias are shown in Figure 3B. Incomplete roof and/or inferior box lines were responsible for the recurrent AT/AFL in three patients. Completion of the box terminated the arrhythmia in all three patients. In two patients, a mitral annular flutter was mapped and ablated successfully, and conduction block of the line was achieved. The remainder of the ATs was believed to be microentry ATs. Figure 4 shows mapping data of a patient with a mitral annular flutter. A large posterior box was demonstrated. In the anterior LA, a narrow isthmus demonstrating slow conduction was identified and ablation terminated the arrhythmia.

Discussion

Main findings

This study showed in patients with persistent AF and long-standing persistent AF that the single and multiple procedure success of first-line single-stage hybrid ablation was 67% and 82%, respectively, at 2-year follow-up; 96% of patients were not on AADs at 2-year follow-up. The majority of recurrences were ATs/AFLs which were ablated successfully during redo ablation; 4% of patients experienced a major complication following hybrid ablation.

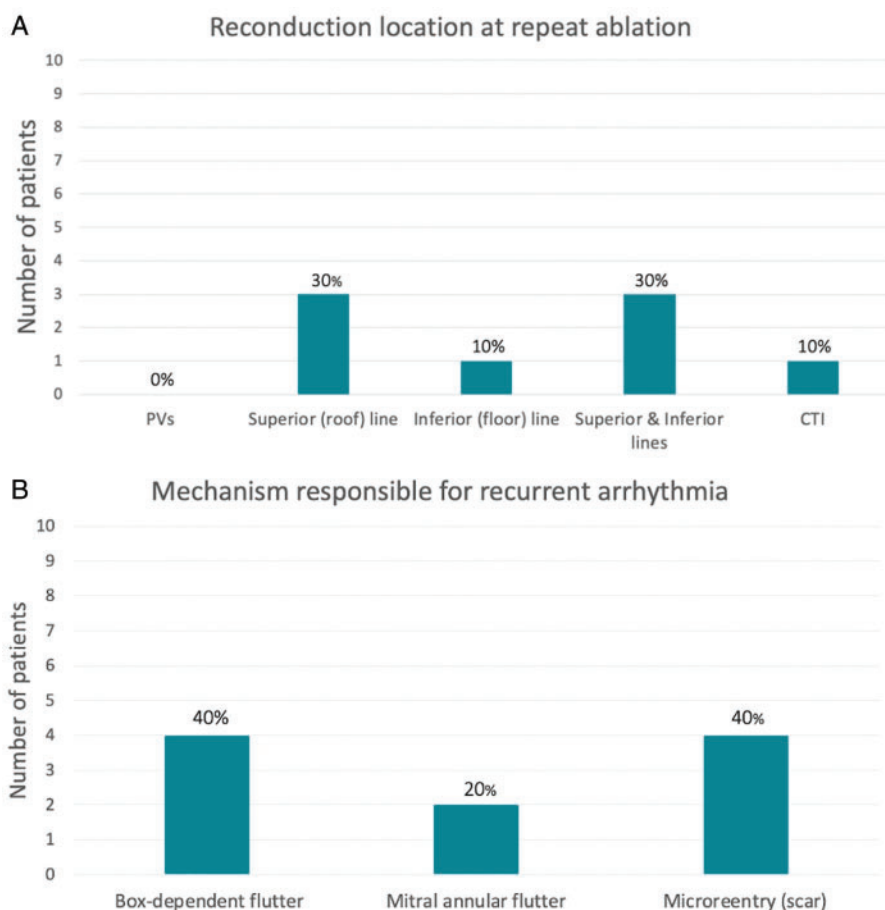


Figure 3 Electrophysiological findings at repeat ($n = 10$) ablation. (A) Reports the number and percentage of patients in which specific mechanisms/reconnection gaps responsible for the recurrent arrhythmia were identified following electrophysiological mapping during repeat ablation and (B) reports an overview of the number and percentage of patients in which gaps in ablation lines made during hybrid ablation were identified following electrophysiological mapping during repeat ablation.

Table 3 Procedural electrophysiological findings at repeat ablation

Patient	PVs isolated	Posterior box isolated	Mechanism atrial tachycardia	Cycle length (ms)
1	Yes	No	AT from junction inferior line/RIPV	440
2	Yes	No	Termination during box mapping. Likely roof dependent flutter	200
3	Yes	Yes	AT lateral mitral annulus	160
4	Yes	No	AT anterior border LAA	240
5	Yes	No	Mitral annular flutter	245
6	Yes	Yes	Mitral annular flutter	280
7	Yes	No	Roof-dependent flutter	300
8	Yes	No	Non-inducible	200
9	Yes	Yes	AF	
10	Yes	No	AT CS ostium	240

AT, atrial tachycardia; CS, superior vena cava; LAA, left atrial appendage; RIPV, right inferior pulmonary vein.

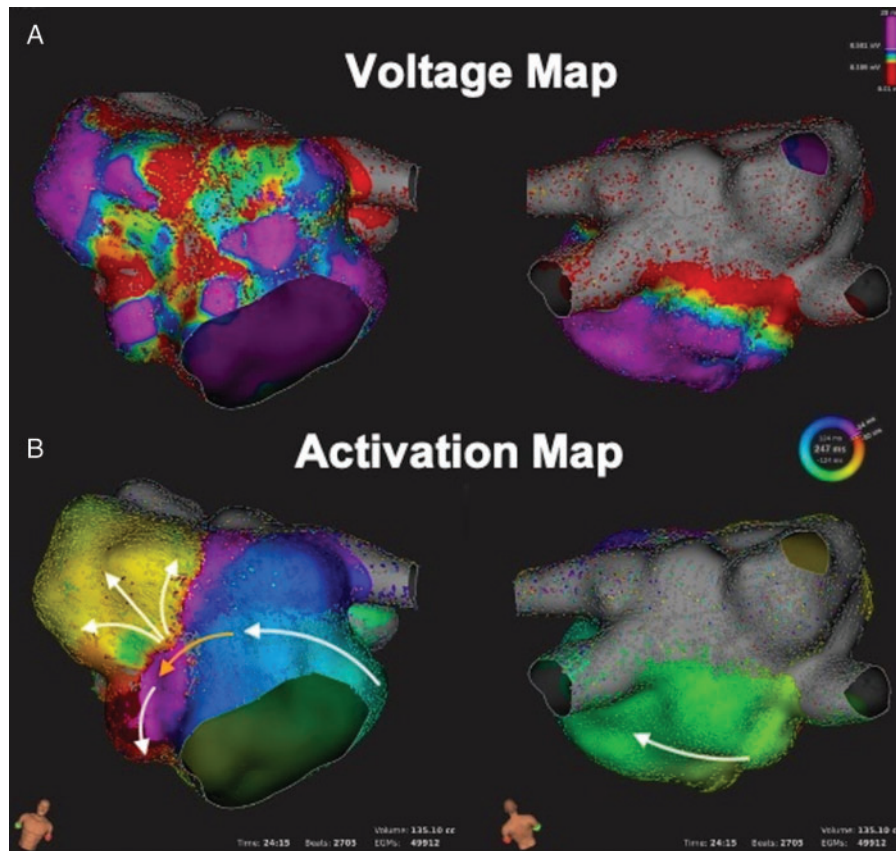


Figure 4 Three-dimensional electrophysiological voltage maps of a mitral annular dependent flutter. (A) Three-dimensional voltage map of the left atrium at redo procedure. Grey areas indicate the absence of electrical activity demonstrating block in the pulmonary veins and posterior box. (B) Three-dimensional activation map demonstrating mitral annular flutter. An area of slowly conducting tissue was detected, represented by the orange arrow. An ablation line from the right superior pulmonary vein (RSPV) to the anterior mitral annulus terminated the tachycardia.

Previous studies on hybrid atrial fibrillation ablation

Hybrid AF ablation can be performed either as a single-stage or as a staged procedure, where the endocardial ablation is scheduled at a later stage. In addition, the convergent surgical ablation technique targets mainly the posterior box via a subxiphoid approach,^{2,8} whereas the bilateral video-assisted thoracoscopic surgery (VATS) allows ablation of the PVs, the posterior box and clipping of the left atrial appendage. As a result, considerable variability exists between hybrid ablation studies. We compare our findings to studies on single-stage hybrid AF ablation that used the bilateral VATS approach. The first report on hybrid ablation by Pison *et al.*⁴ showed in a population of 26 patients a successful maintenance of sinus rhythm of 83%. La Meir *et al.*⁶ reported a 1-year success rate of 100% in the 35 patients treated with hybrid ablation. The higher success rate of these studies compared to ours can be explained by inclusion of a higher number of patients with paroxysmal AF, respectively, 37% and 46%.^{4,6} de Asmundis *et al.*⁵ showed in a population of 64 patients (33% persistent AF; 67% long-standing persistent AF), with a mean follow-up of 23.1 ± 14.1 months, a success rate off AADs of 67.2%. These findings are comparable to ours, demonstrating the efficacy of hybrid AF

ablation in patients with persistent AF. As a history of previous ablation has been shown to influence outcome of later ablation procedures,⁹ it is important to realize that all of the above-mentioned studies included also patients with previous failed catheter ablation, whereas our report shows outcome of hybrid AF ablation as a first-line treatment for patients with persistent forms of AF.

Ablation lesion set for persistent atrial fibrillation

The lesion set used in this study during hybrid ablation is an adaptation of that performed during a Cox Maze IV procedure.² We routinely used a standard lesion set consisting of PVI, superior caval vein ablation, roof and inferior lines for the creation of a posterior box and clipping of the left atrial appendage for patients with a CHA₂DS₂-VASc score of two or higher. Previous studies on hybrid ablation utilized similar lesion sets.⁴⁻⁶ It is unknown whether all elements of the ablation set are necessary to obtain a good outcome. We routinely performed a CTI line. Only a few patients experienced a CTI-dependent flutter during the index procedure. On the other hand, although the majority of recurrences in our study were AT/AFL, none of them was CTI dependent. Conversely, we did not perform an MI line

routinely and only 2/49 patients demonstrated mitral annular flutter as recurrence. Routinely performing MI ablation could have led to more mitral annular flutter since it is challenging to create durable MI block and incomplete lines may set the stage for future AFLs.²

There is debate on the contribution of the posterior wall in the maintenance of AF. Studies have identified the posterior wall of the LA as a relevant location of AF drivers,¹⁰ supporting its isolation through 'box' isolation. Studies investigating this ablation strategy performed during catheter ablation have shown mixed results.^{11,12} Interestingly, the recent Converge trial compared endocardial PVI vs. endocardial PVI + posterior wall ablation via a subxiphoid approach and demonstrated improved efficacy in the posterior wall ablated group.⁸ This supports the contribution of the posterior wall for AF maintenance and suggest that this should be part of the AF ablation lesion set in patients with persistent AF. Nonetheless, achieving durable box isolation even through a combined epi- and endo-cardial ablation remains a challenge, as shown in our study. Novel energy sources that are under development may lead to durable transmural ablation lines and improved outcomes.¹³ In addition, alternate approaches that use a catheter-based homogenization ablation of the posterior wall have also demonstrated promising results.¹⁴

Interestingly, only 3 of 49 patients experienced a recurrence of AF in our study. The majority of recurrences were AT or AFL. This is different from catheter-based PVI only approach where the majority of recurrences will be AF.¹⁵ We speculate that the PVI isolation and large posterior box performed epicardially during hybrid ablation reduced the atrial surface area participating to the fibrillation process and this increases the chance of AF conversion to sinus rhythm or AFL. The majority of arrhythmias observed during redo procedures were micro- or macro-re-entrant circuits. These arrhythmias could be mapped and ablated successfully. Our findings corroborate those of a previous study which showed that, in patients undergoing a repeat ablation, a recurrence of AT is associated with a significantly better outcome compared with a recurrence of AF.¹⁵ In agreement with these findings is the observation that the one patient who required repeat ablation for AF recurrence had still AF at 2-year follow-up even after redo ablation.

We decided to perform LAA occlusion in only a subgroup of patients with CHA₂DS₂-VASc of 2 or higher with the intention to prevent future thrombo-embolic events. We acknowledge that strong evidence for this is lacking and result of adequately powered randomized trials is eagerly awaited.¹⁶ Clipping of the LAA may also eliminate LAA foci and this may contribute to prevention of AF recurrence. Di Biase *et al.*¹⁷ showed that empirical isolation of the LAA improved freedom from AF/AT in patients with long-standing persistent AF. However, Romanov *et al.*¹⁸ observed no reduction in the rate of recurrent AF in patients randomized to LAA excision undergoing VATS ablation with PVI and box lesion. Thus, although LAA clipping is safe and feasible, the evidence for stroke prevention and anti-arrhythmic effect is debated and there is a need for well-powered trials to define the role of LAA occlusion/exclusion.

During surgical epicardial ablation, ganglionated plexi (GP) located around the PVs were also likely ablated. Studies evaluating the effect of ablation of the GP and the outcome of AF ablation have shown conflicting results. In a randomized trial in patients with paroxysmal AF, GP ablation reduced AF recurrences if performed on top of PVI.¹⁹ However, the results of the AFACT (Atrial Fibrillation

Ablation and Autonomic Modulation via Thoracoscopic Surgery) study did not provide evidence for anti-arrhythmic effects of selective GP ablation and actually more adverse events were observed.²⁰ Especially in patients with persistent AF—with advanced structural remodelling—the contribution of the autonomic nervous system to the pathogenesis of AF may be reduced.

Complications

The rate of procedural complications registered in our study was in line with previous studies.^{4–6} In general, a hybrid ablation approach has a higher complication rate as compared to catheter ablation.²¹ The complication rate is likely due to the higher invasiveness of single-stage hybrid ablation. In our study, in one patient a pacemaker was implanted for sick sinus syndrome that became apparent following conversion of AF to sinus rhythm during hybrid ablation (and with hindsight also had been reported after electrical cardioversions). Although an increased risk for pacemaker has been described following surgical AF ablation in our patient, this was probably not a direct result of ablation of the sinus node.

We chose to perform hybrid AF ablation with continuous anticoagulation with vitamin K antagonist since previous studies showed that discontinuation of anticoagulation in combination with heparin bridging is associated with increased risk of bleeding and stroke after catheter ablation.²² It is unknown what anticoagulation strategy is best for hybrid or surgical AF ablation. In our series, we observed two bleeding complications. One could be managed by suturing over the bleeding site and the other required sternotomy. No strokes or post-procedural bleeding complications were observed.

Strengths and limitations

To our knowledge, this is the first study investigating the safety and efficacy of hybrid ablation for the treatment of (long-standing) persistent AF in patients who did not receive previous catheter ablation(s). Previous studies included patients who had mixed types of AF at baseline (paroxysmal and persistent AF) and many patients who had previous failed catheter ablation(s). By investigating exclusively patients who received hybrid ablation as first-line ablation treatment of (long-standing) persistent AF, we aimed at isolating and focusing on outcomes specifically related to this ablation strategy. However, this consecutively resulted in a relatively low number of patients. An additional limitation of present study is the lack of continuous monitoring of the heart rhythm during the period of follow-up, as we might have failed at documenting asymptomatic recurrences of atrial arrhythmias. However, we noticed that most recurrences were cases of stable flutters, making the chance of documentation high. We opted to use a standard epicardial ablation set for all patients during the entire duration of the study. It is unknown whether this resulted in overtreatment of some patient. The small size of our study group does not allow randomization of lesion sets. It would be of interest to tailor the lesion set to the underlying substrate. In addition, RCTs are coming,⁸ which we hope will be able to corroborate our findings with more conclusive data.

Finally, the cases reported in this study are part of a larger series of hybrid AF ablation procedures. As we only included patients who did not have an AF ablation prior to hybrid ablation, part of our learning curve is not represented in the population we reported here. In addition, the surgeons had experience for more than a decade with

thoroscopic AF ablation. Therefore, this makes it difficult to draw any conclusions from the present study on the learning curve of hybrid AF ablation. We did, however, compare the incidence of procedural complications for the first and second half of patients and observed no difference.

Conclusions

Our study investigated the efficacy and safety of single-stage hybrid AF ablation in patients with (long-standing) persistent AF who did not receive prior catheter ablation. Single and multiple procedure success rates were 67% and 82%, respectively, at 2-year follow-up and complication rate was acceptable. The results of our study show that hybrid AF ablation may represent an effective first-line ablation treatment for persistent forms of AF.

Funding

This work was supported by a research grant from AtriCure.

Conflicts of interest: M.A.M. received grants from Abbott, AtriCure, and Edwards and Consultancy from Livanova and Medtronic. Y.B. received research grants (to department) from AtriCure and Medtronic. The other authors have no conflicts of interest to declare.

Data availability

Data made available on request.

References

- Kirchhof P, Benussi S, Kotecha D, Ahlsson A, Atar D, Casadei B et al. 2016 ESC Guidelines for the management of atrial fibrillation developed in collaboration with EACTS. *Europace* 2016;**18**:1609–78.
- Calkins H, Hindricks G, Cappato R, Kim YH, Saad EB, Aguinaga L et al. 2017 HRS/EHRA/ECAS/APHSR/SOLAECE expert consensus statement on catheter and surgical ablation of atrial fibrillation. *Europace* 2018;**20**:e1–160.
- Verma A, Wazni OM, Marrouche NF, Martin DO, Kilicaslan F, Minor S et al. Pre-existent left atrial scarring in patients undergoing pulmonary vein antrum isolation: an independent predictor of procedural failure. *J Am Coll Cardiol* 2005;**45**:285–92.
- Pison L, La Meir M, van Opstal J, Blaauw Y, Maessen J, Crijns HJ. Hybrid thoracoscopic surgical and transvenous catheter ablation of atrial fibrillation. *J Am Coll Cardiol* 2012;**60**:54–61.
- de Asmundis C, Chierchia GB, Mugnai G, Van Loo I, Nijs J, Czupla J et al. Midterm clinical outcomes of concomitant thoracoscopic epicardial and trans-catheter endocardial ablation for persistent and long-standing persistent atrial fibrillation: a single-centre experience. *Europace* 2017;**19**:58–65.
- La Meir M, Gelsomino S, Lucà F, Pison L, Parise O, Colella A et al. Minimally invasive surgical treatment of lone atrial fibrillation: early results of hybrid versus standard minimally invasive approach employing radiofrequency sources. *Int J Cardiol* 2013;**167**:1469–75.
- Al-Jazairi MIH, Rienstra M, Klinkenberg TJ, Mariani MA, Van Gelder IC, Blaauw Y. Hybrid atrial fibrillation ablation in patients with persistent atrial fibrillation or failed catheter ablation. *Neth Heart J* 2019;**27**:142–51.
- DeLurgio DB, Ferguson E, Gill J, Blauth C, Oza S, Mostovych M et al. Convergence of epicardial and endocardial RF ablation for the treatment of symptomatic persistent AF (CONVERGE Trial): rationale and design. *Am Heart J* 2020;**224**:182–91.
- Winkle RA, Mead RH, Engel G, Patrawala RA. Long-term results of atrial fibrillation ablation: the importance of all initial ablation failures undergoing a repeat ablation. *Am Heart J* 2011;**162**:193–200.
- Haissaguerre M, Hocini M, Denis A, Shah AJ, Komatsu Y, Yamashita S et al. Driver domains in persistent atrial fibrillation. *Circulation* 2014;**130**:530–8.
- Kim JS, Shin SY, Na JO, Choi CU, Kim SH, Kim JW et al. Does isolation of the left atrial posterior wall improve clinical outcomes after radiofrequency catheter ablation for persistent atrial fibrillation?: A prospective randomized clinical trial. *Int J Cardiol* 2015;**181**:277–83.
- Lee JM, Shim J, Park J, Yu HT, Kim TH, Park JK et al. The electrical isolation of the left atrial posterior wall in catheter ablation of persistent atrial fibrillation. *JACC Clin Electrophysiol* 2019;**5**:1253–61.
- Reddy VY, Anic A, Koruth J, Petru J, Funasako M, Minami K et al. Pulsed field ablation in patients with persistent atrial fibrillation. *J Am Coll Cardiol* 2020;**76**:1068–80.
- Della Rocca DG, Mohanty S, Trivedi C, Di Biase L, Natale A. Percutaneous treatment of non-paroxysmal atrial fibrillation: a paradigm shift from pulmonary vein to non-pulmonary vein trigger ablation? *Arrhythm Electrophysiol Rev* 2018;**7**:256–60.
- Ammar S, Hessling G, Reents T, Fichtner S, Wu J, Zhu P et al. Arrhythmia type after persistent atrial fibrillation ablation predicts success of the repeat procedure. *Circ Arrhythm Electrophysiol* 2011;**4**:609–14.
- Whitlock R, Healey J, Vincent J, Brady K, Teoh K, Royse A et al. Rationale and design of the left atrial appendage occlusion study (LAAOS) III. *Ann Cardiothorac Surg* 2014;**3**:45–54.
- Di Biase L, Burkhardt JD, Mohanty P, Mohanty S, Sanchez JE, Trivedi C et al. Left atrial appendage isolation in patients with longstanding persistent AF undergoing catheter ablation: BELIEF trial. *J Am Coll Cardiol* 2016;**68**:1929–40.
- Romanov A, Pokushalov E, Elesin D, Bogachev-Prokophiev A, Ponomarev D, Losik D et al. Effect of left atrial appendage excision on procedure outcome in patients with persistent atrial fibrillation undergoing surgical ablation. *Heart Rhythm* 2016;**13**:1803–9.
- Katritsis DG, Pokushalov E, Romanov A, Giazitoglou E, Siontis GC, Po SS et al. Autonomic denervation added to pulmonary vein isolation for paroxysmal atrial fibrillation: a randomized clinical trial. *J Am Coll Cardiol* 2013;**62**:2318–25.
- Driessen AH, Berger WR, Krul SP, van den Berg NW, Neefs J, Piersma FR et al. Ganglion plexus ablation in advanced atrial fibrillation: the AFACT study. *J Am Coll Cardiol* 2016;**68**:1155–65.
- Van Der Heijden CAJ, Vroomen M, Luermans JG, Vos R, Crijns HJGM, Gelsomino S et al. Hybrid versus catheter ablation in patients with persistent and longstanding persistent atrial fibrillation: a systematic review and meta-analysis Hybrid versus catheter ablation in patients with persistent and longstanding persistent atrial fibrillation: a systematic review and meta-analysis. *Eur J Cardio-thorac Surg* 2019;**56**:433–43.
- Nairooz R, Sardar P, Payne J, Aronow WS, Paydak H. Meta-analysis of major bleeding with uninterrupted warfarin compared to interrupted warfarin and heparin bridging in ablation of atrial fibrillation. *Int J Cardiol* 2015;**187**:426–9.