

Interlocking Closed-Wedge High Tibial Osteotomy Modified With Oblique Osteotomy Lines and a Locking Plate Fixation

著者名	OKAZAKI Ken
journal or publication title	Arthroscopy techniques
volume	10
number	4
page range	e1061-e1066
year	2021
URL	http://hdl.handle.net/10470/00033086

doi: 10.1016/j.eats.2020.12.005

Interlocking Closed-Wedge High Tibial Osteotomy Modified With Oblique Osteotomy Lines and a Locking Plate Fixation



Ken Okazaki, M.D., Ph.D.

Abstract: Closed-wedge high tibial osteotomy (CWHTO) is more advantageous over open-wedge high tibial osteotomy in the following viewpoints: (1) compression force from the patellar tendon to the osteotomy site contribute to its stability, (2) patellar baja less likely occurs, and (3) hardware implant is placed under the thick muscle, which could prevent risk of irritation and infection. Although conventional CWHTO resects the wedge bone, including the anterior and posterior cortices, interlocking CWHTO preserves them while performing osteotomy for the anterior or posterior cortex with only the proximal or distal osteotomy line, respectively. When the wedge is being closed, the distal fragment is internally rotated overlying the anterior and posterior cortices on the proximal and distal cortices, respectively. As a result, good rotational stability and anterior advancement of the tibial tubercle are obtained. Interlocking CWHTO can be applied for patients with moderate patellofemoral osteoarthritis. Adopting an oblique osteotomy line enables secure multiple screw fixations for a long locking plate with a good fitting, allowing early postoperative weightbearing.

Closed-wedge high tibial osteotomy (CWHTO) is more advantageous over open-wedge high tibial osteotomy (OWHTO) in the following viewpoints: (1) the traction force from quadriceps transmits to a compression force to the osteotomy site contributing to its stability, (2) the patellar baja less likely occurs even with a large correction, (3) the hardware implant is placed under the thick muscle that could prevent from the irritation and infection risk.^{1,2} Conventional CWHTO is a monoplane osteotomy that resects a wedge-shaped bone including the triangle-shaped cortical bone from the anterior and posterior cortices.

Ogata³ reported the interlocking CWHTO (IL-CWHTO) in 1984. In IL-CWHTO, the wedge-shaped cancellous bone is resected; however, the anterior and posterior cortices are preserved. Osteotomy is made only on the proximal osteotomy line for the anterior cortex and only on the distal osteotomy line for the posterior cortex (Fig 1A). When closing the wedge, the distal fragment of the tibia is internally rotated overlying the anterior cortex on the proximal anterior cortex and the posterior cortex on the distal posterior cortex (Fig 1B). As a result, the osteotomy site is interlocked, achieving a rigid rotational stability with increased contact area. Furthermore, as the tibial tubercle on the anterior cortex of the distal fragment overlies the anterior cortex of the proximal fragment, ventralization, internal rotation, and proximal translation of the tibial tubercle occur, which are all beneficial for patellofemoral kinematics.

In the original IL-CWHTO, the proximal osteotomy line was designed parallel to the tibial joint line and the distal osteotomy line was shorter than the proximal one³ (Fig 1C). After the wedge was closed, a step-off was observed on the lateral cortex, and fixation was made with a step-shaped staple. Then the procedure was modified to make the osteotomy lines oblique and the wedge to be an isosceles triangle (Fig 1D). With this modification, the step-off on the lateral cortex disappeared, and a locking plate for osteosynthesis fit well

From the Department of Orthopaedic Surgery, Tokyo Women's Medical University, Tokyo, Japan.

The author reports the following potential conflicts of interest or sources of funding: K.O. reports lecture fees from Olympus Terumo Biomaterials, Tokyo, Japan. Full ICMJE author disclosure forms are available for this article online, as [supplementary material](#).

Received October 20, 2020; accepted December 6, 2020.

Address correspondence to Ken Okazaki, M.D., Ph.D., Department of Orthopaedic Surgery, Tokyo Women's Medical University, 8-1 Kawadacho, Shinjuku, 162-8666 Tokyo, Japan. E-mail: okazaki.ken@twmu.ac.jp

© 2020 by the Arthroscopy Association of North America. Published by Elsevier. This is an open access article under the CC BY-NC-ND license (<http://creativecommons.org/licenses/by-nc-nd/4.0/>).

2212-6287/201744

<https://doi.org/10.1016/j.eats.2020.12.005>

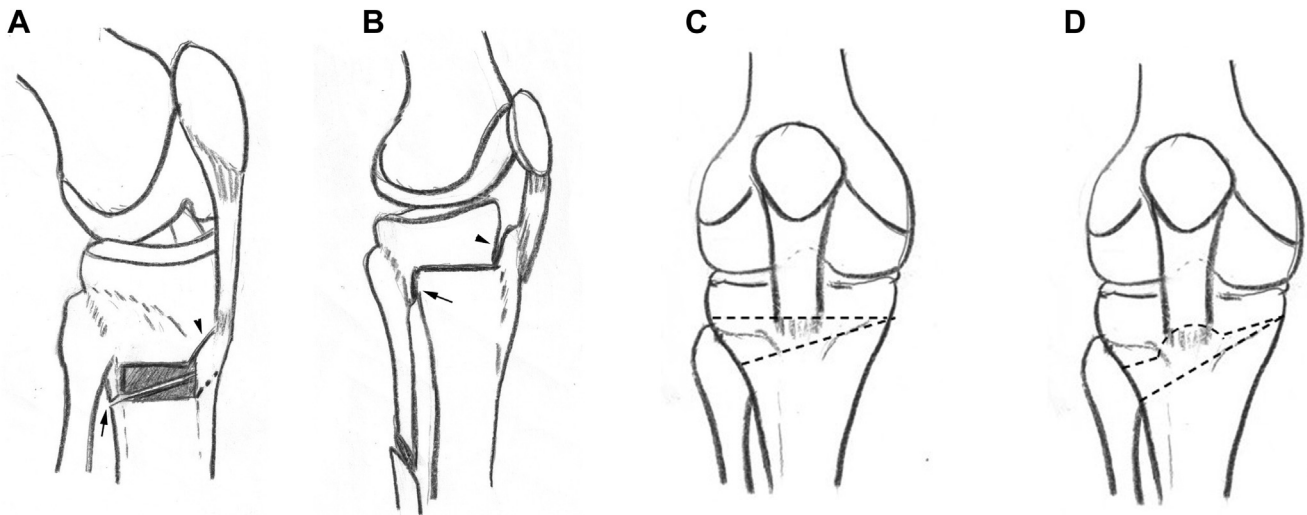


Fig 1. (A) Procedure of interlocking closed-wedge high tibial osteotomy (IL-CWHTO). Right knee. A rectangular-shaped cortical bone is removed from the lateral wall of the tibia, and a wedge-shaped cancellous bone is resected; however, the anterior and posterior cortices are preserved. Osteotomy is made only on the proximal osteotomy line for the anterior cortex and only on the distal osteotomy line for the posterior cortex. Arrowhead, anterior osteotomy line; Arrow: posterior osteotomy line. (B) When closing the wedge, the distal fragment of the tibia is internally rotated overlaying the anterior cortex on the proximal anterior cortex (arrowhead) and the posterior cortex on the distal posterior cortex (arrow). The osteotomy site is interlocked, achieving rigid rotational stability and anterior advancement of the tibial tubercle. (C) Broken lines: Osteotomy lines in the original IL-CWHTO. The proximal osteotomy line was parallel to the joint line, and the distal osteotomy line is shorter than the proximal one. After closing the wedge, a step-off will be observed on the lateral cortex. (D) Broken lines: Osteotomy lines in the modified IL-CWHTO. The procedure was modified to make the osteotomy lines oblique and the wedge to be an isosceles triangle. With this modification, the step-off on the lateral cortex disappeared, and a locking plate for osteosynthesis fit well on the lateral cortex.

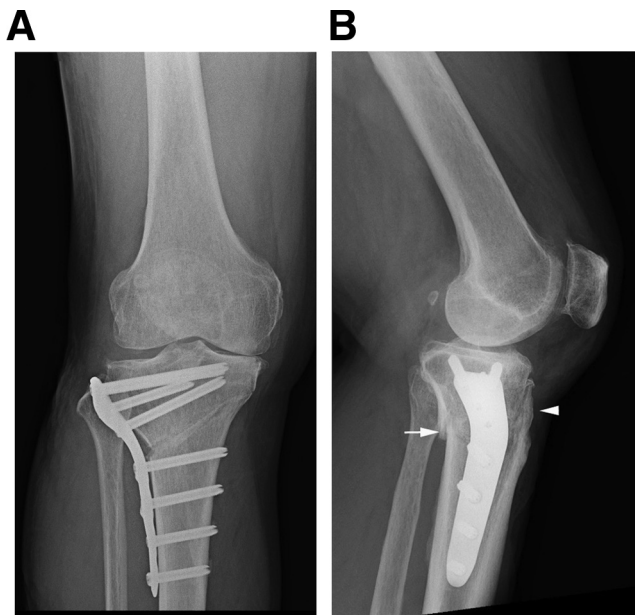


Fig 2. Postoperative radiographs. Right knee. (A) Oblique osteotomy lines for an isosceles triangle wedge bone eliminates the step-off on the lateral cortex after closing the wedge space. With enough proximal space, the osteosynthesis can be performed using a long locking plate with 4 proximal screws, and the plate fits well on the lateral cortex. (B) Tibial tubercle is advanced anteriorly and proximally (arrowhead). Posterior cortices are overlapped (arrow).

on the lateral cortex (Fig 2). Informed consent was obtained from the patient for the presentation in this article.

Preoperative Planning

A standard preoperative planning for CWHTO is conducted using a weightbearing long-leg radiograph and a targeted weightbearing line running on 65% of the tibial joint surface from its medial edge (Fujisawa point). The correction angle, length of the proximal osteotomy line from the hinge point (15 mm distal from the medial edge of the joint) to the 40 mm distal from the lateral joint surface, and distance between the two osteotomy lines on the lateral wall of the tibia are measured (Fig 3).

Surgical Techniques

Fibular Osteotomy (Video)

Fibular osteotomy is performed at the mid portion of the diaphysis, from the posterior margin of the peroneus longus muscle to the posterior edge of the fibula with a caution not to injure the superficial peroneal nerve. The fibula must be exposed in the periosteal fashion with caution not to injure the fibular artery and

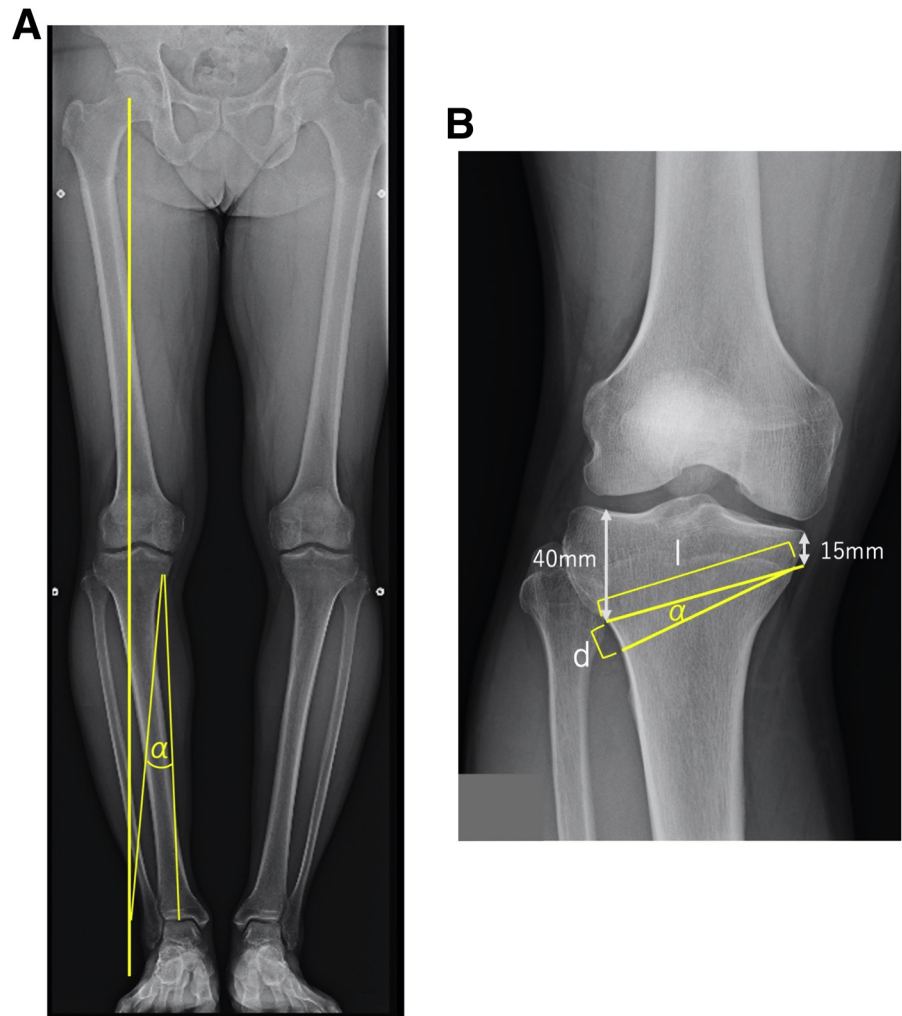


Fig 3. Preoperative planning right leg. (A) Weightbearing long-leg radiograph. Yellow line: targeted weightbearing line running on 65% of the tibial joint surface from its medial edge. The center of ankle joint will translate on the targeted weightbearing line after the correction with the hinge point on the medial proximal tibia. (B) Magnified view of the proximal tibia. Yellow lines, osteotomy line; α , correction angle; l , length of proximal osteotomy line; d , distance between the two osteotomy lines.

vein located just behind the fibula. Osteotomy is made either with bone fragment resection for 15 mm or an oblique transection (Fig 4). Fibular osteosynthesis is not necessary.

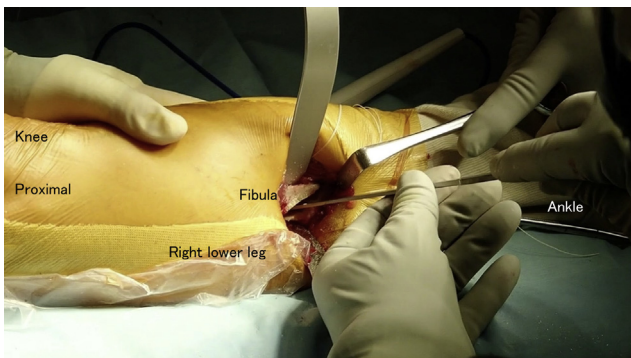


Fig 4. Fibular osteotomy is performed at the mid portion of the diaphysis with an oblique transection using a bone saw and a chisel. Care should be taken to avoid a neurovascular injury by placing retractors under the periosteal fashion. Right lower leg is shown.

Tibial osteotomy (Video)

A curved incision is made from above of the fibular head to 3 cm distal to the tibial tubercle. The fascia of the tibialis anterior is incised, and the muscle is detached from the lateral wall of the tibia. The posterior wall of the tibia is exposed under the periosteal fashion, and a radiolucent Hohman retractor is placed behind the targeted distal osteotomy line. The periosteum is incised at the lateral edge of the tibial tubercle to expose the proximal border of the patellar tendon insertion.

A 2-mm K-wire is inserted under a fluoroscopic guidance at 40 mm distal from the lateral joint surface on the lateral wall of the tibia to 15 mm distal from the medial edge of the joint. The insertion length (l) is measured and compared with preoperative planning (l) to adjust the distance on the lateral edge of the tibia (d'). Another 2-mm K-wire is inserted at the adjusted distance (d') away from the previous K-wire and placed across the previous wire at the medial edge of the tibia (Fig 5).

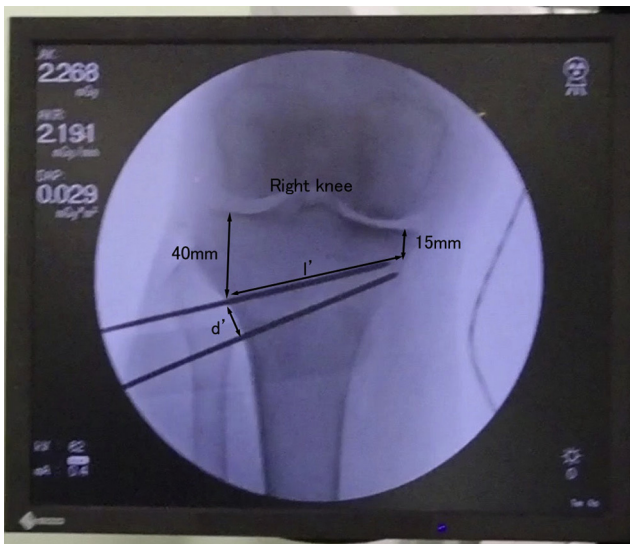


Fig 5. A 2-mm K-wire is inserted under a fluoroscopic guidance at 40 mm distal from the lateral joint surface on the lateral wall of the tibia to 15 mm distal from the medial edge of the joint. The distance (d') between the K-wires are calculated based on the preoperative planning and actual length (l') of the insertion, and another K-wire is inserted to across the previous wire at the medial edge of the tibia. Fluoroscopic view of right knee.

A rectangular-shaped cortex is removed from the lateral wall of the tibia. Depending on the bone size, a 15- to 20-mm chisel is used to cut the bone inside the two K-wires parallel to each other and perpendicular to the posterior wall of the tibia. Depending on the distance between K-wires, a 5- to 10-mm chisel is used to cut the bone at the anterior and posterior edges of the lateral wall. Then, a rectangular-shaped cortex is removed. Next, a wedge-shaped cancellous bone is removed between K-wires. Under fluoroscopic guidance, a 15- to 20-mm chisel is inserted into the cancellous bone inside with the K-wires until the tip reaches the medial cortex. After removing the wedge-

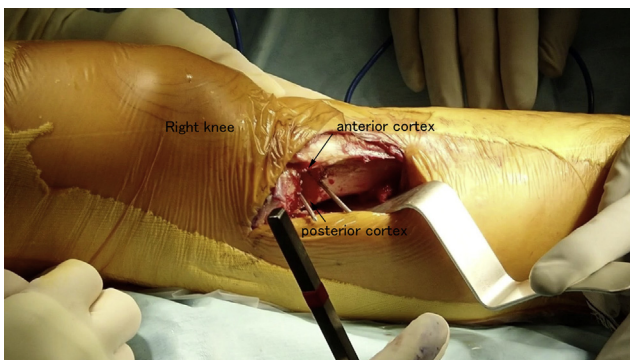


Fig 6. After removing a rectangular shaped cortex from the lateral wall of the tibia, a wedge-shaped cancellous bone is removed between K-wires. The anterior and posterior cortices are preserved. Right lower leg is shown.

shaped cancellous bone, the residual cancellous bone on the anterior and posterior cortices is completely scraped out using a bone curette (Fig 6).

For the posterior cortex, a radiolucent Hohman retractor is placed behind the distal osteotomy line, and a single-edged reciprocating saw is inserted into the wedged bone space along the distal osteotomy line until the tip reaches the medial cortex under fluoroscopic guidance. The distal osteotomy line on the posterior cortex is cut (Fig 7).

A small Hohman retractor is placed under the patellar tendon to expose the proximal edge of the patellar tendon insertion. The saw is inserted along with the proximal osteotomy line until the tip of the saw reaches the medial cortex. Osteotomy of the anterior cortex is performed in an oblique direction toward the proximal edge of the patellar tendon insertion (Fig 8).

When closing the wedge, the lower leg is internally rotated so that the anterior cortex of the wedge overlays the anterior cortex of the proximal fragment and the posterior cortex overlays the posterior cortex of the distal fragment (Fig 9).

Osteosynthesis is performed using an anatomically shaped locking plate for the proximal lateral tibia with 8 screws, such as the Tomofix Lateral High Tibial Plate (DePuy Synthes, West Chester, PA) or TriS Lateral HTO Plate (Olympus Terumo Biomaterials, Tokyo, Japan) (Fig 2).

Postoperative Rehabilitation

Active range of motion exercises are started the next day. Partial weightbearing is allowed from 1 week after operation, and the weight is gradually increased up to full weightbearing as tolerated.

Discussion

OWHTO has become the most popular surgical technique for proximal tibial osteotomy with the modern surgical technique consisting of a biplanar osteotomy and a rigid plate fixation.⁴ Nevertheless, OWHTO has several concerns such as postoperative patella baja, infection, increase of posterior tibial slope, and delayed union of the osteotomy site.⁵⁻⁹ CWHTO should be reconsidered, especially for patients with patellofemoral lesion, large correction, a risk of delayed union, or infection. Furthermore, IL-CWHTO with a long locking plate improves the fixation stability and patellofemoral kinematics.

Although the interlocking procedure improved the rotational stability, the original IL-CWHTO by Ogata³ used a step-shaped staple for fixation combined with a postoperative immobilization, and partial weightbearing was indicated for 6 weeks. The procedure was modified by adopting an oblique osteotomy line, enabling the use of 4 proximal screws for fixation eliminating a step-off of the lateral cortex at the osteotomy site that

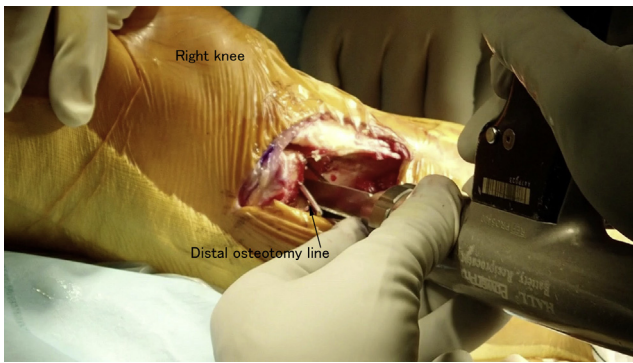


Fig 7. Osteotomy of the posterior cortex is performed only on the distal osteotomy line. A single-edged reciprocating saw is inserted into the wedged bone space along the distal osteotomy line until the tip reaches the medial cortex under fluoroscopic guidance. A retractor is placed under the posterior cortex to protect the popliteal neurovascular bundle. The distal osteotomy line is cut with the saw. Right lower leg is shown.

improves fitting of an anatomic long locking plate. As a result, postoperative rehabilitation can be accelerated, allowing early full weightbearing as tolerated.

Ventralization, internal rotation, and proximal translation of the tibial tubercle are other attractive advantages of IL-CWHTO. Ogata³ reported a good clinical result of 36 knees. Although all knees had slight to severe degenerative changes of the patellar articular surface before surgery, the postoperative subjective assessment at 1 to 3 years after operation showed good results in 78%, fair results in 22%, and no poor result in terms of pain relief and walking tolerance. Improvement of the patellofemoral alignment in the skyline Merchant view of the radiograph is also presented.

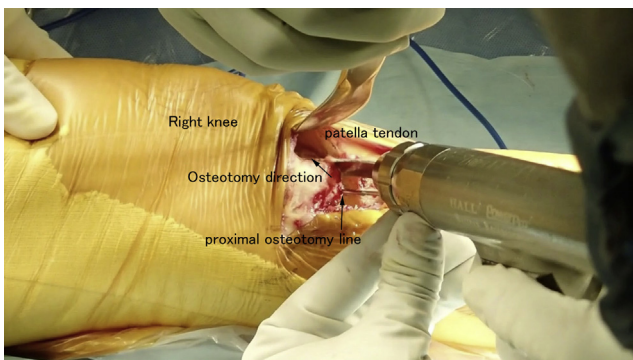


Fig 8. Osteotomy of the anterior cortex is performed only on the proximal osteotomy line. A small Hohman retractor is placed under the patellar tendon to expose the proximal edge of the patellar tendon insertion. The saw is inserted into the wedged bone space along with the proximal osteotomy line until the tip of the saw reaches the medial cortex under fluoroscopic guidance. Osteotomy of the anterior cortex is performed in an oblique direction toward the proximal edge of the patellar tendon insertion. Right knee is shown.

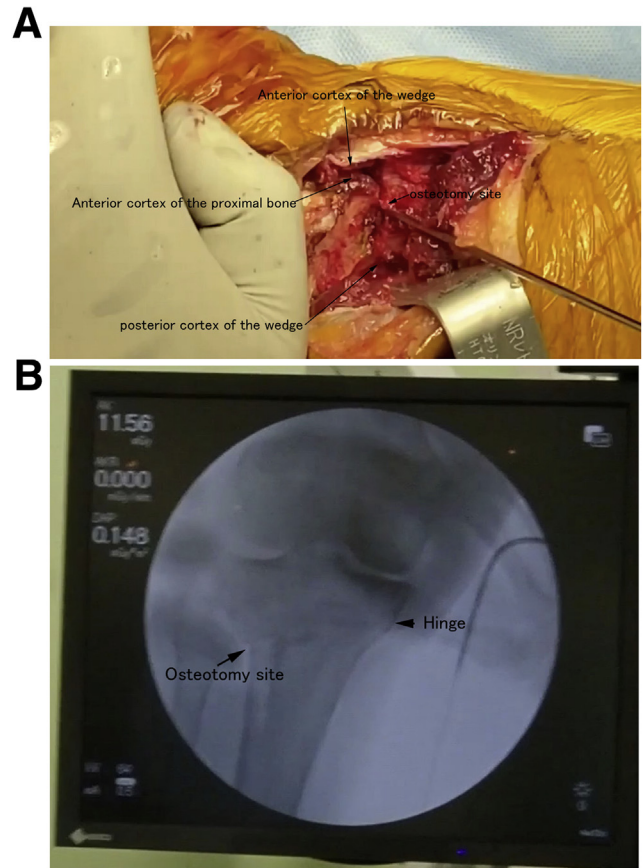


Fig 9. Closing the wedge. (A) When closing the wedge, the lower leg is internally rotated so that the anterior cortex of the wedge overlays the anterior cortex of the proximal fragment and the posterior cortex overlays the posterior cortex of the distal fragment. Right knee is shown. (B) Fluoroscopic image after closing the wedge. The medial hinge is preserved and the lateral wall is continuous without a step-off. Fluoroscopic image of right knee is shown.

Pitfalls and anticipated complications should be noted (Table 1). The medial hinge fracture sometimes occurs, especially in patients with hard bone quality. An incomplete osteotomy on the posterior cortex should be avoided by double checking if the osteotomy reaches the posteromedial corner of the hinge. If the residual cancellous bone is thick on the posterior and anterior cortices, the distal fragment should be internally rotated further when closing the wedge. Scraping the cancellous bone out is the Pearl. Nevertheless, if medial hinge fracture occurs, good stability with the interlocking position and a rigid fixation with the locking plate overcome the clinical problem. Neurovascular injury associated with fibular osteotomy is a common risk for closed wedge osteotomy. Therefore careful subperiosteal exposure of the fibula is critical to prevent injury.

In conclusion, IL-CWHTO provides firm rotational stability and improves patellofemoral kinematics. Adopting an oblique osteotomy line enables secure

Table 1. Benefits, risks, and limitations of interlocking closed wedge high tibial osteotomy

Benefits	
Improved rotational stability	
Increased contact area	
Ventralization, internal rotation and proximal translation of the tibial tubercle	
Locking plate fixation	
Less risk of infections	
Risks and Limitations	
Medial hinge fracture	
Fibula osteotomy is necessary	
Neurovascular injury including the peroneal nerve palsy	

multiple screw fixations for a long locking plate with a good fitting. This procedure is beneficial for medial knee osteoarthritis with moderate patellofemoral degeneration, relatively large correction, and potential risks for complications, such as infection and delayed bone union.

Acknowledgment

The oblique osteotomy in IL-CWHTO was originated by Dr. Hideya Kawamura, Kagoshima, Japan.

References

- Bonasia DE, Governale G, Spolaore S, Rossi R, Amendola A. High tibial osteotomy. *Curr Rev Musculoskelet Med* 2014;7:292-301.
- Cheng XY, Liu FX, Xiong F, Huang YJ, Paulus AC. Radiographic changes and clinical outcomes after open and closed wedge high tibial osteotomy: a systematic review and meta-analysis. *J Orthop Surg Res* 2019;14:179.
- Ogata K. Interlocking wedge osteotomy of the proximal tibia for gonarthrosis. *Clin Orthop Relat Res* 1984;186:129-134.
- Staubli AE, De Simoni C, Babst R, Lobenhoffer P. TomoFix: a new LCP-concept for open wedge osteotomy of the medial proximal tibia—early results in 92 cases. *Injury* 2003;34:B55-B62 (Suppl 2).
- Goshima K, Sawaguchi T, Shigemoto K, Iwai S, Nakanishi A, Ueoka K. Patellofemoral osteoarthritis progression and alignment changes after open-wedge high tibial osteotomy do not affect clinical outcomes at mid-term follow-up. *Arthroscopy* 2017;33:1832-1839.
- Goshima K, Sawaguchi T, Shigemoto K, et al. Large opening gaps, unstable hinge fractures, and osteotomy line below the safe zone cause delayed bone healing after open-wedge high tibial osteotomy. *Knee Surg Sports Traumatol Arthrosc* 2019;27:1291-1298.
- Woodacre T, Ricketts M, Evans JT, et al. Complications associated with opening wedge high tibial osteotomy—a review of the literature and of 15 years of experience. *Knee* 2016;23:276-282.
- Lee SS, So SY, Jung EY, Kim HJ, Lee BH, Wang JH. Predictive factors for patellofemoral degenerative progression after opening-wedge high tibial osteotomy. *Arthroscopy* 2019;35:1713-1720.
- Kaya H, Dastan AE, Bicer EK, Taskiran E. Posteromedial open-wedge high tibial osteotomy to avoid posterior tibial slope increase. *Arthroscopy* 2020;36:2710-2717.