



Aalborg Universitet

AALBORG UNIVERSITY  
DENMARK

**Ten-year comparison of two different techniques for femoral bone cavity preparation-broaching versus compaction in patients with cementless total hip arthroplasty**

*a randomized radiostereometric study of 30 total hip arthroplasties in 15 patients operated bilaterally*

Okowinski, Maciej; Hjorth, Mette Holm; Mosegaard, Sebastian Breddam; Jürgens-Lahnstein, Jonathan Hugo; Storgaard Jakobsen, Stig; Hedevang Christensen, Poul; Kold, Søren; Stilling, Maiken

*Published in:*  
Bone & joint open

*DOI (link to publication from Publisher):*  
[10.1302/2633-1462.212.BJO-2021-0152.R1](https://doi.org/10.1302/2633-1462.212.BJO-2021-0152.R1)

*Creative Commons License*  
CC BY-NC-ND 4.0

*Publication date:*  
2021

*Document Version*  
Publisher's PDF, also known as Version of record

[Link to publication from Aalborg University](#)

*Citation for published version (APA):*

Okowinski, M., Hjorth, M. H., Mosegaard, S. B., Jürgens-Lahnstein, J. H., Storgaard Jakobsen, S., Hedevang Christensen, P., Kold, S., & Stilling, M. (2021). Ten-year comparison of two different techniques for femoral bone cavity preparation-broaching versus compaction in patients with cementless total hip arthroplasty: a randomized radiostereometric study of 30 total hip arthroplasties in 15 patients operated bilaterally. *Bone & joint open*, 2(12), 1035-1042. <https://doi.org/10.1302/2633-1462.212.BJO-2021-0152.R1>

**General rights**

Copyright and moral rights for the publications made accessible in the public portal are retained by the authors and/or other copyright owners and it is a condition of accessing publications that users recognise and abide by the legal requirements associated with these rights.

- Users may download and print one copy of any publication from the public portal for the purpose of private study or research.
- You may not further distribute the material or use it for any profit-making activity or commercial gain
- You may freely distribute the URL identifying the publication in the public portal -

# Ten-year comparison of two different techniques for femoral bone cavity preparation—broaching versus compaction in patients with cementless total hip arthroplasty

A RANDOMIZED RADIOSTEREOMETRIC STUDY OF 30 TOTAL HIP ARTHROPLASTIES IN 15 PATIENTS OPERATED BILATERALLY



**M. Okowinski,  
M. H. Hjorth,  
S. B. Mosegaard,  
J. H. Jürgens-  
Lahnstein,  
S. Storgaard  
Jakobsen,  
P. Hedevang  
Christensen,  
S. Kold,  
M. Stilling**

From Aarhus University  
Hospital, Aarhus,  
Denmark

## Aims

Femoral bone preparation using compaction technique has been shown to preserve bone and improve implant fixation in animal models. No long-term clinical outcomes are available. There are no significant long-term differences between compaction and broaching techniques for primary total hip arthroplasty (THA) in terms of migration, clinical, and radiological outcomes.

## Methods

A total of 28 patients received one-stage bilateral primary THA with cementless femoral stems (56 hips). They were randomized to compaction on one femur and broaching on the contralateral femur. Overall, 13 patients were lost to the ten-year follow-up leaving 30 hips to be evaluated in terms of stem migration (using radiostereometry), radiological changes, Harris Hip Score, Oxford Hip Score, and complications.

## Results

Over a mean follow-up period of 10.6 years, the mean stem subsidence was similar between groups, with a mean of -1.20 mm (95% confidence interval (CI) -2.28 to -0.12) in the broaching group and a mean of -0.73 mm (95% CI -1.65 to 0.20) in the compaction group ( $p = 0.07$ ). The long-term migration patterns of all stems were similar. The clinical and radiological outcomes were similar between groups. There were two intraoperative fractures in the compaction group that were fixed with cable wire and healed without complications. No stems were revised.

## Conclusion

Similar stem subsidence and radiological and clinical outcomes were identified after the use of compaction and broaching techniques of the femur at long-term follow-up. Only the compaction group had intraoperative periprosthetic femur fractures, but there were no long-term consequences of these.

**Cite this article:** *Bone Jt Open* 2021;2-12:1035–1042.

**Keywords:** Compaction, Broaching, Total hip arthroplasty, Radiostereometry, Ten-year follow-up, Cementless

Correspondence should be sent to  
Maciej Okowinski; email:  
maciek3233@wp.pl

doi: 10.1302/2633-1462.212.BJO-  
2021-0152.R1

*Bone Jt Open* 2021;2-12:1035–  
1042.

## Introduction

Total hip arthroplasty (THA) is the standard procedure for hip osteoarthritis (OA). The Danish Hip Arthroplasty Register,<sup>1</sup> the Australian Orthopaedic Association

National Joint Replacement Registry,<sup>2</sup> and the Dutch Arthroplasty Register<sup>3</sup> report ten-year femoral stem survival in patients with primary OA to be between 94.8% and 99% for cementless stems and between 95% and

96.4% for cemented stems. A good primary fixation of cementless femoral stems is important for stability, osseointegration, and long-term survival.<sup>4</sup> Stem stability can be measured prospectively using radiostereometric analysis (RSA). The migration pattern at two years is a good predictor of long-term stem survival. In cementless stem fixation, two-year migration should not exceed 1.5 mm in order to avoid early and mid-term revisions.<sup>5</sup> Long-term migration RSA studies are few, but important to substantiate the predictive value of early migration results.<sup>5,6</sup>

Experimentally, it has been shown that bone compaction technique preserves more bone and provides superior implant fixation than the standard broaching technique.<sup>7,8</sup> Clinical studies have not shown a difference between the two techniques in terms of periprosthetic BMD preservation, RSA-measured stem subsidence, and retroversion at five years.<sup>9,10</sup> No long-term results are available.

The aim of this RCT was to compare the ten-year outcomes and safety of compaction and broaching surgical techniques with regard to 1) stem migration assessed with RSA, 2) radiological evaluation, and 3) clinical outcomes and complications.

## Methods

**Patients and methods.** This study was designed as a patient- and assessor-blinded, randomized, paired controlled trial investigating 28 patients undergoing bilateral primary THA surgery. Patients underwent operation from May 2001 to September 2007. The five-year stem migration and periprosthetic BMD changes have been published previously.<sup>10</sup> This study covers a mean 10.6 -year (9.9 to 12.3) cross-sectional follow-up study measuring cementless stem migration using RSA, radiological evaluation, and clinical outcomes. The inclusion criteria were bilateral, symptomatic, and radiologically diagnosed OA of the hip, age 18 to 70 years, and bone quality suitable for a cementless femoral stem. Exclusion criteria were severe bone deformities, neuromuscular or vascular leg diseases, metabolic or inflammatory bone disorders (including rheumatoid arthritis), regular glucocorticoid treatment, malignant cancer with ongoing chemotherapy, planning pregnancy, chronic infectious disease, and osteoporosis diagnosis. The patients were bilaterally operated with a THA in one surgical session. All patients received compaction technique on one hip and broaching technique on the other hip. The patients were randomized into blocks of ten using software, and the results were kept in sealed envelopes. Half of the patients were positioned first on the right side, and the other half were positioned first on the left side. The randomization envelope for the first and the second hip was drawn after positioning of the patient. Surgeries were performed at Farsoe Hospital and Aalborg University Hospital. The ten-year cross-sectional follow-up hip radiographs and

stereoradiographs were conducted at Aarhus University Hospital (18 hips, 12 males) and Farsoe Hospital (12 hips, 8 males). Details of patient enrolment are described in Figure 1.

**Prosthesis and instruments.** The original surgical instruments were used for insertion of the cementless Bi-Metric femoral stems (Zimmer Biomet, USA). The upper part of the toothed broaches had a diamond-shaped surface, and the distal half had a smooth surface. The tamps used for compaction of the femoral bone cavity had a smooth surface. For each of the broach sizes, the corresponding tamp size was of the same volume but without the rough proximal area.<sup>10</sup> Cementless Bi-Metric stems without hydroxyapatite (HA) coating (Zimmer Biomet) and 28 mm chrome-cobalt femoral heads were used for all patients in this study. On the acetabular side, six patients received cementless Trilogly Fiber-mesh shells and Trilogly ultra-high-molecular-weight polyethylene (UHMWPE) 10° elevated rim liners (Zimmer Biomet), six patients received cementless HA-coated Trilogly Fiber-mesh shells and Trilogly UHMWPE 10° elevated rim liners (Zimmer Biomet), and eight patients received Longevity highly crosslinked 10° elevated rim liners (Zimmer Biomet). All patients were allowed ambulation with 40 kg of weightbearing (aided by crutches) for the first six weeks after surgery, and thereafter full weightbearing was allowed.

**Surgery.** All surgeries were performed by one experienced hip surgeon (PHC) using a posterolateral approach. Compaction was performed with distal reaming, using first a cylindrical reamer to open the femoral canal and then smooth tamps of increasing sizes to prepare the proximal bone. Broaching was performed in a similar fashion, with opening of the femoral canal first, followed by the use of increasingly large toothed broaches to prepare the proximal bone. The recommendations from the manufacturer were followed.

**Radiostereometric analysis.** Eight to ten tantalum markers of  $\varnothing$  1 mm were inserted into the greater and lesser trochanter of the femur as preparation for RSA. All stems were marked with three small marker towers ( $\varnothing$ :1 mm tantalum beads; Wennbergs Finmek, Sweden). The marker towers were placed as follows: one on the tip of the stem, one on the calcar region, and one on the shoulder (proximal-lateral) of the stem. The stereoradiographs were performed at Aarhus University Hospital and Farsoe Hospital with the use of standard radiostereometry set-up consisting of two synchronized ceiling-fixed roentgen tubes angled towards each other at an angle of 40° (Arco-Ceil/Medira; Santax Medico, Sweden). The uniplanar carbon calibration box at Aarhus University Hospital was Box 24 (Medis Specials, the Netherlands), and the uniplanar carbon calibration box at Farsoe Hospital was Box 43 (RSA Biomedical, Sweden). Stereoradiographs were performed with the patient in a standardized supine position, with the body parallel to the examination

**Table 1.** Measurement error for the radiostereometric double-examination stereo radiographs (n = 17 hips), for translations and rotations at the five- and ten-year measurement.

Axis	Translation, mm				Rotation, °			
	X	Y	Z	TT*	X	Y	Z	TR†
Mean diff.‡	0.01	0.00	0.02	-0.03	-0.05	0.14	0.01	0.12
SD diff.§	0.07	0.09	0.19	0.17	0.24	0.43	0.08	0.42
CR	0.14	0.17	0.37	0.34	0.48	0.85	0.16	0.83

\*The total translation was calculated using 3D Pythagorean theorem ( $TT = \sqrt{x^2 + y^2 + z^2}$ ).

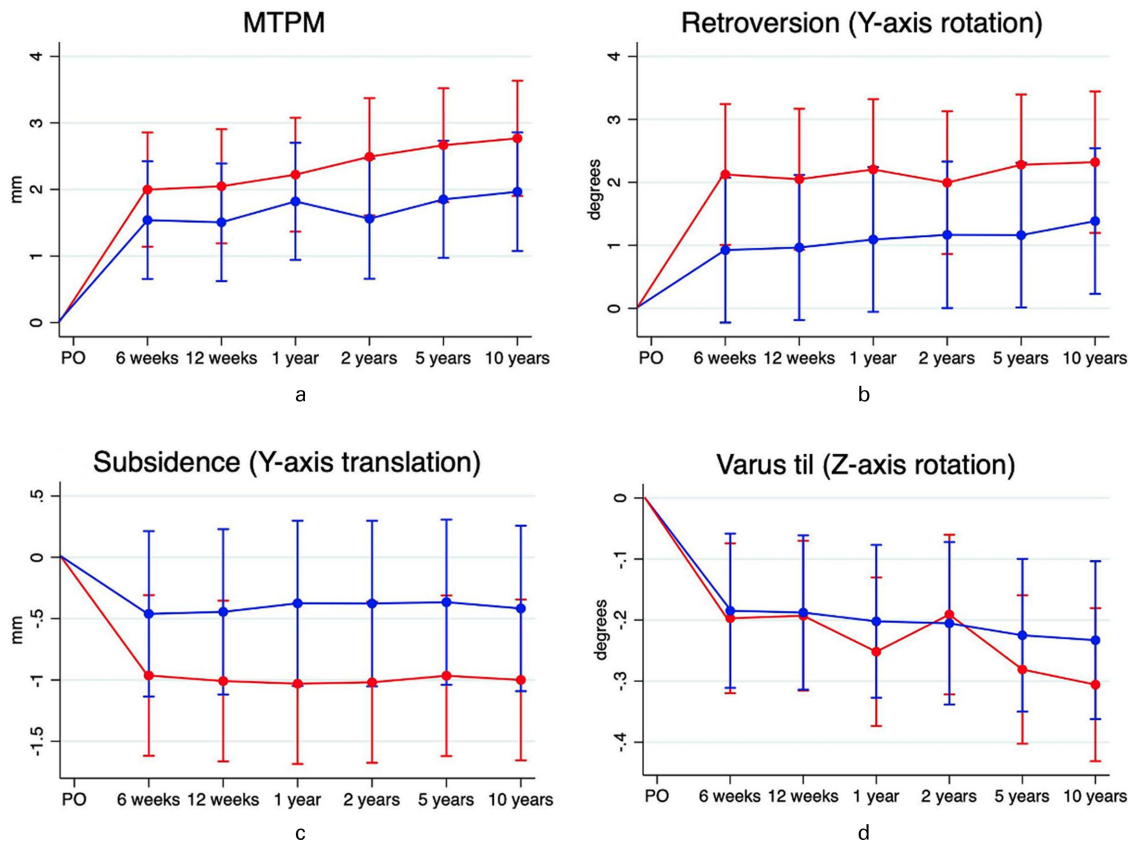
†The total rotation was calculated using the 3D Pythagorean theorem ( $TR = \sqrt{x^2 + y^2 + z^2}$ ).

‡Mean difference represents the systemic error (bias) of the method.

§SD. Diff. is the difference in the random variation in the method comparing the double examinations.

¶Coefficient of repeatability ( $1.96 \times SD_{diff}$ ) reflects the precision of the system on the individual basis.

CR, coefficient of repeatability; SD, standard deviation; TR, total rotation; TT, total translation.

**Fig. 2**

Migration pattern from postoperative (PO) to ten years' follow-up of the broaching (red) and compaction (blue) stem group regarding a) maximum total point motion (MTPM), b) retroversion, c) subsidence, and d) varus tilt.

table and the calibration box underneath the table.<sup>11</sup> Stereoradiographs were taken postoperatively (before weightbearing) at six and 12 weeks and at one, two, five, and ten years.

The follow-up stem migrations were analyzed with reference to the baseline exposure and the coordinate system of the calibration box. Model-based RSA (MBRSA) version 4.2015 (RSAcore, the Netherlands) was used to analyze stem migrations. A combined large marker hip model (LMHM) was used for the analysis of 12 broaching and 12 compaction stems. Three broaching and two

compaction stems were analyzed using an elementary geometrical shape (EGS) hip-stem model<sup>12</sup> due to broken-off implant marker towers, which made marker-based hip-stem migration impossible. One stem was analyzed using CAD model.

The total translations (TTs) and total rotations (TRs) were calculated using the Pythagorean theorem ( $TT = \sqrt{x^2 + y^2 + z^2}$  and  $TR = \sqrt{x^2 + y^2 + z^2}$ ). An upper limit of  $\leq 150$  for the condition number (CN) was used, as suggested in the guidelines for RSA of implants.<sup>4</sup> During long-term studies, stem and bone markers can become

**Table II.** Patient demographic data and radiological evaluation of stems at ten years' follow-up.

Variable	Broaching (n = 15)	Compaction (n = 15)
<b>Demographic</b>		
Sex, % (female n)	40 (6)	40 (6)
Mean age, yrs (range)	57 (36 to 63)	57 (36 to 63)
Side (% left side)	50	50
Mean stem size (range)	11.9 (7 to 14)	11.8 (7 to 14)
<b>Stem alignment, n</b>		
Neutral	15	14
Varus	0	1
Valgus	0	0
<b>Heterotopic ossification, Brooker classification, n</b>		
None	8	5
Class I	2	6
Class II	2	3
Class III	3	1
Class IV	0	0
<b>Hip stem-tip ossification: hypertrophy, n</b>		
Detected	4	3
Not detected	11	12
<b>Femur Dorr type-classification</b>		
Type A (< 0.5)	8	8
Type B ( $\leq 0.5 < 0.75$ )	7	7
Mean Dorr ratio (SD)	0.47 (1.0)	0.49 (0.8)
Radiolucent lines in 7 Gruen zones	None	None
Polyethylene wear	3	2
<b>Complications</b>		
Dislocation treated with reoperation and constrained liners	1	1
Intraoperative periprosthetic fracture	0	2
Mean HHS (SD)	91 (19)	87 (21)
Mean OHS (SD)	44 (8)	42 (9)

Self-assessed HHS multiplied by factor 1.11 (100/90 = 1.11), in order to convert to 100-point scale.

HHS, Harris Hip Score; OHS, Oxford Hip Score; SD, standard deviation.

missing, migrate, or loosen. Therefore, we accepted a CN of 184.9 in one patient treated with femoral bone compaction because the migration pattern was similar to other stems and did not raise suspicion of stem loosening. The mean CN of the stem markers and femoral bone markers were 32.3 (SD 3.70) and 72.1 (SD 33.0), respectively. The stability of the markers can be expressed through rigid body error (RBE), which was 0.16 (SD 0.09) and 0.22 (SD 0.07) for the stem and the femoral bone, respectively. The rigid body match threshold was set at 0.35 mm<sup>4</sup>.

**Sample size.** No pre-study power analysis was performed. Small-scale studies is standard in RSA due to high precision of preclinical testing and of new components and procedures.<sup>4</sup> The patient- and assessor-blinded bilateral design, with each patient serving as his/her own control, is the strongest comparative study design.

**Table III.** Signed migrations (mm) of the Bi-metric femoral stem as predicted means (95% confidence intervals) along and about the three orthogonal axes, measured with radiostereometric analysis at six weeks, and one, five, and ten years after surgery.

Variable	Compaction	Broaching
<b>Medial(+)-lateral(-) (x-axis)</b>		
6 wks	0.10 (-0.01 to 0.21)	0.06 (-0.05 to 0.17)
1 yr	0.11 (0.00 to 0.22)	0.01 (-0.04 to 0.18)
5 yrs	0.13 (0.02 to 0.24)	0.06 (-0.50 to 0.16)
10 yrs	0.15 (0.03 to 0.27)	0.10 (-0.20 to 0.22)
<b>Proximal(+)-distal(-) (y-axis)</b>		
6 wks	-0.46 (-1.14 to 0.21)	-0.96 (-1.62 to -0.31)
1 yr	-0.38 (-1.05 to 0.30)	-1.03 (-1.69 to -0.38)
5 yrs	-0.37 (-1.04 to 0.31)	-0.97 (-1.62 to -0.31)
10 yrs	-0.81 (-1.53 to -0.08)	-1.13 (-1.86 to -0.41)
<b>Anterior(+)-posterior(-) (z-axis)</b>		
6 wks	-0.18 (-0.49 to 0.14)	-0.40 (-0.70 to -0.09)
1 yr	-0.15 (-0.46 to 0.16)	-0.28 (-0.58 to 0.02)
5 yrs	-0.08 (-0.39 to 0.24)	-0.11 (-0.41 to 0.20)
10 yrs	-0.25 (-0.56 to 0.07)	-0.32 (-0.63 to -0.01)
<b>TT</b>		
6 wks	0.65 (-0.03 to 1.34)	1.18 (0.51 to 1.85)
1 yr	0.68 (-0.01 to 1.36)	1.28 (0.62 to 1.95)
5 yrs	0.73 (0.05 to 1.42)	1.26 (0.59 to 1.93)
10 yrs	0.80 (0.12 to 1.49)	1.35 (0.68 to 2.02)
<b>MTPM</b>		
6 wks	1.54 (0.66 to 2.42)	2.00 (1.14 to 2.86)
1 yr	1.82 (0.94 to 2.70)	2.22 (1.37 to 3.08)
5 yrs	1.85 (0.97 to 2.73)	2.67 (1.81 to 3.52)
10 yrs	1.97 (1.07 to 2.86)	2.77 (1.90 to 3.63)
<b>Anterior(+)-posterior(-) tilt (x-axis)</b>		
6 wks	0.07 (-0.21 to 0.35)	0.07 (-0.20 to 0.34)
1 yr	-0.01 (-0.28 to 0.26)	0.01 (-0.25 to 0.28)
5 yrs	-0.09 (-0.36 to 0.19)	-0.20 (-0.47 to 0.07)
10 yrs	0.05 (-0.22 to 0.33)	-0.06 (-0.33 to 0.22)
<b>Retroversion(+)-anteversion(-) (y-axis)</b>		
6 wks	0.92 (-0.23 to 2.08)	2.12 (1.01 to 3.24)
1 yr	1.09 (-0.06 to 2.24)	2.20 (1.09 to 3.32)
5 yrs	1.16 (0.01 to 2.31)	2.28 (1.16 to 3.40)
10 yrs	1.72 (0.47 to 2.97)	2.55 (1.30 to 3.80)
<b>Valgus(+)-varus(-) tilt (z-axis)</b>		
6 wks	-0.18 (-0.31 to -0.06)	-0.20 (-0.32 to -0.07)
1 yr	-0.20 (-0.33 to -0.08)	-0.25 (-0.37 to -0.13)
5 yrs	-0.23 (-0.35 to -0.10)	-0.28 (-0.40 to -0.16)
10 yrs	-0.26 (-0.40 to -0.12)	-0.32 (-0.47 to -0.18)
<b>TR</b>		
6 wks	1.38 (0.29 to 2.47)	2.23 (1.18 to 3.29)
1 yr	1.61 (0.52 to 2.69)	2.33 (1.28 to 3.39)
5 yrs	1.55 (0.46 to 2.64)	2.50 (1.44 to 3.55)
10 yrs	1.78 (0.68 to 2.87)	2.63 (1.56 to 3.69)

MTPM, maximum total point motion; TR, total rotation; TT, total translation.



**Precision of the radiostereometric analysis.** The precision of the RSA analyses was tested by double examinations of 17 hips. The baseline stereoradiographs were used as reference in the migration analysis of the double examination (Table I).

**Radiological evaluation.** Ten-year follow-up pelvic radiographs were evaluated using the Impax software (IMPAX Orthopaedic Tools Version 3.0.2.3, USA) and compared with postoperative and five-year radiographs. A consensus evaluation was performed between a researcher (MO) and an experienced surgeon (SSJ). The evaluation points were: stem alignment in relation to the femoral bone marrow cavity (an angle below  $3^\circ$  was accepted as neutral),<sup>13</sup> heterotopic ossifications using the Brooker classification,<sup>14</sup> hip stem-tip ossification hypertrophy,<sup>15</sup> femoral bone quality and thickness of the bone cortex according to the femur Dorr type classification,<sup>16</sup> radiolucent lines in Gruen Zones 1 to 7,<sup>17</sup> visual indication of polyethylene wear in the form of a decentralized femoral head in the acetabular metal backing, and surgical complications (Table II).

**Clinical outcome measures and complications.** All the patients were evaluated using two standardized PROMs for assessment of THA in terms of OHS and subjective aspects of the modified HHS.<sup>18,19</sup> The modified HHS excluded the physician's assessment of hip mobility; therefore, a score from 38 to 90 was given. To normalize the self-assessed score to the classical HHS, the modified HHS was multiplied by a factor of 1.11 ( $100/90 = 1.11$ ). The scale was interpreted as follows:  $< 70$  = poor result,  $70$  to  $80$  = fair,  $80$  to  $90$  = good, and  $90$  to  $100$  = excellent.<sup>20</sup> Likewise, the OHS ranged from 22 to 48 points, with 48 as least severe pain (48 best, 0 worst).<sup>21</sup> Patients also completed questionnaires concerning satisfaction with the THA surgery and any revision surgeries.

**Statistical analysis.** Normality of continuous variables was evaluated using quantile-quantile plots. Descriptive statistics were used to characterize the study sample (means, medians, standard deviations (SDs), and confidence intervals (CIs)). All patients were evaluated and included in the analysis of stem migration until dropout. Linear mixed-model analysis was used for analysis of RSA-measured component migration from postoperative to ten years. Mixed model was used, as it considers the longitudinal nature of the data and repeated measurements in individual patients. Data distribution assumptions for mixed model analysis were controlled using residual quantile-quantile plots and fitted versus residual plots. The migration data are reported and presented as predicted means with 95% CIs (Table III, Figure 2). However, individual migrations should exceed the precision limit estimate based on double RSA measurements in order to be considered measurable and clinically relevant. At ten years, the comparison between stem subsidence and stem version was tested using a paired *t*-test. Stem

subsidence greater than  $1.5 \text{ mm}^5$  at ten years' follow-up were compared using Fisher's exact test. Clinical outcome questionnaire scores were compared using independent-samples *t*-tests and paired *t*-tests. The statistical analyses were performed using STATA, Version 15 IC (Stata Corp, USA) and Microsoft Excel (Microsoft Office 360 ProPlus, USA), with a significance level of 0.05.

**Ethics and registration.** All examinations were designed and performed in accordance with the Helsinki Declaration (II).<sup>22</sup> All patients gave informed consent before entering the study. The research was approved by the Central Denmark Regional Committee on Biomedical Research (entry no. 2000065; issue date 4 January 2000) and by the Danish Data Protection Agency (protocol no. 1-16-02-62-09). The project was registered with [www.clinicaltrials.gov](http://www.clinicaltrials.gov) (NCT00317889). The reporting of data from this trial complies with the CONSORT statement.

## Results

**RSA-analyzed stem migration.** There were no statistically significant differences in stem migration between the broaching and compaction groups. One patient had a notable stem subsidence and retroversion in the first six weeks after surgery on both the compaction stem ( $-6.1 \text{ mm}$ ,  $11.8^\circ$ ) and the broaching stem ( $-7.1 \text{ mm}$ ,  $13.1^\circ$ ). From six weeks until ten years, there was additional  $0.5 \text{ mm}$  subsidence of both stems. The compaction side had an intraoperative fracture that was fixed with a cable wire. The broaching side had no indications of intraoperative fractures. At group level, stem subsidence and retroversion occurred mainly within the first six postoperative weeks (Table III). At ten years, the paired mean stem subsidence was  $-0.73 \text{ mm}$  (95% CI  $-1.65$  to  $0.20$ ) in the compaction group and  $-1.20 \text{ mm}$  (95% CI  $-2.28$  to  $-0.12$ ) in the broaching group ( $p = 0.07$ , paired *t*-test). Nine stems (eight males) in the broaching group and ten stems (seven males) in the compaction group subsided beyond the precision limit of  $0.17 \text{ mm}$ . Considering the two-year migration threshold of  $1.5 \text{ mm}$ , two hips in the compaction group and five hips in the broaching group subsided beyond this limit ( $p = 0.39$ , paired *t*-test) (Figure 3). At ten years, the paired mean stem version ( $\gamma$ -rotation) was at mean  $1.95^\circ$  (95% CI  $0.25$  to  $3.66$ ) retroversion in the compaction group and  $2.53^\circ$  (95% CI  $0.69$  to  $4.37$ ) retroversion in the broaching group ( $p = 0.18$ , paired *t*-test). A total of 11 broached stems (eight males) and ten compaction stems (seven males) had stem version above the precision limit of  $0.85^\circ$  ( $p = 1.00$ , paired *t*-test), and in all cases, this was retroversion (Figure 2).

**Radiological evaluation.** One male patient had a visible varus stem alignment on the left hip in the compaction group, but the stem subsidence at ten years' follow-up was within the 95% CI of the compaction group. Heterotopic ossification according to Brooker's classification<sup>14</sup> was similar for the compaction and broaching

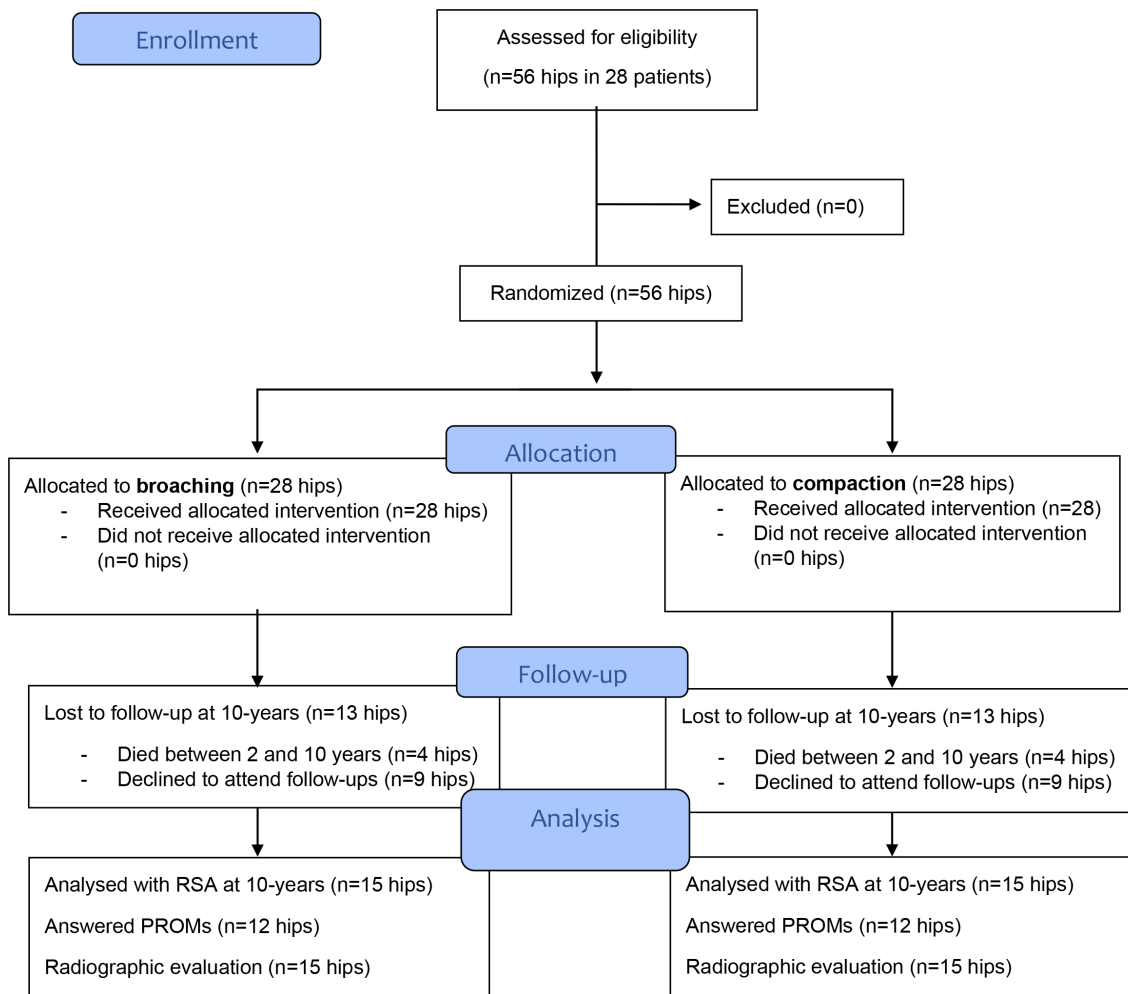


Fig. 1

Consort flow diagram showing the inclusion/exclusion process and follow-up until ten years. PROM, patient-reported outcome measure; RSA, radiostereometric analysis.

groups. Hip stem-tip femoral bone ossification occurred in three femora in the broaching group and in three femora in the compaction group. The radiographs did not show any radiolucent lines in Gruen zones 1 to 7. Dorr type ratio had an equal distribution of eight A types and seven B types within both stem groups. The mean Dorr ratio was 0.47 (SD 1.0) in the broaching group and 0.49 (SD 0.8) in the compaction group ( $p = 0.61$ ). There was no correlation between the Dorr ratio and migration along the three orthogonal axes. Five patients had signs of polyethylene wear on the radiographs. Clinical outcomes (HHS and OHS) were excellent (Table II).

**Clinical outcome measures and complications.** At ten years' follow-up, the modified HHS and OHS scores were comparable between the broaching and compaction groups. The mean value of the normalized HHS in the total patient group was 89 (42 to 100). The mean normalized HHS was 91 (42 to 100) in the broaching group and 87 (42 to 100) in the compaction group. The

mean ten-year OHS score was 43 (22 to 48). The group-specific mean scores were 44 (22 to 48) in the broaching group and 42 (22 to 48) in the compaction group (Table II).

Intraoperative fractures occurred in two of the 15 femora in the compaction group, whereas none were recognized intraoperatively in the broaching group ( $n = 15$ ). The two fractures were fixed with cerclage cables and off-loading for six weeks. Both stems obtained stability at six weeks after surgery (-0.38 mm and -5.37 mm).

Repeated hip dislocation occurred in two THAs (one in the compaction group and one in the broaching group). The hips were reoperated two to three years after primary surgery to constrained liners. Another hip dislocation was successfully resolved with a closed reduction at ten years' follow-up. No deep or superficial infections occurred, and no stem or cup components were revised during the ten-year follow-up.

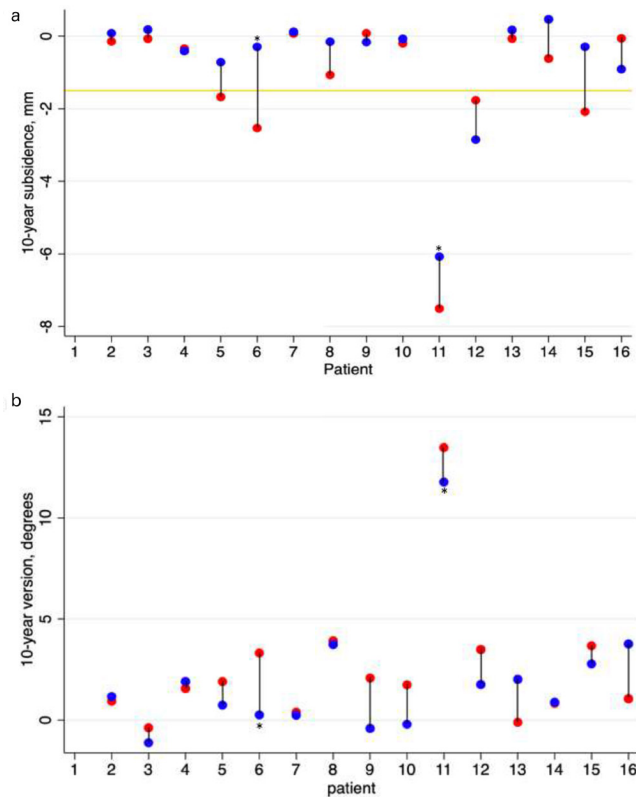


Fig. 3

a) Subsidence (negative y-translation in mm) and b) retroversion (positive y-rotation in mm) illustrated as a pairwise comparison of broaching (red) and compaction (blue) at mean 10.6 -year follow-up. Patients with an intraoperative fracture are marked with \*. The yellow line represents the two-year 1.5 mm subsidence limit.

## Discussion

In this ten-year blinded, randomized bilateral study, we found similar stem migration at all follow-ups comparing broaching versus compaction preparation of the femoral cavity. Two femora in the compaction group had intraoperatively recognized femur fractures, which were treated with wire cables and off-loading and healed until six-week follow-up, with no consequences for stem subsidence or revision.

Primary implant stability is essential in the early postoperative phase of cementless implants to allow for osseointegration, secondary fixation, and good long-term survival. Few studies have investigated migration of the Bi-Metric stem, although it is a widely used cementless stem in Nordic countries.<sup>9,23</sup> We found that stem group migrations primarily occurred within the first six weeks, which is in accordance with the current literature.<sup>9,23</sup> It has been suggested that early stem subsidence (< two years) increases the risk of later aseptic stem loosening in various cementless femoral stem types.<sup>5</sup> In the present study, both stem groups showed a stable migration pattern both in the short term and long term, with no group differences. Kärrholm et al<sup>5</sup> described evidence of an increased risk for cementless stem migration > 1.5 mm within the first two years after THA. In the present

study, 5/15 stems in the broaching group and 2/15 stems in the compaction group migrated above this risk level, but paired comparison of mean subsidence did not show a statistically significant difference. Long-term stem migration studies are important to establish the migration patterns of different stem types and to confirm and re-define early migration thresholds from cases with aseptic loosening.

Periprosthetic fractures around cementless stems are not uncommon. Zhu et al<sup>24</sup> found female sex, age > 80 years, and rheumatoid arthritis to be risk factors for periprosthetic fracture, while OA was a protective factor (OR 0.45). In our study, only men had fractures, patients were younger (mean age 56 years), and the indication for THA was OA. Therefore, the two periprosthetic fractures in the present study were likely related to the compaction procedure. The stem migration pattern in the two intraoperatively recognized fracture cases did not differ from the other well-fixed stems in the compaction group (< 1.5 mm subsidence). One patient had excessive early stem subsidence of both hip stems (compaction and broaching). There was a periprosthetic fracture on the compaction side, and both hip stems seemed undersized upon radiological evaluation, which could explain the extraordinary stem migration.

Long-term HHS outcomes ten years after THA surgery have been reported in the range of mean 86 to 91 points,<sup>15</sup> which is in line with a mean 89 points in our study. We found no statistically significant or clinically relevant differences in HHS between groups. Long-term OHS outcomes > ten years after THA surgery have been reported with a mean of 40.3 points.<sup>25</sup> We found similar excellent results, which indicate a generally high functional level of the patient group. No stems were revised within the 10.6 -year follow-up. This is in line with a report on survival from the DHAR-2020, which reported a 99% 10 year survival rate of cementless stems.<sup>1</sup>

A major strength of this study is the paired design, in which the patient serves as his or her own control due to the bilateral THA procedure. Additionally, all the operations were performed by the same experienced orthopaedic surgeon, reducing the variability of the operator's skill. However, the ten-year follow-up was naturally limited by patient comorbidities. In total, 13 patients were lost to the ten-year follow-up (46%). This large number of patients lost to follow-up is to be expected in a study with ten years' follow-up. However, these 13 patients were not statistically significantly different from the patients with complete follow-up with regard to both age and sex.

In conclusion, similar stem subsidence, and radiological and clinical outcomes, were identified after the use of compaction and broaching techniques of the femur at long-term follow-up. Only the compaction group had intraoperative periprosthetic femur fractures, but there were no long-term consequences of these. Intraoperative periprosthetic fractures were only found in the compaction group, and although there were no long-term consequences, avoidance of fracture risks is the preferred, safer option.





### Take home message

- Long-term stem migration was similar with compaction and broaching technique.

- Intraoperative periprosthetic fractures were only found in the compaction group.

### References

- No authors listed.** Danish Hip Arthroplasty Register: National Annual Report 2020. Danish Hip Arthroplasty Register. 2020. [http://danskhoftaaloplastikregisterdanskhoftaaloplastikregister.dk/wp-content/uploads/2020/11/dhr-aarsrapport-2020\\_til\\_offentliggørelse-1.pdf](http://danskhoftaaloplastikregisterdanskhoftaaloplastikregister.dk/wp-content/uploads/2020/11/dhr-aarsrapport-2020_til_offentliggørelse-1.pdf) (date last accessed 10 November 2021).
- No authors listed.** Australian Orthopaedic Association National Joint Replacement Registry: Hip, Knee & Shoulder Arthroplasty. Australian Orthopaedic Association. 2020. <https://aoanjr.sahmri.com/documents/10180/689619/Hip%2C+Knee+%26+Shoulder+Arthroplasty+New/6a07a3b8-8767-06cf-9069-d165dc9baca7> (date last accessed 10 November 2021).
- No authors listed.** Online LROI annual report 2019. Dutch Arthroplasty Register. 2019. <https://www.lroi-report.nl/app/uploads/2020/10/PDF-Online-LROI-annual-report-2019-min.pdf> (date last accessed 10 November 2021).
- Valstar ER, Gill R, Ryd L, Flivik G, Börlin N, Kärrholm J.** Guidelines for standardization of radiostereometry (RSA) of implants. *Acta Orthop.* 2005;76(4):563–572.
- Kärrholm J, Herberts P, Hultmark P, Malchau H, Nivbrant B, Thanner J.** Radiostereometry of hip prostheses. Review of methodology and clinical results. *Clin Orthop Relat Res.* 1997;344:94–110.
- Kärrholm J, Gill RH, Valstar ER.** The history and future of radiostereometric analysis. *Clin Orthop Relat Res.* 2006;448:10–21.
- Green JR, Nemzek JA, Arnoczky SP, Johnson LL, Balas MS.** The effect of bone compaction on early fixation of porous-coated implants. *J Arthroplasty.* 1999;14(1):91–97.
- Kold S, Rahbek O, Toft M, Ding M, Overgaard S, Søballe K.** Bone compaction enhances implant fixation in a canine gap model. *J Orthop Res.* 2005;23(4):824–830.
- Hjorth MH, Kold S, Søballe K.** Preparation of the Femoral Bone Cavity for Cementless Stems: Broaching vs Compaction. A Five-Year Randomized Radiostereometric Analysis and Dual Energy X-Ray Absorption Study. *J Arthroplasty.* 2017;32(6):1894–1901.
- Hjorth MH, Stilling M, Søballe K, Nielsen PT, Christensen PH, Kold S.** Preparation of the femoral bone cavity in cementless stems: broaching versus compaction. *Acta Orthop.* 2016;87(6):575–582.
- Lindgren L, Jørgensen PB, Mørup RMS, et al.** Similar patient positioning: A key factor in follow-up studies when using model-based radiostereometric analysis of the hip. *Radiography.* 2020;26(2):e45–e51.
- Kaptein BL, Valstar ER, Spoor CW, Stoel BC, Rozing PM.** Model-based RSA of a femoral hip stem using surface and geometrical shape models. *Clin Orthop Relat Res.* 2006;448:92–97.
- TR, WS, HM, et al.** DOES varus or VALGUS alignment of the EXETER stem influence survival or patient outcome in total hip arthroplasty? A review of 4126 cases with a minimum follow-up of five years. *Orthopaedic Proceedings.* 2019;101-B:22.
- Hug KT, Alton TB, Gee AO.** Classifications in brief: Brooker classification of heterotopic ossification after total hip arthroplasty. *Clin Orthop Relat Res.* 2015;473(6):2154–2157.
- Meding JB, Ritter MA, Keating EM, Berend ME.** Twenty-year follow-up of an uncemented stem in primary THA. *Clin Orthop Relat Res.* 2015;473(2):543–548.
- Park CW, Eun HJ, SH O, Kim HJ, Lim SJ, Park YS.** Femoral Stem Survivorship in Dorr Type A Femurs After Total Hip Arthroplasty Using a Cementless Tapered Wedge Stem: A Matched Comparative Study With Type B Femurs. *J Arthroplasty.* 2019;34(3):527–533.
- XD W, Chen Y, Wang ZY.** Comparison of periprosthetic bone remodeling after implantation of anatomic and tapered cementless femoral stems in total hip arthroplasty: A prospective cohort study protocol. *Medicine (Baltimore).* 2018;97(39):e12560.
- Mahomed NN, Arndt DC, McGrory BJ, Harris WH.** The Harris hip score: comparison of patient self-report with surgeon assessment. *J Arthroplasty.* 2001;16(5):575–580.
- Edwards PK, Queen RM, Butler RJ, Bolognesi MP, Lowry Barnes C.** Are Range of Motion Measurements Needed When Calculating the Harris Hip Score? *J Arthroplasty.* 2016;31(4):815–819.
- Harris WH.** Traumatic arthritis of the hip after dislocation and acetabular fractures: Treatment by mold arthroplasty. An end-result study using a new method of result evaluation. *J Bone Joint Surg Am.* 1969;51-A(4):737–755.
- Paulsen A, Odgaard A, Overgaard S.** Translation, cross-cultural adaptation and validation of the danish version of the Oxford hip score: Assessed against generic and disease-specific questionnaires. *Bone Joint Res.* 2012;1(9):225–233.
- World Medical Association.** World Medical Association Declaration of Helsinki: ethical principles for medical research involving human subjects. *JAMA.* 2013;310(20):2191–2194.
- Dyreborg K, Andersen MR, Winther N, Solgaard S, Flivik G, Petersen MM.** Migration of the uncemented Echo Bi-Metric and Bi-Metric THA stems: a randomized controlled RSA study involving 62 patients with 24-month follow-up. *Acta Orthop.* 2020:1–6.
- Zhu Y, Chen W, Sun T, Zhang X, Liu S, Zhang Y.** Risk factors for the periprosthetic fracture after total hip arthroplasty: a systematic review and meta-analysis. *Scand J Surg.* 2015;104(3):139–145.
- Taylor JW, Frampton C, Rothwell AG.** Long-Term Survival of Total Hip Arthroplasty Using Implants From Different Manufacturers. *J Arthroplasty.* 2018;33(2):491–495.

#### Author information:

- M. Okowski, Stud.med, Research Assistant
- M. H. Hjorth, MD, PhD, Orthopaedic Consultant  
AutoRSA Research Group, Orthopaedic Research Unit, Aarhus University Hospital, Aarhus, Denmark.
- S. B. Mosegaard, PhD, Research Assistant, AutoRSA Research Group, Orthopaedic Research Unit, Aarhus University Hospital, Aarhus, Denmark; Department of Orthopedics, Aarhus University Hospital, Aarhus, Denmark.
- J. H. Jürgens-Lahnstein, MD, Research Assistant, AutoRSA Research Group, Orthopaedic Research Unit, Aarhus University Hospital, Aarhus, Denmark; Department of Clinical Medicine, Aarhus University Hospital, Aarhus, Denmark.
- S. Storgaard Jakobsen, MD, PhD, Orthopaedic Consultant, Department of Orthopedics, Aarhus University Hospital, Aarhus, Denmark; Department of Clinical Medicine, Aarhus University Hospital, Aarhus, Denmark.
- P. Hedevang Christensen, MD, Orthopaedic Consultant
- S. Kold, MD, PhD, Orthopaedic Consultant  
Department of Orthopedics, Aalborg University Hospital, Aalborg, Denmark.
- M. Stilling, MD, PhD, Professor, Clinical Professor, Orthopaedic Consultant, AutoRSA Research Group, Orthopaedic Research Unit, Aarhus University Hospital, Aarhus, Denmark; Department of Orthopedics, Aarhus University Hospital, Aarhus, Denmark; Department of Clinical Medicine, Aarhus University Hospital, Aarhus, Denmark.

#### Author contributions:

- M. Okowski: Data curation, Formal analysis, Investigation, Methodology, Visualization, Writing – original draft, Writing – review & editing.
- M. H. Hjorth: Conceptualization, Data curation, Investigation, Methodology, Project administration, Supervision, Writing – review & editing.
- S. B. Mosegaard: Data curation, Formal analysis, Software, Validation, Visualization, Supervision, Writing – original draft, Writing – review & editing.
- J. H. Jürgens-Lahnstein: Visualization, Software, Supervision, Methodology, Writing – review & editing.
- S. Storgaard Jakobsen: Supervision, Data curation, Methodology, Supervision, Writing – review & editing.
- P. Hedevang Christensen: Conceptualization, Data curation, Investigation, Methodology, Resources, Writing – review & editing.
- S. Kold: Conceptualization, Data curation, Investigation, Funding acquisition, Methodology, Project administration, Resources, Writing – review & editing.
- M. Stilling: Conceptualization, Data curation, Formal analysis, Investigation, Methodology, Project administration, Resources, Software, Supervision, Validation, Visualization, Writing – original draft, Writing – review & editing.

#### Funding statement:

- The author or one or more of the authors have received or will receive benefits for personal or professional use from a commercial party related directly or indirectly to the subject of this article. Zimmer Biomet and the Danish Rheumatism Association kindly supported the study financially, but had no influence on the manuscript or publication.

#### Acknowledgements:

- Thank you to Rikke Mørup for her work with study coordination and radiostereometric analyses. Thank you to Poul Torben Nielsen for helping with patient inclusion.

#### Open access funding

- The authors confirm that the open access fee for this study was self-funded.

© 2021 Author(s) et al. This is an open-access article distributed under the terms of the Creative Commons Attribution Non-Commercial No Derivatives (CC BY-NC-ND 4.0) licence, which permits the copying and redistribution of the work only, and provided the original author and source are credited. See <https://creativecommons.org/licenses/by-nc-nd/4.0/>